

Information System for Early Diabetic Retinopathy Diagnostics based on Multiscale Texture Gradient Method

L. S. Godlevsky, N. V. Kresyun, V. P. Martsenyuk, K. S. Shakun, T. V. Tatarchuk, K. O. Prybolovets, L. F. Kalinichenko, M. Karpinski, T. Gancarczyk

Abstract—Structures of eye bottom were extracted using multiscale texture gradient method and color characteristics of macular zone and vessels were verified in CIELAB scale. The difference of average values of L^* , a^* and b^* coordinates of CIE (International Commission of Illumination) scale in patients with diabetes and healthy volunteers was compared. The average value of L^* in diabetic patients exceeded such one in the group of practically healthy persons by 2.71 times ($P < 0.05$), while the value of a^* index was reduced by 3.8 times when compared with control one ($P < 0.05$). b^* index exceeded such one in the control group by 12.4 times ($P < 0.05$). The integrated index on color difference (ΔE) exceeded control value by 2.87 times ($P < 0.05$). More pronounced differences with ΔE were followed by a shorter period of MA appearance with a correlation level at -0.56 ($P < 0.05$). The specificity of diagnostics raised by 2.17 times ($P < 0.05$) and negative prognostic index exceeded such one determined with the expert method by 2.26 times ($P < 0.05$).

Keywords—Diabetic retinopathy, multiscale texture gradient, color spectrum analysis.

I. INTRODUCTION

COLOR is an informative feature in the diagnosis of many diseases. Creating a local feature based on color metrics is an important task of identifying a pathological object. At present, there are no clear guidelines for the protocol of information methods for detecting pathology on laparoscopic images, which should be performed in real time and in a short period of time. Therefore, methods that have proven effective in other scientific fields should be tried.

The development of vessel microaneurisms (MA) is regarded as the earliest manifestation of diabetic retinopathy (DR) [1], [2]. The small size of MA, along with the similar color of neighboring tissue, complicates the approach for DR

Leonid S. Godlevsky, Tatyana V. Tatarchuk, and Kseniya O. Prybolovets are with the Department of Biophysics, Informatics and Medical Devices of Odesa National Medical University (ONMedU), Odesa - 65082, Ukraine, (e-mail: godlevskyleonid@yahoo.com, gluon2008@meta.ua, lashelgo@gmail.com).

Natalya V. Kresyun is with the Department of Ophthalmology, ONMedU, Odesa - 65082, Ukraine, (e-mail: talochka.kr@yandex.ru).

Vasyl P. Martsenyuk, Mikolaj Karpinski, and Tomasz Gancarczyk are with the Department of Computer Science and Automatics, University of Bielsko-Biala, Bielsko-Biala 43-309, Poland, (e-mail: vmartsenyuk@ath.bielsko.pl, mkarpinski@ath.bielsko.pl, tgan@ath.bielsko.pl).

Konstantin S. Shakun and Larisa F. Kalinichenko are with the Department of Physics and Chemistry Department, NU "Odesa Maritime Academy", Odesa-65029, Ukraine (e-mail: gluon@meta.ua, l.kalinich.17@gmail.com).

diagnostics based on MA verification [2]. That is why the early diagnostics of DR is still actual for the ophthalmology [1], [3].

We assumed that in the course of retinal inflammation development, free radicals can cause depigmentation of retinal tissue [4], [5]. Hence, evaluation of the color in macula zone with the indirect comparison with the other zones of eye bottom, which are free from such pigment, might be helpful for the verification of early signs of DR precipitation.

An earlier informational system on the analysis of color characteristics of biological surfaces was developed. It was used for the early caries diagnostics [6], [7]. Also, it was explored with the purpose of the checking up the level of pigment in patients with diabetes mellitus. The color of the vessel trunk identified at the eye bottom was used as a color standard for the comparison with the color spectrum of the macular zone. Such a decision was justified by a more stable state of hemoglobin to the action of free radicals at retinal tissue and presumably minimal deterioration of hemoglobin color. That is why reliable extraction of vessel trunk was performed using a multiscale gradient method [1]. Hence, the present work aimed to evaluate the principal possibility of the diagnostics of early stage of DR on the basis of comparative color characteristics of the macular zone with such one of the vessel trunk. Also, we compared the effectiveness of early DR diagnostics with the expert diagnostics, which based on the verification of MA.

II. MATERIALS AND METHODS

17 apparently healthy volunteers (the mean age 33.2 ± 3.5 years old) and 52 insulin-dependent patients who had second type of diabetes (the mean age 30.6 ± 3.3 years old) were under observation.

All subjects provided written consent to research conduction. All investigations were performed in accordance with ethical demands of commission on ethics at Odesa National Medical University (ONMedU Animal Care and Ethics Committee, 2008/84).

When selecting a control group, the following criteria were met: intraocular pressure less than 21 mm Hg, preserved visual acuity, unchanged perimeter of vision and the absence of eye diseases and neurological disorders. For diabetics, the criteria were as follows: intraocular pressure less than 21 mm Hg, well-corrected visual acuity (more than 7/10), as well as

the absence of signs of proliferative retinopathy, established by fluoroangiography [1].

Digital images of eye bottom are characterized by low contrast of structures and heterogeneous illumination being most bright in the center of the image [3], [8]. With the aim of diminishing of mentioned aberrations, we used the contrast - limited adaptive histogram equalization (CLAHE) technology, which proved to be valid for the increasing contrast of vessels of eye bottom and permitted to increase the contrast by 1,7 - 3 times [3], [8]. The multiscale textural gradient for the extraction of vessels [1] was undertaken as a next step. It was critically important for the consequent evaluation of "blood color" with color of the macular zone.

A. Multiscale Texture Gradient Method

The multiscale texture gradient (MTG) method was developed for detecting image objects with blurred borders. It showed very satisfactory results both when implementing for automatic detection of microaneurysms and soft exudates in fundus images [1] and when fragmenting blurry frames of a video sequence [9].

The central idea of the method was the transition from the RGB image space to the space of texture gradients. The transition was carried out as follows – in each pixel of the image, the K color gradients were calculated, each of which was obtained along the direction of the vector, determined by the polar angle $\varphi_k = k\pi / K$, $k \in [0, K]$, relative to the horizontal.

The value of the gradient along the k -th direction was determined according to the expression:

$$\nabla_k = \frac{\sum_{i=1}^{n-1} C_i \cdot \nabla_{k,i}}{\sum_{i=1}^{n-1} C_i} \quad (1)$$

Here $\nabla_{k,i} = \sqrt{(r_{i+1} - r_i)^2 + (g_{i+1} - g_i)^2 + (b_{i+1} - b_i)^2}$ – is the local color gradient between two adjacent pixels of the k -th vector, r, g, b – is the corresponding color intensities of the RGB model, n – is the length of the vector, i.e. the number of pixels on which the gradient ∇_k is calculated.

In (1), following the general ideas of [10] and [11], the

analytical weight coefficient C_i was introduced. It served for increasing the relative role of the local gradient in the vicinity of the considered pixel [1]:

$$C_i = \cos\left(\frac{(i-n/2)}{n}\pi\right), \quad (2)$$

If the total gradient $\nabla = \sum_{k=1}^K \nabla_k$ along all K directions is larger than the threshold value $\nabla > (>>) \Delta_b$, then the flag "1" is assigned to the considered pixel (i.e., the belonging to the object boundary is set up).

It was necessary to increase (scale) the width where texture gradients were calculated just for the applicability of the method for low sharpness images [1]. Then, in the general case, it is more efficient to use MTG:

$$d = \sum_{m=1}^M \delta_m \nabla_m, \quad (3)$$

Here ∇_m – is a color gradient calculated according to the algorithm described above along vectors length of $m \cdot n$ pixels. δ_m – is a weight factor for the corresponding scale level. The values of the coefficients obey the rule $\delta_1 < \dots < \delta_m < \dots < \delta_M$, where M – is the maximum scale level of the method.

All characteristics which have been gained in RGB color scale were transferred into CIELAB scale in accordance with working algorithm [6], [7]. Later on, the CIE scale permitted to evaluate coordinates of L^* , a^* and b^* . The amount of white color rising was informative as an index of depigmentation [5]-[7].

Diagnostic effectiveness was assessed by determining sensitivity, specificity, and prognostic positive and negative indicators [5].

Research results were statistically processed, applying the ANOVA method and the Newman-Keuls test.

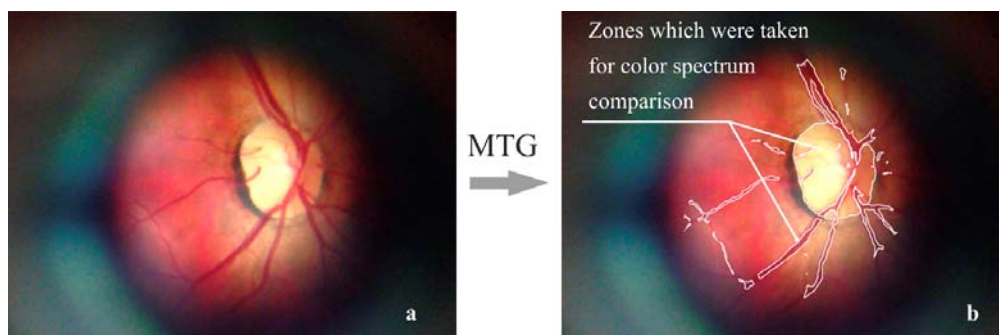


Fig. 1 MTG-based extraction of zones for comparative color analysis: before (a) and after (b) method application. The fundus scan (a) obtained by I-Phone 7 with a help of D-Eye retinal imaging system

III. RESULTS AND DISCUSSION

The results on the application of MTG method for the vessel visualization are presented at Fig. 1. The next parameters of textural gradient were used: $K = 6$, $n = 4$, $M = 2$, $\Delta_b = 34$. Zones for color analysis, which included vessel and macular ones, were identified (Fig. 1).

The lightness index (L^*) in the macular zone of patients with diabetes was greater when compared with the normal value (Fig. 2). Thus the average value of L^* in diabetic patients exceeded this value in the control group (practically healthy persons) by 2.71 times ($P < 0.05$). At the same time value of a^* index was reduced by 3.8 times when compared with the control one ($P < 0.05$). b^* index of CIELAB scale exceeded this value in the control group by 12.4 times ($P < 0.05$). The integrated index on color difference (ΔE) exceeded control value by 2.87 times ($P < 0.05$) (Fig. 2). Hence, gained data are in favor of the increased lightness in the macular zone in patients with diabetes, and such effect is developed on behalf of diminution of red and blue colors along with rising of green and yellow colors. The increasing of integral color difference in comparison with the control data is observed at the same time.

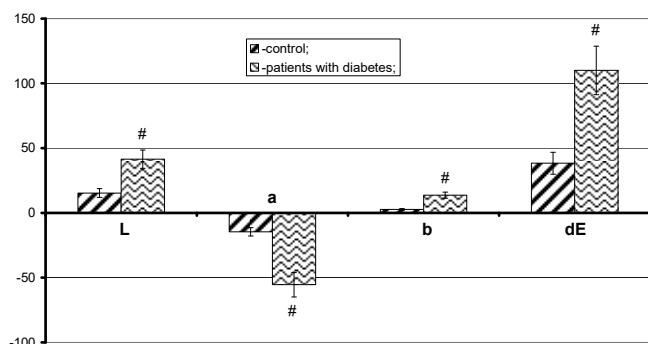


Fig. 2 CIELAB scale data in patients with diabetes ($M \pm m$). Ordinate- the difference between macular and arterial trunk (relative units); abscissa- indices of CIELAB scale. Notes: # - $P < 0.05$ in comparison with the data in control group (ANOVA+ Newman- Keuls test)

Investigation of eye bottom of patients with diabetes in one year from the moment of color differences investigations revealed the appearance of MA in 11 patients (Fig. 3). The coefficient of correlation " r " between dynamics of MA appearance and value of ΔE was $-0,56$ ($P < 0.05$). Correspondently, more pronounced differences with ΔE were followed by a shorter period of MA appearance.

The estimation of the effectiveness of the developed method of DR diagnostics revealed that sensitivity exceeded the effectiveness of expert diagnostics not-significantly ($P < 0.05$), while specificity was significantly higher, by 2.17 times ($P < 0.05$) (Table I). Negative prognostic index raised substantially when compared with this value determined with expert method, by 2.26 times ($P < 0.05$), while rising of the positive prognostic index was not significant ($P > 0.05$) (Table I). Hence, developed method significantly reduced the number of false-positive diagnoses, while the reduction of false negative diagnoses was less pronounced. Thus, gained data are

in favor for the informative significance of the color difference between macular zone and vessels (arterial trunk) as a diagnostic index for DR. Also gained data point on the diabetes-induced loosening of pigment in macular zone, which is in correspondence with other authors' data [12], [13]. Thus, our data revealed that the reduction of a^* index of CIELAB scale is in favor of the increasing of green channel contribution while the contribution of the red channel was reduced. At the same time, the increased contribution from the yellow channel with reciprocal decrease of contribution from the blue channel is supposed as a result of increase of the b^* index [8], [14]. Taking into consideration that the absorption model of the colored retina [3] is in favor of the greater significance of blue color as a melanin marker, the registered reduction of blue color contribution stressed the reduced role of melanin in retina color determination in patients with diabetes. Meanwhile, an established decrease of red channel contribution supports the decreased role of melanin in retina color determination. Mentioned changes are in good correlation with the ability of pigments to be washed out from their color by free radicals, an effect which manifested as spectral characteristic changes [5].

TABLE I
 RESULTS OF EXPERT DIAGNOSTICS OF DR AND DIAGNOSTICS USING THE DEVELOPED METHOD (%)

	Expert diagnostics	Diagnostics with developed method
Sensitivity (%) (n = 52)	39 (75.0)	46 (88.5)
Specificity (%) (n = 17)	6 (35.3)	13 (76.5)*
Positive prognostic index (%)	78.0	92.0
Negative prognostic index (%)	31.6	76.5*

Notes: * - $P < 0.05$ when compared with expert diagnostics ("z" criteria on comparison two proportions was used).

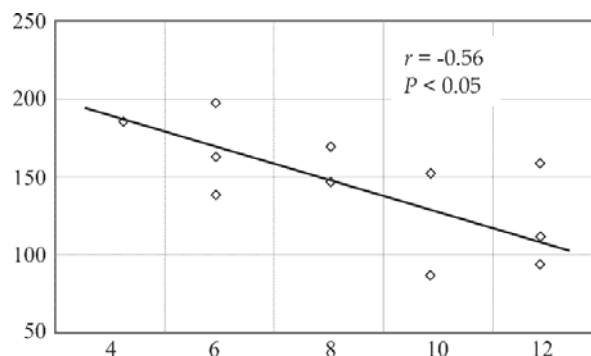


Fig. 3. Correlation between integral color difference (ΔE) and time of appearance of MA in patients with the second type of diabetes.

Notes: ordinate - ΔE (relative units), abscissa - the time from the moment of diagnostics of color differences (months). Marks (rhombus) - patients with newly appeared MA. The regression trend is presented as the declined line

It should be stressed that the appearance of MA, as first and robust signs of DR [1]-[3], might be the result of more deep development of pathological process with degeneration of pericytes due to free radicals cytotoxic action. Established color changes are observed earlier than MA appearance and deserve attention for further estimation as the first indicative

manifestation of DR.

IV. CONCLUSIONS

- 1) The effective diagnostics on the loosening of pigment in the macular zone is possible to perform based on comparison of color characteristics in the CIELAB scale of the macular zone and neighboring vessel trunks.
- 2) Patients suffered from DR display the raise of the lightness in the macular zone in green-yellow bandwidth along with the decreasing it in the red one.
- 3) Established deteriorations of the color of eye bottom structures predicted the appearance of MA as the most reliable markers for DR development (correlation coefficient $r = -0.56$).

REFERENCES

- [1] N. V. Kresyun, T. V. Tatarchuk, K. S. Shakun, and L. S. Godlevsky. "Multiscale textural gradient method of eye bottom images analysis in automatic diagnostics of diabetic retinopathy". *Ophthalmological J. (Ukrainian)*, 2014, pp. 9-13.
- [2] E. K. Chin, B. V. Ventura, and K. Y. See. "Nonmydriatic fundus photography for teleophthalmology diabetic retinopathy screening in rural and urban clinics". *Telemed. J. e-Health*. 2014, pp. 102-108.
- [3] A. F. M. Hani and H. A. Nugroho. "Retinal vasculature enhancement using independent component analysis". *J. Biomed. Sci. Engineer.* 2009, pp. 543-549.
- [4] Yu Y. Chen, S. B. Su "Neuroinflammatory responses in diabetic retinopathy". *J. of Neuroinflammation*. 2015, vol. 12, pp. 141-147.
- [5] L. S. Godlevsky, N. V. Kresyun, H. O. Son, V. V. Godovan, O. N. Nenova, M. P. Pervak, T. L. Godlevska, K. A. Bidnuk, and T. V. Prybolovets, "Retina Protection with Cerebellum Activation in Experimental Diabetes and Translational Perspectives" In: *Development of the Cerebellum, Clinical and Molecular Perspectives*. S.Fabbri, Ed. New York: Nova Science Publishers Inc., 2018, pp. 147-173.
- [6] L. S. Godlevsky, E. A. Bidnyuk, N. V. Kresyun, N. R. Bayazitov, A. V. Lyashenko, and V. V. Balykov. "Application of mobile photography with smartphone cameras for monitoring of orthodontic correction with dental BRACKETS". *China Journal of Modern Medicine*. 2014, pp. 10-14.
- [7] L. S. Godlevsky, E. A. Bidnyuk, N. R. Bayazitov, N. V. Kresyun, A. S. Kovalenko, A. V. Lyashenko, and V. V. Balykov. "Application of mobile photography with smartphone cameras for monitoring of early caries appearance in the course of orthodontic correction with dental brackets". *Applied Medical Informatics (Romania)*. 2013, pp. 21-26.
- [8] M. H. A. Fadzil, L. I. Izhar, P. A. Venkatachalam, and T. V. Karunakar. "Extraction and reconstruction of retinal vasculature". *J. Medical Engineer. Technol.* 2007, pp. 435-442.
- [9] L.S. Godlevsky, K.S. Shakun, V.P. Martsenyuk, T.V. Tatarchuk, T.V. Stoeva, T.L. Godlevska, I.K. Shakun. "Dynamic Changes of the Colour Intensity of Collected Urine as a Basis for a Distant Uroflowmetry," *Proc. 10th IEEE Internat. Conf. on Intelligent Data Acquisition and Advanced Computing Systems: Technology and Applications (IDAACS'2019)*, Sept. 2019, pp. 308-314.
- [10] P.A. Chochiya. "Pyramidal algorithm of images segmentation". *Informationnyie Protsessy [Russian]*. 2010, pp. 23-35.
- [11] R.C. Gonzales, R.E. Woods, *Digital image processing*, Prentice-Hall, Inc., 2002, pp. 567-643.
- [12] G. Scanolon, P. Connell, M. Ratzlaff, B. Foerg, D. Mc Cartney, A. Murphy, K. O'Connor, and J. Loughman. "Macular pigment optical density is low in type 2 diabetes, compared with type 1 diabetes and normal controls". *Retina*. 2015, pp. 1808-1816.
- [13] V. C. Lima, R. B. Rosen, M. Maia, T. S. Prata, S. Dorairaj, M. E. Farah, and J. Salum. "Macular pigment optical density measured by dual-wavelength autofluorescence imaging in diabetic and nondiabetic patients: a comparative study". *Invest. Ophthalmol. Vis. Sci.* 2010, pp. 5840-5845.
- [14] T. T. J. M. Berendschot, P. J. DeLint, and D. Norren. "Fundus reflectance-historical and present ideas". *Progress in Retinal and Eye Research*. 2003, pp. 171-200.