

**MINISTRY OF HEALTH PROTECTION OF UKRAINE  
ODESSA NATIONAL MEDICAL UNIVERSITY**

Faculty Medical 2  
*(faculty name)*

Department of Normal and Pathological Clinical Anatomy  
*(name of department)*

**CONFIRMED** by  
Acting vice-rector for scientific and pedagogical work  
**Svitlana KOTYUZHYNKA**

" " 20

**METHODOLOGICAL DEVELOPMENT  
TO LECTURES ON PATHOMORPHOLOGY**

Faculty, course Medical, III

Educational discipline Pathomorphology  
*(name of academic discipline)*

**Approved:**

Meeting of the department of normal and pathological clinical anatomy  
Odessa National Medical University

Minute No. 1 of "30" серпня 2022

The Head of the department  **Nataliia NESKOROMNA**  
*(signature)* *(First Name Last Name)*

**Developers:**

Sytnikova Varvara Oleksandrivna, MD in medicine, professor

Lytvynenko Marianna Valeriivna, PhD in medicine , associate professor

Buryachkivskyi Eduard Stanislavovych, PhD in medicine, associate professor

Narbutova Tamara Evgenivna, PhD in medicine, assistant

Vasyliiev Vladyslav Vadymovych, assistant

Syvyi Sylvester Mykhailovych, assistant

## Lecture No. 1

**Subject:** Predmet and problems of pathomorphology. Pathomorphological research methods. The main stages of the development of pathomorphology. Morphology of reversible and irreversible damage to cells and tissues. Intracellular and extracellular accumulation of proteins, carbohydrates and lipids.

**Actuality of theme:** You need to know this material to understand the principles of pathomorphology, to know and learn the types of dystrophies, to calculate reversible and irreversible types of damage to cells and tissues, to know the essence and location of intracellular and extracellular accumulated proteins, fats and carbohydrates.

**Goal:** Familiarize yourself with the subject "Pathomorphology", learn the concepts, types, classifications of dystrophies, parenchymal lipidoses, parenchymal carbohydrate dystrophies, mesenchymal dystrophies, Mesenchymal dysproteinoses, Stromal-vascular lipidoses, Mesenchymal carbohydrate dystrophies, Mixed dystrophies, Violations of the metabolism of proteinogenic (tyrosinogenic) pigments, Violations of the metabolism of lipidogenic pigments, Violations of the metabolism of nucleoproteins, mineral dystrophies, causes of formation and formation of stones.

**Basic concepts:** Pathomorphology, microscopy, biopsy, autopsy, electron microscopy; van Gieson staining, Sudan 3, hematoxylin-eosin, toluidine blue. Dystrophies: intracellular, stromal-vascular, mixed, hereditary, acquired, protein, carbohydrate, fat, pigment, mineral; goose liver, tiger heart, hyaline and its types, hyalinosis and its types, amyloid, amyloidosis and its types, obesity and its types, glazed spleen, sebaceous spleen, sago spleen, simple fatty heart, large white kidney, sebaceous kidney, lipomatosis, melanosis, calcification and its types, stone formation (stone disease and its types: nephrolithiasis, urolithiasis, sialolithiasis, gallstone disease ...) hemoglobinogenic pigments, jaundice and its types, hemosiderosis and its types;

### **Plan and organizational structure of the lecture:**

Greetings, verification of those present, announcement of the topic, purpose of the lesson, motivation of higher education seekers to study the topic.

### **Content of lecture material (lecture text)**

Pathomorphology is the morphology of the diseased organism. The word "pathological" comes from the Greek word "pathos", which means "suffering". From the same word comes "pathology" - the name of that section of medical and biological knowledge, which includes the entire scope of issues related to a sick organism. This includes the clinic of the disease, that is, its symptoms and manifestations, violations of physiological functions, structural changes of organs and tissues, as well as treatment and preliminary measures.

A distinctive feature of pathological anatomy is the clinical-anatomic direction, the study of the structural features of the disease is closely related to its clinical manifestations.

The study of the structural features of the disease is carried out at different levels: 1) organismic, 2) systemic, 3) organ, 4) tissue, 5) cellular, 6) subcellular, 7) molecular.

Pathomorphology establishes the morphogenesis of the disease and determines those phases when, with the help of medical measures, it is possible to stop the course of the disease and achieve full or partial recovery. Pathomorphology investigates various deviations from the usual course of the disease, which arise during its development, certain complications, and also studies in detail the outcome of the disease and its possible consequences for the human body.

A change in the clinical and morphological picture of the disease under the influence of drugs or changes in people's lives is called pathomorphosis.

The term "pathomorphosis" has a broad and narrow interpretation. In a broad interpretation, pathomorphosis reflects changes in the structure of morbidity and mortality, that is, changes in the general panorama of diseases. They are associated with mass preventive and curative measures, changes in the human environment and living conditions of the population of developed countries, industrialization of production, growth of occupational hazards, etc. Thus, pathomorphosis as a concept that reflects changes in the structure of morbidity and mortality is determined primarily by the development of human society and the conquest of the civilized world.

In the narrow sense, pathomorphosis is persistent and significant clinical and morphological changes of a certain disease, nosology. It is in this sense that the concept of pathomorphosis was introduced into medicine and is most often used.

Pathomorphosis, as a change in a certain disease, is usually divided into natural, or spontaneous, associated with changes in living conditions and human constitution, and induced, or therapeutic, arising as a result of the use of medicinal products. Often, it is extremely difficult to draw a line between medicinal and induced pathomorphosis.

Pathomorphology obtains material about structural disorders in diseases by means of autopsy, study of surgical material, biopsy and experiment.

## **DYSTROPHY**

Dystrophy is a complex pathological process, the basis of which is a

violation of cellular metabolism, which leads to structural disorders.

Morphogenetic mechanisms of dystrophy: infiltration – excessive penetration of substances from blood and lymph into cells or intercellular substance; decomposition - breakdown of ultrastructures of cells and intercellular substance; transformation – formation of products of one type of exchange from general initial products; distorted synthesis - synthesis in cells or tissues of substances that do not occur normally.

1. Classification of dystrophies

2. Depending on the predominance of morphological changes in specialized cells or stroma and vessels: a) parenchymatous, b) stromal-vascular, c) mixed.

3. Depending on the type of disturbed metabolism: a) protein (dysproteinosis), b) fat (lipidosis), c) carbohydrate, d) mineral.

4. Depending on the prevalence of the process: a) local, b) general.

5. Depending on the origin: a) acquired, b) hereditary.

6. Parenchymatous dystrophies

7. In parenchymal dystrophies, there are disturbances in the exchange of highly specialized cells of parenchymal organs - heart, kidneys, liver.

8. The development of parenchymal dystrophies is based on acquired or hereditary enzyme diseases.

9. A large group of accumulation diseases, or thesaurisms, is associated with hereditary enzyme diseases. Parenchymatous dysproteinoses

10. Hyaline-droplet dystrophy is characterized by the fusion of small protein grains into large hyaline-like masses that fill the cell body. This dystrophy most often occurs in the kidneys, less often in the liver and myocardium. Macroscopic changes in organs are not determined. The development of hyaline-drop dystrophy is associated with infectious and non-infectious diseases.

11. The outcome is unfavorable. The process is irreversible and causes cell necrosis.

12. The functional value is very high - there is a sharp decrease in the function of the organ.

13. Hydropic (vacuolar) dystrophy is characterized by the appearance of vacuoles in the cell, filled with cytoplasmic fluid. The nucleus shifts to the periphery, sometimes becomes vacuolated or shriveled.

It occurs in epithelial cells (skin, liver, kidneys), heart muscle, and nerve cells.

The appearance of organs and tissues with hydropic dystrophy practically does not change. Microscopically, an increase in the volume of cells is determined, the cytoplasm is filled with vacuoles.

Causes: infectious and infectious-toxic effects, hypoproteinemia and violation of the water-electrolyte balance.

The outcome is unfavorable, as it often turns into ballooning dystrophy, which ends in colliquative cell necrosis.

Corneal dystrophy (pathological keratinization) is characterized by the excessive formation of horny substance in the keratinized epithelium or the formation of horny substance where it normally does not occur (leukoplakia). The process can be local or general.

Causes: impaired skin development, chronic inflammation, viral infections, vitamin deficiency.

The outcome is determined by the degree of dystrophy, prevalence and duration of the process.

An example of a hereditary dystrophy associated with a hereditary disorder of amino acid metabolism is cystinosis, tyrosinosis, phenylketonuria.

### **Parenchymatous lipidosis.**

Violation of the exchange of cytoplasmic lipids is observed in the cells of the liver, myocardium, kidneys, in the endothelium of vessels and reticular cells.

Mechanisms of fatty dystrophy development: fatty decomposition, fatty infiltration, fatty transformation.

During fat decomposition, lipoprotein complexes are destroyed, the freed fat accumulates in the cytoplasm of cells in the form of dust-like particles (dust-like obesity of heart muscle fibers). With fatty infiltration, fat most often enters the cells in excessive quantities and accumulates in the form of small, and later larger drops (liver, kidneys). During fatty transformation, fat is formed from carbohydrates and proteins of the cell, and accumulates in the cytoplasm in the form of droplets (liver).

The appearance of the organs is a slight increase in size, the color is yellow or yellow-brown, and the consistency is loose.

The causes of fatty dystrophy are various: oxygen starvation (diseases of the heart, lungs, anemia, alcoholism), intoxication (acute and chronic infectious diseases, poisoning with chloroform, phosphorus, arsenic, carbon tetrachloride), vitamin deficiency, protein starvation.

The functional value of fatty dystrophy is very great. The activity of

organs decreases sharply, and in a number of cases it even falls out.

The outcome of fatty dystrophy depends on its degree. It can be reversible or end in necrosis.

Hereditary systemic lipidoses include Gaucher's disease (cerebrosidal lipidosis), Niemann-Pick disease (sphingomyelin lipidosis), and others.

### **Parenchymatous carbohydrate dystrophies.**

They are observed in disorders of neuro-endocrine regulation of carbohydrate metabolism (diabetes mellitus, glycogenosis).

In diabetes, the cells of the liver and skeletal muscles lose glycogen, and the epithelium of the renal tubules accumulates glycogen by resorption and infiltration. With glycogenosis, glycogen deposition is observed in the cells of the liver, heart, kidneys, and skeletal muscles.

Hereditary glycogenosis includes Gierke's, Pompe's, McArdle's, Hers's, and other diseases.

### **Stromal-vascular (mesenchymal) dystrophies**

Mesenchymal dystrophies develop as a result of metabolic disorders in connective tissue, which are verified in the stroma of organs and vessel walls. Depending on the type of disturbed metabolism, they are divided into protein, fat and carbohydrate.

Mesenchymal dysproteinoses include mucoid swelling, fibrinoid swelling, hyalinosis, and amyloidosis.

Very often, mucoid, fibrinoid swelling and hyalinosis are successive stages of connective tissue disorganization, the basis of which is the accumulation of blood plasma products in the main substance as a result of increased vascular and tissue permeability (plasmorrhagia), destruction of connective tissue elements and the formation of protein (protein-polysaccharide) complexes. Amyloidosis differs from these processes in that the protein-polysaccharide complexes that are formed include fibrillar protein, which is not found normally, and which is synthesized by cells - amyloidoblasts.

### **Mesenchymal dysproteinoses**

Mucoid swelling. The basis of myxomatous edema is the accumulation and redistribution of hydrophilic glycosaminoglycans in the interstitial tissue, which is connected with its further penetration by proteins and glycoproteins of the blood plasma. There is swelling of the main substance and collagen fibers of the connective tissue, which determines the essence of the process. Mucoid swelling is quite well studied in collagen diseases. There are no macroscopic changes in the organs.

During ultrastructural examination, in the areas of mucoid swelling of the connective tissue of the heart, in rheumatism, an expansion of the space between collagen fibers is constantly found. In the main substance, a granular precipitate is found, which resembles a blood plasma precipitate. In the fibers, collagen fibrils are unraveled. The prevalence of unraveling of collagen microfibrils is correlated with the severity of metachromasia of mucoid swelling centers.

The outcome may be complete recovery or transition to fibrinoid swelling.

Fibrinoid swelling is a manifestation of deep disorganization of connective tissue. The basis of this process is damage to collagen fibers and their acquisition of fibrin properties. This is how the concept of fibrinoid appeared - a substance that occurs during fibrinoid swelling of connective tissue and differs in tinctorial properties.

Histochemically, fibrinoid is different in different diseases.

Thus, in rheumatic diseases, the formation of fibrinoid is mainly associated with immune-complex damage to the connective tissue with subsequent adsorption of fibrin. This is the fibrinoid of immune complexes, "fibrinoid destruction". Fibrinoid of immune complexes also occurs with allergic inflammation - the Artus phenomenon, which is a manifestation of an immediate hypersensitivity reaction.

In vascular diseases of angioneurotic (hypertensive disease) and plasmorrhagic (atherosclerosis) genesis, as well as in coagulopathy (Sanarelli-Schwartzman phenomenon), the leading role in the formation of fibrinoid belongs to the insudation of plasma proteins, in particular fibrinogen. Thanks to this, in renal hypertension and atherosclerosis, fibrinoid is identical to fibrin.

As a result of fibrinoid changes, necrosis develops with replacement of the center of destruction by connective tissue (sclerosis) or hyalinosis.

Hyalinosis is a type of mesenchymal protein dystrophy, which is characterized by the formation of homogeneous translucent dense masses in the tissue that resemble hyaline cartilage. Hyalinosis unites different processes by origin, mechanism of development and biological essence. The leading factor in its development is the destruction of fibrous structures and an increase in vascular and tissue permeability (plasmorrhagia), in connection with dyscirculatory, metabolic and immunopathological processes. Plasmorrhagia is associated with tissue impregnation with plasma proteins and their adsorption on changed fibrous structures with subsequent precipitation and formation of protein - hyaline. Hyalinosis can be general or local in nature and can be manifested both in physiological and pathological conditions. A distinction is made between



vascular hyalinosis and connective tissue hyalinosis, although the pathogenetic mechanisms of these types of hyalinosis are common.

**Hyalinosis of vessels.** Small arteries or arterioles are mainly exposed to hyalinosis. It is preceded by damage to the endothelium, argyrophilic membranes and smooth muscle fibers of the wall and its impregnation with blood plasma, the components of which, especially proteins, are exposed to the action of enzymes, coagulate and compact, turning into a dense hyaline-like substance, which is usually found in diseases of the cardiovascular system, connective tissues, autoimmune diseases and diabetes. Falling into the subendothelial space, hyaline masses push outward and destroy the elastic plate, which causes thinning of the middle membrane, as a result of which arterioles turn into thickened dense tubes with a sharply narrowed or completely closed lumen.

The expression of hyalinosis in these diseases is directly dependent on their duration. Hyalinosis of small arteries and arterioles causes atrophy, deformation and shrinkage of the organ (atherosclerotic nephrocirrhosis).

**Types of vascular hyaline.** Destruction of the elements of the vascular wall and plasmatic impregnation can be expressed differently depending on the features of the pathogenesis of hyalinosis, which are determined by dyscirculatory, metabolic and immunopathological disorders. They distinguish: 1) simple hyaline (hypertensive disease, atherosclerosis), 2) lipohyaline (in diabetes), 3) complex hyaline includes immune complexes, fibrin, destroyed structures (rheumatic diseases).

Hyalinosis of the connective tissue itself develops as a result of various processes - fibrinoid swelling, necrosis, sclerosis.

The output of fibrinoid swelling, which causes the destruction of collagen, tissue impregnation with plasma proteins and glycoproteins, connective tissue bundles swell, lose their fibrillation and merge into a homogeneous dense cartilage-like mass. Fibrinoid becomes the basis of hyaline construction in such cases. Hyalinosis can complete fibrinoid changes at the bottom of a chronic stomach ulcer, in the tissue of the appendix in appendicitis, in the focus of chronic inflammation.

With hyalinosis, the connective tissue itself becomes dense, whitish, translucent (change in heart valves in rheumatism).

In most cases, hyalinosis is an irreversible process, but resorption of hyaline masses in scars (keloids) is possible. In the hyalinized tissue, calcium salts often fall out, which is associated with further changes in both the tissue itself and the soluble parts of the plasma. Sometimes the hyalinized tissue becomes slimy or undergoes lipoidosis.

Amyloidosis is an ambiguous concept. This is a type of dysproteinosis and a complication of many diseases of an infectious, inflammatory or

tumor nature. This is an independent disease of a genetic (hereditary amyloidosis) or unknown yet "primary" nature, a disease of old age, a tumor-like disease and a disease of the tumor itself (APUD-amyloid). This does not exhaust the diversity of amyloidosis, which can be considered equally a problem of modern clinic, a problem of molecular biology.

Amyloid is a glycoprotein in which the fibrillar protein (F-component) is closely related to plasma glycoproteins (P-component).

The basis of amyloid glycosaminoglycans is chondroitin sulfate, heparin sulfate, or both of these polysaccharides. Certain connections between polysaccharides and amyloid proteins have been established.

The chemical nature and physical properties of amyloid testify to the strength of the bonds of its protein-polysaccharide components between themselves and the tissue elements where they fall. The strength of these bonds can explain the resistance of amyloid to the action of many enzymes. Physico-chemical features of amyloid also determine its tinctorial properties, which are revealed when using various methods. Congo red, methyl violet, and especially thioflavin T staining has diagnostic value.

Cellular transformations of the reticuloendothelial system (RES) are the essence of the pre-amyloid stage, which is characterized by plasmatization of the RES organs, primarily the spleen, bone marrow, lymph nodes, and liver.

Synthesis of fibrillar protein amyloid by cells of mesenchymal origin can be considered proven.

The connection of amyloid fibrils with plasma proteins and glycoproteins and tissue glycosaminoglycans is the final stage of amyloid substance formation. The formation of amyloid occurs outside the cells, in close connection with the fibers of the connective tissue - reticular or collagen. These data served as the basis for distinguishing two types of amyloid depending on its relationship to the fibrillar structures of connective tissue - perireticular and pericollagen.

For perireticular amyloid (AA-amyloidosis), which falls along the membranes of vessels and glands, as well as along the reticular stroma of parenchymal organs, the predominant lesion of the spleen, liver, kidneys, adrenal glands, intestines, and the intima of small and medium-sized vessels is typical.

Pericollagenous amyloid (AL-amyloidosis), which is formed along the course of collagen fibers, is characterized by predominant damage to the adventitia of large and medium-sized vessels, the stroma of the myocardium, striated and smooth muscles, nerves, and skin (mesenchymal amyloidosis).

Typical organ localization of amyloid deposits. Most often, the spleen, kidneys, liver, adrenal glands, intestines are affected, which is characteristic of parenchymal amyloidosis. The myocardium, skeletal muscles, lungs, and skin are less frequently affected. Thyroid and pancreatic glands, lymph nodes, bones, vascular plexuses and brain substance are even rarer. There are clinical types of amyloidosis: a) cardiopathic, b) nephropathic, c) neuropathic, d) hepatopathic, e) other.

Amyloidosis can be generalized (general, widespread) or local (local). In some cases, amyloid deposits grow like a tumor ("amyloid tumor"), amyloid is also formed in tumors of endocrine organs - apudomas, such amyloid is called - APUD-amyloid.

The appearance of organs in amyloidosis depends on the degree of the process. If the amyloid deposits are small, the appearance of the organ changes little and amyloidosis is detected only by microscopic examination. With pronounced amyloidosis, the organ increases in volume, becomes very dense, brittle, and on section has a peculiar waxy or greasy appearance.

### **Stromal-vascular lipidosis**

Stromal-vascular lipidoses include disorders of fat metabolism of adipose tissue and fat depots, and disorders of fat metabolism (cholesterol and its esters) in the walls of large arteries in atherosclerosis.

An increase in fat in adipose tissue is called obesity. Depending on the mechanism of development, the following types of obesity are distinguished: alimentary, cerebral (in case of trauma, brain tumor), endocrine (in case of Frelich and Itsenko-Cushing syndrome, adipose-genital dystrophy, hypothyroidism, etc.), hereditary.

According to external manifestations, there is a symmetric type of obesity (even distribution of fat), upper type (face, back of head, neck, upper shoulder girdle), middle type (on the stomach in the form of an apron) and lower type (thighs and lower legs).

Depending on the percentage of excess body weight, several degrees of obesity are distinguished: I degree - 20-29%, II degree - 30-49%, III - 50-59%, IV - more than 100%.

Depending on the number of adipocytes and their size, there can be a hypertrophic variant of general obesity (the number of adipocytes is unchanged, adipocytes are enlarged and contain several times more triglycerides, the course is malignant) and a hyperplastic variant of obesity (the number of adipocytes is increased, the function of adipocytes is not disturbed, the course is benign).

### **Mesenchymal carbohydrate dystrophies.**

Mesenchymal carbohydrate dystrophies can be associated with a violation of the balance of glycoproteins and glycosaminoglycans. Mesenchymal dystrophy associated with a violation of glycoprotein metabolism is called mesenchymal mucous dystrophy. Its essence is that chromotropic substances are released from bonds with proteins and accumulate mainly in the intermediate substance. In contrast to mucoid swelling, collagen fibers are replaced by a mucous mass. The connective tissue itself, the stroma of organs, adipose tissue, and cartilage become swollen, translucent, mucous-like (tissue slippage), and their cells have a star-like appearance.

The cause of tissue sliminess most often lies in the dysfunction of the endocrine glands, exhaustion (for example, mucous edema, or myxedema, in case of thyroid gland insufficiency; sliminess of connective tissue formations in cachexia of any genesis).

The process can be reversed, but its progression leads to tissue colicivation and necrosis with the formation of mucus-filled cavities.

The functional significance of tissue mucinization is determined by the severity of the process, its duration, and the nature of the tissue that has undergone dystrophy.

Hereditary disorders of glycosaminoglycan (mucopolysaccharide) metabolism are represented by a large group of accumulation diseases - mucopolysaccharidoses. Among them, the main clinical significance is gargoylism, or Pfoundler-Gurler disease, which is characterized by disproportionate growth, deformation of the skull ("massive skull"), other bones of the skeleton, the presence of heart defects, inguinal and umbilical hernias, opacification of the cornea, hepato- and splenomegaly. It is believed that the basis of mucopolysaccharidoses is the deficiency of a specific factor that determines the exchange of glycosaminoglycans.

Mixed dystrophies. Mixed dystrophies are characterized by metabolic disorders in the parenchyma, stroma, walls of blood vessels, organs and tissues. Mixed dystrophies occur in disorders of the metabolism of complex proteins - chromoproteins, nucleoproteins, lipoproteins, minerals.

Violation of chromoprotein metabolism. Endogenous pigments - chromoproteins - are divided into hemoglobinogenic, proteinogenic or tyrosinogenic and lipidogenic.

Hemoglobinogenic pigments: ferritin, hemosiderin, bile pigments, hematoidin, hematin, porphyrin.

Ferritin is an iron protein containing up to 23% iron. Depending on the origin, anabolic and catabolic ferritin are distinguished. Anabolic ferritin is formed from iron absorbed in the intestine, catabolic - from iron in hemolyzed erythrocytes. Normally, ferrin is found in the liver, spleen,

bone marrow, and lymph nodes, taking part in the synthesis of hemoglobin, hemosiderin, and cytochromes. In conditions of pathology, the amount of ferritin can increase. The irreversibility of shock accompanied by vascular collapse is explained by ferritinemia, since the active form - SH-ferritin, which has vasoparalytic and hypotensive properties, acts as an adrenaline antagonist.

Hemosiderin consists of a protein - globin and a prosthetic pigment part - heme, it is formed intracellularly in the form of brown grains. It contains iron and is determined by the Perls reaction (under the action of ferric blue potassium and hydrochloric acid, a blue color is formed - "Berlin blue"), turns black from ammonium sulphide. In pathological conditions, excessive accumulation of hemosiderin is observed - hemosiderosis. General hemosiderosis develops with intravascular destruction of erythrocytes and occurs in diseases of the hematopoietic system, intoxication with hemolytic poisons, some infectious diseases, transfusions of other blood groups, etc. The spleen, liver, bone marrow and lymph nodes become rusty brown.

A disease close to general hemosiderosis is hemochromatosis, which can be primary (impaired absorption of iron in the small intestine) and secondary. The disease is associated with an overload of the body with iron. In the form of ferritin and hemosiderin, it is deposited mainly in parenchymal elements of various organs, as a result of which they acquire a brown color. The result is sclerosis and atrophy of internal organs.

Data on the prevalence of hemochromatosis force one to treat with caution the fortification of food products with iron, which is widely practiced, the consequences of which, in relation to risk groups for the development of microelement overload, are practically not studied.

The classification of microelement diseases associated with iron metabolism disorders is reflected in the Online Mendelian Inheritance in Man (OMIM) register.

Bile pigments - bilirubin, biliverdin, urobilin.

Bilirubin is formed in the reticular cells of the spleen, liver and bone marrow. From these cells, bilirubin enters hepatocytes, where bile is synthesized.

An increase in the content of bile pigments in the blood and staining of tissues in yellow color (jaundice) is observed in various pathological conditions.

Suprahepatic (hemolytic) jaundice occurs with hemolysis of erythrocytes. It occurs with blood diseases (anemia, leukemia), some infectious diseases (malaria, sepsis, typhoid) and intoxications.

Hepatic (parenchymal) jaundice occurs with infections and intoxications (viral hepatitis, sepsis, acute toxic dystrophy of the liver, phosphorus, arsenic, mushroom poisoning). Liver cells lose the ability to synthesize bilirubin and secrete it into the bile ducts.

Subhepatic (mechanical) jaundice develops when the outflow of bile from the liver is obstructed. Occurs with gallstone disease, biliary tract cancer, etc. Bile stagnation leads to stretching of the bile ducts and rupture of bile capillaries. Bile enters the blood, causes jaundice and general intoxication of the body.

Hematoidin is a bright orange crystalline pigment that does not contain iron and is formed outside the cells in the centers of hemorrhages and infarcts under anaerobic conditions.

Hematin is an oxidized form of heme and is formed during hemolysis of oxyhemoglobin. They have the appearance of dark brown or black diamond-shaped crystals or grains, give birefringence in polarized light (anisotropic), contain iron in a bound state, dissolve in alkalis, sparingly soluble in acids, discolored by hydrogen peroxide.

Hematin found in tissues include: malarial pigment (hemomelanin), hydrochloric acid hematin (hemin) and formalin pigment. Histochemical properties of these pigments are identical.

Hemomelanin is a malarial pigment. It is formed in the body of a malarial plasmodium that parasitizes erythrocytes. It has the appearance of black-brown grains. When erythrocytes are destroyed, it enters the blood and undergoes phagocytosis by cells of the reticuloendothelial system. The spleen, liver, lymph nodes, bone marrow, and brain acquire a gray-aspid color.

Hydrochloric acid hematin (hemin) is formed in erosions and ulcers of the stomach under the action of enzymes of gastric juice and hydrochloric acid on hemoglobin. The site of the defect of the gastric mucosa acquires a brown-black color. Hydrochloric hematin crystals in polarized light reveal the properties of anisotropy and dichroism.

Formalin pigment in the form of dark brown needles or granules is found in tissues when they are fixed in acidic formalin (this pigment is not formed if formalin has a pH greater than 6.0). It is considered a hematin derivative.

Porphyrins are precursors of the prosthetic part of hemoglobin, having the same tetrapyrrole ring as heme, but without iron. Porphyrins are chemically similar to bilirubin: they dissolve in chloroform, ether, and pyridine. The method of detecting porphyrins is based on the ability of solutions of these pigments to give red or orange fluorescence in ultraviolet light (fluorescent pigments).

Normally, a small amount of porphyrins is found in blood, urine, and tissues. They have the property of increasing the sensitivity of the body, primarily the skin, to light and therefore play the role of melanin antagonist.

With disorders of porphyrin metabolism, porphyrias occur, which are characterized by an increase in the content of pigments in the blood (porphyrinemia) and urine (porphyrinuria), a sharp increase in sensitivity to ultraviolet rays (photophobia, erythema, dermatitis). Acquired and congenital porphyria are distinguished.

Acquired porphyria is observed with intoxication (lead, sulfazole, barbiturates), vitamin deficiency (pellagra), pernicious anemia, and some liver diseases. There is a violation of the function of the nervous system, increased sensitivity to light, jaundice often develops, skin pigmentation, a large amount of porphyrins is found in the urine.

Congenital porphyria is a rare hereditary disease. When porphyrin synthesis is disrupted in erythroblasts, the erythropoietic form develops, and when porphyrin synthesis is disrupted in liver cells, the hepatic form of porphyria develops.

Violation of the metabolism of proteinogenic (tyrosinogenic) pigments

Melanin is a black-brown pigment contained in the cells of the epidermis, hair, iris and retina of the eyes. Its composition includes carbon, nitrogen, and sulfur. In the melanoblasts of the basal layer of the epidermis, dioxyphenylalanine is formed from tyrosine under the influence of tyrosinase in the presence of vitamin C, which in turn is transformed into melanin under the influence of tyrosinase. The pigment can be captured by macrophages - melanophages and transported deep into the tissues. Regulation of melanin exchange is carried out by endocrine glands: adrenal glands, gonads, pituitary gland, thyroid gland. There are racial and individual differences in melanin content. A physiological increase in melanin in the skin is observed under the action of ultraviolet rays. Violation of melanin metabolism can be manifested in an increase (hyperpigmentation) and decrease (hypopigmentation) of its content. And that

Hyperpigmentation develops with cachexia, vitamin diseases (pellagra, scurvy), Addison's disease (a sharp decrease in adrenal function with tuberculosis, amyloidosis). Local hyperpigmentation: pigment spots, colon melanosis, chloasma during pregnancy, some tumors (melanoma). General hypopigmentation - albinism (congenital disease). Local hypopigmentation - leukoderma, vitiligo.

Adrenochrome, a product of adrenaline oxidation, is found in the form of granules in the cells of the medulla of the adrenal glands.

The pigment of enterochromaffin cell granules scattered in various parts of the gastrointestinal tract is a derivative of tryptophan. In tumors from these cells, called carcinoids, there are usually many granules containing pigment.

### **Violation of the metabolism of lipidogenic pigments**

Lipofuscin is a glycoprotein in which fats predominate, and phospholipids are among them. Lipofuscin is a normal component of the cell. In pathological conditions, the amount of lipofuscin increases sharply (lipofuscinosis). It can be primary (congenital) and secondary, it is observed most often in the elderly, as well as in debilitating diseases that cause cachexia (brown atrophy of the myocardium, liver), with increased functional load (lipofuscinosis of the myocardium in heart disease), with phagocytosis (lipofuscinosis of the macrophage) .

Lipochromes are represented by lipids in which carotenoids are dissolved, which are the source of the formation of vitamin A. Lipochromes give a yellow color to adipose tissue, adrenal cortex, and blood serum. In conditions of pathology, there is an excessive accumulation of lipochromes (diabetes). With cachexia, lipochromes condense in adipose tissue, which becomes ocher-yellow.

Ceroid is a lipopigment of mesenchymal cells, mainly macrophages. Ceroid formation is most often observed with tissue necrosis, especially if lipid oxidation is exacerbated by hemorrhage.

### **Violation of nucleoprotein metabolism**

Nucleoproteins are formed from protein and nucleic acids (DNA and RNA). The final product of nucleic acid metabolism is uric acid and its salts. Therefore, the presence of uric acid and its salts in tissues, which is observed in uric acid infarction and gout, indicates a violation of nucleoprotein metabolism.

Uric acid infarction occurs in newborns who have lived for at least two days, and is manifested by the precipitation of amorphous masses of uric acid sodium and ammonium in the tubules and collecting tubules of the kidneys. These cells on the section of the kidney have a triangular shape, reminiscent of a heart attack.

Gout is a disease that is characterized by periodic drops of sodium uric acid in the synovium and cartilage of small joints, ankle and knee joints, in tendons and joint bags, in the cartilage of the auricles. At the place of deposition of salts, necrosis develops, surrounded by an inflammatory reaction with the accumulation of giant cells of the type of foreign bodies - a gouty lump is formed, which may later become covered with ulcers. Often, gout is a congenital metabolic disorder (primary gout), sometimes it is a complication of other diseases (secondary gout), such as



nephrocirrhosis, blood diseases, etc.

Urinary stone disease, like gout, can be primarily associated with purine metabolism disorders and be a manifestation of uric acid diathesis. In the kidneys, the accumulation of uric acid and uric acid sodium salts in the tubules with obturation of their lumen, the development of secondary inflammatory and atrophic changes is noted.

### **Violations of mineral metabolism (mineral dystrophies)**

More than 20 elements are involved in mineral exchange. Disturbances in the metabolism of calcium, potassium, copper and iron are of the greatest practical importance.

Calcium is associated with the processes of permeability of cell membranes, excitability of the neuromuscular apparatus, blood coagulation, regulation of the acid-base state, formation of the skeleton, etc. Calcium exchange is carried out by the neurohumoral pathway. Disorders of calcium metabolism in body tissues are called calcification (calcific dystrophy). Its morphological manifestation is the precipitation of calcium salts from the dissolved state and their accumulation in cells or intercellular substance. By prevalence, the process can be general or local.

Calcific dystrophy can be cellular, extracellular and mixed. The process can be systemic (widespread) and local. There are three forms of calcification: 1) metastatic, 2) dystrophic, 3) metabolic.

Metastatic calcification (calcareous metastases) is a general process of calcium release from the depot and delayed removal from the body, which causes calcium to precipitate in tissues and organs with an alkaline environment (artery wall, myocardium, lungs, gastric mucosa, kidney tubules).

Dystrophic calcification (petrification) - has a local character, the precipitation of lime is usually found in dead tissues and tissues with deep dystrophic changes or necrosis (caseous foci in tuberculosis, gums in syphilis, heart attacks, parasites, dead fetus, scars, cartilage).

Metabolic calcification (calcific gout) is a local or systemic disease in which lime accumulates in the skin, tendons, muscles, nerves, and vessel walls. The reason is not established.

Violation of calcium metabolism can be accompanied by a decrease in the amount of calcium in the depot (bone system), occurs in rickets, osteomalacia, parathyroid osteodystrophy.

Rickets is a chronic disease characterized by a change in phosphorus-calcium metabolism with a violation of bone mineralization and the process of bone formation with the development of bone deformations.

Copper is a mandatory component of the cytoplasm, where it participates in enzymatic reactions.

Acquired copper deficiency is rare, mainly in children and adults who are on parenteral nutrition for a long time. Such patients develop anemia and leukopenia.

Congenital disorder of copper metabolism develops in Wilson-Konovalov disease (hepatocerebral dystrophy). An autosomal recessive disease characterized by a decrease in serum ceruloplasmin (a copper-binding protein). The disease is manifested by significant deposition of copper in the cells of the liver, kidneys, brain and cornea. Different types of changes are detected in the liver - chronic active hepatitis, large- or small-nodular cirrhosis. Angiotoxic changes (paralysis of small vessels, stasis, hemorrhages, edema, foci of necrosis, cysts) and cytotoxic changes (dystrophy and necrosis of nerve cells and astroglia; characteristic appearance ugly nuclei, naked nuclei, chromatolysis). A greenish ring of Kaiser-Fleischer appears in the peripheral parts of the cornea,

### **Formation of stones**

Stones (concrements) are dense formations lying freely in cavity organs or excretory ducts of glands. Stones are formed as a result of precipitation of salts from liquids located in these cavities or ducts.

The appearance of stones (shape, size, color, structure) is different, depending on localization in one or another cavity, chemical composition, mechanism of formation. There are huge stones and microliths. The shape of the stone often repeats the cavity it fills: round or oval stones - in the urinary and gall bladders, appendages - in the bowls and cups of the kidneys, cylindrical - in the ducts of the glands. Stones can be single or numerous. In the latter case, the stones often have a faceted, polished surface (faceted stones). The surface of stones is not only smooth, but also rough (oxalates, for example, resemble mulberry berries), which injures the mucous membrane and causes its inflammation. The color of the stones is determined by their chemical composition: white (phosphates), yellow (urates), dark brown or dark green (pigment) stones. In some cases, stones have a radial structure (crystalloid), in others - layered (colloidal), in others - layered-radial (colloidal-crystalloid). The chemical composition of stones is also different. Gallstones can be cholesterol, pigment, calcareous or cholesterol-pigment-calcareous (complex or combined stones). Urinary stones can consist of uric acid and its salts (urates), calcium phosphate (phosphates), calcium oxalate (oxalates), cystine and xanthine. Bronchial stones usually consist of mucus encrusted with lime. Urinary stones can consist of uric acid and its salts (urates), calcium phosphate (phosphates), calcium oxalate (oxalates), cystine and xanthine. Bronchial stones usually consist of mucus encrusted with lime. Urinary stones can consist of uric

acid and its salts (urates), calcium phosphate (phosphates), calcium oxalate (oxalates), cystine and xanthine. Bronchial stones usually consist of mucus encrusted with lime.

Most often, stones are formed in the biliary and urinary tracts and are the cause of the development of gallstones and urolithiasis. They are also found in other cavities and ducts: in the excretory ducts of the pancreas and salivary glands, in the bronchi and bronchiectasis (bronchial stones), in the crypts of the tonsils. A special type of stones is the so-called venous stones (phlebolites), which are petrified blood clots that have separated from the wall, and intestinal stones (coprolites), which occur when the contents of the intestine are encrusted.

The pathogenesis of stone formation is very complex and is determined by general and local factors. General factors include all kinds of metabolic disorders (fat, nucleoprotein, carbohydrates, minerals). For local ones - secretion disorders, inflammatory processes. The presence of stones can lead to diseases. Their complications are unfavorable (obturation of the ducts, inflammation, necrosis and perforation of the wall, formation of adhesions and cysts).

**Materials on the activation of students of higher education during the lecture: questions, situational tasks, etc(if necessary):**

A 25-year-old patient with a clinical picture of nephrotic syndrome underwent a puncture biopsy of the kidney. During microscopic examination, the cells of the epithelium of the proximal tubules of the nephron are enlarged in volume, in the cytoplasm there are vacuoles with a transparent liquid, the nucleus is shifted to the periphery. What kind of dystrophy was found in the epithelium of the tubules?

A And hydropic

B Grainy

C Zhirova

D Rohova

E Hyaline droplet

During histological examination of the myocardium of a 47-year-old patient with rheumatic heart disease (sectional material), large optically empty vacuoles were found in cardiomyocytes. When stained with osmic acid, they are black, when stained with Sudan III - yellow-red. Name the type of pathological process:

A And fatty dystrophy

B Hyaline droplet dystrophy

C Hydropic dystrophy

D Carbohydrate dystrophy

E Dysproteinosis

A 35-year-old woman was diagnosed with pharyngeal diphtheria. She died of acute heart failure. On autopsy: the heart cavity is widened in cross section, the heart muscle is dull, flaccid, variegated on cross-section, with yellowish areas under the

endocardium. What type of dystrophy is detected in cardiomyocytes?

And Zhirova

B Hydrocarbon

C Balloon

D Hyaline droplet

Hydropic

In a 45-year-old woman who died of chronic alcohol intoxication, the liver was sharply enlarged, had a dough-like consistency, and was yellowish in color at the autopsy. Microscopically, optically empty vacuoles of various sizes are found in the cytoplasm of hepatocytes when stained with hematoxylin and eosin. What kind of dystrophy does the place have?

A Parenchymatous fat

B Carbohydrate parenchymatous

C Hyaline droplet

D Mesenchymal fat

Hydropic

In a 45-year-old woman who died of chronic alcohol intoxication, the liver was sharply enlarged, had a dough-like consistency, and was yellowish in color at the autopsy. Microscopically, optically empty vacuoles of various sizes are found in the cytoplasm of hepatocytes when stained with hematoxylin and eosin. What kind of dystrophy does the place have?

A Parenchymatous fat

B Carbohydrate parenchymatous

C Hyaline droplet

D Mesenchymal fat

Hydropic

At the autopsy of a 49-year-old man who was in a hospital with hepatotropic intoxication and died suddenly, the liver was enlarged, flaccid, yellow-brown in color; drops of fat are visible on the surface of the liver cut and the knife blade. Microscopically: the hepatocytes of the periphery of classical liver lobes contain a mass of small droplets that fill the cytoplasm and push the nucleus to the periphery. Which process most likely takes place in the liver?:

A Fatty liver dystrophy

B Sphingomyelin lipidosis (Niemann-Pick disease)

Generalized gangliosidosis (Norman-Landing disease)

Ganglioside lipidosis (Tay-Sachs disease)

Cerebroside lipidosis (Gauche disease)

The child was diagnosed with pharyngeal diphtheria at the clinic. She died of acute heart failure. At the autopsy, it was found that the cavities of the heart are expanded in diameter, the heart muscle has a dull, lethargic, variegated appearance, with yellowish areas. In the cytoplasm of some cardiomyocytes with preserved cytoplasm, small vacuoles are detected, on frozen sections, vacuoles are stained with Sudan III in a yellow-hot color. What type of dystrophy is detected in cardiomyocytes?:

And Zhirova

BHyaline - dropsy

Hydropic

D Hydrocarbon

EBalloon

At the autopsy of the corpse of a woman who died with symptoms of heart failure, the heart is enlarged in volume, flabby; myocardium - clay-yellow, dull; from the side of the endocardium, a yellow-white streak is visible (tiger heart).

Microscopically: the groups of cardiomyocytes do not have transverse striations, the cytoplasm of cardiomyocytes contains small drops that are stained black with Sudan IV. Your diagnosis?:

A Fatty dystrophy of the myocardium

BCardiosclerosis

Rheumatic myocarditis

Heart obesity

EMyomalacia

In a 62-year-old man who died with increasing symptoms of heart failure, an enlarged heart was found at autopsy. The heart has a flaccid consistency, the chambers are stretched, the myocardium is dull, clay-yellow on cross-section. From the endocardium, a yellow-white striation is visible, which is especially pronounced in the papillary muscles.

What is the most likely pathological process?:

A Fatty dystrophy of the myocardium

Myomalacia

Cardiosclerosis

Obesity of the heart

Dilated cardiomyopathy

In a woman with severe intoxication due to sepsis, which was the direct cause of death, an autopsy revealed a "tiger heart". Microscopically, lipids were found in the cytoplasm of cardiomyocytes. What morphogenetic mechanism of development mainly underlies this dystrophy?:

Decomposition

BSedimentation

CTransformation

D Infiltration

Distorted synthesis

During the autopsy, it was found that the lungs were dense, brown in color due to the deposition of endogenous pigment. It is known that the patient had chronic venous stasis in the small circle of blood circulation during his life. What pathological process caused such a picture?

And Hemosiderosis

BMelanosis

CZhovtyanitsa

Porphyria

ECalcinosis

At the autopsy of a deceased man in his 70s, the heart was reduced in size, there was

no fatty tissue under the epicardium, and the myocardium was dense and brown in color. Under microscopy, cardiomyocytes are reduced in size, there are many granules of the brown lipofuscin pigment in the sarcoplasm. Determine the nature of the pathological process in the myocardium:

A Bura atrophy

Amyloidosis

Fatty dystrophy

D Hemochromatosis

Hypertrophy

An autopsy of a woman who suffered from adenoma of the parathyroid glands with hyperproduction of parathyroid hormone and died of chronic kidney failure revealed lime deposits in the stomach, lungs, and kidneys. What is the mechanism of development of calcification?

A Metastatic

B Metabolic

C Dystrophic

D Mixed

E-

A 46-year-old patient with rheumatic stenosis died of chronic pulmonary and heart failure. An autopsy revealed dense brown lungs. What pigment caused the color of the lungs?

Hemosiderin

B Melanin

Lipofuscin

Porphyrin

E Hemozoin

In typhoid fever, necrotized Peyer's patches of the small intestine are yellow-brown in color. What pigment permeates the necrotic tissue?:

A Bilirubin

B Melanin

Lipofuscin

D Hemoglobin

E Indol

### **General material and bulk-methodological support of the lecture:**

#### **Questions for self-control:**

1. General organization of the pathomorphology course
2. Definition of pathological anatomy (pathomorphology) as a subject

3. Development of pathomorphology as an independent science
4. Goals and objectives of our subject
5. Methods of pathological anatomy: autopsy and biopsy (with macroscopy, microscopy: light, phase-contrast, luminescence microscopy, histochemistry, immunohistochemistry, electron microscopy, genetic studies, etc.).
6. General information about pathogenic factors (endogenous and exogenous)
7. Types of cellular reactions (cellular response) to damage and development pathologies.
8. Definition of dystrophies (degenerations), causes of their development.
9. Mechanisms of development of dystrophies.
10. Types of dystrophies according to various signs, their morphology characteristics.
11. Intracellular (parenchymal) dystrophies, classification.
12. Intracellular protein dystrophies: granular, hyaline-droplet, hydropic, keratoid. Morphological characteristics, complications, consequences
13. Intracellular fatty dystrophy: powdery, small droplet, large droplet; fatty degeneration of the heart, kidneys, liver. Morphological characteristics, complications, consequences.
14. Intracellular carbohydrate degeneration. Accumulation diseases (storage diseases).

#### **References:**

##### **Main:**

1. Atlas of micropreparations in pathomorphology / I.I. Starchenko, B.M. Filenko, N.V. Royko, etc.; VDZU "UMSA". - Poltava, 2018. - 190 p
2. Starchenko, S.O. Bilokon and others.. – Poltava: Tov. "ASMI" - 2018. - 190 p.
3. Fundamentals of pathology according to Robbins: in 2 volumes. Volume 1 / Vinay Kumar, Abul K. Abbas, John C. Astaire; translation of the 10th Eng. edition. Publisher: All-Ukrainian specialized publishing house "Medytsyna". – X II. - 2019. - 420 p.
4. Fundamentals of pathology according to Robbins: in 2 volumes. Volume 1 / Vinay Kumar, Abul K. Abbas, John C. Astaire; translation of the 10th Eng. edition. Publisher: All-Ukrainian specialized publishing house "Medytsyna". – X II. - 2019. - 420 p.
5. Pathomorphology. General pathomorphology: a study guide / edited by Ya. Ya. Bodnara, V.D. Voloshina, A.M. Romanyuk, V.V. Gargin. - New Book, 2020. - 248 p.
6. Pathomorphology of the main diseases of the cardiovascular system: study guide / I.I. Starchenko, B.M. Filenko, N.V. Royko – Poltava: "UMSA". - 2019. - 150 p.
7. Starchenko I.I. Pathomorphology of the main diseases of the maxillofacial region: academician. manual / I.I. Starchenko, B.M. Filenko, V.V. Chernyak ; "UMSA". – Vinnytsia: Nova Kniga, 2019. – 128 p.
8. Starchenko I.I. Special pathomorphology (basic course) for students of medical faculties of higher medical educational institutions of III-IV levels of

accreditation / II Starchenko, N.V. Royko, B.M. Filenko. – Poltava, 2017. – 174 p.

9. Tuffaha S. A. Muin Immunohistochemistry in the diagnosis of tumors / S. A. Tuffaha Muin, S. G. Hychka, Husky Hans. - "Book Plus", 2018. - 336 p.

10. Essentials of pathology: textbook / Ya. Bodnar, A. Romanyuk, V. Voloshyn, V. Gargin - Kharkiv, "Planeta-Print" Ltd, 2020, 219 p.

11. Pathology: textbook / IVSorokina, VD Markovskiy, DI Halata et al.; edited by IVSorokina, VD Markovskiy, DI Halata. - Kyiv: AUS Medicine Publishing, 2019. - 328p. + 2 color inserts (8p. + 12p.).

12. Pathology: textbook / IVSorokina, VD Markovskiy, DI Halata et al.; edited by IVSorokina, VD Markovskiy, DI Halata. - 2nd edition. - Kyiv: AUS Medicine Publishing, 2020. - 328p. + 2 color inserts (8p. + 12p.).

#### Additional:

1. Benign neoplasms of bones of the maxillofacial area in children / P.I. Tkachenko, I.I. Starenko, S.O. Bilokin [and others] - P.: "UMSA", 2016. - 85 p

2. General pathomorphology / I.I. Starchenko, N.V. Royko, B.M. Filenko [et al.] – Poltava, 2016. – 136 p.

3. Zerbino D. D. Pathomorphology and histology: atlas / D. D. Zerbino, M. M. Bagriy, Y. Ya. Bodnar, V. A. Dibrova. – Vinnytsia: Nova Kniga, 2016. – 800 p.

4. Methods of morphological research / M.M. Baghrii, V.A. Dibrova, O.G. Papadynets, M.I. Grischuk; edited by M.M. Baghria, V.A. Dibrovyy – Vinnytsia: Nova Kniga, 2016. – 328 p.

5. Novoseltseva T.V. Pathology of sexual and endocrine systems / T.V. Novoseltseva, B.M. Filenko, N.I. Hasiuk - Poltava: LLC "ASMI", 2015. - 199 p.

6. Pathomorphology: national. / V.D. Markovskiy, V.O. Tumanskyi, I.V. Sorokina [and others]; edited by V.D. Markovsky, V.O. Tumanskyi. - K.: VSV "Medicine", 2015. - 936p.

7. Practicum on biopsy section course / I.I. Starchenko, A.P. Hasyuk, S.A. Proskurnya [etc.] – Poltava, 2016. – 160 p.

## Lecture No. 2

**Subject:** Necrosis-definition, terms and phases of development, consequences. Clinical and morphological forms of necrosis. Pathological anatomy of multiple organ failure. Fundamentals of Thanatology. Death, mechanisms, signs. Biological, medical, social aspects due to a chronic incurable disease. The concept of thanatogenesis. Structural mechanisms of cessation of activity of vital organs during the natural course of the disease. Complications of stopping the work of the heart, lungs, brain, kidneys, and liver.

**Actuality of theme:** Necrosis is the premature death and destruction of cells in a



living organism under the influence of factors, most often critical damage, terms and phases of development, consequences. Clinical and morphological forms of necrosis. Pathological anatomy of multiple organ failure. The basics of thanatology. Death, mechanisms, signs. Biological, medical, social aspects due to a chronic incurable disease. The concept of thanatogenesis. Structural mechanisms of cessation of activity of vital organs during the natural course of the disease. The immediate consequences of stopping the work of the heart, lungs, brain, kidneys, liver.

**Goal:** Familiarize yourself with the topic "Necrosis", its development phases, the consequences of the cause, forms and types, types of gangrene, determining the causes of pressure ulcers, and the causes of heart attacks, strokes, necrosis, understand the features of apoptosis, the concept of PON, and death.

**Basic concepts:** Necrosis, Coagulation (dry) necrosis, Infarct, Caseous necrosis, Zenker's, Fibrinoid, Fatty, Enzymatic fatty, Non-enzymatic fatty, Gangrene, Dry gangrene, Wet gangrene, Gas gangrene, Bedsore, Colicative necrosis, Brain infarction, Necrosis, Apoptosis, PON, Death.

### **Plan and organizational structure of the lecture:**

Greetings, verification of those present, announcement of the topic, purpose of the lesson, motivation of higher education seekers to study the topic.

### **Content of lecture material (lecture text)**

**Necrosis**(from the Greek nekros – dead) – death, death of cells and tissues in a living organism under the influence of disease-causing factors. This type of cell death is not genetically controlled.

Causes of necrosis: physical (gunshot wounds, radiation, electricity, low and high temperatures - frostbite and burns); toxic (acids, alkalis, salts of heavy metals, enzymes, drugs, ethyl alcohol, etc.); biological (bacteria, viruses, protozoa); allergic (endo- and exoantigens, for example, fibrinoid necrosis in infectious-allergic and autoimmune diseases, Artus phenomenon); vascular (heart attack - vascular necrosis); trophoneurotic (bedsores, unhealed ulcers).

Depending on the mechanism of action of the pathogenic factor, the following are distinguished: direct necrosis caused directly by the action of the factor (traumatic, toxic, and biological necrosis); indirect necrosis, which occurs directly through the vascular and neuroendocrine systems (allergic, vascular and

trophoneurotic necrosis).

Necrosis is preceded by a period of necrobiosis, the morphological substrate of which is dystrophic changes. In the initial period of necrobiosis, the cell is not morphologically changed. 1-3 hours must elapse before changes visible by electron microscopy or histochemistry appear, and at least 6-8 hours before changes visible by light microscopy appear; macroscopic changes develop even later.

One of the important and significant morphological signs of cell necrosis is changes in the structure of the nucleus. The chromatin of the dead cell condenses into large clumps, and the nucleus decreases in volume, becomes wrinkled, dense, intensely basophilic, i.e., stained dark blue with hematoxylin. This process is called karyopyknosis (shrinking). The pyknotic nucleus can then break up into numerous small basophilic particles (karyorrhexis) or undergo lysis (dissolution) as a result of the action of lysosomal deoxyribonuclease (karyolysis). Then it increases in volume, barely staining with hematoxylin, the contours of the nucleus are gradually lost. With rapidly developing necrosis, the nucleus undergoes lysis without a pyknotic stage.

In the cytoplasm, coagulation of proteins takes place, which is changed mainly by their colicivation.

Changes in the intercellular substance include both interstitium and fibrous structures. Most often, changes characteristic of fibrinoid necrosis develop: collagen, elastic and reticulin fibers turn into dense, homogeneous pink, sometimes basophilic masses that can undergo fragmentation, disintegration into lumps or lysis. Less often, edema, lysis, and sloughing of fibrous structures can be observed, which is characteristic of colliquative necrosis.

Necrosis is manifested by various clinical and morphological changes. The differences depend on the structural and functional features of organs and tissues, the speed and type of necrosis, as well as the causes of its occurrence and conditions of development. Among the clinical and morphological forms of necrosis, coagulation (dry) necrosis and colliquation (wet) necrosis are distinguished.

**Coagulation (dry) necrosis.** With this type of necrosis, cells that have died retain their contours for several days. Cells without a nucleus appear as a mass of

coagulated, homogeneous, pink cytoplasm.

The mechanism of coagulation necrosis is not clear enough. Coagulation of cytoplasmic proteins makes them resistant to the action of lysosomal enzymes and, in connection with this, their dissolution slows down.

Coagulation necrosis usually occurs in organs that are rich in proteins and poor in fluids, for example, in the kidneys, myocardium, adrenal glands, spleen, mainly due to insufficient blood circulation and anoxia, the effects of physical, chemical and other damaging factors, for example, coagulation necrosis of cells liver in case of viral damage or during the action of toxic agents of bacterial and non-bacterial origin. Coagulation necrosis is also called dry, because it is characterized by the fact that it causes dead, dry, dense areas that crumble, white or yellow in color.

*Infarctis* a dead area of an organ or tissue that is excluded from blood circulation as a result of a sudden cessation of blood supply (ischemia). A heart attack is a type of vascular (ischemic) coagulation or colliquation necrosis. Causes of heart attack: acute ischemia (caused by prolonged spasm, thrombosis or embolism, pressure on the arteries from the outside) and functional load of the organ in conditions with insufficient blood supply. Usually, heart attacks have a wedge-shaped shape. At the same time, the pointed part of the wedge faces the gate of the organ, and the wide part goes to the periphery. An infarct can involve a large part or the entire organ (subtotal or total infarct) or can be detected only under a microscope (microinfarct). If the heart attack develops according to the type of coagulation necrosis, then the tissue in the area of death becomes compacted, becomes dry, white-yellow in color (infarction of the myocardium, kidneys, spleen). Depending on the mechanism of development and appearance, the following are distinguished: white (ischemic) heart attack (with complete cessation of arterial blood circulation in the organs); red (hemorrhagic) heart attack (when blood exits the infarct zone from necrotized vessels of the microcirculatory channel); white heart attack with a hemorrhagic crown.

Aseptic and septic heart attacks are distinguished. Most infarcts of internal organs that do not come into contact with the environment are aseptic. Septic heart

attacks occur only when a secondary bacterial infection enters necrotized tissues.

Infarcts of the heart, brain, intestines, lungs, kidneys, spleen have the greatest clinical significance.

In the heart, the infarct is white with a hemorrhagic crown, has an irregular shape, occurs more often in the left ventricle and interventricular septum. Necrosis can be localized under the endocardium, epicardium, in the thickness of the myocardium or cover the entire thickness of the myocardium. In the area of infarction, thrombotic layers appear on the endocardium, and fibrinous layers appear on the pericardium.

A hemorrhagic heart attack occurs in the lungs, the cause of which is thromboembolism, less often - thrombosis in vasculitis. The area of the infarction is well separated, has the shape of a cone, the base of which is turned to the pleura. Layers of fibrin appear on the pleura, and a thrombus or embolus is found in the branches of the pulmonary artery.

In the kidneys, the infarct is white with a hemorrhagic crown. A cone-shaped area of necrosis covers either the cortical substance or the entire thickness of the parenchyma.

In the spleen, there are white infarcts with reactive fibrous inflammation of the capsule and the subsequent formation of adhesions with the diaphragm, parietal leaf of the peritoneum, etc.

In the intestines, infarcts are hemorrhagic and always subject to septic disintegration, which causes perforation of the intestinal wall and the development of peritonitis.

*Caseous necrosis* develops in tuberculosis, syphilis, leprosy, as well as in lymphogranulomatosis. It is also called specific, because it is most often found in specific infectious granulomas. In the internal organs, a dry, limited area of white-yellowish tissue appears, which crumbles easily. In syphilitic granulomas, very often such areas do not crumble, but are pasty, resembling glue. This is a mixed (that is, extra- and intracellular) type of necrosis, in which both parenchyma and stroma (both cells and fibers) die. Microscopically, this area of the tissue is structureless,

homogeneous, stained pink with hematoxylin and eosin, chromatin lumps of nuclei (karyorrhexis) are clearly visible.

*Waxy*, or Zenker's necrosis (necrosis of muscles, most often of the front abdominal wall and thigh, with severe infections - typhoid and typhus, cholera);

*Fibrinoid necrosis*— type of necrosis of connective tissue, which was previously considered in the lecture "Stromal-vascular dystrophy" as a result of fibrinoid edema. Fibrinoid necrosis is observed in allergic autoimmune diseases (for example, rheumatism, rheumatoid arthritis and systemic lupus erythematosus). Collagen fibers and smooth muscles of the middle layer of blood vessels are the most damaged. Fibrinoid necrosis of arterioles is observed in malignant hypertension. This necrosis is characterized by the loss of the normal structure of collagen fibers and the accumulation of a homogeneous, bright pink necrotic material that microscopically resembles fibrin.

*Fat necrosis* can be enzymatic or non-enzymatic.

*Enzymatic fat necrosis* most often occurs in acute pancreatitis and damage to the pancreas, when pancreatic enzymes leave the ducts in the surrounding tissues. Pancreatic lipase acts on triglycerides in fat cells, breaking them down into glycerol and fatty acids, which interact with plasma calcium ions to form calcium soaps. At the same time, opaque, white (like chalk) plaques and nodules (steatonecrosis) appear in the adipose tissue surrounded by the pancreas.

With pancreatitis, it is possible for lipase to enter the bloodstream, followed by widespread distribution, which is the cause of fat necrosis in many parts of the body. Subcutaneous adipose tissue and bone marrow are most often damaged.

*Non-enzymatic fat necrosis* observed in the mammary gland, subcutaneous adipose tissue and in the abdominal cavity. Most patients have a history of trauma. Non-enzymatic fat necrosis is also called traumatic fat necrosis, even if trauma is not identified as the underlying cause. Non-enzymatic fat necrosis causes an inflammatory response characterized by the presence of numerous macrophages with foamy cytoplasm, neutrophils, and lymphocytes. This is followed by fibrosis, and this process is sometimes difficult to distinguish from a tumor.

*Gangrene*(from the Greek gangraina - fire): this is the necrosis of tissues that are in contact with the external environment and change under its influence. The term "gangrene" is widely used to denote a clinical and morphological condition in which tissue necrosis is often complicated by a secondary bacterial infection of various degrees of severity or, being in contact with the external environment, secondary changes occur as a result. Dry, wet, gas gangrene and bedsores are distinguished.

*Dry gangrene* is necrosis of tissues that are in contact with the external environment, necrosis occurs without the participation of microorganisms. Dry gangrene most often occurs on the limbs as a result of ischemic coagulation necrosis of tissues. Necrotized tissues look black, dry, they are clearly separated from the adjacent viable tissue. Demarcation inflammation occurs at the border with healthy tissues. The color change is due to the transformation of hemoglobinogenic pigments in the presence of hydrogen sulfide into iron sulfide.

*Wet gangrene* develops as a result of attachment to necrotic tissue changes of a severe bacterial infection. Under the action of enzymes of microorganisms, secondary colicivation occurs. Cell lysis by enzymes that are not produced in the cell itself, but penetrate from the outside, is called heterolysis. The type of microorganisms depends on the localization of gangrene. Moist gangrene usually develops in tissues rich in moisture. It can be found on the limbs, but more often in internal organs, for example, in the intestine with obstruction of mesenteric arteries (thrombosis, embolism), in the lungs as a complication of pneumonia (influenza, measles). Children weakened by an infectious disease (more often measles) may develop wet gangrene of the soft tissues of the cheeks and perineum, which is called a noma (from the Greek nome - water cancer). Acute inflammation and accumulation of bacteria is the reason why

*Gas gangrene* occurs when the wound is infected with anaerobic flora, for example, *Clostridium perfringens* and other microorganisms of this group. It is characterized by widespread tissue necrosis and the formation of gases due to the enzymatic activity of the bacterium. The main manifestations are similar to wet gangrene, but with the additional presence of gas in the tissues. Crepitation (cracking phenomenon during palpation) is a frequent clinical symptom of gas gangrene.

*Bed-sore*(decubitus) is a type of gangrene, necrosis of the superficial parts of the body (skin, soft tissues), which are subject to pressure between the bed and the bone. Therefore, bedsores most often appear in the areas of the sacrum, spinous processes of the vertebrae, and the greater trochanter of the femur. According to its genesis, it is trophoneurotic necrosis, because vessels and nerves are squeezed, which increases tissue trophic disorders in seriously ill patients suffering from cardiovascular, oncological, infectious or nervous diseases.

### **Colicative (moist) necrosis.**

Colicative (wet) necrosis is characterized by the melting of dead tissue. It develops in tissues relatively poor in proteins and rich in liquid, where there are favorable conditions for hydrolytic processes. Cell lysis occurs as a result of the action of own enzymes (autolysis). A typical example of moist colliquative necrosis is an area of gray softening (ischemic infarction) of the brain.

*Brain infarction* often called softening, because the main macroscopic feature is a decrease in the elasticity of the brain tissue in the affected area in all terms. During the first days, it is a vaguely limited area of a bluish shade, soft to the touch. By the end of the first days, the area becomes clearer and pales. In the following days, the brain substance in this area becomes even more limp, yellowish in color, sometimes even with a greenish tint.

Microscopically, the brain tissue is homogeneous, structureless, slightly pink when stained with hematoxylin and eosin. Resorption of dead tissues is carried out by macrophages, which have the appearance of fat-granular balls.

Necrosis is an irreversible process. With a relatively favorable outcome, reactive inflammation occurs around the dead tissue, which separates the dead tissue. Such inflammation is called demarcation, and the separation zone is called the demarcation zone. In this zone, blood vessels expand, hematoma, edema occurs, a large number of leukocytes appear, which release hydrolytic enzymes and melt necrotic masses. Necrotic masses are absorbed by macrophages. After that, the cells of the connective tissue multiply, which replaces or overgrows the area of necrosis. When dead masses are replaced by connective tissue, they are said to be organized. In

such cases, a scar forms at the site of necrosis (a scar at the site of a heart attack). Overgrowth of the area of necrosis with connective tissue leads to its encapsulation. In dead masses with dry necrosis and in the area of necrosis, which has been organized, calcium salts can be deposited. In this case, calcification (petrification) of the necrosis center develops. In some cases, bone formation - ossification - is noted in the area of death. During the resorption of tissue detritus and the formation of a capsule, which occurs with wet necrosis and most often in the brain, a cavity - a cyst - appears at the site of death.

An unfavorable outcome of necrosis is purulent (septic) melting of the necrotic area. Sequestration is the formation of an area of dead tissue that is not subject to autolysis, is not replaced by connective tissue, and is freely located among living tissues. Sequestrations occur more often in bones with inflammation of the bone marrow - osteomyelitis. A sequestral capsule and a cavity filled with pus form around such a sequestration. Sequester often leaves the cavity through fistulas, which close only after its complete removal. A type of sequestration - mutilation - rejection of the ends of the fingers.

The importance of necrosis is determined by exclusion from the function of dead zones, therefore, necrosis of vital organs, especially large areas of them, often leads to death. Often tissue death can be the cause of severe complications of many diseases (heart rupture in myomalacia, paralysis in hemorrhoids and ischemic strokes, infections in massive bedsores, intoxication in connection with the effect on the body of the products of tissue decay, for example, gangrene of a limb, etc.).

### **Apoptosis.**

The term "apoptosis" was first proposed by W. Kerr and AR Currie, who described the unique morphology of tumor cell death. With this, they showed that there are two morphologically distinct forms of cell death: apoptosis and necrosis. The term "apoptosis" is used to refer to this form of cell death, in which it actively produces certain molecules involved in energy production processes aimed at self-destruction. This term is used to describe the normal, regular process of tissue termination in a multicellular organism at various stages of embryogenesis, which is



necessary for the formation of organs, replacement of some tissues by others, resorption of temporary organs, etc. Therefore, the following forms of programmed cell death were distinguished: phylogenetic, morphogenetic, histogenetic and death of individual cells. Such a program is necessary for the development and functioning of higher organisms, in which there are constant changes in the cell populations of most tissues and complex processes of morphogenesis, which require the regulation of the death of a large number of cells in the process of embryogenesis. Such a mechanism is very important for multicellular organisms, because with it the death of a certain subpopulation of cells is not accompanied by damage to the surrounding structures. In addition, the cell death program is necessary to eliminate damaged, mutated, and virus-infected cells that are potentially dangerous for the entire body. Apoptosis is one form of cell death; cell self-destruction has an active nature involving energy. It can occur as a programmed process, which is carried out due to the effects of tumor necrosis factor- in which there is a regular change in the cell populations of most tissues and complex processes of morphogenesis, which require the regulation of the death of a large number of cells in the process of embryogenesis. Such a mechanism is very important for multicellular organisms, because with it the death of a certain subpopulation of cells is not accompanied by damage to the surrounding structures. In addition, the cell death program is necessary to eliminate damaged, mutated, and virus-infected cells that are potentially dangerous for the entire body. Apoptosis is one form of cell death; cell self-destruction has an active nature involving energy. It can occur as a programmed process, which is carried out due to the effects of tumor necrosis factor-

can occur as a programmed process, which is carried out due to the effects of tumor necrosis factor- which require the regulation of the death of a large number of cells in the process of embryogenesis. Such a mechanism is very important for multicellular organisms, because with it the death of a certain subpopulation of cells is not accompanied by damage to the surrounding structures. In addition, the cell death program is necessary to eliminate damaged, mutated, and virus-infected cells that are potentially dangerous for the entire body. Apoptosis is one form of cell death; cell self-destruction has an active nature involving energy. It can occur as a programmed process, which is carried out due to the effects of tumor necrosis factor- which require the regulation of the death of a large number of cells in the process of embryogenesis. Such a mechanism is very important for multicellular organisms, because with it the death of a certain subpopulation of cells is not accompanied by damage to the surrounding structures. In addition, the cell death program is necessary to eliminate damaged, mutated, and virus-infected cells that are potentially dangerous for the entire body. Apoptosis is one form of cell death; cell self-destruction has an active nature involving energy. It can occur as a programmed process, which is carried out due to the effects of tumor necrosis factor- the cell death program is necessary for the elimination of damaged, mutated and virus-infected cells that are potentially dangerous for the entire body. Apoptosis is one form of cell death; cell self-destruction has an active nature involving energy. It can occur as a programmed process, which is carried out due to the effects of tumor necrosis factor- the cell death program is necessary for the elimination of damaged, mutated and virus-infected cells that are potentially dangerous for the entire body. Apoptosis is one form of cell death; cell self-destruction has an active nature involving energy. It can occur as a programmed process, which is carried out due to the effects of tumor necrosis factor-  $\alpha$ (TNF- $\alpha$ ), or Fas-ligand (FasL) on the corresponding receptors, or in response to numerous exogenous influences—both physiological and pathological (chronic harmful stimuli at a subtoxic level). These include cytotoxic drugs, ionizing radiation, hypoxia, free radicals, cytolytic secretions of cytotoxic lymphocytes, disruption of cell-cell and cell-matrix connections, presence or absence of specific growth factors,

increase or decrease in the level of specific hormones (for example, steroid), etc. . These etiological factors lead to the launch of the next phases of the cell death process, which is a cascade, with the participation of numerous activator, effector and negative regulators. The active process of apoptosis can be interrupted or stopped by general inhibitors of RNA or protein synthesis, which indicates the existence of a certain number of specific genes and proteins required for its initiation, progression and regulation. Morphological manifestations of apoptosis are observed in the nucleus, cytoplasm and plasma membrane. Characteristic changes are ring-shaped condensation of chromatin on the periphery of the nucleus (margination) with intact cytoplasmic and organoid membranes, compaction of the cytoplasm, cell collapse due to the destruction of the cytoskeleton, loss of microvilli, fragmentation of the entire cell, and in most, but not all tissues, the formation of apoptotic bodies. A cell in a state of apoptosis is usually quickly phagocytosed by macrophages, epithelial or other cells without demarcation inflammation. Apoptosis is always accompanied by compression and densification of the cell due to its loss of water, although the membrane pump continues to function throughout the cascade. Characteristic changes are ring-shaped condensation of chromatin on the periphery of the nucleus (margination) with intact cytoplasmic and organoid membranes, compaction of the cytoplasm, cell collapse due to the destruction of the cytoskeleton, loss of microvilli, fragmentation of the entire cell, and in most, but not all tissues, the formation of apoptotic bodies. A cell in a state of apoptosis is usually quickly phagocytosed by macrophages, epithelial or other cells without demarcation inflammation. Apoptosis is always accompanied by compression and densification of the cell due to its loss of water, although the membrane pump continues to function throughout the cascade. Characteristic changes are ring-shaped condensation of chromatin on the periphery of the nucleus (margination) with intact cytoplasmic and organoid membranes, compaction of the cytoplasm, cell collapse due to the destruction of the cytoskeleton, loss of microvilli, fragmentation of the entire cell, and in most, but not all tissues, the formation of apoptotic bodies. A cell in a state of apoptosis is usually quickly phagocytosed by macrophages, epithelial or other cells without demarcation

inflammation. Apoptosis is always accompanied by compression and densification of the cell due to its loss of water, although the membrane pump continues to function throughout the cascade. but not in all tissues, the formation of apoptotic bodies. A cell in a state of apoptosis is usually quickly phagocytosed by macrophages, epithelial or other cells without demarcation inflammation. Apoptosis is always accompanied by compression and densification of the cell due to its loss of water, although the membrane pump continues to function throughout the cascade. but not in all tissues, the formation of apoptotic bodies. A cell in a state of apoptosis is usually quickly phagocytosed by macrophages, epithelial or other cells without demarcation inflammation. Apoptosis is always accompanied by compression and densification of the cell due to its loss of water, although the membrane pump continues to function throughout the cascade.

Apoptosis plays a leading role in the normal development and restoration of tissue, in the process of embryogenesis, immune response, ontogenesis. Many works are devoted to the study of this phenomenon in the placenta both during pregnancy with a physiological course and during pathology.

Early apoptotic damage to the cytoskeleton and plasma membranes, induced by initiator caspases, does not necessarily end in cell death by apoptosis, since the progression of the cascade can be delayed or even blocked by inhibitors of the activation of executive caspases before the onset of irreversible degenerative changes. Bcl-2 and mcl-1 are two leading inhibitors of the apoptotic cascade, found in various tissues and cells in which apoptosis could be temporarily blocked, for example in E-lymphocytes

The final stage of apoptosis is characterized by internucleosomal DNA degradation, which occurs under the influence of non-lysosomal nuclear endonucleases, which in some cells are activated by  $\text{Ca}^{2+}$  and  $\text{Mg}^{2+}$  and inhibited by  $\text{Zn}^{2+}$ , in others—discovered  $\text{Ca}^{2+}$ - and  $\text{Mg}^{2+}$ -independent endonucleases. Late apoptotic changes that indicate the irreversible progression of the cascade caused by the activation of executive caspases are chromatin condensation and damage to the

nuclear structure. Condensation of chromatin usually begins with a diffuse increase in the density of the nucleus with the subsequent formation of areas of greatest density on the periphery of the nucleus, which ultimately leads to annular (ring-shaped) condensation of chromatin. This is accompanied by a decrease in the volume of the nucleus. In most, but not all tissues, nuclear and cellular fragments form small apoptotic bodies that are phagocytosed by macrophages without the development of an inflammatory response.

### **Multiple organ failure**

Multiple organ failure (POF) is universal damage to all organs and tissues of the body by aggressive mediators of a critical state. PON is not a simple result of organ failure, it is a new form of pathology. It forms the basis of any critical condition regardless of its etiology. Therefore, PON can be considered as a basic pathophysiological process. There are 2 groups of factors that cause PON: complications of pathology that lead to such a violation of vital functions that requires their artificial replacement; pathology arising in connection with medical actions of a curative, diagnostic and preventive nature (radiation damage during X-ray and radiological studies and radiation therapy; allergic and toxic reactions to contrast agents and test preparations; instrumental injuries caused by endoscopes and other instruments; drug intoxication (chemotherapy of tumors, etc.); allergic reactions to medications, mechanical damage to organs during operations, accompanied by the development of operational stress; reactions to vaccination; invasive methods of intensive therapy and diagnostics, which sometimes cause increased PON.

All named processes lead to relative tissue ischemia. During a reduction in the volume of circulating blood (external blood loss, blood sequestration, capillary loss), a hypovolemic vicious cycle occurs, accompanied by the centralization of blood circulation, during which blood is redistributed to the benefit of vital organs (brain, heart, lungs, etc.) with simultaneous reduction of microcirculation in peripheral tissues (ischemia). These mechanisms make a certain contribution to the pathogenesis of PON.

The problems of the strategy of such non-standard conditions as PON need to be solved by normalizing the body's energy, detoxification, syndromic therapy, and reducing harmful effects.

### **Death, signs of general death.**

Death is the irreversible termination of the body's vital activity. Natural death, violent death, and death from disease are distinguished.

*Natural death* occurs in the elderly from the old wear and tear of the body. Violent death is the result of such malicious actions as murder, suicide, injury, accidents. Death from diseases is caused by changes incompatible with life, which occur under the influence of pathogenic factors.

*Clinical death* characterized by the cessation of breathing and blood circulation, and within a few minutes, changes in vital activity can be reversed. Biological death - irreversible changes in the body's vital activity, the beginning of autolytic processes.

Signs of general death are: cooling of the corpse, cadaveric incantation, cadaveric desiccation, redistribution of blood, corpse stains, decay of corpse tissues. The cooling of the corpse ("algor mortis") occurs as a result of the cessation of metabolic processes and the gradual equalization of the temperature of the body and the environment. Rigor mortis is characterized by a sharp tightening of the somatic muscles due to the disappearance of ATP acid from them after death and the accumulation of lactic acid in them (2-5 hours after the death). Corpse drying occurs as a result of evaporation of moisture from its surface: this applies to the skin, eyeballs, mucous membranes. The redistribution of blood is characterized by its accumulation in the veins, while the lumen of the arteries remains almost empty. Postmortem blood coagulation takes place in the veins. Corpse spots arise in connection with the redistribution of blood and are presented in the form of corpse hypostases (appear after 3–6 hours) or corpse imbibition (appears much later as a result of hemolysis of erythrocytes and tissue imbibition with blood plasma stained with hemoglobin). Corpse decay is caused by the processes of autolysis in connection

with the reproduction of putrefactive microorganisms in the intestines.

**Materials on the activation of students of higher education during the lecture: questions, situational tasks, etc(*if necessary*):**

In a child after measles, examination of the soft tissues of the cheeks and perineum revealed vaguely demarcated, swollen, red-black areas that fluctuate slightly. What complication did the child develop?

AND Wet gangrene

B Dry gangrene

Gas gangrene

D Bedsores

Atrophic ulcer

In a 6-year-old child hospitalized for measles pneumonia, the dentist found a dirty-gray area measuring 2x2.5 cm without clear boundaries on the mucous membrane of the cheek. Soft tissues are swollen, dim, with an unpleasant smell. What is the most likely diagnosis established by the dentist?

AND Noma

B Gangrenous stomatitis

Pustular stomatitis

Phlegmonous stomatitis

Ulcerative stomatitis

A 70-year-old patient was operated on for "acute abdomen". During the operation, about 80 cm of the ileum was found to be black, the peritoneum was dull, the lumen of the superior mesenteric artery was blocked by a thrombus. What process developed in the intestine?:

AND Gangrene

B White heart attack

Coagulation necrosis

D White heart attack with a hemorrhagic crown

Bedsores

A patient with diabetes developed a sharp pain in the right foot. On examination, the big toe is black, the tissues of the foot are swollen, the epidermis is peeling off, discharge with an unpleasant smell. What clinical and morphological form of necrosis developed in the patient?:

AND Gangrenous moisture

B Dry gangrene

Heart attack

D Bedsores

E Sequestration

An autopsy of a 57-year-old man who died of typhus revealed that the muscles of the anterior abdominal wall and thighs were dense, whitish-yellow in color, resembling a stearin candle. The described changes in the muscles are a manifestation of which

pathological process:  
A AND Waxy necrosis  
B Fibrinoid necrosis  
C Caseous necrosis  
D Colic necrosis  
E Apoptosis

## **General material and bulk-methodological support of the lecture:**

### **Questions for self-control:**

1. Definition of necrosis.
2. Causes of necrosis. Mechanisms of irreversible cell damage.
3. Classification of necrosis according to various criteria.
4. The concept of coagulation necrosis, collicative necrosis, caseous necrosis.
5. Heart attack as a type of necrosis: definitions, types, their morphology characteristics, complications and consequences.
6. Gangrene as a type of necrosis: definition, types, their morphology characteristics, complications, consequences.
7. Bedsores and noma as separate types of gangrene: causes of development, morphological characteristics, results.
8. Sequestration as a type of necrosis, morphological characteristics, consequences.
9. Fibrinoid, fatty and waxy (Zenker) necrosis, morphological characteristics.
10. Stages of necrosis. Morphological characteristics.
11. Consequences and complications of necrosis.
12. Comparative characteristics of necrosis and apoptosis
13. Death, definition of death, types of death.
14. Postmortem changes in the body.

### **References:**

Main:

1. Atlas of micropreparations in pathomorphology / I.I. Starchenko, B.M. Filenko, N.V. Royko, etc.; VDZU "UMSA". - Poltava, 2018. - 190 p
2. Starchenko, S.O. Bilokon and others.. – Poltava: Tov. "ASMI" - 2018. - 190 p.
3. The basics of pathology according to Robbins: in 2 volumes. Volume 1 / Vinay Kumar, Abul K. Abbas, John C. Astaire; translation of the 10th Eng. edition. Publisher: All-Ukrainian specialized publishing house "Medytsyna". – X II. - 2019. - 420 p.



4. The basics of pathology according to Robbins: in 2 volumes. Volume 1 / Vinay Kumar, Abul K. Abbas, John C. Astaire; translation of the 10th Eng. edition. Publisher: All-Ukrainian specialized publishing house "Medycyna". – X II. - 2019. - 420 p.
5. Pathomorphology. General pathomorphology: a study guide / edited by Ya. Ya. Bodnara, V.D. Voloshina, A.M. Romanyuk, V.V. Gargin. - New Book, 2020. - 248 p.
6. Pathomorphology of the main diseases of the cardiovascular system: study guide / I.I. Starchenko, B.M. Filenko, N.V. Royko – Poltava: "UMSA". - 2019. - 150 p.
7. I.I. Starchenko Pathomorphology of the main diseases of the maxillofacial region: academician. manual / I.I. Starchenko, B.M. Filenko, V.V. Chernyak ; "UMSA". – Vinnytsia: Nova Kniga, 2019. – 128 p.
8. Ctarchenko I.I. Special pathomorphology (basic course) for students of medical faculties of higher medical educational institutions of III-IV levels of accreditation / II Starchenko, N.V. Royko, B.M. Filenko. – Poltava, 2017. – 174 p.
9. Tuffaha S. A. Muin Immunohistochemistry in tumor diagnostics / S. A. Tuffaha Muin, S. G. Hychka, Gusky Hans. - "Book Plus", 2018. - 336 p.
10. Essentials of pathology: textbook / Ya. Bodnar, A. Romanyuk, V. Voloshyn, V. Gargin - Kharkiv, "Planeta-Print" Ltd, 2020, 219 p.
11. Pathology: textbook / IVSorokina, VD Markovskiy, DI Halata et al.; edited by IVSorokina, VD Markovskiy, DI Halata. - Kyiv: AUS Medicine Publishing, 2019. - 328p. + 2 color inserts (8p. + 12p.).
12. Pathology: textbook / IVSorokina, VD Markovskiy, DI Halata et al.; edited by IVSorokina, VD Markovskiy, DI Halata. - 2nd edition. - Kyiv: AUS Medicine Publishing, 2020. - 328p. + 2 color inserts (8p. + 12p.).

#### Additional:

1. Benign neoplasms of bones of the maxillofacial area in children / P.I. Tkachenko, I.I. Starenko, S.O. Bilokin [and others] - P.: "UMSA", 2016. - 85 p
2. General pathomorphology / I.I. Starchenko, N.V. Royko, B.M. Filenko [et al.] – Poltava, 2016. – 136 p.
3. Zerbino D. D. Pathomorphology and histology: an atlas / D. D. Zerbino, M. M. Bagrii, Y. Ya. Bodnar, V. A. Dibrova. – Vinnytsia: Nova Kniga, 2016. – 800 p.
4. Methods of morphological research / M.M. Baghrii, V.A. Dibrova, O.G.

- Papadynets, M.I. Grischuk; edited by M.M. Baghria, V.A. Dibrov – Vinnytsia: Nova Kniga, 2016. – 328 p.
5. Novoseltseva T.V. Pathology of sexual and endocrine systems / T.V. Novoseltseva, B.M. Filenko, N.I. Hasiuk - Poltava: LLC "ASMI", 2015. - 199 p.
  6. Pathomorphology: national. / V.D. Markovskiy, V.O. Tumanskiy, I.V. Sorokina [and others]; edited by V.D. Markovsky, V.O. Tumanskiy. - K.: VSV "Medicine", 2015. - 936p.
  7. Workshop on biopsy-sectioning course / I.I. Starchenko, A.P. Hasyuk, S.A. Proskurnya [etc.] – Poltava, 2016. – 160 p.

### Lecture No. 3

**Topic:** Rcirculatory disorders: hyperemia, ischemia, heart attack, bleeding, hemorrhage, stasis, plasmarrhagia. Shock. Violation of lymphatic circulation.

**Actuality of theme:** In this topic, we will consider the dysfunction of the cardiovascular system of the human body, such as circulatory disorders: hyperemia, ischemia, heart attack, bleeding, hemorrhage, stasis, plasmarrhagia. Shock. Violation of lymphatic circulation.

**Goal:** Familiarize yourself with circulatory disorders, types of hemoptysis and hyperemia, causes of ischemia, types and causes of bleeding, familiarize yourself with such concepts as: Plasmarrhagia, stasis, shock (shock organs), embolism, thrombosis (and its types), and DVZ -syndrome.

**Basic concepts:** Hyperemia: physiological, pathological, arterial, venous, edema, anasarca, bluish compaction of the spleen, cyanotic compaction kidneys, brown compaction of the lungs, nutmeg liver; bleeding and hemorrhages: epistaxis, hemoptysis, vomiting blood, cyclic and acyclic uterine bleeding, blood in stool, urine, hematomas, hemorrhagic inclusions, ecchymoses, purpura, pithecia, hemopericardium, hemoperitoneum, hemothorax, hydrothorax, pyothorax, hemarthrosis; thrombosis, thrombus (white, red mixed, occlusive, parietal, moranic, axial, spherical, agonal), embolism (thromboembolism, gasembolism, air, tissue, foreign body embolism, fat, amniotic fluid)

#### Plan and organizational structure of the lecture:

Greetings, verification of those present, announcement of the topic, purpose of the

lesson, motivation of higher education seekers to study the topic.

### **Content of lecture material (lecture text)**

It is difficult to imagine the normal functioning of the body without the clear work of the organs of blood and lymph circulation, which are in close structural and functional unity.

The function of the circulatory system determines, first of all, the level of metabolic processes in each tissue and each organ, necessary for sending specialized function. The circulatory system performs this transport and exchange function together with the lymphatic drainage system and the blood system. From this it follows that in the course of microcirculation, with the help of which transcapillary exchange is carried out, the circulatory and lymphatic systems, as well as blood, serve the same purpose and function interconnectedly.

The circulatory system coordinates and connects functionally different organs and systems in the interests of the organism as a whole. This coordinating function in relation to homeostasis is performed by the circulatory system with the help of the lymphatic system. The function of the circulatory system, as well as the lymphatic system, is ensured by mechanisms of neurohumoral regulation (nerve devices of the heart, vascular receptors, vasomotor center, humoral constants of blood, lymph, vasoconstrictors and vasodilators, etc.). But the circulatory system, as well as the lymphatic system, is united into a single entity not only functionally, but also structurally: the heart is the source of blood flow, vessels are the source of blood distribution and lymph collection; the microcirculatory channel is a bridgehead for transcapillary exchange and tissue metabolism. However, structural and functional integration as a circulatory,

Disorders of blood circulation can be divided into 3 groups: 1) disorders of blood filling, determined by complete blood (arterial or venous) and anemia; 2) violation of the permeability of the vessel wall, which should include bleeding (hemorrhage) and plasmorrhagia; 3) violation of blood flow and state (ie, rheology) of blood in the form of stasis, sludge phenomenon, thrombosis, and embolism.

**Thoroughbred**(hyperemia) can be arterial and venous.

**Arterial full blood** - increased blood filling of an organ, tissue due to increased arterial blood flow. It can be general, which is observed with an increase in the volume of circulating blood (plethora) or the number of erythrocytes (erythremia). In such cases, there is a red color of the skin and mucous membrane and an increase in blood pressure. More often, arterial hyperemia is local in nature and occurs for various reasons.

Physiological arterial hyperemia that occurs under the influence of adequate doses of physical and chemical factors, feelings of anger, shyness (reflex hyperemia), when the function of organs increases (working hyperemia), and pathological arterial hyperemia.

Based on the features of the etiology and mechanism of development, the following types of pathological arterial hyperemia are distinguished: angioneurotic (neuroparalytic); collateral; hyperemia after anemia (postanemic); vacant; inflammatory; hyperemia on the basis of arteriovenous fistula.

*Angioneurotic (neuropathic) hyperemia* observed as a result of irritation of vasodilator nerves or paralysis of vasoconstrictor nerves. The skin and mucous membranes become red, slightly swollen, warm or even hot to the touch. This type of hyperemia can occur in some parts of the body when the innervation is disturbed; on the skin and mucous membranes of the face in case of some infectious diseases, in which damage to nodes of the sympathetic nervous system is possible; this type of hyperemia passes quickly, without consequences.

*Collateral hyperemia* arises in connection with the obstruction of blood flow in the main arterial trunk closed by a thrombus or embolus. In such cases, blood is directed through collateral vessels. Their lumen reflexively expands, the flow of arterial blood increases and the tissue receives an increased amount of blood.

*Hyperemia after anemia*(postanemic) develops in those cases when the factor that caused compression of the artery (tumor, accumulation of fluid in the cavities, ligature, etc.) and ischemia of the tissues is quickly eliminated. In such cases, the vessels of the previously bloodless tissue expand sharply and overflow with blood,

which can lead not only to their rupture and hemorrhage, but also to ischemia of other organs, for example, the brain, due to a sharp redistribution of blood. Therefore, such manipulations as removing fluid from body cavities, large tumors, and removing an elastic tourniquet should be performed slowly.

*Vacuated hyperemia* (from Latin *Vacuus* - empty) develops in connection with a decrease in barometric pressure. It can be common, for example, in divers and caisson workers when quickly rising from a place of increased pressure. The hyperemia that occurs at the same time is associated with gas embolism, thrombosis of blood vessels, and hemorrhages.

Local vacant hyperemia appears on the skin under the influence of, for example, medical cans, which form a rarefied space (vacuum) over certain areas.

*Inflammatory hyperemia* is a constant companion of inflammation.

*Hyperemia on the basis of arteriovenous fistula* occurs in those cases when, for example, with a gunshot wound or other injury, there is a connection between an artery and a vein, then the arterial blood is directed into the vein.

The value of pathological arterial hyperemia is determined by its type. Collateral hyperemia is compensatory in nature and ensures blood circulation with a closed arterial trunk. Inflammatory hyperemia is a mandatory component of this protective and adaptive reaction. At the same time, vacant hyperemia becomes one of the components of caisson disease.

**Venous full blood** - increased blood filling of an organ or tissue in connection with a violation (reduction) of blood outflow; blood flow at the same time is unchanged or reduced. Congestion of venous blood (congestive hyperemia) leads to dilation of veins and capillaries, slowing of blood flow in them, which is associated with the development of hypoxia and increased permeability of the basal membranes of capillaries.

Venous congestion can be general or local.

*General venous congestion* develops in cardiovascular diseases systems that cause acute or chronic heart (cardiovascular) failure; can be both acute and chronic.

In acute general venous congestion, which is a manifestation of the syndrome

of acute heart failure (insufficiency of myocardial contractility during myocardial infarction, acute myocarditis), as a result of hypoxic damage to histohematal barriers and a sharp increase in capillary permeability in tissues, plasma seepage (plasmorrhagia) and edema are observed, stasis in capillaries and multiple hemorrhages of a diapedic nature; dystrophic and necrotic changes develop in parenchymal organs. The structural and functional features of the organ in which acute venous stasis occurs determine the preference for edematous-plasmorrhagic, hemorrhagic or dystrophic and necrotic changes, their combination is possible. Histophysiological features of aerogenic bar' The development of edema and hemorrhages in acute venous stasis is explained by pulmonary edema. Due to the peculiarities of the nephron structure and blood circulation, mainly dystrophic and necrotic changes occur in the kidneys, especially the tubule epithelium. In the liver, in connection with the peculiarities of the architecture of the hepatic lobule and its blood circulation, centrilobular hemorrhages and necrosis appear in it during acute pleurisy.

*Chronic general venous congestionis* a manifestation of the syndrome of chronic heart (cardiovascular) failure, which complicates many chronic heart diseases (heart defects, ischemic heart disease, chronic myocarditis, cardiomyopathy, endocardial fibroelastosis, etc.). It often causes severe, irreversible changes in organs and tissues. By maintaining a state of tissue hypoxia for a long time, it determines the development of not only plasmorrhagia, edema, stasis and hemorrhages, dystrophy and necrosis, but also atrophic and sclerotic changes. Sclerotic changes, that is, the development of connective tissue, are associated with the fact that chronic hypoxia stimulates the synthesis of collagen by fibroblasts and fibroblast-like cells. Connective tissue displaces parenchymal elements, stagnant compaction (induration) of organs and tissues develops. Aqueous cycle in chronic venous congestion

Organ changes in chronic venous stasis, despite a number of common features (stasis and induration), have their own characteristics.

The skin, especially of the lower extremities, becomes cold and acquires a blue color (cyanosis). The veins of the skin and subcutaneous tissue are dilated, filled with blood; enlarged and filled with lymph and lymphatic vessels. Pronounced swelling of

the dermis and subcutaneous tissue, the development of connective tissue in the skin. In connection with venous stasis, edema and sclerosis, inflammatory processes and ulcers occur in the skin, which do not heal for a long time.

With chronic venous stasis, the liver is enlarged, dense, the edges are rounded, the dissection surface is gray-yellow with a dark red speck, similar to nutmeg, which is why such a liver is called "nutmeg".

Under microscopic examination, it is observed that only the central parts of the lobules, where hepatocytes are destroyed; these areas on liver dissection are dark red in color. On the periphery of the lobules, the liver cells are in a state of dystrophy, often fatty, which explains the gray-yellow color of the liver tissue.

The morphogenesis of liver changes with long-term venous stasis is quite complex. Selective hemolysis of the lobular center is due to the fact that congestion in the liver covers, first of all, the hepatic veins, spreading to the collecting and central veins, and then to the sinusoids. The latter expand not only in the central and middle parts of the lobes, where they meet resistance from the capillary branches of the hepatic artery flowing into the sinusoids, where the pressure is higher than in the sinusoids. As the whole blood grows, hemorrhages appear in the center of the lobes; dystrophy, atrophy and necrosis develop in hepatocytes. Hepatocytes of the periphery of the lobes compensatory hypertrophy and become similar to centrilobular ones. The growth of connective tissue in the area of hemorrhages and death of hepatocytes is associated with the proliferation of cells of sinusoids - lipocytes, which can act as fibroblasts, and near the central and collecting veins - with the proliferation of fibroblasts of the adventitia of these veins. As a result of the growth of connective tissue in the sinusoids, a continuous basement membrane appears (it is absent in a normal liver), that is, the sinusoids capillarize, a capillary-parenchymal block occurs, which increases hypoxia and leads to the progression of atrophic and sclerotic changes in the liver. This process is also facilitated by blood shunting, which develops with sclerosis of the walls and obturation of the lumen of many central and collecting veins, as well as increasing stagnation of lymph - this is how congestive fibrosis (sclerosis) of the liver is formed. a capillary-parenchymal block occurs,

which increases hypoxia, leads to the progression of atrophic and sclerotic changes in the liver. This process is also facilitated by blood shunting, which develops with sclerosis of the walls and obturation of the lumen of many central and collecting veins, as well as increasing stagnation of lymph - this is how congestive fibrosis (sclerosis) of the liver is formed. a capillary-parenchymal block occurs, which increases hypoxia, leads to the progression of atrophic and sclerotic changes in the liver. This process is also facilitated by blood shunting, which develops with sclerosis of the walls and obturation of the lumen of many central and collecting veins, as well as increasing stagnation of lymph - this is how congestive fibrosis (sclerosis) of the liver is formed.

With the progressive development of connective tissue, it appears incompletereeneration of hepatocytes with the formation of regenerate nodes, reorganization and deformation of the organ. Congestive (muscat) cirrhosis of the liver develops, which is also called cardiac, because it usually occurs in chronic heart failure.

Two types of changes occur in the lungs with chronic venous congestion - multiple hemorrhages, which cause hemosiderosis of the lungs, and the development of connective tissue, that is, sclerosis. The lungs become large, brown and dense - brown induration (induration) of the lungs.

In the morphogenesis of the brown compaction of the lungs, a significant role is played by stagnant full blood and hypertension in the small circle of blood circulation, which cause hypoxia and increased vascular permeability, edema, diapedesis hemorrhages. The development of such changes is preceded by adaptive processes in the vascular bed of the lungs. Hypertrophy of the muscle-elastic structures of the small branches of the pulmonary vein and artery occurs in response to hypertension in the small circle of blood circulation, with a reorganization of the vessels according to the type of closing arteries, which protect the capillaries of the lungs from sudden overflow of blood.

After some time of adaptive changes in blood vessels, the lungs become sclerotic, decompensation of the pulmonary blood circulation develops, the capillaries



of the interalveolar septa are filled with blood. Hypoxia of the tissue increases, in connection with which vascular permeability increases, multiple diapedesis hemorrhages occur. Accumulations of hemosiderin-loaded cells - sideroblasts and siderophages and free-lying hemosiderin appear in the alveoli, bronchi, interalveolar septa, lymphatic vessels and nodes; diffuse hemosiderosis of the lungs occurs. Hemosiderin and plasma proteins (fibrin) "clog" the stroma and lymphatic drainage of the lungs, which causes resorptive failure of the lymphatic system, which is replaced by a mechanical one. Sclerosis of blood vessels and insufficiency of the lymphatic system increase pulmonary hypoxia, which causes the proliferation of fibroblasts, thickening of interalveolar partitions. This is how a capillary-parenchymal block occurs, which closes a vicious circle in the morphogenesis of lung induration - congestive sclerosis of the lungs develops. It is more significant in the lower parts of the lungs, where venous congestion is more pronounced and there are more accumulations of blood pigments, fibrin. Pneumosclerosis, like hemosiderosis, with brown compaction of the lungs has a caudoapical distribution and depends on the degree and duration of venous congestion in the lungs.

Kidneys with chronic venous stasis become enlarged, dense and cyanotic - cyanotic induration of the kidneys; especially full-blooded veins of the brain substance and border zone. Lymphostasis develops against the background of venous stasis. In conditions of increasing hypoxia, nephrocyte dystrophy of the main parts of the nephron and sclerosis occur, which is not sharply expressed.

Chronic venous congestion in the spleen also leads to its cyanosis and induration. It is enlarged, dense, dark cherry in color; follicle atrophy and pulp sclerosis are determined. With general chronic venous stasis, cyanotic induration is characteristic of other organs as well.

*Local venous congestion* (hyperemia) is observed when the outflow of venous blood from one or another organ or part of the body is obstructed due to the closure of the lumen of the vein (thrombus or embolus) or its compression from the outside (tumor developed by connective tissue). Thus, acute venous hyperemia of the gastrointestinal tract develops with thrombosis of the portal vein. Nutmeg liver and

nutmeg cirrhosis are found not only with general venous congestion, but also with inflammation of the hepatic veins and their thrombosis (obliterating thrombophlebitis of the hepatic veins), which is characteristic of the disease (syndrome) of Budd - Chiari. Thrombosis of the renal veins can be the cause of cyanotic induration of the kidneys. Vein thrombosis also leads to venous stasis and swelling of the limb, if the collateral blood circulation is insufficient.

Local venous hyperemia can also occur as a result of the development of venous collaterals in the case of obstruction or cessation of blood flow through the main venous lines (portocaval anastomoses when blood flow is impaired through the portal vein). Collateral veins overflowing with blood expand sharply, and their wall becomes thin, which can cause hemorrhages (from dilated and thinned veins of the esophagus in cirrhosis of the liver).

Venous hyperemia is associated with the occurrence of not only plasmorrhagic, dystrophic, atrophic and sclerotic changes, but also venous (congestive) infarctions.

### **Anemia**

*Anemia* (ischemia) is a decrease in blood supply to a tissue, organ, or part of the body as a result of reduced blood flow. We are talking about both insufficient blood supply and complete cessation of blood flow.

Tissue changes that occur with anemia are associated with hypoxia or anoxia (oxygen starvation). Depending on the cause that leads to ischemia, the time of its occurrence, the duration of hypoxia, the degree of tissue sensitivity to it, with ischemia, there are either subtle changes at the level of ultrastructures, or gross destructive changes that can even lead to ischemic necrosis - a heart attack .

With acute anemia, dystrophic and necrobiotic changes occur. Their precursors are histochemical and ultrastructural changes: disappearance from the tissue glycogen, reduction of activity of redox enzymes and destruction of mitochondria. Based on the data of electron-histochemical study of tissue changes in acute ischemia and infarction, acute ischemia should be considered as a pre-necrotic (pre-infarction) condition. With long-term anemia, atrophy of parenchymal elements and sclerosis

develops as a result of increased collagen-synthesizing activity of fibroblasts.

Depending on the causes and conditions of occurrence, anemia is divided into the following types: angiospastic, obturation, compression, due to redistribution of blood.

*Angiospastic anemia* occurs as a result of spasm of the artery in connection with the influence of various irritants. Yes, a painful stimulus causes spasm of arteries and anemia in some parts of the body. The same mechanism of action of vasoconstrictor drugs (adrenaline). Angiospastic ischemia also occurs with negative emotional affects ("angiospasm of unreacted emotions").

*Obstructive anemia* develops as a result of thrombosis or embolism, with growth of connective tissue in the lumen of the artery, inflammation of its wall (obliterating endarteritis), narrowing of the lumen of the artery by atherosclerotic plaque. Obstructive ischemia due to thrombosis of an artery often completes angiospasm, and, conversely, angiospasm complements the obturation of an artery with a thrombus or embolus.

*Compression anemia* appears when an artery is compressed by a tumor, tourniquet, or ligature.

*Ischemia due to redistribution of blood* observed in cases of hyperemia after anemia. Such is, for example, ischemia of the brain during the release of fluid from the abdominal cavity, where a significant amount of blood flows. The meaning and consequences of anemia are different; depend on the specifics of the cause and the duration of its influence. Thus, anemia due to spasm of arteries is short-lived, and it does not cause any special disorders. However, with prolonged (long-term) spasms, the development of dystrophic changes and even ischemic necrosis (heart attack) is possible. Acute obstructive ischemia is especially dangerous because it often leads to the development of a heart attack. If the artery closes gradually, then blood circulation can be restored with the help of collaterals and the consequences of such ischemia can be insignificant. However, long-term anemia sooner or later ends with tissue atrophy and sclerosis.

**Bleeding** (hemorrhage) is the exit of blood from the lumen of a blood vessel

or heart cavity, into the environment (external bleeding) or into body cavities (internal bleeding). Examples of external bleeding can be hemoptysis (haemoptoa), nosebleeds (epistaxis), vomiting blood (haemotenesis), the appearance of blood in the stool (melaena), bleeding from the uterus (metrorrhagia). With internal bleeding, blood can accumulate in the pericardial cavity (hemopericardium), pleura (hemothorax), abdominal cavity (hemoperitoneum). If blood accumulates in the tissues during bleeding, it is called hemorrhage. It follows that hemorrhage is one of the types of bleeding. Accumulation of coagulated blood in a tissue with a violation of its integrity is called a hematoma, and when tissue elements are stored, it is called a hemorrhagic impregnation (hemorrhagic infiltration).

Flat hemorrhages in the skin and mucous membranes are called bruises, and small point-like hemorrhages are called petechiae or ecchymoses.

The causes of bleeding (hemorrhages) can be rupture, erosion and increased permeability of the vessel (heart) wall. Bleeding as a result of a rupture of the wall of the heart or blood vessel occurs when the wall is wounded, injured, or develops such pathological processes as necrosis (infarction), inflammation, or sclerosis.

Rupture of the heart and bleeding most often causes necrosis (heart attack). Supravulvular rupture of the aorta is the result of necrosis of its middle layer (medionecrosis), inflammation of the middle layer of the aorta (mesaortitis) with transition to sclerosis in syphilis can also lead to rupture of the aortic wall and bleeding. Ruptures of aneurysms of the heart, aorta, brain arteries, pulmonary artery and vessels of other organs are quite common, causing fatal bleeding.

Bleeding when the organ capsule ruptures due to the development of pathological processes in them should be included in the same category.

*Bleeding due to erosion of the vessel wall (erosive bleeding)* occurs in many pathological processes, but more often in inflammation, necrosis and malignant tumor. Such erosive bleeding occurs when the vessel wall is eroded by proteolytic enzymes in the center of purulent inflammation (with purulent appendicitis), gastric juice – at the bottom of a stomach ulcer, caseous necrosis (in the wall of a tuberculous cavity), when a cancerous tumor is ulcerated (ulcerative cancer of the rectum,

stomach, mammary gland). Erosive bleeding also develops during ectopic (tubal) pregnancy, when the chorionic villi sprout and erode the wall of the fallopian tube and its vessels. Bleeding due to increased permeability of the vessel wall, diapedesis bleeding, occurs from arterioles, capillaries and venules for various reasons. Angioneurotic disorders, changes in microcirculation, and tissue hypoxia occupy a significant place among them. Therefore, diapedesis hemorrhages are quite common with brain damage, arterial hypertension, systemic vasculitis, infectious and infectious-allergic diseases, diseases of the blood system (hemoblastosis and anemia), coagulopathy. When diapedesis hemorrhages become systemic, they become a manifestation of hemorrhagic syndrome.

The consequences of bleeding (hemorrhages) can be various: resorption of blood, formation of cysts at the site of hemorrhages (brain), encapsulation or germination of the hematoma by connective tissue, attachment of infection and suppuration.

The value of bleeding is determined by its type and cause, the amount lost of blood, the rate of blood loss. Rupture of the heart, aorta and its aneurysm leads to rapid loss of a significant amount of blood; in most cases - to death (death from rapid bleeding). Bleeding for several days can also lead to significant blood loss and death (death from acute anemia). Long-term, periodically recurring bleeding (with peptic ulcer disease of the stomach and duodenum, hemorrhoids) can cause chronic anemia (posthemorrhagic anemia). The importance of hemorrhage for the body largely depends on localization. Hemorrhage in the brain (a manifestation of hemorrhagic stroke in hypertensive disease, rupture of a brain artery aneurysm) is especially dangerous, often fatal. Hemorrhage in the lungs is often fatal when a pulmonary artery aneurysm ruptures, erosion of a vessel in the tubercular cavern wall, etc. At the same time, massive hemorrhages in the subcutaneous fatty tissue, muscles often do not threaten a person's life.

**Plasmarrhagia** is the exit of plasma outside the blood vessel. The consequence of plasmarrhagia is the impregnation of blood plasma of the vessel wall and the tissues surrounding it - plasma impregnation; this is one of the manifestations of

impaired vascular permeability, which normally provides transcapillary exchange.

The mechanism of the development of plasmorrhagia and plasmatic percolation is determined by two main conditions - damage to the vessels of the microcirculatory bed by changes in blood constants that contribute to increased vascular percolation.

Damage to microvessels is associated with neurovascular disorders (spasms), tissue hypoxia, and immunopathological reactions. Changes in the blood contribute to plasmorrhagia and are due to an increase in the plasma content of vasoactive substances (histamine, serotonin), natural anticoagulants (heparin, fibrinolysin), coarsely dispersed proteins, lipoproteins, the appearance of immune complexes, and a violation of rheological properties. Plasmorrhagia is often found in hypertension, atherosclerosis, decompensated heart defects, infectious, infectious-allergic and autoimmune diseases.

Consequences: fibrinoid necrosis and hyalinosis of vessels

The meaning of plasmorrhagia lies in the violation of transcapillary exchange with a consequent change in the structure of organs and tissues.

**Stasis**—it is a stoppage of blood flow in a vessel of the microcirculatory channel (mainly in capillaries). Stoppage of blood flow begins slowly, which is defined as a prestatic state, or prestasis.

The main properties of the sludge phenomenon are the sticking together of erythrocytes, leukocytes or platelets; at the same time, plasma viscosity increases, which causes difficulty in blood perfusion through the vessels of the microcirculatory channel. Sludge phenomenon (syndrome) is one of the varieties of stasis.

**Mechanism of development.** The main importance in the occurrence of stasis is given to changes in rheological properties of blood as a manifestation of increased intracapillary aggregation of erythrocytes, which leads to an increase in resistance to blood flow through capillaries, its slowing down and complete stoppage. Hemolysis and blood coagulation do not occur during stasis. The development of intracapillary erythrocyte aggregation is facilitated by: changes in capillaries with increased permeability of their walls, i.e. plasmorrhagia; violation of the physical and chemical properties of erythrocytes, in particular, a decrease in their surface potential; changes

in the composition of blood proteins due to an increase in coarse fractions; dyscirculatory disorders – venous congestion (congestive stasis) or ischemia (ischemic stasis) and disruption of innervation of the microcirculatory channel.

The cause of stasis is often dyscirculatory disorders of blood circulation. They develop due to the influence of physical (high temperature, cold) and chemical (acids, alkalis) factors; occur with infectious (malaria, typhus), infectious-allergic and autoimmune (rheumatic diseases) diseases, diseases of the heart and blood vessels (heart defects, coronary heart disease).

The value of stasis depends not only on the duration, but also on the sensitivity of the organ or tissue to oxygen starvation (brain). Stasis is the opposite phenomenon; the state of vessels after the end of stasis is called poststatic; irreversible stasis ends with necrobiosis and tissue necrosis.

**Shock** is an acute pathological process caused by actionan overpowering stimulus characterized by disruption of the activity of the central nervous system, metabolism and autoregulation of the microcirculatory system, which leads to destructive changes in organs and tissues.

The basis of the shock of various origins is a single complex multiphase mechanism of development. The early period of shock is characterized by relatively specific signs, which are due to the peculiarities of etiology and pathogenesis.

Depending on the cause, the following types of shock are distinguished: 1) hypovolemic, which occurs with a sharp decrease in the volume of circulating blood (or liquid); 2) traumatic, the trigger of which is excessive afferent (mainly painful) impulse; 3) cardiogenic, which arises as a result of a rapid decline in the contractile function of the myocardium and an increase in the flow of afferent (mainly "hypoxic") impulses; 4) septic (toxic-infectious), the cause of which is endogenous intoxication by pathogenic microflora.

In the late period of shock, the relative specificity of signs due to the peculiarities of its etiology and pathogenesis disappears, and the clinical and anatomical manifestations become stereotyped.

Morphological changes of shock are characterized by hemocoagulation

disorders in the form of DVZ-syndrome, hemorrhagic diathesis, liquid cadaveric blood, which can be the basis of the diagnosis of shock at the autopsy of the deceased. During a microscopic examination of hemodynamic and rheological properties of blood, widespread spasm of blood vessels, microthrombi in the microcirculation system, signs of increased permeability of capillaries, and hemorrhages are found.

Internal organs develop a number of general changes in the form of dystrophy and necrosis, which is caused by a violation of hemodynamics, hypoxia, the damaging effect of biogenic amines, endotoxins of pathogenic microflora. The severity of these changes largely determines the possibility of reversibility of the shock.

Morphological changes during shock have a number of features due to structural and functional specialization of the organ, as well as the advantage in the pathogenesis of shock of one of its chains (neuroreflex, hypoxic, toxic). Based on this, the term "shock organ" is used when characterizing shock.

Necrotic nephrosis develops in a shocked kidney (sometimes there are symmetrical cortical necrosis of the kidneys), which causes acute renal failure. In a shock liver, hepatocytes lose glycogen, undergo hydropic dystrophy, develop centrilobular necrosis of the liver, and show signs of structural and functional insufficiency of stellate reticuloendotheliocytes. Such morphological changes determine the possibility of developing acute liver failure in shock. A combination of kidney and liver failure is often observed; in such cases, they speak of hepatorenal syndrome.

Shock lung is characterized by the appearance of atelectasis centers, serous-hemorrhagic edema with fibrin falling into the alveoli, hemostasis and the formation of blood clots in the microcirculatory channel, which causes the development of acute respiratory failure.

Structural changes of the myocardium during shock are represented by dystrophic and necrotic changes in cardiomyocytes: the disappearance of glycogen, the appearance of lipids and myofibril contractures. The appearance of



small centers of necrosis is possible.

Structural damage during shock is found not only in shock organs, but also in the gastrointestinal tract, nervous, endocrine and immune systems.

### **Thrombosis**

Thrombosis is a lifelong coagulation of blood in the lumen of blood vessels or heart cavities. The clot formed in this case is called a thrombus.

*Stages of thrombosis:* 1) formation of prothrombinase; 2) formation of thrombin; 3) formation of fibrin.

In addition to the coagulation system, there is also an anticoagulation system, which ensures a normal liquid state of the blood. Thus, thrombosis is a manifestation of dysregulation of hemostasis systems (coagulation and anticoagulation).

*Conditions for the development of a thrombus:* 1) damage to the vascular wall (rupture, inflammation, spasms of arteries and arterioles); 2) slowing of blood flow (cardiovascular insufficiency); 3) violation of regulation of coagulation and anti-coagulation systems; 4) violation of blood composition (increase in fractions of coarsely dispersed proteins (fibrinogen), lipoproteins, lipids, platelets). Such changes are often observed in atherosclerosis, autoimmune diseases, and blood tumors.

*Features of a thrombus:* 1) the thrombus attaches to the vessel wall at the site of its damage (that is, where the process of thrombus formation began); 2) the thrombus has a corrugated surface (due to layering of platelets and fibrin); 3) the consistency of the thrombus is dense, dry, fragile.

*Types of blood clots by structure and appearance:* 1) White (consists of platelets, fibrin and leukocytes). It is formed more often in arteries, slowly, with fast blood flow. 2) Red (contains platelets, fibrin and erythrocytes). It forms more often in the veins, slowly, with slow blood flow. 3) Mixed (contains elements of both white and red blood clots, has a layered structure). It distinguishes the head (white thrombus structure), body (mixed thrombus) and tail (red thrombus). Such thrombi are more often found in veins, in the cavities of aneurysms of the aorta and heart. 4) Hyaline (does not contain fibrin, consists of destroyed erythrocytes, platelets and precipitated plasma proteins, resembles hyaline from the outside). It occurs more often in the

vessels of the microcirculatory channel.

Thrombi can be paramural (most of the lumen of the vessel remains free) and occluding (obstructive). Mural thrombus is more common on heart valves, endocardium, auricles, large arteries with atherosclerosis and large veins with thrombophlebitis, aneurysms of the heart and blood vessels. The obturator is formed more often in veins and small arteries with the growth of a wall thrombus, less often in large arteries and the aorta.

Thrombosis is the leading triggering factor of DVZ-syndrome and thromboembolic syndrome.

Consequences of thrombosis: 1) aseptic autolysis of a thrombus (under the influence of proteolytic enzymes of leukocytes); 2) organization, canalization and vascularization of the thrombus (ingrowth of connective tissue into the thrombus with the subsequent appearance of slits and channels lined with endothelium that contain blood); 3) calcification of the thrombus (sometimes stones are formed - phlebolites); 4) detachment of a thrombus and its transformation into a thromboembolism, which is the source of thromboembolism; 5) purulent melting (when purulent bacteria hit thrombotic masses). Can be observed with sepsis; 6) strengthening of the aneurysm wall of the heart and large vessels (for example, in case of myocardial infarction); 7) obturating blood clots lead to the development of a heart attack or gangrene, portal hypertension syndrome (with blockage of the portal vein), splenomegaly (blockage of the splenic vein), etc.

**Embolism**- this is the circulation in the blood or lymph of particles that do not occur normally, with their subsequent clogging of blood vessels. These particles are called emboli. Emboli are more likely to move with the blood flow: 1) from the venous system of the large circulatory circle and the right part of the heart to the vessels of the small circulatory circle (that is, emboli of the veins of the lower extremities can migrate to the pulmonary vessels); 2) from the left half of the heart, aorta and large arteries in the arteries of the heart, brain, kidneys, spleen, limbs, etc. (that is, along the course of the great circle of blood circulation); 3) from the branches of the portal system of the liver to the portal system.

Sometimes the embolus, due to its weight, moves retrogradely: it descends from the vena cava into the renal, splenic veins, etc.

In the presence of defects of the interatrial and interventricular membrane, emboli, bypassing the lungs, fall from the small circle of blood circulation into the large one (paradoxical embolism). Paradoxical embolism can also include microembolism due to arteriovenous anastomoses.

Types of emboli depending on the nature of emboli: thromboembolism occurs when a thrombus or part of it breaks off. If emboli become thrombi of the veins of a large blood circulation, thromboembolism of the pulmonary artery occurs, which leads to death (if large branches are blocked) or hemorrhagic lung infarction (if small branches are blocked). If thrombi of heart valves, aorta or large arteries become emboli, then organ infarctions develop. Fat embolism. The source of embolism is drops of fat (body fat). It develops with traumatic crushing of adipose tissue, bone marrow (fractures of tubular bones), injection of oil solutions. Death occurs when brain vessels are blocked by emboli. Air embolism. Occurs when air is injected into the bloodstream (in case of injury to the veins of the neck, rupture of the veins of the uterus after childbirth due to negative pressure in them, during open heart surgery, applying a pneumothorax, accidentally injecting air into a vein along with medications). Air bubbles cause embolism of small blood vessels and sudden death. Gas embolism. Clogging of blood vessels with gas bubbles. This embolism occurs in cases of rapid transition from high pressure to normal (caisson disease in divers, caisson workers). Gas emboli clog the capillaries of the brain and spinal cord, liver, kidneys and other organs, which is accompanied by the appearance of foci of ischemia and necrosis in them. Tissue (cellular) embolism. It develops when tissues are destroyed in connection with an injury or a pathological process, which lead to the impact of pieces of tissues (or cells) into the blood. Emboli can be tumor tissue (in case of decay or metastasis), brain tissue (in the case of a head injury), amniotic fluid in the perineum, etc. Microbial embolism. It develops in those cases when microbes circulate in the blood and obstruct the lumen of the capillaries. At the same time, metastatic abscesses develop at the site of vessel blockage with microbial

emboli. Embolism by foreign objects. It is observed when fragments of shells, mines, bullets and other bodies hit the lumen of large vessels. Because foreign objects are heavy, they often travel retrograde. This embolism also includes embolism with lime and cholesterol crystals of atherosclerotic plaques, which crumble into the lumen of the vessel during their ulceration. Embolism by foreign objects. It is observed when fragments of shells, mines, bullets and other bodies hit the lumen of large vessels. Because foreign objects are heavy, they often travel retrograde. This embolism also includes embolism with lime and cholesterol crystals of atherosclerotic plaques, which crumble into the lumen of the vessel during their ulceration. Embolism by foreign objects. It is observed when fragments of shells, mines, bullets and other bodies hit the lumen of large vessels. Because foreign objects are heavy, they often travel retrograde. This embolism also includes embolism with lime and cholesterol crystals of atherosclerotic plaques, which crumble into the lumen of the vessel during their ulceration.

**Disseminated intravascular coagulation syndrome**(DVZ-syndrome) is a generalized coagulation of blood in the middle of the vessels, which causes the formation of a large number of microclots and aggregates of cells that disrupt microcirculation in organs and tissues. This syndrome is often described as a catastrophe for the body.

Depending on the causes of development, the following varieties of DVZ-syndrome are distinguished:

- 1) infectious-septic (develops with sepsis); 2) post-traumatic (with crash syndrome, burn disease, multiple bone fractures);
- 3) shockogenic (with all types of shock); 4) surgical (after operations with extensive tissue trauma); 5) obstetric (with premature detachment of the placenta, inflow of amniotic fluid into the blood); 6) toxicogenic (with malignant tumor growth); 7) tumor (with immune tissue damage) and others.

The pathogenesis of DVZ-syndrome is based on the so-called "humoral protease explosion", that is, the simultaneous activation of all proteolytic enzymes of the blood plasma, which are part of four extracellular biochemical systems: a)

coagulation system; b) fibrinolytic system; c) kallikrein-kinin system; d) complement systems.

The main principle of activation of extracellular proteases is the cleavage of peptides that close their active center.

Sources of active proteases entering the blood in DVZ-syndrome:

1) damaged cells. Acute damage to a large number of cells from which lysosomal proteases and tissue thromboplastin enter the extracellular space and blood is important. Inflammation, as a local process that occurs when a cell is damaged, limits the entry of decay products into the blood, thus localizing the damage and preventing the development of DVZ-syndrome; 2) entry into the blood of a large amount of extracellular proteases, for example, trypsin in acute pancreatitis, enzymes that are in the amniotic fluid; 3) exogenous proteases. Their sources can be bacterial cells in sepsis, snake venom, etc.

Two phases are distinguished in the pathogenesis of DVZ-syndrome: 1) The phase of hypercoagulation and aggregation of platelets. The basis of this phase is the generalized activation of the blood coagulation system, that is, the formation of thrombin (thrombinemia), which leads to the formation of fibrin and platelet aggregates. Clinical manifestations of the syndrome in the 1st phase: hypoxia, acidosis, intoxication by decomposition products, acute respiratory failure (microclots clog the capillaries of the lungs), acute renal failure (clogged glomerular capillaries), impaired cerebral circulation. 2) Phase of hypocoagulation (hemorrhagic syndrome). This phase develops as a result of exhaustion of the mechanisms of vascular-platelet and coagulation hemostasis. This phase is clinically manifested by heavy bleeding that is difficult to stop.

**Violation of lymphatic circulation** is a condition in which the lymphatic vessels do not perform their main function - the implementation of constant and effective drainage of the interstitium.

The following forms of lymphatic circulation disorders are distinguished: 1) Mechanical insufficiency. It is manifested by the obstruction of lymph outflow in connection with the presence of organic (compression by a tumor, scar, obliteration of

lymphatic vessels during their inflammation, thrombosis, etc.) or functional causes (increased pressure in the main venous vessels, spasm of lymphatic vessels, cessation of muscle contractions and etc.); 2) dynamic insufficiency. It occurs when the volume of transudation of interstitial fluid exceeds the ability of the lymphatic system to provide effective drainage of interstitial tissue;

3) resorptive insufficiency. It is caused by structural changes at the border of the exact tissue, the accumulation of proteins and the deposition of their pathological species in the interstitium.

The main manifestations of insufficiency of lymphatic circulation in the acute stage are edema, the accumulation of proteins and their breakdown products in the boundary of the fine tissue, and in the chronic stage - the development of fibrosis and sclerosis.

### **Violation of tissue fluid content**

The content of tissue fluid depends primarily on the state of blood and lymph circulation and the level of vascular and tissue permeability. It is also determined by the state of the blood and lymph, cells and intercellular substance, where tissue fluid accumulates. The content of tissue fluid is regulated by neurohumoral mechanisms, and aldosterone and antidiuretic hormone of the pituitary gland occupy a significant place.

The tissue fluid is poor in proteins (up to 1%) and is bound in the cells with protein colloids, and in the connective tissue with proteins and glycosaminoglycans of the main substances. A significant mass of it is in the intercellular substance. Violation of the content of tissue fluid can fluctuate in the direction of increase or decrease.

An increase in the content of tissue fluid leads to the development of edema or dropsy. At the same time, edema fluid, or transudate, accumulates in tissues or in body cavities. This transparent liquid contains no more than 2% protein and does not bind well to protein colloids. The accumulation of edematous fluid in the subcutaneous tissue is called anasarca; in the heart cavity – hydropericardium, in the pleural cavity – hydrothorax, in the abdominal cavity – ascites, in the vaginal cavity of the testicle – hydrocele.

Depending on the disease, this or that pathological process, which can be the cause of edema, the following types of edema are distinguished: congestive, cardiac, renal, dystrophic, marantic (cachectic), inflammatory, allergic, toxic, neurotic, traumatic.

Congestive edema occurs with phlebothrombosis, thrombophlebitis, compression of veins, with lymphostasis; usually have a limited, local character. They are caused by chronic venous stasis, which causes an increase in pressure in the veins, hypoxia of tissues with successive damage to the endothelium and basal membranes of capillaries, increased permeability and transudation of the liquid part of the blood into the tissue. The weakening of the function of the lymphatic system contributes to the increase in edema.

Cardiac edema is observed with decompensation of cardiac activity. The redistribution of blood that occurs at the same time leads to increased secretion of aldosterone and its insufficient destruction in the liver in conditions of decompensation. Aldosteronemia means sodium retention, which contributes to the growth of edema.

Both the oncotic factor and sodium retention are important in the development of renal edema, but their role in various kidney diseases is different. With nephrotic syndrome of any genesis, characterized by the loss of a significant amount of proteins in the urine (proteinuria) and their depletion of blood plasma (hypoproteinemia), the main role in the development of edema is the reduction of oncotic blood pressure. With glomerulonephritis, sodium retention and, to a lesser extent, oncotic pressure are of primary importance. Renal swellings appear first of all on the face - on the eyelids, under the eyes, then they spread to the hands and feet.

Dystrophic edema occurs due to insufficient protein content in food. Hypoproteinemia, which develops as a result, leads to a decrease in oncotic blood pressure. This also includes marantic (cachectic) edema. Inflammatory swellings are observed around the center of inflammation (the so-called perifocal swelling), they are due to increased permeability of capillary membranes. The mechanism of allergic, toxic, neurotic and traumatic swellings is the same.

Thus, swellings that occur for various reasons in various diseases and pathological processes often have common mechanisms.

The consequences of edema in many cases can be favorable - the edema fluid is absorbed. With long-term swelling in the tissues, hypoxia develops, which leads to dystrophy and atrophy of parenchymal cells and the development of sclerosis.

The value of edema depends on the cause, localization, and distribution.

Allergic edema quickly disappears; cardiac and renal—long, and from them the consequence of the disease depends on its presence. Edemas of the brain or lungs are often the cause of death; dropsy of the cavities leads to a violation of the vital activity of the organs.

Inflammation often occurs in swollen tissues, which is associated with trophic disorders or autoinfection. Transudate in body cavities for the same reason can become the basis for the formation of fluid of an inflammatory nature, that is, turn into exudate (for example, the development of peritonitis against the background of ascites - ascites-peritonitis).

A decrease in the content of tissue fluid is called dehydration, or exicosis, which is accompanied by blood loss of water, that is, anhydremia.

The appearance of a person with exicosis is quite characteristic: pointed nose, sunken eyes, cheeks, wrinkled skin, severe weight loss. At the same time, the blood becomes thick and dark, the surface of the serous membranes is dry or covered with a viscous mass. Organs are reduced, their capsule becomes wrinkled. Exycosis develops under conditions of rapid loss of a large amount of fluid, which is characteristic of cholera, prolonged diarrhea, dyspepsia. Sometimes dehydration is observed in comatose states, for example, in encephalitis.

**Materials on the activation of students of higher education during the lecture: questions, situational tasks, etc(*if necessary*):**

The autopsy of the deceased, who had heart disease, revealed an enlarged liver of a variegated appearance, with a pattern of nutmeg on the cut. Name the type of blood circulation disorder:

AND General venous complete blood



B Hemorrhage

Bleeding

D General arterial complete blood

Anemia

A young man suddenly died during an emotionally stressful job. An autopsy revealed uneven blood filling of the myocardium. Histochemically: decrease in glycogen content. Electron microscopic: destruction of mitochondria, contractures of myofibrils. Specify the probable circulatory disorder?:

AND Acute ischemia

B Acute venous hyperemia

Angioneurotic arterial hyperemia

Chronic ischemia

Vacant arterial hyperemia

In a sick person, 25 years after the formation of a thrombus in the main arterial trunk, signs of hyperemia of synergist arteries appeared. What is hyperemia?:

AND collateral

B Angioneurotic

Hyperemia after anemia

D Vacant

E Inflammatory

At the autopsy of a 30-year-old man with aortic valve insufficiency due to rheumatism, a wedge-shaped area of dense consistency, dark red color, with clear borders was found in the lungs. The base of the wedge is located subpleural, the top is directed to the root of the lungs. What pathological process developed in the lungs?:

AND Hemorrhagic heart attack

B Hematoma

C Hemothorax

Abscess

Ischemic heart attack

The deceased man, 30 years old, who suffered from decompensated heart disease for a long time, had an enlarged, dense liver, with rounded edges, the surface of the section was variegated with dark red spots. What is the name of such a liver?:

AND Nutmeg liver

B Shock liver

C More variegated liver

D Toxic liver

E Toxic liver

At the autopsy of the deceased patient, multiple hemorrhages, hemosiderosis and growth of connective tissue were found in the lungs. The lungs are enlarged, brown and dense. What process leads to these changes?:

AND Chronic venous stasis

B Pulmonary infarction

Silicosis of the lungs

D Gangrene of the lungs

E Atrophy

Short-term angiospasm led to the development of thrombosis. Dystrophic and necrobiotic changes occurred in the blood supply zone. What is this anemia called?:

AND Angiospastic

B Compensatory

Chronic anemia

D Parenchymatous

E Result of redistribution of blood

At the autopsy of a 30-year-old woman who died suddenly, blood was found in the pericardial cavity. What is this process called?:

AND Hemopericardium

B Hemorrhagic infiltration

C Synets

D Hematoma

E Hemothorax

### **General material and bulk-methodological support of the lecture:**

#### **Questions for self-control:**

1. Classification of circulatory disorders.
2. Types of blood circulation disorders associated with damage to the vascular wall permeability: bleeding, hemorrhage, plasmorrhagia, edema. General definition and characteristics, causes of development, clinical significance.
3. Bleeding. Definition, classification, morphological characteristics of certain species, complications and consequences.
4. Bleeding. Definition, classification, morphological characteristics of certain species, complications and consequences.
5. Plasmorrhagia. Definition, morphological characteristics of the results.
6. edema. Definition, morphological characteristics of the results.
7. Types of circulatory disorders associated with circulatory disorders: arterial congestion, venous congestion, ischemia, shock. General definition and characteristics, causes of development, clinical significance.
8. Arterial hyperemia. Definition, classification, morphological characteristics of individual species, complications and consequences.
9. Venous hyperemia. Definition, classification, morphological characteristics of certain types, complications and consequences.
10. Ischemia. Definition, classification, morphological characteristics of certain species, complications and consequences.
11. Shock. Definition, classification, stages of development.
12. The concept of "impact organ" (shock kidney, shock lung), morphological characteristics, complications and consequences.
13. Classification of circulatory disorders, general characteristics and causes of

development. The concept of hemostasis.

14. Types of blood circulation disorders associated with blood flow disorders and condition: stasis, thrombosis, embolism, disseminated intravascular coagulation.

General definition and characteristics, causes of development.

15. Thrombosis. Definition, causes of development (general and local factors), morphological characteristic.

16. Thrombus. Types of blood clots, structure of different types of blood clots.

Comparative morphological characteristics of thrombus and postmortem deposition of thrombus.

17. Complications and consequences of thrombosis, clinical significance.

18. Embolism. Definition, classification, general morphological characteristics, complications and consequences.

19. Morphological characteristics of different types of embolism, conditions and causes of development, diagnostic features.

20. DVZ-syndrome. Definition, causes of development, stages of development. Morphological characteristics.

## References:

Main:

1. Atlas of micropreparations in pathomorphology / I.I. Starchenko, B.M. Filenko, N.V. Royko, etc.; VDZU "UMSA". - Poltava, 2018. - 190 p
2. Starchenko, S.O. Bilokon and others.. – Poltava: Tov. "ASMI" - 2018. - 190 p.
3. The basics of pathology according to Robbins: in 2 volumes. Volume 1 / Vinay Kumar, Abul K. Abbas, John C. Astaire; translation of the 10th Eng. edition. Publisher: All-Ukrainian specialized publishing house "Medytsyna". – X II. - 2019. - 420 p.
4. The basics of pathology according to Robbins: in 2 volumes. Volume 1 / Vinay Kumar, Abul K. Abbas, John C. Astaire; translation of the 10th Eng. edition. Publisher: All-Ukrainian specialized publishing house "Medytsyna". – X II. - 2019. - 420 p.
5. Pathomorphology. General pathomorphology: a study guide / edited by Ya. Ya. Bodnara, V.D. Voloshina, A.M. Romanyuk, V.V. Gargin. - New Book, 2020. - 248 p.
6. Pathomorphology of the main diseases of the cardiovascular system: study guide / I.I. Starchenko, B.M. Filenko, N.V. Royko – Poltava: "UMSA". - 2019. - 150 p.
7. I.I. Starchenko Pathomorphology of the main diseases of the maxillofacial region: academician. manual / I.I. Starchenko, B.M. Filenko, V.V. Chernyak ; "UMSA". – Vinnytsia: Nova Kniga, 2019. – 128 p.

8. Ctarchenko I.I. Special pathomorphology (basic course) for students of medical faculties of higher medical educational institutions of III-IV levels of accreditation / II Starchenko, N.V. Royko, B.M. Filenko. – Poltava, 2017. – 174 p.
9. Tuffaha S. A. Muin Immunohistochemistry in tumor diagnostics / S. A. Tuffaha Muin, S. G. Hychka, Gusky Hans. - "Book Plus", 2018. - 336 p.
10. Essentials of pathology: textbook / Ya. Bodnar, A. Romanyuk, V. Voloshyn, V. Gargin - Kharkiv, "Planeta-Print" Ltd, 2020, 219 p.
11. Pathology: textbook / IVSorokina, VD Markovskiy, DI Halata et al.; edited by IVSorokina, VD Markovskiy, DI Halata. - Kyiv: AUS Medicine Publishing, 2019. - 328p. + 2 color inserts (8p. + 12p.).
12. Pathology: textbook / IVSorokina, VD Markovskiy, DI Halata et al.; edited by IVSorokina, VD Markovskiy, DI Halata. - 2nd edition. - Kyiv: AUS Medicine Publishing, 2020. - 328p. + 2 color inserts (8p. + 12p.).

Additional:

1. Benign neoplasms of bones of the maxillofacial area in children / P.I. Tkachenko, I.I. Starenko, S.O. Bilokin [and others] - P.: "UMSA", 2016. - 85 p
2. General pathomorphology / I.I. Starchenko, N.V. Royko, B.M. Filenko [et al.] – Poltava, 2016. – 136 p.
3. Zerbino D. D. Pathomorphology and histology: an atlas / D. D. Zerbino, M. M. Bagrii, Y. Ya. Bodnar, V. A. Dibrova. – Vinnytsia: Nova Kniga, 2016. – 800 p.
4. Methods of morphological research / M.M. Baghrii, V.A. Dibrova, O.G. Papadynets, M.I. Grischuk; edited by M.M. Baghria, V.A. Dibrov – Vinnytsia: Nova Kniga, 2016. – 328 p.
5. Novoseltseva T.V. Pathology of sexual and endocrine systems / T.V. Novoseltseva, B.M. Filenko, N.I. Hasiuk - Poltava: LLC "ASMI", 2015. - 199 p.
6. Pathomorphology: national. / V.D. Markovskiy, V.O. Tumanskyi, I.V. Sorokina [and others]; edited by V.D. Markovsky, V.O. Tumanskyi. - K.: VSV "Medicine", 2015. - 936p.
7. Workshop on biopsy-sectioning course / I.I. Starchenko, A.P. Hasyuk, S.A. Proskurnya [etc.] – Poltava, 2016. – 160 p.

**Topic:** For the general doctrine of inflammation. Exudative inflammation. Morphology of exudative inflammation. Productive inflammation.

**Actuality of theme:** Today's topic is the general teaching about Zaplenience (lat. inflammatio) general and local reactions with a change in their chemistry, microcirculation disorders. Exudative inflammation. Morphology of exudative inflammation.

**Goal:** Familiarize yourself with the topic of "inflammation", its types, stages, and factors that provoke inflammation.

**Basic concepts:** Inflammation, acute inflammation, chronic inflammation, exudate (serous exudate, hemorrhagic exudate, catarrhal exudate, purulent exudate, fibrinous exudate: diphtheritic and croupous), transudate, phlegmon, abscess, boil, carbuncle, empyema, CRUP (true and false); interstitial inflammation, inflammatory infiltrate, polyp, condyloma, granuloma (tuberculous granuloma, Pirogov-Langhans cells, syphilitic granuloma, leprosy granuloma, Virchow cells, sclerotic granuloma, Mikulich cells).

### **Plan and organizational structure of the lecture:**

Greetings, verification of those present, announcement of the topic, purpose of the lesson, motivation of higher education seekers to study the topic.

### **Content of lecture material (lecture text)**

Inflammation is a complex vascular-mesenchymal reaction to damage caused by various agents.

Inflammation is a protective and adaptive reaction aimed at limiting the area of damage; destruction (neutralization) of agents that caused inflammation; restoration of damaged tissues (repair).

In addition to the positive, inflammation has negative sides: it can be accompanied by the melting of tissues with the formation of fistulas and scars; inflammation is the basis of many diseases.

Inflammation can be caused by various factors: 1) biological (exogenous and endogenous): a) microorganisms and products of their vital activity; b) immune factors: antibodies, immune complexes, sensitized lymphocytes, etc., 2) physical (radiation, electric current, high and low temperatures, trauma), 3) chemical (drugs, toxins, poisons).

It is not necessary that the external etiological factors directly themselves are the starting mechanism of the inflammatory reaction. A dystrophic or dead substrate biochemically irritates vascular nerves, disrupts the permeability of vascular walls, that is, increases inflammation. Denaturation products of the body's own tissues can be the cause of inflammation, so an inflammatory reaction occurs around heart attacks, bordering on gangrene. Such inflammation at the border between living and dead tissue is called demarcation.

Usually, the inflammatory reaction in a given person under the influence of a given stimulus is moderately pronounced, adequate to the strength of the etiological factor. When the action is weak, it is weak, when it is strong, it is strong. Such an inflammatory reaction is called normergic. The body may have increased sensitivity to the cause of inflammation of an allergic or antigenic nature. The resulting inflammatory reaction has a sharply expressed character and is called hyperergic. There are hypoergic and anergic reactions, which reflect reduced sensitivity and reactivity. This happens in old age, in premature newborns. Clinical signs of inflammation: fever, temperature, redness, etc. with an anergic reaction may be completely absent.

During inflammation, changes occur in the center of inflammation and in the adjacent lymph nodes. Adjacent lymph nodes increase in size and together with the center of inflammation form a primary inflammatory complex. Complexes are formed during human infectious diseases: tuberculosis, plague, syphilis, typhoid fever, etc. In childhood, the reaction of lymph nodes during inflammation is weak.

Inflammation consists of three phases: alteration, exudation and proliferation.

Alteration is represented by dystrophy and necrosis. This is the initial phase of inflammation, which leads to the release of mediators that determine the entire subsequent development of the inflammatory reaction.

The phenomenon of alteration, i.e. tissue damage, is accompanied by dystrophic changes, rejection of cells, their necrobiosis and necrosis. An alteration occurs both as a result of the direct action of a harmful agent on the tissue, and as a result of a disorder of blood circulation and innervation. Membranes are destroyed in

the cells, enzymes are released that autolyze the structures. Mucoïd and fibrinoid swelling and necrosis are observed in the connective tissue. Plasma and cellular mediators act in the area of damage

*Plasma mediators* provide an increase in vascular permeability, activate chemotaxis of polymorphonuclear leukocytes for phagocytosis, intravascular coagulation in the vessels departing from the center of inflammation to demarcate the pathogen and the center itself. They appear when the factors circulating in the blood are activated.

Plasma mediators are represented by the following systems: kallikrein-kinin system, complement system, blood coagulation system and fibrinolytic system.

The main mediators: Hageman factor, plasmin, fibrin degradation products (formed during fibrinolysis).

The Hageman factor is a connecting link between the complementary, kallikrein-kinin system and the coagulation-fibrinolytic systems. It activates the kinin system, "triggers" the internal coagulation system and the fibrinolytic system, which, in turn, includes the complement system.

*Cellular mediators* produced by various cells; are contained in the cell in a ready form (histamine, serotonin, lysosomal enzymes) or are formed during an inflammatory reaction. They provide: increased permeability of the vessel wall, chemotaxis, phagocytosis; activation of the immune response to eliminate the damaging agent; repair by proliferation and differentiation of cells in the center of inflammation.

The following groups of cellular mediators are distinguished: vasoactive amines (histamine, serotonin); products of arachidonic acid metabolism, lysosomal products (leukocytes, macrophages), platelet activation factor, cytokines.

**Exudation**- exit of the liquid part of the blood and formed elements outside the vascular bed. Initially, a reaction of the microcirculatory channel with a violation of the rheological properties of blood develops: short-term vasoconstriction; vasodilatation (arterioles, capillaries and post-capillaries) with the development of inflammatory hyperemia; slowing of blood flow and increase in blood viscosity,

stasis. In the future, the permeability of the microcirculatory channel increases: the appearance of pores between endothelial cells due to their contraction and expansion of vessels, as well as due to damage to the endothelium. The above promotes the release of fluid and plasma proteins: interendothelially through interendothelial pores; intraendothelially with increased pinocytosis in the endothelium.

Cell emigration (exit of cells from vessels) occurs mainly in postcapillaries and venules. Polymorphonuclear leukocytes (PLN) are the first to appear in the field of vision (after 10-15 minutes with stimuli of medium strength).

Stages of leukodiapedesis: marginalization (marginal standing); adhesion to the endothelium (with the help of adhesive molecules expressed on the surface of cells); emigration takes place interendothelially: leukocytes use pseudopodia to move interendothelial contacts and migrate between the endothelium and the basement membrane. Penetration of FAL through the basal membrane of the endothelium is associated with the phenomenon of thixotropy, which is based on the transition of the basal membrane from the state of gel to sol and vice versa. The movement of FAL toward the center of damage is carried out with the help of chemotactic factors.

Phagocytosis - absorption and digestion by cells (phagocytes) of various particles (living and dead bacteria and other pathogens, necrotic detritus, foreign bodies, etc.). The most important phagocytic cells are PAL and monocytes-macrophages.

Phagocytosis can be: complete; incomplete (microorganisms are not digested by phagocytes and multiply in their cytoplasm; incomplete phagocytosis causes chronic inflammation).

Exudate and inflammatory cellular infiltrate are formed.

Exudate is an inflammatory fluid containing protein (more than 2%) and cellular elements. When cells accumulate in tissues, they speak of an inflammatory cell infiltrate.

The composition of the cells of the infiltrate is different: in the first 6-24 hours, the exudate is dominated by PAL; in the period of 24-48 hours, monocytes-macrophages begin to dominate; in inflammation associated with immediate-type



hypersensitivity reactions, eosinophils predominate in the exudate.

Inflammation in the clinic is manifested by 5 classic signs: redness, swelling, pain, temperature rise and functional impairment. Redness - rubor, reflects hyperemia, expansion of all working and auxiliary blood vessels as a result of irritation of vasodilator nerves. At first, blood flow accelerates, and then slows down to peresstasis and stasis.

Tissue swelling - tumor - is an inflammatory infiltrate - an exit from blood vessels into the tissue of blood plasma and leukocytes mixed with local tissue cells. Thus, the infiltrate consists of histogenic and hematogenous elements.

Pain - dolor, associated with irritation of nerve endings in the area of the inflamed infiltrate. When the nerve endings die, the pain disappears, although the inflammation has not been eliminated

A local increase in temperature, fever - calor, is associated with the rapid course of metabolism and synthesis of substances, blood flow.

Disturbance of function - functio laesa - the damaged tissue works weaker.

All the listed phenomena are not the exclusive property of inflammation. They also occur normally, for example, the migration of leukocytes during digestion or facial hyperemia when a person feels ashamed.

**Proliferation**- the final phase of inflammation, which is characterized by:

1. Proliferation of proliferative cells in the center of inflammation: macrophages, cambial mesenchymal cells, smooth muscle cells (SMC), epithelium.

2. Cell differentiation and transformation: a macrophage can transform into an epithelioid and giant cell; B-lymphocyte - into a plasma cell; a cambial mesenchymal cell turns into a fibroblast.

Proliferation of cells in the center of inflammation with the appearance of a large number of fibroblasts is the basis for the restoration of damaged tissues.

Proliferation and differentiation of cellular elements in the center of inflammation are carried out with the help of cytokines and numerous growth factors.

Regulation of inflammation is carried out with the help of hormonal, nervous and immune factors. Hormones such as somatotropic hormone (STH) of the pituitary

gland, deoxycorticosterone, aldosterone, increase the inflammatory reaction (pro-inflammatory hormones), others - glucocorticoids and adrenocorticotrophic hormone (ACTH) of the pituitary gland, on the contrary, reduce it (anti-inflammatory hormones). Cholinergic substances, stimulating the release of inflammatory mediators, act like pro-inflammatory hormones, adrenergic substances, suppressing mediator activity, behave like anti-inflammatory hormones.

The biological essence of proliferation is the revival of dead structures - regeneration.

Depending on the course of inflammation, it can be acute, subacute and chronic.

**Exudative inflammation** - characterized by the predominance of exudation and the formation of exudate in tissues and body cavities.

The nature of the exudate depends on the state of vascular permeability and the depth of damage, which is determined by the type and intensity of the damaging factor.

Depending on the nature of the exudate, the following are distinguished: serous, fibrinous, purulent, hemorrhagic and mixed inflammation; a special type of inflammation can develop on the mucous membranes - catarrhal.

Serous, fibrinous and purulent are independent and main forms of inflammation. Hemorrhagic, catarrhal and ichorous (putrefactive) are not independent forms of inflammation.

*Serous* inflammation is characterized by the release of a watery exudate from the blood, with a low content of protein and cells.

Outwardly, this exudate is similar to stagnant liquid transudate, which appears, for example, in cardiac edema.

The transudate has a low specific gravity and contains no more than 1-2% protein. In the serous exudate there is more protein, up to 6-8%, the specific gravity is higher (1018-1020 p.o.), there are more cells.

If acetic acid is added to a test tube with serous exudate, the proteins coagulate, and a cloud is formed, like a haze from a cigarette. In the future, exudate accumulates

quickly, thus, serous inflammation proceeds acutely. Transudate accumulates slowly, slowly and increases in quantity only over time. However, the transudate dissolves without a trace, while after serous inflammation, connective tissue, adhesions develop on the basis of the remaining proteins. Connective tissue, collagen fibers arise in serous exudate with incredible ease. After peritonitis, pleuritis, pericarditis, patients often have adhesions, even complete obliteration of cavities. A distinctive feature is also the condition of the tissues themselves and the serous leaves of the cavities in which the liquid is contained. In case of inflammation, hyperemia, redness, small hemorrhages are determined, some tarnishing from protein layering. The cause of serous inflammation can be various factors: chemical, physical, biological. Serous inflammation can develop in the skin, serous sheets, mucous membranes and internal organs. In different tissues, this inflammation manifests itself differently. Serous skin inflammation is characterized by vascular reactions in the skin's own layer. Serous exudate accumulates between the collagen and elastic fibers of the skin under the epidermis and between the Malpighian and stratum corneum of the epidermis. Unable to destroy the stratum corneum, serous exudate accumulates under it, peels off the epidermis and forms blisters, vesicles. Serous inflammation of the skin develops with thermal or chemical burns in the I and especially in the II degree, when blisters appear on the damaged area of the skin between the stratum corneum and Malpighian layer, filled with a clear or slightly cloudy liquid due to abundant inflammatory exudation. Blisters are formed either immediately after the burn, or after 1-2 days. Serous inflammation in the serous sheets of the pleura, pericardium, peritoneum, and joints is accompanied by the accumulation of serous exudate in the corresponding cavity, because the exudate very easily penetrates through the serous sheets, which are covered with one layer of endothelium. Accumulation of exudate in serous cavities can reach large volumes - many liters. In this way, exudative serous pleurisy, peritonitis, pericarditis, etc. occur. Along with the presence of serous fluid in the cavities, there are signs of inflammation of the serous membranes in the form of hyperemia, edema, darkening, which is an important distinguishing feature of the corresponding dropsy - hydrothorax, ascites, hydropericardium. Serous inflammation

on the serous sheets occurs with rheumatism,

In the same way, serous inflammation can develop on the mucous membranes.

In internal organs, serous inflammation occurs quite often. This includes serous inflammation in the myocardium - serous myocarditis, in the lungs - serous pneumonia, in the kidneys - serous nephritis, and in the liver - serous hepatitis.

If serous inflammation is complicated by purulent inflammation in the skin, serous leaves, and mucous membranes, this does not happen in internal parenchymal organs.

Serous inflammation in internal organs always develops in the interstitial tissue of the organ, and as a rule has a diffuse character, covering the organ as a whole. It is usually acute, ends with resorption of serous fluid and recovery, or turns into productive inflammation.

Another independent type of exudative inflammation is fibrinous inflammation. Fibrinous inflammation is characterized by the release of exudate containing a large amount of coarsely dispersed proteins and fibrinogen, leukocytes and cells of necrotic tissue. Due to the content of fibrinogen and enzymes released from the necrotic tissue, hyaluronidase and thromboplastin, for example, the exudate coagulates immediately after leaving the vessels. If necrosis with fibrinous inflammation captures only the surface layers of the tissue, then the coagulated fibrin lies on the surface, it is easily removed without damaging the tissue. This subtype of fibrinous inflammation is called croupous inflammation. If the necrosis of the tissue is deep, the fibrinous exudate is released and coagulated in the depth of the tissue itself, often hyalinized with the formation of a tightly bound film. When you try to remove the films, bleeding and ulcers appear. This subtype of fibrinous inflammation is called diphtheritic inflammation.

The type of fibrinous inflammation (croupous or diphtheritic) depends not only on the depth of damage to the underlying tissue, but also on the nature of the epithelium. Where there is a multi-layered flat epithelium (oral cavity, pharynx, tonsils, epiglottis, esophagus, true vocal cords, cervix), films are firmly connected to the epithelium, although necrosis and fibrin shedding are sometimes limited to the

epithelial cover. This is explained by the fact that the multi-layered flat epithelium is closely connected with the underlying connective tissue and therefore "firmly holds" the films.

On mucous membranes covered with prismatic epithelium (upper respiratory tract, gastrointestinal tract, etc.), the connection between the epithelium and the underlying tissue is weak. The films formed here are easily separated together with the epithelium even with a deep loss of fibrin. Therefore, the clinical significance of fibrinous inflammation in the pharynx and trachea is ambiguous even with the same etiology. For example, with diphtheria on the tonsils, the films are tightly connected to the underlying tissues, and microorganisms multiplying under the films cause intoxication. At the same time, the films in the trachea are easily separated together with the epithelium and underlying tissue. Intoxication in these cases is insignificant, but there is another danger: films that are easily separated can be aspirated, cause a reflex spasm, irritate the surrounding tissues and be the cause of asphyxiation.

Scars appear at the site of deep ulcers that occur after the film is rejected.

*Purulent inflammation* -is characterized by the predominance in the exudate of PNLAL (preserved and those that have disintegrated).

The most common cause is pyogenic microorganisms (staphylococci, streptococci, gonococci, meningococci, *Pseudomonas aeruginosa*, etc.).

A characteristic morphological feature is histolysis - tissue melting by proteolytic enzymes of leukocytes (neutral proteases - collagenase, elastase, cathepsin and acid hydrolases).

Purulent inflammation can be limited (abscess) and diffuse (phlegmon), purulent inflammation in pre-existing cavities with accumulation of pus is called empyema.

An abscess is a focal purulent inflammation characterized by the formation of a cavity filled with pus. An abscess, or abscess, develops in those cases when tissue necrosis occurs in the center of inflammation, its impregnation with leukocytes and melting as a result of the proteolytic action of enzymes released from leukocytes upon their death. The resulting abscess is separated from the adjacent tissue by a shaft

of granulation tissue, rich in capillaries, through the walls of which increased emigration of leukocytes occurs, i.e., a shell is formed. This shell has a different structure. On the outside, it consists of connective tissue fibers that adhere to unchanged tissue, and on the inside, it is formed by granulation tissue and thickened pus, which is continuously renewed due to the release of leukocytes by the granulation tissue. The lining of an abscess that forms pus,

Abscesses can be single or numerous; the latter are often formed in organs with septicopyemia due to microbial embolism.

Scars form at the site of abscesses; in some cases, the abscess acquires a chronic course: a connective tissue capsule is formed around it, the inner layer of which is granulation tissue.

Phlegmon is diffuse (diffuse) purulent inflammation, in which purulent exudate spreads diffusely between tissue elements, permeating and delaminating tissues. It most often occurs in the subcutaneous tissue, in the area of the fascia, along the vascular and nerve trunks. Diffuse purulent inflammation can also occur in parenchymal organs, in soft meninges. Tissues with phlegmonous inflammation swell, seep with pus.

There is a distinction between soft and hard phlegmon. Soft phlegmon is characterized by the absence of necrosis cells in the tissue, hard phlegmon - by the presence of such cells that are not subject to purulent melting, as a result of which the tissue becomes very dense; dead tissue gradually separates.

*Hemorrhagic inflammation* characterized by the presence of a large number of erythrocytes in the exudate. Vascular permeability is of great importance in its development. Occurs with severe infectious diseases: plague, anthrax, flu, in the past – with natural smallpox.

*Purulent inflammation* occurs more often in wounds with extensive crushing of tissues. It is most often associated with anaerobic infection in combination with purulent microorganisms. Large foci of necrosis are characteristic.

*Catarrhal inflammation* occurs on mucous membranes. It is characterized by a large amount of exudate that flows from the surface. Exudate always contains mucus.

It can be serous, purulent and mucous. Occurs with infectious diseases of the upper respiratory tract, allergic conditions, etc.

The result is most often favorable - complete restoration of the mucous membrane; sometimes catarrhal inflammation can take on a chronic course, which is accompanied by remodeling of the mucous membrane and its atrophy or hypertrophy.

**Productive inflammation** characterized by the predominance of cell proliferation of hematogenous and histogenic origin. The causes of productive inflammation are different. It can be caused by biological (microorganisms, animal parasites), physical (radiation) and chemical (drugs) factors; arise as a result of the development of immunopathological processes (immune inflammation). Productive inflammation occurs in the case of persistence of the damaging agent in connection with an imperfect exudative reaction (often caused by defects of the CSF) or in connection with the special properties of the pathogen itself (resistance to the action of phagocytes - incomplete phagocytosis). It is accompanied by the appearance of limited or diffuse infiltrates consisting mainly of macrophages, lymphocytes, and plasma cells. Characteristic transformation of macrophages into epithelioid cells, and the latter have giant cells (foreign bodies or Pirogov-Langhans), as well as increased activity of fibroblasts. Mediators of productive inflammation arise when monocytes-macrophages interact with lymphocytes.

A frequent consequence of productive inflammation is sclerosis with the development of atrophy and shrinkage of organs with a violation of their structure - cirrhosis.

Types of productive inflammation: interstitial, granulomatous and inflammation with the formation of polyps and condylomas.

*Interstitial inflammation* occurs in the stroma of parenchymal organs - myocardium, liver, kidneys and lungs.

Consider, for example, interstitial myocarditis, which occurs in many infectious diseases (influenza, diphtheria, typhus, etc.).

In the stroma of the myocardium, an infiltrate is formed, consisting of macrophages, lymphocytes, plasma cells, single CSF, epithelioid cells, and

fibroblasts. Dystrophic, sometimes necrobiotic changes are expressed in cardiomyocytes. Newly formed collagen fibers are visible in the areas of infiltration.

The result is diffuse small-cell cardiosclerosis.

*Granulomatous inflammation* characterized by the formation of granulomas - cell nodules, the basis of which are monocytic phagocytes.

In the development of granulomatous inflammation, the stability of the causative agent (irritant) in relation to phagocytes is of crucial importance.

Positive value of granuloma: restriction (localization) of the causative agent when it is impossible to eliminate it.

Granuloma morphogenesis consists of 4 stages:

1. Accumulation of young monocytic phagocytes in the focus of tissue damage
2. Maturation of these cells into macrophages and formation of macrophage granuloma.
3. Maturation and transformation of monocytic phagocytes and macrophages into epithelioid cells and formation of epithelioid cell granuloma.
4. Fusion of epithelioid cells (or macrophages) with the formation of giant cells (foreign body cells or Pirogov–Langhans cells) and epithelioid-cell or giant-cell granuloma.

Giant cells are characterized by significant polymorphism: from 2-3 nuclei to giant symplasts containing 100 nuclei or more. In the giant cells of foreign bodies, the nuclei are located evenly in the cytoplasm, in the cells of Pirogov-Lanhgans - mainly on the periphery. The diameter of the granulomas does not exceed 1-2 mm. The consequence of granuloma is sclerosis.

According to the composition of cells, granulomas are divided into three types: macrophage granuloma, epithelioid cell, giant cell granuloma.

Depending on the level of metabolism, a distinction is made between granulomas with a low level of metabolism when damaged by inert substances (inert foreign bodies) and consisting mainly of giant cells of foreign bodies and granulomas with a high level of metabolism when damaged by toxic stimuli (mycobacterium



tuberculosis, leprosy) and represented by epithelioid-cell nodules .

By etiology: infectious (associated with bacteria, viruses, rickettsia, protozoa, chlamydia, etc.); non-infectious granulomas (around foreign bodies, particles of organic and inorganic dust: silicosis, talcosis, byssinosis (from the Greek. byssos – flax)). Such granulomas can be the result of medication: granulomatous hepatitis, oleogranulomatous disease; granulomas of unknown nature—with sarcoidosis, Crohn's disease, Horton's disease, Wegener's granulomatosis, etc.

Diseases accompanied by the development of granulomas are called granulomatous diseases.

According to the pathogenesis: immune (which more often reflects the GST reaction based on macrophage-T-lymphocyte interaction) - most infectious granulomas or arising from the introduction of dust particles of plant or animal origin are immune; in case of infectious diseases, they reflect the relative resistance of the organism to the causative agent (non-sterile immunity); non-immune (most foreign body granulomas): most often built from cells of foreign bodies, contain a small number of lymphocytes and plasma cells.

By morphology: non-specific granulomas do not have specific features. An example would be inflammation around foreign bodies and animal parasites; specific granulomas have a certain structure, which often (but not always) allows establishing the etiological factor.

They are found in the following diseases: tuberculosis; syphilis; leprosy; scleroma; actinomycosis; sap.

**Tuberculosis** caused by mycobacterium tuberculosis, which has its own specific properties.

High resistance, stability. It is stored in the body for many years even in calcified environments - petrified.

Mycobacterium causes an increase in the sensitivity of the body, that is, sensitization to the further entry of Koch bacilli into the body.

Causes establishment of immunity; immunity is called infectious, that is, it exists until the moment of activity of the tubercle bacillus. After the death of the

mycobacterium, immunity also disappears.

When mycobacterium tuberculosis enters the human body for the first time, which usually happens in early childhood, it causes the development of exudative inflammation. In the place of primary localization of Koch's bacilli, as a rule, a small center of fibrinous inflammation and alteration appears in the lungs in the form of caseous necrosis - necrosis, outwardly similar to cheese that has lain down and dried up. Inflammation and caseous necrosis also develop in regional lymphatic vessels and regional lymph nodes. The zone of primary localization of Koch bacilli and inflammation is called the primary tubercular affect. An inflammatory reaction develops in lymph nodes - lymphadenitis, lymphatic vessels - lymphangitis.

Together, these 3 elements are called the primary tuberculosis complex. The primary tuberculosis complex can be cured, or it can be complicated by the development of any forms of tuberculosis.

Among the forms of inflammation in tuberculosis in humans, exudative, necrotic and productive forms are distinguished. Productive forms of inflammation progress with the formation of a tuberculous granuloma. Tuberculous granuloma is otherwise called an epithelioid cell tubercle. Epithelioid cell granulomas develop in conditions of sensitization

A center of caseous necrosis is located in the center of the granuloma. It is a structureless mass of disintegrated tissues with the phenomena of karyorrhexis and karyopyknosis, which are quite characteristic of tuberculosis. A mass of all kinds of mesenchymal cells is adjacent to the caseous necrosis from all sides, and these cells are located in a certain order, as if by zones. Individual very large Pirogov–Langhans giant cells lie closest to the necrosis. The shape of giant cells is round or oval, protoplasm with a large number of round nuclei located on the periphery of the cell in the form of a corolla or horseshoe. Nuclei are well colored, dark, lie under the cell membrane. The widest zone of the so-called epithelioid cells is located outside of the giant cells of Pirogov-Lankhgans. These cells on the preparations have an elongated oval shape and a light, chromatin-poor, blister-like nucleus. Since there is not enough chromatin, the nucleus is pale colored and resembles an air bubble. Epithelioid cells

lie in several rows and layers and make up the majority, which is why the tubercle is called epithelioid. Round lymphoid cells are located on the very periphery of the granuloma. They are small in size, have a round core, which is quite compact, well colored. This is the 3rd zone. Finally, plasma cells are scattered around the granuloma in varying amounts, which are also round, the nucleus is located eccentrically, the lumps of chromatin in the nucleus are coarse, dense, well visible, lying in the form of spokes in a wheel. Thin reticulin fibers are located between the cells in the tubercle. In the conditions of treatment of tuberculosis with antibiotics, a granuloma can consist almost entirely of giant cells and is then called a giant cell tubercle. the nucleus is pale in color and resembles an air bubble. Epithelioid cells lie in several rows and layers and make up the majority, which is why the tubercle is called epithelioid. Round lymphoid cells are located on the very periphery of the granuloma. They are small in size, have a round core, which is quite compact, well colored. This is the 3rd zone. Finally, plasma cells are scattered around the granuloma in varying amounts, which are also round, the nucleus is located eccentrically, the lumps of chromatin in the nucleus are coarse, dense, well visible, lying in the form of spokes in a wheel. Thin reticulin fibers are located between the cells in the tubercle. In the conditions of treatment of tuberculosis with antibiotics, a granuloma can consist almost entirely of giant cells and is then called a giant cell tubercle. the nucleus is pale in color and resembles an air bubble. Epithelioid cells lie in several rows and layers and make up the majority, which is why the tubercle is called epithelioid. Round lymphoid cells are located on the very periphery of the granuloma. They are small in size, have a round core, which is quite compact, well colored. This is the 3rd zone. Finally, plasma cells are scattered around the granuloma in varying amounts, which are also round, the nucleus is located eccentrically, the lumps of chromatin in the nucleus are coarse, dense, well visible, lying in the form of spokes in a wheel. Thin reticulin fibers are located between the cells in the tubercle. In the conditions of treatment of tuberculosis with antibiotics, a granuloma can consist almost entirely of giant cells and is then called a giant cell tubercle. layers and make up the majority, that is why the tubercle is called epithelioid. Round lymphoid cells are located on the

very periphery of the granuloma. They are small in size, have a round core, which is quite compact, well colored. This is the 3rd zone. Finally, plasma cells are scattered around the granuloma in varying amounts, which are also round, the nucleus is located eccentrically, the lumps of chromatin in the nucleus are coarse, dense, well visible, lying in the form of spokes in a wheel. Thin reticulin fibers are located between the cells in the tubercle. In the conditions of treatment of tuberculosis with antibiotics, a granuloma can consist almost entirely of giant cells and is then called a giant cell tubercle. layers and make up the majority, that is why the tubercle is called epithelioid. Round lymphoid cells are located on the very periphery of the granuloma. They are small in size, have a round core, which is quite compact, well colored. This is the 3rd zone. Finally, plasma cells are scattered around the granuloma in varying amounts, which are also round, the nucleus is located eccentrically, the lumps of chromatin in the nucleus are coarse, dense, well visible, lying in the form of spokes in a wheel. Thin reticulin fibers are located between the cells in the tubercle. In the conditions of treatment of tuberculosis with antibiotics, a granuloma can consist almost entirely of giant cells and is then called a giant cell tubercle. have a round core, which is quite compact, well colored. This is the 3rd zone. Finally, plasma cells are scattered around the granuloma in varying amounts, which are also round, the nucleus is located eccentrically, the lumps of chromatin in the nucleus are coarse, dense, well visible, lying in the form of spokes in a wheel. Thin reticulin fibers are located between the cells in the tubercle. In the conditions of treatment of tuberculosis with antibiotics, a granuloma can consist almost entirely of giant cells and is then called a giant cell tubercle. have a round core, which is quite compact, well colored. This is the 3rd zone. Finally, plasma cells are scattered around the granuloma in varying amounts, which are also round, the nucleus is located eccentrically, the lumps of chromatin in the nucleus are coarse, dense, well visible, lying in the form of spokes in a wheel. Thin reticulin fibers are located between the cells in the tubercle. In the conditions of treatment of tuberculosis with antibiotics, a granuloma can consist almost entirely of giant cells and is then called a giant cell tubercle. have a round core, which is quite compact, well colored. This is the 3rd zone. Finally, plasma cells are scattered around the granuloma in varying amounts, which are also round, the nucleus is located eccentrically, the lumps of chromatin in the nucleus are coarse, dense, well visible, lying in the form of spokes in a wheel. Thin reticulin fibers are located between the cells in the tubercle. In the conditions of treatment of tuberculosis with antibiotics, a granuloma can consist almost entirely of giant cells and is then called a giant cell tubercle. Thin reticulin fibers are located between the cells in the tubercle. In the

conditions of treatment of tuberculosis with antibiotics, a granuloma can consist almost entirely of giant cells and is then called a giant cell tubercle. Thin reticulin fibers are located between the cells in the tubercle. In the conditions of treatment of tuberculosis with antibiotics, a granuloma can consist almost entirely of giant cells and is then called a giant cell tubercle.

**Syphilis** caused by pale treponema. The disease is chronic, lasts for many years and is characterized by stages depending on changes in the phases of immunity and increased sensitivity to the causative agent and tissue decay products. In the course of syphilis, periods of alternating exudative, alterative and productive reactions are distinguished, just as it happens in tuberculosis. There are basically three such periods.

The 1st period - the formation of the primary affect at the site of entry of the treponema and regional lymphadenitis. Primary affection in syphilis is called hard chancre. A hard chancre appears 2-4 weeks after infection in the form of a dense copper-red painless infiltrate (nerves die, so there is no pain). This infiltrate is a productive inflammation without any specific features. Soon enough, the infiltrate is covered with ulcers and turns into a dense, shallow chancre containing a lot of spirochetes, and therefore very contagious. In the vessels - the phenomena of productive panvasculitis. Inflamed lymph nodes are called syphilitic buboes. After 1–1.2 months. the ulcer heals and there is an asymptomatic period of pseudo-wellness. But during this time, the spirochete multiplies in the body and spreads to all organs and tissues.

The II period or stage - the stage of cutaneous syphilides or the papular period occurs 6-8 weeks after infection. A copper-red rash appears on the skin or visible mucous membranes in the form of flat red spots - roseolae and dense infiltrative papules that protrude. There are also abscesses-pustules and wide condylomas (on the genitals) - papillary growths. Syphilides contain a lot of treponemes, which easily enter the external environment during ulceration. The secondary period is considered highly contagious, syphilides heal with scars. The second stage of the disease is followed by an asymptomatic period, during which infectious immunity develops. In

the conditions of the immunity that has appeared, the next stage is manifested.

Stage III – the gummy stage occurs 3–6 years after infection. This 3rd period is characterized by the focal character of productive inflammation, the formation of granulomas. A granuloma in syphilis is called a gumma.

Gumma is built mainly of lymphoid and plasma cells, chaotically mixed with each other, there is no zonation. This is the first difference from tuberculous tubercle. Among the small cells, there are single giant multinucleated cells, similar to Pirogov–Langhans giant cells in tuberculous granuloma. However, the second distinction from the tuberculous tubercle is that the nuclei in the giant cells do not lie under the cell membrane, but are clustered in the center of the protoplasm. Epithelioid cells are also found in the gum, but in small quantities. The third difference between a gumma and a tuberculous granuloma is that there are many blood vessels in the gumma. The walls of these vessels are thickened, and the lumens are narrowed and even completely closed - the phenomenon of obliterating endarteritis. As a result of the obliteration of blood vessels, there are several foci of semi-liquid colliquative necrosis in the gum, glue-like mass (gummi - glue). This is another difference. In a tuberculous nodule there is only one center of necrosis, in gum - several. In the centers of necrosis in the gum, there are often separately preserved structures of the tissue in which the gum is located, for example, bone beams, liver trabeculae, etc. No structures in the zone of necrosis are visible in tuberculous nodules. Gradually, the gum is subject to scarring, and sharp, rough scarring with the formation, again, in contrast to tubercular granuloma, star-shaped retracted scars. Gums have various locations and come in different sizes. Small microgums can be located in the walls of the thoracic aorta, which is called syphilitic mesoaortitis. The intima of the aorta becomes uneven - shagreen, elastic fibers are destroyed and an aneurysm of the aorta is formed - a protrusion that can even rupture. This is another difference. In a tuberculous nodule there is only one center of necrosis, in gum - several. In the centers of necrosis in the gum, there are often separately preserved structures of the tissue in which the gum is located, for example, bone beams, liver trabeculae, etc. No structures in the zone of necrosis are visible in tuberculous nodules. Gradually, the



formation, again, in contrast to tubercular granuloma, star-shaped retracted scars. Gums have various locations and come in different sizes. Small microgums can be located in the walls of the thoracic aorta, which is called syphilitic mesoaortitis. The intima of the aorta becomes uneven - shagreen, elastic fibers are destroyed and an aneurysm of the aorta is formed - a protrusion that can even rupture. In the centers of necrosis in the gum, there are often separately preserved structures of the tissue in which the gum is located, for example, bone beams, liver trabeculae, etc. No structures in the zone of necrosis are visible in tuberculous nodules. Gradually, the gum is subject to scarring, and sharp, rough scarring with the formation, again, in contrast to tubercular granuloma, star-shaped retracted scars. Gums have various locations and come in different sizes. Small microgums can be located in the walls of the thoracic aorta, which is called syphilitic mesoaortitis. The intima of the aorta becomes uneven - shagreen, elastic fibers are destroyed and an aneurysm of the aorta is formed - a protrusion that can even rupture. In the centers of necrosis in the gum, there are often separately preserved structures of the tissue in which the gum is located, for example, bone beams, liver trabeculae, etc. No structures in the zone of necrosis are visible in tuberculous nodules. Gradually, the gum is subject to scarring, and sharp, rough scarring with the formation, again, in contrast to tubercular granuloma, star-shaped retracted scars. Gums have various locations and come in different sizes. Small microgums can be located in the walls of the thoracic aorta, which is called syphilitic mesoaortitis. The intima of the aorta becomes uneven - shagreen, elastic fibers are destroyed and an aneurysm of the aorta is formed - a protrusion that can even rupture. No structures in the zone of necrosis are visible in tuberculous nodules. Gradually,



the gum is subject to scarring, and sharp, rough scarring with the formation, again, in contrast to tubercular granuloma, star-shaped retracted scars. Gums have various locations and come in different sizes. Small microgums can be located in the walls of the thoracic aorta, which is called syphilitic mesoaortitis. The intima of the aorta becomes uneven - shagreen, elastic fibers are destroyed and an aneurysm of the aorta is formed - a protrusion that can even rupture. Small microgums can be located in the walls of the thoracic aorta, which is called syphilitic mesoaortitis. The intima of the aorta becomes uneven - shagreen, elastic fibers are destroyed and an aneurysm of the aorta is formed - a protrusion that can even rupture. Small microgums can be located in the walls of the thoracic aorta, which is called syphilitic mesoaortitis. The intima of the aorta becomes uneven - shagreen, elastic fibers are destroyed and an aneurysm of the aorta is formed - a protrusion that can even rupture. Small microgums can be located in the walls of the thoracic aorta, which is called syphilitic mesoaortitis. The intima of the aorta becomes uneven - shagreen, elastic fibers are destroyed and an aneurysm of the aorta is formed - a protrusion that can even rupture.

In addition to gumma, in the tertiary period of syphilis, diffuse productive-necrotic processes, or so-called gummous infiltrates, occur in the aorta and other vessels, as well as in the liver.

This is a characteristic of inflammatory reactions in acquired syphilis. If a syphilitic woman becomes pregnant, intrauterine infection of the fetus can occur via the hematogenous route through the placenta and the umbilical vein, and then congenital syphilis occurs. Placental blood circulation is established in the 4th month of pregnancy, infection of the fetus occurs no earlier than this period. There are: syphilis of stillborn fetuses; syphilis of newborns and infants; late congenital syphilis at the age of 4 to 17 years.

In congenital syphilis of newborns and children up to 4 years of age, immunity is established, the inflammation is exudative-necrotic in nature, with the development of small necrosis centers with admixtures of leukocytes and a large number of treponema in all organs. These foci have been called "miliary gummas" since ancient times, although they have nothing to do with the gummas of the tertiary period of syphilis. The rash on the skin is diffuse, confluent, rashes are characteristically located on the soles and palms, diffuse damage to internal organs - liver, lungs - is noted.

In late congenital syphilis, the changes are similar to acquired syphilis - ordinary papular syphilides and gums in the internal organs.

### **Actinomycosis.**

Currently, it has been established that the causative agent of actinomycosis is gram-positive bacteria - microaerophilic, aerobic and anaerobic actinomycetes, which are widespread in nature. They make up 65% of the total number of soil microorganisms, are found in water, in particular tap water and spring water, in hot (up to 65°C), mineral springs, on plants, on stony rocks and even in the sands of the Sahara. In the human body, actinomycetes are also permanent residents, they contaminate the oral cavity, bronchi, gastrointestinal tract, and vagina.

Actinomycetes, as a rule, lead a saprophytic lifestyle, but some strains can cause disease under certain conditions. It is known that actinomycetes do not penetrate through healthy skin and mucous membranes, therefore, the main contributing factor, along with a decrease in the body's immune defenses, is injury to the barrier membranes. The causative agent enters the body, as usual, through the digestive tract. The process spreads mainly through the fiber and connective tissue layers of organs and tissues. In some cases, general infection is noted. Skin damage often occurs again as a result of the spread of the pathological process from deep-lying tissues. Cervical-maxillofacial actinomycosis, pulmonary and other varieties are distinguished according to the ways of its spread and localization. The affected area is characterized by the presence of a dense nodular infiltrate in the subcutaneous adipose tissue, which was formed from fused nodes, the skin under which has a bluish-red color. Later, the infiltrate in some areas softens and small fistulas appear, from which pus is released.

Actinomycotic granuloma is composed of plasmatic, epithelioid and giant multinucleated cells. All the cells are scattered in disorder. Actinomycotic drusen are found in granuloma in 50% of cases. Drusen stain well according to Gram and Van Gieson. Russel bodies and hyaline spheres, which are hyalinized dead plasma cells, are also found. The presence of large dense sclerotic fields, among which abscesses are scattered, is characteristic. In abscesses, drusen are usually found among dead

leukocytes.

A cluster of xanthoma cells loaded with cholesterol can be found near the border of the abscesses. The word "xanthos" means "yellow"; cells are yellow from cholesterol.

**Respiratory scleroma** - chronic disease of the respiratory tract. It is called a Frisch-Volkovich stick. It is characterized by the growth of a peculiar, dense consistency of granulation tissue, built from plasmatic, epithelioid and lymphoid cells. Specific large Mikulich cells with vacuolated cytoplasm, light, as if reticulated. The nuclei, in the number of 1 or 2, are small, compacted, rod-shaped, located near the shell on the periphery of the cell. In the vacuoles of the cytoplasm of Mikulich cells, the causative agents of the disease are located - Frisch-Volkovich bacilli. They have a mucilaginous capsule, and therefore the cytoplasm of the cells, becoming mucilaginous, becomes light, reticulate. During the development of the process, part of the plasma cells ages and undergoes hyalinosis, turning into Russel bodies and hyaline spheres. There are quite a lot of blood capillaries in the granuloma. The growth of connective tissue narrows the lumen of the respiratory tract. This causes breathing problems and can cause death from asphyxiation.

**Leprosy** - a chronic infectious disease that usually affects the skin and peripheral nerves.

The disease is caused by mycobacterium Hansen. The source of infection is a sick person. There are three types of leprosy: lepromatous, tuberculoid, and intermediate.

Most often, the skin, upper respiratory tract and peripheral nerves are affected. Specific granulomas are formed - lepromas.

*Lepromatous form of leprosy* most often develops in the skin, is characterized by the appearance in it of nodules of various sizes and nodules (leproma) of a soft consistency, located in the surface layers of the skin.

Histologically active lepromatous process is represented by the development of nodules. They merge with each other and consist mainly of macrophages with an admixture of lymphocytes, plasma cells, and histiocytes. Leprosy contains a huge

amount of leprosy mycobacteria. According to Binford, 1 g of flowering leproma contains  $5 \cdot 10^9$  mycobacteria. Such a powerful and unstoppable reproduction of the causative agent of leprosy is explained by the fact that their phagocytosis by macrophages is incomplete. Electron microscopy shows that the phagolysosomes of the macrophage contain intact, viable mycobacteria arranged in regular rows. Partial decay of mycobacteria occurs only over time. Macrophages that have phagocytosed leprosy mycobacteria increase in size. Vacuoles, fatty inclusions, very characteristic of leprosy, gradually appear in them. Macrophages changed in this way are called Virchow's leprosy cells. Masses of bacteria in the macrophage stick together in the form of "balls", when the cells die, they are released from it and are located freely in the tissue. In the future, the spheres are phagocytosed by giant cells of foreign bodies. Lepromatous infiltration in the skin is often diffuse. The tuberculoid form of leprosy is characterized by the proliferation of epithelioid cells, the formation of giant Pirogov–Langhans cells, and the accumulation of lymphocytes. Cellular infiltrates in the tubercular form of leprosy are located in the papillary layer under the epidermis itself. Leprosy mycobacteria are found in very small quantities. With the tuberculoid form of leprosy, small nerves of the skin are constantly involved in the process, which are destroyed. Nerve damage is accompanied by loss of skin sensitivity as one of the early symptoms of leprosy. Based on the nature of the tissue reaction, it can be assumed that the tuberculoid form shows a high resistance of the macroorganism to infection. Cellular infiltrates in the tubercular form of leprosy are located in the papillary layer under the epidermis itself. Leprosy mycobacteria are found in very small quantities. With the tuberculoid form of leprosy, small nerves of the skin are constantly involved in the process, which are destroyed. Nerve damage is accompanied by loss of skin sensitivity as one of the early symptoms of leprosy. Based on the nature of the tissue reaction, it can be assumed that the tuberculoid form shows a high resistance of the macroorganism to infection. Cellular infiltrates in the tubercular form of leprosy are located in the papillary layer under the epidermis itself. Leprosy mycobacteria are found in very small quantities. With the tuberculoid form of leprosy, small nerves of the skin are constantly involved in the process, which are

destroyed. Nerve damage is accompanied by loss of skin sensitivity as one of the early symptoms of leprosy. Based on the nature of the tissue reaction, it can be assumed that the tuberculoid form shows a high resistance of the macroorganism to infection.

*An intermediate form of leprosy* manifested by the appearance of a nonspecific cellular reaction in the skin around blood vessels and appendages of the skin, and sometimes small nerve trunks. With this form of mycobacterium leprosy, sometimes it is found in intact nerves. The intermediate form of leprosy is very difficult for clinical and morphological diagnosis.

Leprous granulomas do not always undergo necrosis. Ulcerative complications on the skin occur as a result of trophic disorders in connection with damage to nerve trunks. In some cases, when a specific inflammatory reaction occurs in the bone marrow of the phalanges of the fingers or toes, their separation (mutilation) is possible. Under the influence of treatment, leprosy granulomas are replaced by proliferating cells of connective tissue and scars remain at the site of granulomas. However, after a certain period of fading, the disease can flare up again with a complete repetition of the entire cycle of cellular reactions. In other words, both clinically and morphologically, leprosy proceeds in a wave-like manner, with periods of disease outbreaks alternating with subsidence of inflammation. In this regard, leprosy patients must be constantly under the control of a doctor.

**Sap** -zoonotic infectious disease, which proceeds according to the type of septicopyemia with the formation of specific granulomas, abscesses in various tissues and organs.

With acute phlegm, nodules appear, which consist of epithelioid cells with an admixture of neutrophilic leukocytes. These nodules very quickly undergo necrosis and purulent melting. Karyorrhexis is very characteristic; nuclei turn into small lumps that are intensively stained with hematoxylin. In addition to granuloma, abscesses can occur in organs and skin.

Nodules are formed in case of chronic sputum. Nodules appear in various organs, including the lungs, and are very similar to tuberculous tubercles. With

chronic asthma, sclerotic changes can occur in the organs, in particular in the lungs.

*Productive inflammation with the formation of polyps and condylomas.* It is observed on the mucous membranes and in the flat epithelium bordering them. It is characterized by the simultaneous involvement of the epithelium and stroma of the mucous membrane in the process. The growth of the glandular epithelium together with the cells of the underlying connective tissue leads to the formation of polyps. Such polypous growths are observed with long-term inflammation of the mucous membrane of the nose, stomach, rectum, uterus, vagina, etc. It should be noted that polyps on some mucous membranes often have an inflammatory origin, while on others - tumor origin. In the areas of the flat epithelium, which is located near the prismatic one (anus, genitals), exudate during chronic inflammation constantly irritates them, which causes the growth of the stroma and epithelium with the formation of papillary formations - condylomas. Similar papillary growths of the epithelium are observed in syphilis,

In the second half of the 70s of the last century, views on condylomatous lesions of the cervix changed significantly. Along with the well-known classic form - acuminate condyloma (papillary or exophytic type), two more types of papillomavirus lesions were identified in the cervix: "flat" and endophytic condyloma (intraepithelial and inverted types). The last type, namely endophytic condyloma, is rare. Flat condylomas predominate among condylomatous lesions of the cervix. It is possible to develop all three types of papillomavirus lesions in the vagina.

According to the literature, there is a gradual increase in the frequency of condylomatous lesions, and flat condylomas of the cervix are observed almost exclusively in young women.

The incubation period for papillomavirus infection ranges from 1 to 9 months, with an average of three months. Acuminate condylomas have the appearance of single or numerous small (sometimes significant, giant size) papillary-type formations, pale pink in color on a short stem and resemble a wart, raspberry berry, cauliflower, or cock's comb. Depending on the location (external genitals, vagina, cervix), condyloma acuminata can be flesh-colored or intensely red, and whitish

when macerated. When ulcerated, they secrete a liquid with an unpleasant, stinky smell. Giant condylomas can be symmetrically located on the labia majora and labia minora, occupy the entire genital opening, and move to the femoral-inguinal folds. Sometimes they are located in the crotch, between the buttocks, and also isolated around the anus with a transition to the mucous membrane of its sphincter. Large condylomas in the form of a clutch can be localized around the urinary canal.

In the initial period of the formation of condyloma acuminata, symptoms are often absent, but with their rapid growth, patients seek help from a doctor. The appearance of a significant amount of exudate causes maceration, ulceration of condyloma and skin, which leads to the appearance of itching and heartburn. With large and gigantic condylomas, patients have difficulty moving.

For the diagnosis of papillomavirus infection, in particular flat condyloma, cytological and histological examination of the tissue removed during targeted biopsy is of great importance. During cytological examination, koilocytes are found in the smears, which are cells of the flat epithelium of the intermediate and surface layers with wide perinuclear clearing, a narrow rim of cytoplasm preserved on the periphery, with amphophilic properties (when stained according to Papanicolaou) and nuclei with dystrophic changes and as if "suspended" in space, as well as dyskeratocytes (isolated or exfoliated in the form of aggregates), which are squamous epithelial cells with an enlarged hyperchromic or pyknotic nucleus and orange-philic cytoplasm. Both cell types can be multinucleated.

According to the literature, during cytological examination hyperkeratosis is diagnosed in 53% of cases, parakeratosis in 28%, proliferation of cylindrical epithelium in 50%, hyperplasia of reserve cells in 11%, dyskaryosis in 7%, koilocytosis in 48%. More often, these signs are observed in combination.

On histological examination, classic condylomas are characterized by papillomatosis, acanthosis, elongation and expansion of papillae, parakeratosis, and the presence of koilocytes. Flat condylomas are located in a multi-layered flat epithelium with acanthosis. There is usually a clear demarcation between the unchanged basal and parabasal layers and the more superficial layers of the

epithelium, which contain koilocytes. Sometimes in the superficial parts of the damage there is a layer of different thickness of dyskeratocytes with pyknotic nuclei and other dystrophic changes. Condylomas are always removed, regardless of their type, location and size, spontaneous recovery (disappearance) never occurs, and benign condylomas can sometimes turn into carcinoma.

Thus, it can be concluded that the features of productive inflammation are determined not only by the character of the pathogen, but also by the features of the structure of the organs. Thus, productive inflammation in the myocardium can have both nodular limited and interstitial diffuse character. In the liver, interstitial inflammation is more often diffuse, spreading through the stroma of the organ. In the kidneys, productive inflammation is observed both in the glomeruli in the form of productive glomerulitis without damage to the stroma of the organ, and in the stroma in the form of interstitial nephritis. In the central nervous system, proliferation occurs mainly due to neuroglia and vascular elements. In the walls of blood vessels, inflammation is accompanied by the proliferation of cambial cells of the endothelium and adventitia.

The course of productive inflammation can be acute, but in most cases it is chronic. The acute course is characteristic of productive inflammation, which occurs in a number of infectious diseases - typhoid and typhus, tularemia, relapses of acute rheumatism; productive glomerulitis is observed in scarlet fever. The chronic course is characteristic of most interstitial productive inflammatory processes (for example, in the myocardium, kidneys, liver, muscles, etc.), which end in sclerosis.

The consequence of productive inflammation is different depending on the organ or tissue in which it occurs and the course of the disease. Chronic productive inflammation causes the development of focal or diffuse sclerosis of the organ. If at the same time deformation (shrinking) of the organ and its structural restructuring develops, then we are talking about cirrhosis. Nephrocirrhosis as a result of chronic glomerulonephritis, liver cirrhosis as a result of chronic hepatitis, pneumocirrhosis as a result of chronic pneumonia, etc.



**Materials on the activation of students of higher education during the lecture: questions, situational tasks, etc (if necessary):**

A 55-year-old man suffered from chronic glomerulonephritis for a long time. He died of chronic kidney failure. On the surface of the epicardium and pericardium, grayish-whitish villous layers are found. What pathological process took place in the pericardium?

- AND Fibrinous inflammation
- B Bodyization
- C Proliferative inflammation
- D Hemorrhagechronic inflammation
- E Arterial thoroughbred

At the autopsy of a 34-year-old deceased from rheumatism, the surface of the epicardium is woolly, covered with gray films that are easily detached. After their separation, a swollen full-blooded surface is determined. What is the most likely diagnosis?

- AND Fibrinous pericarditis
- B Hn1st pericarditis
- C Hemorrhagechronic pericarditis
- D Proliferative pericarditis
- E Catarrhal pericarditis

A 55-year-old man suffered from chronic glomerulonephritis. Death occurred due to the phenomena of chronic kidney failure. Macroscopically: on the surface of the epicardium and pericardium, there are grayish-whitish villous layers, after removal of which sharply expanded and filled with blood vessels are clearly visible. What process took place in the pericardium?

- AND Fibrinous inflammation
- B Bodyization
- C Proliferative inflammation
- D Hemorrhagechronic inflammation
- E Arterial thoroughbred

A 40-year-old patient died of cerebral edema. There is a history of facial carbuncles. At the autopsy, hemoptysis and swelling of the brain tissue were noted. In the white matter of the left hemisphere, two cavities measuring 6x5.5 and 5x4.5 cm filled with a yellowish-green creamy liquid were found. The walls of the cavities are nerve tissue with uneven edges. What complication of carbuncle developed in the patient?

- AND acuteand abscesses
- B Chroneye abscesses
- C Empi have
- D Qtyicvation necrosis
- E Kto go

A 40-year-old patient died of cerebral edema. There is a history of facial carbuncles. At the autopsy, hemoptysis and swelling of the brain tissue were noted. Two cavities measuring 6x5.5 cm and 5x4.5 cm were found in the white matter of the left

hemisphere, filled with a yellowish-green, creamy liquid. The walls of the cavities are nerve tissue with uneven edges. What complication of carbuncle developed in the patient?

- A AND acute abscesses
- B Chroneye abscesses
- C Empi have
- D Qtyicvation necrosis
- E Kto go

### **General material and bulk-methodological support of the lecture:**

#### **Questions for self-control:**

1. Definition of inflammation. Factors leading to the development of inflammation.
2. Classification of inflammation according to various criteria. Phases inflammation.
3. Acute inflammation. General characteristics, morphological classification.
4. Serous inflammation, morphological characteristics. The concept of exudate. Comparative characteristics of exudate and transudate.
5. Purulent inflammation, classification, morphological characteristics general and its individual types.
6. Fibrinous inflammation, classification, morphological characteristics general and its individual types. Concept of TRUE AND FALSE CRUISE
7. Catarrhal inflammation, classification, morphological characteristics general and its individual types.
8. Hemorrhagic inflammation, morphological characteristics.
9. Purulent inflammation.
10. Mixed inflammation.
11. Complications and consequences of inflammation
12. Definition of inflammation, classification, macro- and microscopic signs inflammation.
13. Causes of the development of chronic inflammation. (Or why acute inflammation became chronic?)
14. Classification (types) of chronic inflammation.
15. Interstitial inflammation, morphological characteristics, consequences.
16. What is a polyp, morphological characteristics of a polyp (macro- and microscopic structure), examples?
17. What is a condyloma, morphological characteristics (macro- and microscopic structure), examples?
18. Granulomatous inflammation. morphological characteristics, results.
19. What is a granuloma, types of granulomas, types of giant cells?
20. Structure of tuberculous granuloma.

21. Structure of syphilitic granuloma.
22. The structure of a leprosy granuloma.
23. Structure of rhinoscleral granuloma.

### References:

#### Main:

1. Atlas of micropreparations in pathomorphology / I.I. Starchenko, B.M. Filenko, N.V. Royko, etc.; VDZU "UMSA". - Poltava, 2018. - 190 p
2. Starchenko, S.O. Bilokon and others.. – Poltava: Tov. "ASMI" - 2018. - 190 p.
3. The basics of pathology according to Robbins: in 2 volumes. Volume 1 / Vinay Kumar, Abul K. Abbas, John C. Astaire; translation of the 10th Eng. edition. Publisher: All-Ukrainian specialized publishing house "Medytsyna". – X II. - 2019. - 420 p.
4. The basics of pathology according to Robbins: in 2 volumes. Volume 1 / Vinay Kumar, Abul K. Abbas, John C. Astaire; translation of the 10th Eng. edition. Publisher: All-Ukrainian specialized publishing house "Medytsyna". – X II. - 2019. - 420 p.
5. Pathomorphology. General pathomorphology: a study guide / edited by Ya. Ya. Bodnara, V.D. Voloshina, A.M. Romanyuk, V.V. Gargin. - New Book, 2020. - 248 p.
6. Pathomorphology of the main diseases of the cardiovascular system: study guide / I.I. Starchenko, B.M. Filenko, N.V. Royko – Poltava: "UMSA". - 2019. - 150 p.
7. I.I. Starchenko Pathomorphology of the main diseases of the maxillofacial region: academician. manual / I.I. Starchenko, B.M. Filenko, V.V. Chernyak ; "UMSA". – Vinnytsia: Nova Kniga, 2019. – 128 p.
8. Ctarchenko I.I. Special pathomorphology (basic course) for students of medical faculties of higher medical educational institutions of III-IV levels of accreditation / II Starchenko, N.V. Royko, B.M. Filenko. – Poltava, 2017. – 174 p.
9. Tuffaha S. A. Muin Immunohistochemistry in tumor diagnostics / S. A. Tuffaha Muin, S. G. Hychka, Gusky Hans. - "Book Plus", 2018. - 336 p.
10. Essentials of pathology: textbook / Ya. Bodnar, A. Romanyuk, V. Voloshyn, V. Gargin - Kharkiv, "Planeta-Print" Ltd, 2020, 219 p.
11. Pathology: textbook / IVSorokina, VD Markovskiy, DI Halata et al.; edited by IVSorokina, VD Markovskiy, DI Halata. - Kyiv: AUS Medicine Publishing, 2019. - 328p. + 2 color inserts (8p. + 12p.).
12. Pathology: textbook / IVSorokina, VD Markovskiy, DI Halata et al.; edited by IVSorokina, VD Markovskiy, DI Halata. - 2nd edition. - Kyiv: AUS

Medicine Publishing, 2020. - 328p. + 2 color inserts (8p. + 12p.).

Additional:

1. Benign neoplasms of bones of the maxillofacial area in children / P.I. Tkachenko, I.I. Starenko, S.O. Bilokin [and others] - P.: "UMSA", 2016. - 85 p
2. General pathomorphology / I.I. Starchenko, N.V. Royko, B.M. Filenko [et al.] – Poltava, 2016. – 136 p.
3. Zerbino D. D. Pathomorphology and histology: an atlas / D. D. Zerbino, M. M. Bagrii, Y. Ya. Bodnar, V. A. Dibrova. – Vinnytsia: Nova Kniga, 2016. – 800 p.
4. Methods of morphological research / M.M. Baghrii, V.A. Dibrova, O.G. Papadynets, M.I. Grischuk; edited by M.M. Baghria, V.A. Dibrov – Vinnytsia: Nova Kniga, 2016. – 328 p.
5. Novoseltseva T.V. Pathology of sexual and endocrine systems / T.V. Novoseltseva, B.M. Filenko, N.I. Hasiuk - Poltava: LLC "ASMI", 2015. - 199 p.
6. Pathomorphology: national. / V.D. Markovskiy, V.O. Tumanskyi, I.V. Sorokina [and others]; edited by V.D. Markovsky, V.O. Tumanskyi. - K.: VSV "Medicine", 2015. - 936p.
7. Workshop on biopsy-sectioning course / I.I. Starchenko, A.P. Hasyuk, S.A. Proskurnya [etc.] – Poltava, 2016. – 160 p.

## Lecture No. 5

**Topic:** Patomorphology of the immune system. Reactions and mechanisms of hypersensitivity. Adaptation and compensation processes. Regeneration and reparation. Sclerosis.

**Actuality of theme:** This topic will let us know the pathomorphology of the immune system. Reactions and mechanisms of hypersensitivity, immediate type, processes of adaptation and compensation. Regeneration and reparation. Sclerosis.

### Goal:

Understand the concept of immunity, its types, types of immune response, cellular and humoral immunity, immunodeficiency, immunogenesis, hypersensitivity, anaphylaxis, autoimmune reactions, immunodeficiencies, AIDS, adaptation,

compensation, atrophy, hyperplasia, metaplasia, compensation, regeneration, features of regeneration of individual organs and tissues, wound healing, sclerosis, serosis, scar, hypoxia.

**Basic concepts:** Hypersensitivity (anaphylaxis, atopy, granulomatosis, cytotoxic type hypersensitivity, immune complex type hypersensitivity) Autoimmune diseases (organ-specific autoimmune diseases, non-specific autoimmune diseases) Immunodeficiency primary immunodeficiency syndromes, secondary immunodeficiency syndromes, accidental involution of the thymus, transplant rejection, graft versus host, thymomegaly (syndrome sudden infant death);

### **Plan and organizational structure of the lecture:**

Greetings, verification of those present, announcement of the topic, purpose of the lesson, motivation of higher education seekers to study the topic.

### **Content of lecture material (lecture text)**

**Immunity**—it is a complex of reactions aimed at protecting the body from infectious agents of substances that differ from it in biological (antigenic) properties.

The immune response consists of cellular interactions that are activated by the introduction of foreign antigenic material into the body. After processing by macrophages, the antigen is handled by lymphocytes, which are the main cells of the executive branch of the immune system (Fig. 1). Activation of a lymphocyte by an antigen leads to the proliferation and transformation of lymphocytes. There are two main types of immune response:

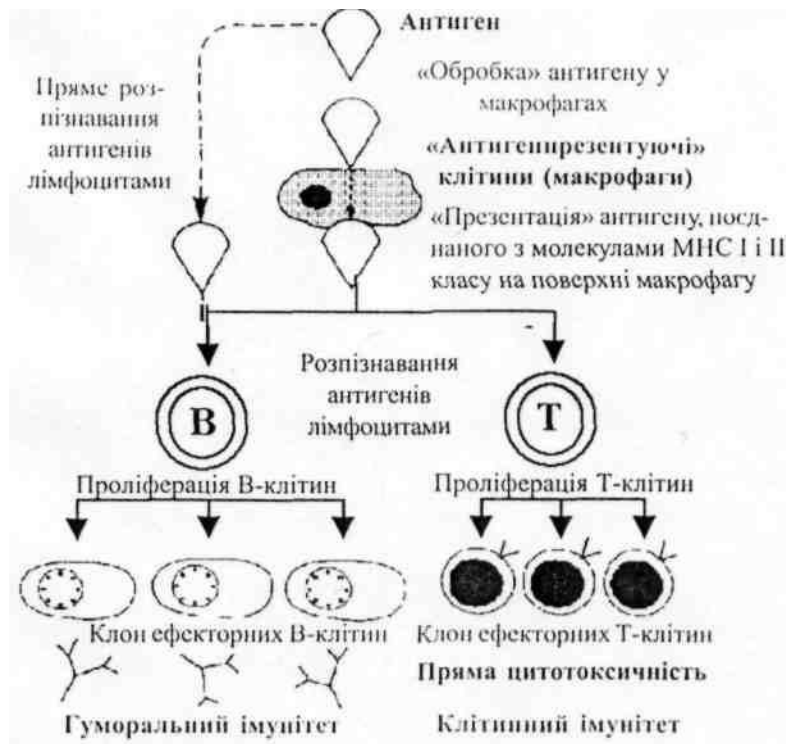


Fig. 1. General scheme of the immune response

Lymphocytes (both T and B), which carry specific antigen receptors, begin to proliferate (the growth phase of the immune response) after encountering an antigen. Antigen-presenting cells (various types of macrophages) are involved in the mechanism of antigen recognition. During reproduction, clones of effector cells are formed. Plasma cells secreting immunoglobulins (antibodies) arise from B-cells, and cytotoxic cells from T-cells.

*Cellular immunity* is the function of T-lymphocytes; with cellular immunity, effector cells are formed - T-killers, capable of destroying cells that have an antigenic structure, through direct cytotoxicity and through the synthesis of certain substances called lymphokines, they participate in the processes of interaction between cells (macrophages, T cells, B- cells) during an immune response. In addition, two subtypes of T cells take. participation in the regulation of the immune response: T-helpers enhance the immune response; T-suppressors have the opposite effect.

*Humoral immunity* -it is a function of B cells and is characterized by the transformation of B cells into plasma cells that secrete immunoglobulins (antibodies)

that have specific activity against the antigen that has entered the body.

**The immune response is characterized:**

- 1) specificity (reactivity is aimed only at a certain agent, which is called an antigen);
- 2) potentiation (the ability to produce an enhanced response when the body receives the same antigen continuously);
- 3) immunological memory (the ability to recognize and produce an enhanced response against the same antigen upon repeated exposure to the body, even if the first and subsequent exposures occur after long intervals of time).

These features distinguish the immune response from other non-specific host responses (acute inflammation and non-immune phagocytosis).

*Tolerance to own antigens.* The concept of "own" and "other" is central to immunological reactivity. A large number of molecules in the body are antigens, that is, they cause an immune response when introduced into another body, but are not recognized as antigens by the host. The inability to respond to one's own antigens is called natural tolerance. This phenomenon prevents the host's immune system from destroying its own tissues. Tolerance to one's own antigens develops in the embryonic period, and this is a manifestation of the specificity and memory of the immune response.

**The cellular basis of the immune response**

*Lymphoid system*

The immune response is carried out by the body's lymphoid system, which is divided into central and peripheral organs of immunogenesis.

*To the central bodies of immunogenesis* include thymus and bone marrow, in which primary, semi-stem lymphoid cells arise during the fetal period (variety and tolerance arise during this period). It is believed that the final development of diversity and tolerance in humans is completed within a few months after birth).

*To the peripheral organs of immunogenesis* include the lymph nodes, the spleen, the Pirogov–Valdeier ring (tonsils), and the lymphatic follicles in the walls of the intestine, which accumulate mature lymphocytes that respond to antigenic

stimulation.

Peripheral blood also contains lymphocytes. Circulating lymphocytes make up a pool of cells that continuously exchange with cells of peripheral lymphoid tissue.

*Lymphocytes* are formed in the embryonic period from a lymphoid sprout in the bone marrow. Based on their origin and immune functions, lymphocytes are divided into two main types – T- and B-lymphocytes: 1) T-lymphocytes (thymus-dependent) are formed in the thymus and 2) B-lymphocytes are formed outside the thymus. B-lymphocytes develop in birds in the bag of Fabricius (lat. bursa - bag, hence the term "B-cells"); the functional equivalent in humans is the embryonic liver or bone marrow.

Inactive small lymphocytes are cells with a diameter of approximately 8-10  $\mu\text{m}$ , with a small volume of cytoplasm and a spherical nucleus that occupies almost the entire cell. The nucleus contains condensed chromatin, which looks quite basophilic with conventional staining of preparations. All inactive populations of lymphocytes are similar to each other morphologically and can be differentiated only by immunological and immunomorphological means.

*Distribution of T cells in the body:* T-lymphocytes are formed in the embryonic thymus. In the post-embryonic period, after maturation, T-lymphocytes settle in the T-zones of the peripheral lymphoid tissue. These zones include:

- paracortical zone of lymph nodes and the space between lymphoid follicles (70% of lymphocytes in lymph nodes are T-lymphocytes);
- periarterial zones of lymphoid follicles in the white pulp of the spleen (40% of splenic lymphocytes are T-cells). T-lymphocytes continuously and actively circulate between peripheral blood and peripheral lymphoid tissue. From 80 to 90 percent of peripheral blood lymphocytes are T cells.

*T cell transformation:* After stimulation (activation) by a certain antigen, T-lymphocytes are transformed into large, actively dividing ones, and are called transformed T-lymphocytes, or T-immunoblasts, from which the executive branch of T cells then arises. T-immunoblasts with a diameter of 15–20  $\mu\text{m}$ , with a large volume of cytoplasm and an irregular nucleus with light chromatin and nucleolus; the



nucleus is located in the center of the cell. T-immunoblasts can be distinguished from B-immunoblasts only with the help of immunomorphological methods. Effector T-lymphocytes are morphologically similar to inactive small lymphocytes and are often called sensitized, cytotoxic or T-killer cells

This process of T-cell transformation constitutes a stage of development, (amplification) of the immune response, during which several T-cells bearing receptors recognize this specific antigen, form a numerous clone of T-cells of the executive branch, active against the same antigen, therefore that they have the appropriate receptor. The complete process of T-cell activation begins when macrophages intercept the antigen and, with the help of a certain mechanism that is not yet fully understood, “process” the antigen and re-expose it to the cell surface in combination with MHC molecules before interacting with the T-cell. Recognition occurs only when the T-cell carries a specific receptor capable of recognizing the “antigen-MHC-molecule” complex.

*Effector T-cells* play an important role in three functions of the immune system:

- cellular immunity;
- regulating the activity of B cells;
- hypersensitivity of delayed (IV) type.

1. *Cellular immunity* includes two main aspects:

- cytotoxic cells that carry surface antigens cause direct damage to cells (cytotoxic, or killer cells). Direct cytotoxicity is observed in the immune response to antigens on the surface of neoplastic cells, transplanted tissues and virus-infected cells. Cytotoxic T-cells may cause lysis by forming pores in the cytoplasmic membranes of antigen-positive cells.

- production of lymphokines: effector T cells play a crucial role in shaping the immune response by producing soluble proteins (lymphokines) that regulate the functions of certain cells, such as macrophages and other lymphocytes

2. *Regulation of B-lymphocyte activity*: two important subtypes of T-lymphocytes take part in regulating the function of B-lymphocytes.

Helper T-cells (CD4 antigen-positive) help in the activation and transformation

of B-lymphocytes and in the synthesis of immunoglobulins. Suppressor T-cells (CD8 antigen-positive) inhibit the activation of B-cells and regulate the synthesis of immunoglobulins.

*Distribution of B cells in the body:* B-lymphocytes develop in the functional equivalent of the bag of Fabricius of birds (probably in the embryonic bone marrow of mammals), undergoing a complex process that includes multiplication and division into classes. After that, B-lymphocytes spread through the bloodstream to the B-zone of the peripheral lymphoid tissue. These zones include: 1) reactive (secondary or germinal) centers of follicles and sinuses of the cerebral layer of lymph nodes (30% of lymphocytes in lymph nodes are B-cells); 2) reactive centers in the follicles of the white pulp of the spleen (40% of splenic lymphocytes are B cells). The term "primary, follicle" is used to refer to a cluster of B cells in the lymph nodes or spleen that do not show proliferative activity. Like T cells, B cells also constantly circulate between lymphoid tissue and peripheral blood. However, I am less active. B-cells make up 10-20 percent of the total number of peripheral blood lymphocytes.

*B-cell transformation:* after stimulation with a specific antigen, B lymphocytes are transformed into plasma cells. This process proceeds in stages, with the formation of a number of intermediate forms that form the reactive (germinative) center of the follicle. Plasma cells synthesize immunoglobulins (antibodies), which are specific for an antigen. The formation of circulating antibodies specific for antigens is the basis of acquired immunity, which is called humoral immunity.

"Null" cells are a heterogeneous group of lymphocytes that fail to form E-rosettes (an immunological test previously used to identify T lymphocytes) and do not carry surface immunoglobulin (hence, unlabeled, or "null" cells). This group includes some cells that are clearly T- or B-cells, which has recently been proven by genetic methods and the method of monoclonal antibodies, but the designation of these cells has been left. The population of "null" cells are T- and B-cells that are in the early stages of differentiation, before the appearance of a large number of markers on their surface. "Null" cells make up 5-10% of all peripheral blood lymphocytes. NK cells (natural killers) have cytotoxic activity; K-cells participate in the destruction

of cells with the help of antibodies.

### **Types of immune response**

Based on whether the immune system was previously familiar with the antigen or not, two types of immune response are distinguished: primary and secondary.

*Primary immune response* occurs upon first encounter with a specific antigen. Although the antigen is recognized almost immediately after exposure, it takes several days before sufficient immunoglobulin is produced to detect an increase in serum immunoglobulin levels. During this latent period, those B cells with receptors that have reacted with a specific antigen go through six to eight successive cycles of division before a large enough clone of antibody-secreting plasma cells is formed. IgM is the first immunoglobulin produced during the primary response, followed by IgG. Switching from IgM to IgG synthesis or other immunoglobulins occurs as a normal phenomenon during the activation of B cells and is carried out as a result of heavy chain gene switching.

*Secondary immune response* occurs when re-meeting with an antigen. Re-recognition occurs immediately and the production of serum immunoglobulins, which is detected by laboratory tests, occurs faster (after 2-3 days) than with the initial response. IgG is the main immunoglobulin that is secreted during the secondary response. In addition, the peak level is higher and the decline is slower than in the primary response.

### **Abnormalities of the immune response**

Basically, immune reactions develop covertly, while they lead either to the complete destruction of the antigenic aggressor; or to partial inhibition of its pathogenic action, ensuring a state of immunity in the body.

However, under some circumstances, these reactions may develop unusually.

In some cases; when a foreign agent is introduced into the body, they are so intense that they lead to tissue damage and are accompanied by the phenomenon of inflammation, then we speak of a reaction (or disease) of hypersensitivity.

Sometimes, under certain conditions, body cells acquire antigenic properties or antibodies are produced in the body that can react with normal cell antigens. In these

cases, they talk about diseases due to autoimmunization, or autoimmune diseases.

Finally, there are conditions in which, despite the arrival of antigenic material, immune reactions do not develop. Such conditions are referred to as immune failure or immunodeficiency.

Thus, the immune system, which is normally involved in maintaining homeostasis, can be the source of pathological conditions caused by excessive reaction or insufficient response to aggression, which are designated as immunopathological processes.

*Immunopathological* such processes are called, the development of which is associated with a violation of the function of immunocompetent (lymphoid) tissue. Immunopathological processes form the basis of immunopathology - a branch of medicine that studies all pathological diseases that arise as a result of immunological conflict and violations of immunological homeostasis. In addition to such a broad interpretation of immunopathology, there is another, more narrow one. According to him, immunopathology includes autoimmunization, autoallergy, and autoaggression.

The morphology of immunopathological processes includes the structural reflection of immunogenesis disorders (antigenic stimulation or immune deficiency) and local immune reactions that occur in a sensitized organism - hypersensitivity reactions.

### **Morphology of disorders of immunogenesis**

The morphology of disorders of immunogenesis (immunological homeostasis) can affect both the thymus and peripheral lymphoid tissue and is associated with two types of immune reactions - humoral and cellular.

### **Changes in the thymus gland (thymus) that occur with disorders of immunogenesis**

The thymus belongs to the central organs of the immune system, at the same time it is also a gland of internal secretion, therefore this gland is called a connecting chain - a "switch" between the immune and endocrine systems.

The main functions of the thymus (lymphopoietic, immunoregulatory, and endocrine) are performed primarily thanks to the secretion of hormones, mainly of a

polypeptide nature - thymosin, thymopoietin, thymic serum factor, etc. by its epithelial cells. The influence of the thymus on the processes of immunogenesis is also mediated by the endocrine system and regulatory T-lymphocytes - T-effectors, helpers, suppressors.

During a person's life, the thymus is subject to age-related involution, which is characterized by the slow replacement of its tissue with fatty tissue. However, at any age, islands of thymus parenchyma remain in the adipose tissue of the anterior mediastinum, and the secretion of thymic hormones and the production of T-lymphocytes are partially preserved. Age-related involution of the thymus is one of the reasons for a decrease in the activity of cellular immunity and an increase in the frequency of infectious, autoimmune, and oncological diseases in the elderly. Thymus pathology is associated with aplasia, hypo- and dysplasia, accidental involution, atrophy, thymomegaly and hyperplasia with lymphoid follicles. The development of a number of immunodeficiency syndromes, autoimmune diseases and some endocrine disorders are associated with thymus pathology.

*Aplasia, hypo-, dysplasia of the thymus* are congenital abnormalities of the development of the thymus and are accompanied by a deficiency of the cellular chain of immunity or a combined immune deficiency. Thymic hormones are not produced at all or their production is minimal. In aplasia (agenesis), the thymus is completely absent; with hypo- and dysplasia, its size is reduced; distribution to the cortex and medulla is disturbed, the number of lymphocytes is sharply reduced.

*Accidental involution of the thymus* is a rapid decrease in its mass and volume under the influence of primarily glucocorticosteroids in various stressful situations, including infectious diseases, intoxications, and injuries. At the same time, the production of thymic hormones progressively decreases, the emigration of T-lymphocytes from the thymus increases, although the main mass of them is subject to disintegration on the spot (apoptosis). The functional significance of acute involution of the thymus is unknown, but its delay ("immobile" thymus) is accompanied by a decrease in the activity of the cellular and humoral links of immunity. Accidental involution of the thymus can be reversed, but in cases of an adverse outcome leads to

atrophy of the thymus.

*Atrophy of the thymus* develops as an adverse consequence of accidental involution of the thymus and may be the cause of some acquired immunological syndromes (in chronic infectious diseases, immunosuppressive therapy). As a result of the decrease in lymphocytes and the collapse of the network of epithelial cells, the lobes of the thymus parenchyma decrease in volume, the thymic bodies become calcified, and connective and adipose tissue grows in the perivascular spaces. At the same time, the production of thymic hormones is significantly reduced.

*Thymomegaly* is characterized by an increase in the mass and volume of the thymus parenchyma above the age norm while maintaining its normal structure. It can be congenital or acquired. Congenital thymomegaly occurs more often in children, less often in adults, and is quite often associated with defects in the development of the nervous and cardiovascular systems, congenital dysfunction of the endocrine system, first of all, chronic insufficiency of the kidneys and gonads. Congenital thymomegaly, especially in infectious diseases, is accompanied by generalized hyperplasia of lymphoid tissue. At the same time, the production of thymic hormones is reduced, violations of mainly the cellular link of immunity are noted, which are close to congenital immunodeficiency syndrome.

The cause of death of patients with thymomegaly can be infectious and infectious-allergic diseases. In connection with endocrine disorders under the influence of stress factors (medical manipulations, surgical interventions), sudden death is possible.

Previously, cases of thymomegaly were united by the concept of "thymic-lymphatic condition", the basis of which was considered congenital hyperfunction of the thymus. This interpretation is inherently incorrect, therefore the term "thymic-lymphatic condition" is not used in medical everyday life. Nowadays, this condition has acquired a different meaning and reflects immunoendocrine dysfunction of various origins.

*Thymus hyperplasia with lymphoid follicles* is characteristic of autoimmune diseases. B-lymphocytes, plasma cells accumulate in the sharply expanded

intralobular perivascular spaces of the thymus parenchyma, and lymphoid follicles appear, which are not normally found there. The production of thymic hormones can be increased or decreased. Until recently, the significance of thymus hyperplasia with lymphoid follicles in the pathogenesis of autoimmune diseases was still unknown. It is assumed that damage to the thymus can be one of the reasons for the development of the autoimmune process, but secondary damage to this gland is possible.

### **Changes in peripheral lymphoid tissue that occur when immunogenesis is impaired**

Changes in peripheral lymphoid tissue are most characteristic of antigenic stimulation and its hereditary deficiency.

During antigenic stimulation (sensitization) of the body, the changes in the peripheral lymphoid tissue are unambiguous and are manifested by a macrophage reaction, hyperplasia of lymphocytes with their successive plasmacytic transformation. These changes are complemented by an increase in the permeability of microvessels, swelling of the interstitium and accumulation of protein-polysaccharide (HIK-positive) substances in it (tissue dysproteinosis). The degree of macrophage-plasmacytic transformation of lymphoid tissue reflects the stress of immunogenesis and, above all, the level of antibody (immunoglobulin) formation by plasmacytic cells.

Especially vivid changes with antigenic stimulation are manifested in the lymph nodes (primarily regional in relation to the place of arrival of the antigen) and the spleen.

A large number of plasmablasts and plasma cells appear in the lymph nodes, which increase in size, become full-blooded and swollen, in their cortical layer, in the light centers of the follicles, and in the medullary layer. They displace lymphocytes. The proliferation and desquamation of cells of the sinuses, the formation of a significant number of macrophages and protein-polysaccharide substances in the stroma is noted. The spleen increases, looks full-blooded and juicy; large follicles are clearly visible on the dissection surface. There is hyperplasia and plasmatization of both the red pulp and its follicles, the peripheral zone of which consists entirely of

plasmablasts and plasma cells. Along with plasmablasts, there are many macrophages in the red pulp.

If mainly cellular immune reactions develop in response to antigenic stimulation, then mainly sensitized lymphocytes proliferate in the lymph nodes and spleen, and not plasmablasts and plasma cells. At the same time, there is an expansion of T-dependent zones.

The same changes in the form of cellular hyperplasia and macrophage-plasmacytic transformation, and in some cases myeloma hyperplasia, are found in the bone marrow, portal tracts and sinusoids of the liver, in the interalveolar septa, perivascular and peribronchial tissue, in the interstitium of the kidneys, pancreas and intestines, intermuscular layers, adipose tissue, etc.

*Hereditary deficiency* peripheral lymphoid tissue is characterized by changes in both the spleen and especially the lymph nodes. In the spleen, the size of the follicles is significantly reduced, light centers and plasma cells are absent. Lymph nodes lack follicles and the cortical layer (B-dependent zones), only the cortical layer (T-dependent zone) is preserved. Such changes are characteristic of hereditary immunodeficiency syndromes associated with a defect in humoral immunity.

### **Immunological hypersensitivity**

*Hypersensitivity is a pathological excessively strong immune reaction to a foreign agent*, which leads to damage to body tissues. There are four different types of hypersensitivity. All forms, except for type IV, have a humoral mechanism (that is, they are mediated by antibodies); Type IV hypersensitivity has a cellular mechanism. In all forms, primary exposure to a specific antigen (sensitizing dose) causes a primary immune response (sensitization). After a short period (one or more weeks) during which the immune system is activated, a hypersensitive response occurs to any subsequent exposure to the same antigen.

*Type I hypersensitivity (immediate) (atopy; anaphylaxis)*

Mechanism of development: the first arrival of an antigen (allergen) activates the immune system, which leads to the synthesis of antibodies - IgE (reagins), which have a specific reactivity against this antigen. After that, they are fixed on the surface



membrane of tissue basophils and blood basophils due to the high affinity (affinity) of IgE to Fc receptors. Synthesis of antibodies in sufficient quantity to develop hypersensitivity continues for one or more weeks. At the next introduction of the same antigen, the interaction of the antibody (IgE) and the antigen occurs on the surface of tissue basophils or blood basophils, which causes their degranulation. From the cytoplasmic granules of tissue basophils, vasoactive substances (histamine and various enzymes involved in the synthesis of bradykinin and leukotrienes (see "Inflammation")) that cause vasodilation,

*Local manifestations* -atopy, a congenital predisposition, familial to a pathological response against certain allergens.

Skin - sudden redness, swelling (hives) and itching occurs when the allergen hits the skin; in some cases – acute dermatitis and eczema.

Mucous membrane of the nose– when inhaling an allergen (for example, plant pollen, animal wool), vasodilation and mucus hypersecretion occur in the nasal mucosa (allergic rhinitis).

Lungs -inhalation of allergens (plant pollen, dust) leads to contraction of bronchial smooth muscles and mucus hypersecretion, which leads to acute airway obstruction and suffocation (allergic bronchial asthma).

Intestine -oral ingestion of an allergen (for example, nuts, shellfish, crabs) causes muscle contraction and fluid excretion, which manifests itself in the form of spastic abdominal pain and diarrhea (allergic gastroenteritis).

*Systemic manifestations*- anaphylaxis. A rare but extremely life-threatening systemic type I hypersensitivity reaction. The entry of vasoactive amines into the bloodstream causes a contraction of smooth muscles, widespread vasodilation and an increase in vascular permeability with the release of fluid from the vessels into the tissues. The resulting peripheral vascular insufficiency and shock can lead to death within minutes (anaphylactic shock). In less severe cases, the increase in vascular permeability leads to allergic edema, which has the most dangerous manifestation in the larynx, because it can cause fatal asphyxiation.

Systemic anaphylaxis mainly occurs with the injection of allergens (for

example, penicillin, foreign serum, local anesthetics, radiopaque substances). Rarely, anaphylaxis can occur when allergens are ingested orally (shellfish, crabs, eggs, berries) or when allergens hit the skin (bee and wasp stings). In sensitized people, even a small amount of allergen can trigger the development of fatal anaphylaxis (penicillin hypersensitivity test).

### *Type II hypersensitivity*

Mechanism of development: type II hypersensitivity is characterized by the reaction of an antibody with an antigen on the surface of a host cell, which causes the destruction of this cell. The antigen can be one's own, but for some reason recognized by the immune system as foreign (at the same time, an autoimmune disease occurs). An antigen can also be external and can accumulate on the cell surface (for example, a drug can be a hapten when combined with a cell membrane protein and thus stimulate an immune response).

A specific antibody, mainly IgG or IgM, that is synthesized against an antigen, interacts with it on the cell surface and causes cell damage in several ways:

1. Cell lysis – activation of the complement cascade leads to the formation of the "membrane attacking" complex C5b6789, which causes cell membrane lysis.

2. *Phagocytosis* -the cell that carries the antigen is engulfed by phagocytic macrophages that have Fc or C3b receptors, which allows them to recognize antigen-antibody complexes on the cell.

3. Cellular cytotoxicity - the antigen-antibody complex is recognized by unsensitized "null" lymphocytes (K cells; see Immunity), which destroy the cell. This type of hypersensitivity is sometimes classified separately as type VI hypersensitivity.

4. *Change in cell function* -an antibody can react with cell surface molecules or receptors to cause either enhancement or inhibition of a particular metabolic response without causing cell necrosis (see Stimulation and Inhibition in Hypersensitivity, below). Some authors classify this phenomenon separately as type V hypersensitivity.

Manifestations of type II hypersensitivity reactions depend on the type of cell that carries the antigen. Note that transfusion reactions are actually normal immune responses against foreign cells. They are identical in the mechanism of the type II

hypersensitivity reaction and also have an adverse effect on the patient, in connection with which hemotransfusion complications are often considered together with disorders that occur with hypersensitivity.

Type II hypersensitivity occurs in hemotransfusion reactions (antibodies in the patient's serum react with antigens on erythrocytes, causing either indirect intravascular hemolysis by complement or delayed hemolysis as a result of immune phagocytosis by splenic macrophages); hemolytic disease of newborns; hemolytic reactions caused by drugs, infectious diseases (mycoplasma pneumonia, infectious mononucleosis).

*Immune complex damage.*

The third mechanism associated with the toxic effect on cells and tissues of circulating immune complexes, which leads to the activation of complement components and the development of reactions of immune complexes (immunocomplex reaction). Accumulation of immune complexes activates complement and causes acute inflammation and necrosis (Reactions such as the Artus phenomenon – with repeated administration of the rabies vaccine; reactions of the serum sickness type – repeated intake of a large amount of antigen, foreign serum proteins, drugs, viral, microbial agents).

The fourth mechanism is caused by the effect on tissues of effector cells of sensitized T-lymphocytes, which exhibit cytotoxicity either directly or through the secretion of lymphokines. Type IV hypersensitivity reactions generally occur 24-72 hours after administration of the antibody. Histological examination of tissues in which a type IV hypersensitivity reaction occurs reveals cell necrosis and pronounced lymphocytic infiltration.

Direct cytotoxicity plays an important role in contact dermatitis, in the response against tumor cells, virus-infected cells, transplanted cells, in some autoimmune diseases.

So, the first immunological mechanisms are a manifestation of humoral immunity (antibodies, complement components, circulating antigen-antibody complexes) and others of cellular immunity (lymphocytes, macrophages). This

determines the nature of hypersensitivity reactions and the principle of their classification. Reactions associated with immunopathological mechanisms, which are manifestations of humoral immunity, are called immediate-type hypersensitivity reactions (IHRT), and those associated with immunopathological mechanisms, which are manifestations of cellular immunity, are called delayed-type hypersensitivity reactions (HST). In addition, transplant immunity reactions (rejection reactions) are distinguished.

Hypersensitivity reactions are morphologically reflected in immune inflammation. It is called immune because the trigger for the development of this inflammation is an immune reaction. Immune inflammation can be acute or chronic.

*Immediate type hypersensitivity reaction* morphologically, it is a manifestation of acute immune inflammation. It is characterized by the speed of development, the advantage of alterative and vascular-exudative changes, and the slow course of reparative processes. Alterative changes concern mainly the walls of blood vessels, the main substance and fibrous structures of connective tissue. They are represented by plasma leakage, mucoid and fibrinoid swelling, fibrinoid necrosis. The appearance of coarsely dispersed proteins, fibrin, neutrophils, "digesting" immune complexes, and erythrocytes in the center of immune inflammation is associated with pronounced plasmorrhagic and vascular-exudative reactions. In this regard, fibrinous or fibrinous-hemorrhagic exudate becomes the most characteristic of GNT. Proliferative-reparative reactions in HNT develop later and are poorly expressed. They are manifested by the proliferation of cells of the endothelium and perithelium (adventitia) of vessels and over time coincide with the appearance of mononuclear-histiocytic elements, which reflects the elimination of immune complexes and the beginning of reparative processes. Evaluation of morphological changes in HNT, their belonging to an immune reaction requires evidence using the immunohistochemical method.

The most typical dynamics of morphological changes in HNT is reflected in the Arthus phenomenon, which occurs in sensitized animals upon local administration of a resolving dose of the antigen. In human pathology, GNT is the essence of many

bacterial infections, allergic diseases and processes. Manifestations of GNT with the advantage of alteration are constant in tuberculosis, syphilis, they are the basis of vascular changes in rheumatism, systemic lupus erythematosus, glomerulonephritis, nodular periarteritis, etc. Vascular-exudative manifestations of HNT are pronounced in case of croupous inflammation of the lungs.

GNT reactions are similar to so-called reagin reactions, i.e. reactions involving allergic antibodies, or reagins (IgE), fixed on cells. They are distinguished by the surface alteration of cells and tissues, which explains the lack of participation of complement in the reaction and the prevalence of vascular-exudative changes associated with massive degranulation of tissue basophils (labrocytes) and the release of histamine; the infiltrate is dominated by eosinophils - inhibitors of basophils. An example of a reagin reaction can be changes in atopic bronchial asthma.

*Delayed type hypersensitivity reaction(GST).* Two types of cells participate in this reaction - sensitized lymphocytes and macrophages. Lymphocyte and macrophage infiltration in the focus of immune conflict is a reflection of chronic immune inflammation, which is the basis of GST.

Destruction of the target cell, that is, immunologically determined cellular cytolysis, is, of course, associated with the activation of lysosomal enzymes of killer lymphocytes. At the same time, macrophages enter into a specific reaction with the antigen with the help of mediators of cellular immunity - lymphokines and cytophilic antibodies adsorbed on the surface of these cells. At the same time, contacts appear between lymphocytes and macrophages in the form of cytoplasmic bridges, which may serve to exchange information between cells about the antigen. Immunologically determined cellular cytolysis can be connected with cellular antibodies, that is, with NK- and K-cells.

Inflammation in the form of lymphohistiocytic and macrophage tissue infiltration in combination with vascular-plasmatic and parenchymatous-dystrophic processes can be recognized as immune, that is, reflecting HST, only if there is evidence of the connection of infiltrated cells with sensitized lymphocytes. This evidence can be found in histochemical and electron microscopic examination.

Clinical and morphological manifestations of HST include the following: a tuberculin-type reaction in the skin in response to the introduction of an antigen, contact dermatitis (contact allergy), autoimmune diseases, immunity to many viral and some bacterial infections (viral hepatitis, tuberculosis, brucellosis). Morphological manifestation of HST is granulomatosis.

Reactions of HNT and HST often combine or change each other, thus reflecting the dynamics of the immunopathological process.

Manifestations of transplant immunity are represented by the reaction of the recipient's body to the donor's genetic transplant, that is, the reaction of transplant rejection. Antigens of the transplant induce the formation of specific antibodies that circulate in the blood, and the production of sensitized lymphocytes, which carry out cellular invasion of the transplant. The main role in the rejection reaction is played by sensitized lymphocytes, so the manifestations of transplant immunity are similar to HST.

The morphological manifestations of the rejection reaction are reduced to the growing infiltration of the transplant mainly by lymphocytes, as well as by histiocytes due to the invasion of these cells and their reproduction in place. Cellular infiltration is accompanied by impaired blood circulation and swelling of the graft. In the end, many neutrophils and macrophages appear among the cells of the infiltrate. It is believed that immune lymphocytes that destroy transplant cells are able to saturate with its antigens, so humoral antibodies directed against transplant antigens not only bind to transplant cells, but also lyse lymphocytes. Enzymes released from activated lymphocytes destroy the transplant cells, which leads to the release of new transplant antigens. This is how the growing enzymatic destruction of the transplant is carried out. Clinical types of transplant rejection: a rapid reaction that occurs within a few minutes after transplantation; acute rejection lasts from several days to months; chronic rejection, characterized by progressive deterioration of organ function over many months or years. The rejection reaction can be suppressed using a number of immunosuppressive agents. This makes it possible to use not only an isograft (recipient and donor - twins), but also an allograft (recipient and donor - foreign),

both from a living person and from a corpse, when transplanting organs and tissues. characterized by progressive deterioration of organ function over many months or years. The rejection reaction can be suppressed using a number of immunosuppressive agents. This makes it possible to use not only an isograft (recipient and donor - twins), but also an allograft (recipient and donor - foreign), both from a living person and from a corpse, when transplanting organs and tissues. characterized by progressive deterioration of organ function over many months or years. The rejection reaction can be suppressed using a number of immunosuppressive agents. This makes it possible to use not only an isograft (recipient and donor - twins), but also an allograft (recipient and donor - foreign), both from a living person and from a corpse, when transplanting organs and tissues.

### **Autoimmunization and autoimmune diseases**

Autoimmunization(autoallergy, autoaggression) is a condition characterized by the appearance of a reaction of the immune system to normal antigens of one's own tissues.

Autoimmunization is closely related to the concept of immunological tolerance (from Latin tolerare – to bear, tolerate), which is characterized by a state of reactivity (“tolerance”) of lymphoid tissue in relation to antigens that can cause an immune response. During the maturation of lymphoid tissue, immunological tolerance to antigens of all organs and systems occurs, except for the tissues of the eye, thyroid gland, gonads and adrenal glands, brain and nerves. It is taken into account that the antigens of these organs and tissues are separated from the lymphoid tissue by physiological barriers, which explains the lack of tolerance to them by the immunocompetent system. The immune system begins to recognize "own" and "foreign" tissue antigens in a newborn a few weeks after birth. At the same time, the production of autoantibodies in a small amount constantly occurs throughout life, and autoantibodies are believed to be involved in the regulation of various body functions. their action is under the control of T-suppressors and anti-idiotypic antibodies, which prevents the development of an autoimmune process.

Among the etiological factors of autoimmunization, chronic viral infections, radiation, and genetic disorders occupy a significant place. Etiology is closely related to pathogenesis. In the pathogenesis of autoimmune diseases, there are causative, initiating and contributing factors. The causative factors should include some genes of the HLA system, which determine the quantitative and qualitative individual abilities of the immune response; the hormonal background, related, first of all, to gender (autoimmune diseases are 6-9 times more common in women than in men) and genetically determined features of the cells of the target organs of the autoimmune process. An unfavorable combination of these factors determines 50% of the risk of developing the disease. Initiating factors can be viral and bacterial infections, physical and chemical damage to both immune system organs and target organs.

Autoimmune diseases are diseases that arise as a result of autoimmunization, that is, the aggression of autoantibodies, circulating immune complexes containing autoantigens, and effector immune cells (killer lymphocytes) against antigens of the body's own tissues. Therefore, autoimmune diseases are also called autoaggressive.

Guided by the mechanism of autoimmunization, two groups of autoimmune diseases are distinguished. The first group is organ-specific autoimmune diseases that arise in connection with damage to the physiological barriers of immunologically separated organs, which allows the immune system to respond to their unchanged antigens by producing autoantibodies and sensitized lymphocytes. At the same time, morphological changes occur in the organs, which are characteristic mainly for GST - the tissue of the organs is infiltrated by lymphocytes, parenchymal elements die, and in the end, sclerosis develops. This group includes thyroiditis (Hashimoto's disease), encephalomyelitis, polyneuritis, multiple sclerosis, idiopathic Addison's disease, aspermatogenia, sympathetic ophthalmia.

The second group is organ-specific autoimmune diseases. The leading cause of these diseases is a violation of control of immunological homeostasis by the lymphoid system. At the same time, autoimmunization develops in relation to antigens of many organs and tissues, which do not have organ specificity and are not



able to cause the production of antibodies during parenteral administration. Organs and tissues develop morphological changes that are characteristic of both delayed-type and especially immediate-type hypersensitivity reactions. This group of autoimmune diseases should include systemic lupus erythematosus, rheumatoid arthritis, systemic scleroderma, dermatomyositis (a group of rheumatic diseases), secondary thrombotic thrombocytopenic purpura (Moshkovich's disease).

Autoimmune diseases of the intermediate type are also known, that is, they are close to autoimmune diseases of the first or second type. These are myasthenia gravis, type 1 diabetes, thyrotoxicosis, Sjogren's and Goodpascher's syndromes, etc.

In addition to autoimmune diseases, there are diseases with autoimmune disorders. The appearance of autoantigens in these diseases is associated with a change in the antigenic properties of tissues and organs - denaturation of tissue proteins (in case of burns, irradiation, trauma, chronic inflammation, viral infections); the formation of an autoantigen is possible under the influence of a bacterial antigen, especially a cross-reactive one (eg, in glomerulonephritis, rheumatism). In the formation of autoantigen, great importance is attached to the hapten mechanism, and the role of a hapten can be the products of the body's metabolism, as well as microorganisms, toxins, and medicinal substances. Autoimmunization in these conditions causes not the occurrence of the disease, but the progression of local (organ) changes characteristic of it, which reflect the morphology of delayed and immediate types of hypersensitivity reactions.

### **Immunodeficiency syndromes**

Immunodeficiency syndromes represent an extraordinary manifestation of the insufficiency of the immune system. They can be primary, due to underdevelopment (hypoplasia, aplasia) of the immune system - hereditary and congenital immunodeficiency syndromes, or secondary (acquired), which arise in connection with disease or treatment.

Primary immunodeficiency syndromes

Primary immunodeficiency syndromes can be a manifestation of insufficiency:

1) cellular and humoral immunity (combined)

2) cellular immunity;

3) humoral immunity.

*Syndromes of insufficient cellular and humoral immunity are called combined.* Most patients have an autosomal recessive form, occur in children and newborns (Swiss-type agammaglobulinemia, or Glanzmann-Riniker syndrome, Louis-Bar ataxia-telangiectasia). In these syndromes, hypoplasia of both the thymus and peripheral lymphoid tissue is found, the number of lymphocytes is reduced in the thymus, as well as in the lymph nodes, spleen, and peripheral blood. There are no immunoglobulins in the serum, which determines the defect of cellular and humoral immunity. In connection with insufficient immunity, such children often develop infectious diseases (viral, fungal, bacterial), which recur and cause severe complications (pneumonia, meningitis, sepsis), and physical development is delayed. In combined immunodeficiency syndromes, malformations and malignant mesenchymal tumors often occur.

*Syndromes of insufficient cellular immunity* in some cases, of course, they follow the autosomal dominant type (immunodeficiency with achondroplasia, or Mac-Cusick syndrome), in others, they are congenital (agenesis or hypoplasia of the thymus, or Dy-George syndrome). The syndrome is characterized by a lack of T-lymphocytes in the blood, in the thymus-dependent areas of the lymph nodes and spleen. Signs of insufficient cellular immunity are manifested in the form of severe viral and fungal infectious diseases in childhood. Children die from developmental defects or from complications of infectious diseases.

*Syndromes of humoral immunity deficiency* have a hereditary nature, and their linkage with the X-chromosome has been established. Children of the first five years of life are sick. Some syndromes (X-linked agammaglobulinemia or Bruton's syndrome) are characterized by the loss of the ability to synthesize all immunoglobulins, which is morphologically confirmed by the absence of B-dependent zones and cells of the plasmacytic line in the peripheral lymphoid tissue, primarily in the lymph nodes and spleen. Observed in boys, infectious diseases break up mainly in the second half of the first year of life after the level of passively

transmitted maternal antibodies falls.

Isolated InA deficiency is the most common immunodeficiency, resulting from a defect in terminal differentiation of plasma cells secreting InA. In most patients, InA deficiency is asymptomatic. Only some patients are prone to liver and intestinal infections.

### **Secondary immunodeficiency syndromes**

Secondary (acquired) immunodeficiency syndromes differ from primary ones in that they arise in connection with the disease or as a result of drug therapy.

Among the diseases that lead to the development of the immune system deficiency, acquired immune deficiency syndrome, or AIDS, which is widespread in many countries of the world, is an independent disease, the causative agent of which is a virus (see Viral diseases). The development of secondary immunodeficiency syndromes can also be caused by various infections, leukemias, malignant lymphomas (lymphogranulomatosis, reticulosarcoma), thymoma, sarcoidosis. In these diseases, there is a deficiency of humoral and cellular immunity due to a defect in the population of both B and T lymphocytes, and possibly their precursors.

Radiation therapy, the use of corticosteroids, and immunosuppressants after organ transplantation occupy a significant place among the types of treatment that lead to secondary insufficiency of the immune system.

Insufficiency of the immune system, which occurs in connection with the treatment of one or another disease, is considered as a pathology of therapy (iatrogeny).

Immunodeficiency is always accompanied by the development of opportunistic infections and at the final stage, most often Kaposi's sarcoma and malignant B-cell lymphomas. The occurrence of infectious diseases depends on the type of immunodeficiency. A decrease in the number of T cells predisposes to the development of infectious diseases caused by viruses, mycobacteria, and fungi. Deficiency of B cells predisposes to the development of purulent bacterial infectious

diseases

The emergence of malignant neoplasms can be associated with either a violation of the immune response aimed at removing malignant cells, or with the nominal stimulation of the damaged immune system, when the normal control of cell proliferation is disturbed.

## **ADAPTATION AND COMPENSATION PROCESSES. REGENERATION AND REPAIR. SCLEROSIS.**

Adjustment (adaptation) is the processes of vital activity, thanks to which the relationship of the organism with the external environment is carried out. The device is aimed at preserving the species, therefore it covers both health and disease.

Compensation is a private manifestation of adaptation, aimed at correcting the impaired function during illness ("self-preservation" in a critical situation).

Adaptive and compensatory reactions of the whole organism, which vary quantitatively and change qualitatively, take place in all its diseases.

All compensatory and adaptive processes are based on two basic principles of living systems: 1) constancy of preservation of form and function under changing conditions of existence (homeostasis); 2) mobility and variability of form and function in the process of adaptation to environmental conditions.

These two properties are fixed in the process of phylo- and ontogenesis at different levels of organization (molecular, cellular, tissue, organ, system, organismic).

At the molecular level of organization, compensatory and adaptive reactions are ensured by: 1) high-quality stability of protein metabolism; 2) its wide quantitative fluctuations; 3) the presence of a general plastic reserve of cells (stock of structurally organized proteins, stock of RNA, ability for rapid synthesis of RNA, DNA reproduction); 4) reversibility of differentiation of structure and function.

Mechanisms of regulation of the molecular level of the organization of compensatory and adaptive processes: 1) enzymatic; 2) humoral (selective action of a set of metabolites, hormones); 3) nervous.

At the cellular level of the organization, compensatory and adaptive reactions

are provided by: 1) the general plastic reserve of the cell; 2) a large supply of cells and their ability to alternate between work and rest; 3) the ability of the cell to reproduce; 4) their ability to metaplasia.

At the organ level: 1) a reserve of functional units of the organ; 2) heterogeneity of their functions; 3) the ability to regenerate functional units.

At the systemic level: quantitative wide fluctuations of structure and function.

All the above-listed levels of organization of compensatory and adaptive reactions ensure the adaptation of the organism as a whole to the action of the environment.

Three phases were identified in their development:

1. The genesis of compensation or the phase of formation of compensation. At this moment, the functions are sharply strained, the metabolism is excited, the reserves may not be enough, and dystrophic changes, hypoxia, develop at first. This phase is sometimes called the emergency phase.

2. Fixation phase. Compensatory and adaptive reactions are fully developed. Dystrophic changes decrease, protein synthesis begins to increase, the weight and mass of organs increases, function sometimes increases by 50-100-150%.

3. Exhaustion phase. Exhaustion always occurs after increased work. Sooner or later, but always. Since ATP resynthesis is weakened. When all ATP is used, the function stops completely.

Adaptation in pathology can reflect various functional states: functional tension, reduction or disruption of tissue (organ) function. In this regard, it can be manifested by various pathological processes: 1) atrophy; 2) hypertrophy (hyperplasia); 3) organization; 4) reconstruction of tissues; 5) metaplasia; 6) dysplasia.

*Atrophy*- lifelong decrease in the volume of cells, tissues, organs with suspension or termination of their function, but not every decrease in the organ refers to atrophy. In connection with a violation in the process of ontogenesis, the organ may be completely absent - agenesis; preserve the appearance of the early embryo - aplasia; not reaching full development - hypoplasia. If there is a decrease in all organs

and a general underdevelopment of all body systems, then they speak of dwarfism.

Physiological and pathological atrophy are distinguished. Physiological atrophy is observed throughout a person's life. Thus, after birth, the umbilical arteries atrophy and are subject to obliteration, the gonads atrophy in the elderly, the bones and intervertebral cartilages in the elderly. Pathological atrophy occurs for various reasons; among which the most important are insufficient nutrition, disorders of blood circulation and activity of endocrine glands, central and peripheral nervous system, intoxication. After eliminating the causes that caused atrophy, if it has not reached a high degree, a complete restoration of the structure and function of the organ or system is possible.

Pathological atrophy can be both general and local. General atrophy, or exhaustion, occurs in the form of alimentary exhaustion (with starvation or impaired absorption of food); exhaustion with cancer cachexia; exhaustion with pituitary cachexia; with cerebral cachexia (damage to the hypothalamus), as well as with other diseases (chronic infections, such as tuberculosis, dysentery, brucellosis, etc.). The characteristic appearance of patients with exhaustion is a sharp weight loss, a decrease in body weight, there is no subcutaneous adipose tissue; where it is preserved, it has a brownish color (accumulation of lipochrome pigment). Muscles are atrophic, the skin is dry, flabby; internal organs are reduced in size. Brown atrophy (accumulation of lipofuscin pigment in cells) occurs in the liver and myocardium. In endocrine glands, atrophic and dystrophic changes differ in their intensity depending on the cause of exhaustion; in bones - osteoporosis; in the cerebral cortex - cells of dead nerve cells.

Local atrophy occurs for various reasons. The following types are distinguished: dysfunctional; caused by insufficient blood supply; from squeezing; neurotic; under the influence of physical and chemical factors.

Dysfunctional atrophy - occurs as a result of a decrease in the function of an organ - muscle atrophy in case of bone fractures, joint diseases, when movements are limited; optic nerve after surgical removal of the eye; edges of the tooth cell after tooth extraction. At the same time, the intensity of metabolism in the tissues is

reduced, they receive an insufficient amount of blood and nutrients.

Atrophy from insufficient blood supply occurs as a result of narrowing of arteries; insufficient blood flow leads to hypoxia, as a result of which the activity of parenchymal organs decreases, the size of cells decreases. Hypoxia stimulates the proliferation of fibroblasts with subsequent development of sclerosis. Such a process is observed in the myocardium, when atrophy of myocytes and diffuse fibrosclerosis occur with progressive atherosclerosis of the coronary arteries; with sclerosis of kidney vessels, atrophy and shrinkage of the kidneys develop.

Atrophy from compression can develop even in organs consisting of dense tissue. With long-term compression, tissue integrity disorders occur (wrinkles in the bodies of the vertebrae and in the sternum when in contact with an aneurysm of the aorta). Atrophy from compression occurs in the kidneys when the outflow of urine is difficult. The basis of atrophy from compression is insufficient blood flow to cells and hypoxia that occurs in connection with this.

Neurotic atrophy is due to a violation of the connection between the organ and the nervous system, which occurs when the nerve conductors are destroyed. Most often, this type of atrophy occurs in striated muscles due to the death of motor neurons of the anterior horns of the spinal cord or nerve trunks that innervate these muscles (in poliomyelitis, inflammation of the facial nerve).

Atrophy under the influence of physical and chemical factors is quite common. Under the influence of radiation energy, atrophy is especially pronounced in the bone marrow and genitals. With long-term use of ACTH and corticosteroids, atrophy of the cortex of the adrenal glands may occur and their insufficiency may develop.

The appearance of organs with local atrophy is diverse. In most cases, the size of organs decreases, the surface is smooth (smooth atrophy). Less often, organs, such as kidneys, liver, acquire a granular appearance (granular atrophy). With hydronephrosis, hydrocephalus, pseudohypertrophy, the organs are enlarged, but not due to parenchymal elements, but due to the accumulation of fluid or the growth of fatty tissue. Sometimes this fiber grows around the atrophied organ (kidney).

The value of atrophy for the body is determined by the degree of reduction of

the organ and decrease in its function. If atrophy and sclerosis do not reach a significant degree, then after eliminating the cause that caused the atrophy, it is possible to restore the structure and function, which was discussed above. Under certain conditions, an atrophied organ may even undergo hypertrophy over time.

Hypertrophy (hyperplasia) can have an adaptive nature - an increase in the volume of a cell, tissue, or organ due to cell proliferation or an increase in the number and size of intracellular ultrastructures. Two types of hypertrophies should be classified as adaptive: neurohumoral hypertrophy (hyperplasia) and hypertrophic growths.

Neurohumoral hypertrophy and hyperplasia occur when the function of the endocrine glands is disturbed (hormonal or correlative hypertrophy and hyperplasia). The physiological prototype of such hypertrophy and hyperplasia, which have an adaptive value, can be the hypertrophy of the uterus and mammary glands during pregnancy and lactation. In conditions where ovarian dysfunction occurs, hyperplasia of the glands develops in the mucous membrane of the uterus, sometimes with cystic expansion of their lumen - the so-called glandular-cystic hyperplasia of the endometrium, which is accompanied by irregular uterine bleeding. With atrophic processes in the testicles in the chest gland of men, hyperplasia of the glandular lobes develops, which leads to an increase in the size of the entire gland - gynecomastia. Hyperfunction of the anterior lobe of the pituitary gland, which occurs with its adenoma, accompanied by an increase in organs and protruding parts of the skeleton - occurs. Correlative hypertrophies and hyperplasias, which arise as a reaction to certain hormonally determined stimuli, are often the basis for the development of the tumor process.

Hypertrophic growths, which lead to an increase in the size of tissues and organs, arise due to various reasons. They are quite common in chronic inflammation (e.g., in mucous membranes with the formation of polyps), in disorders of lymphatic circulation in the lower extremities and lymph stagnation, which leads to the growth of connective tissue (elephantitis). Hypertrophic growth of fat and connective tissue occurs with partial or complete atrophy of the organ (false hypertrophy). Thus, with



muscle atrophy, fatty tissue grows between their fibers; with atrophy of the kidney, the growth of adipose tissue around it increases; with brain atrophy, the bones of the skull thicken; when the blood pressure in the vessels decreases, the intima grows and thickens.

All the processes of hypertrophic growth of supporting tissue listed above, filling the place previously occupied by an organ or tissue, are called vacant hypertrophy.

*Organization*, as one of the forms of manifestation of adaptation, it represents the replacement of the center of necrosis or thrombus by connective tissue, as well as encapsulation. The replacement of the center of necrosis or thrombotic masses by connective tissue (organization itself) occurs when the masses are subject to resorption and at the same time young connective tissue grows in them, which then turns into a scar. They talk about encapsulation in those cases when dead masses, animal parasites, foreign bodies are not resorbed, but become covered with connective tissue and are separated from the rest of the organ by a capsule. Masses of necrosis are permeated with lime; petrifications occur. Sometimes bone tissue is formed in the inner layers of the capsule by metaplasia. Multinucleated giant cells (giant cells of foreign bodies) are formed around foreign bodies and animal parasites in the granulation tissue.

Hyperplasia, regeneration and accommodation are the basis of adaptive tissue remodeling. An example of reconstruction can be collateral blood circulation, which occurs when the flow of blood in the main vessels is obstructed. With it, there is an expansion of the lumen of the veins and arteries that depart from the affected main vessel, thickening of the walls due to muscle hypertrophy and neoplasms of elastic fibers. The structure of small vessels takes on the character of larger ones. Reconstruction of the spongy substance in the bones is observed when the direction of the load on the bone is changed (after a fracture, with rickets, joint diseases). Tissue remodeling occurs in some tissues under changed conditions of their existence. For example, in the lungs, in the foci of atelectasis, the compacted alveolar epithelium acquires a cubic shape due to the cessation of air flow. Nephrothelium,

which covers the cavity of the capsule of the renal glomerulus, when it is excluded from its function, it becomes cubic. Such changes in the epithelium are called histological accommodation.

*Metaplasia*- the transition of one type of tissue to another, related to it. Metaplasia is most often found in the epithelium and connective tissue, less often in other tissues. Reconstruction of one tissue into another is possible within one germ layer and develops during the proliferation of young cells (during regeneration, neoplasms). Metaplasia always occurs in connection with the previous proliferation of undifferentiated cells, that is, it is indirect. Heterotopia or heteroplasia, when the epithelium does not appear in the usual place due to a developmental defect, should not be taken for metaplasia.

Epithelial metaplasia is most often manifested as the transformation of a prismatic epithelium into a flat one with keratinization (epidermal or squamous epithelial metaplasia). It is observed in the respiratory tract with chronic inflammation, with a deficiency of vitamin A in the pancreas, prostate, mammary, and thyroid glands, in the appendix of the testicle with inflammation and hormonal influences. Metaplasia begins with the proliferation of cambial cells, which differentiate in the direction of not prismatic, but multilayered flat epithelium. The transition of a multi-layered flat epithelium without cornification into a cylindrical one is called prosoplasia. Metaplasia of the stomach epithelium into the intestinal epithelium (intestinal metaplasia or enterolization of the gastric mucosa) is possible, as well as metaplasia of the intestinal epithelium into the gastric epithelium (gastric metaplasia of the intestinal mucosa).

The term "dysplasia" as a kind of adaptive process is often used in oncomorphology. It is characterized by significant violations of the proliferation and differentiation of the epithelium with the development of cellular atypia and a violation of histoarchitectonics. Cellular atypia is represented by a different size and shape of cells, an increase in the size of the nuclei and their hyperchromia, an increase in the number of mitotic figures, and the appearance of atypical mitoses. Violation of histoarchitectonics in dysplasia manifests itself as a loss of the polarity

of the epithelium, and sometimes of its properties that are characteristic of a given tissue or a given organ (loss of histo- or organ-specificity of the epithelium). The basement membrane is not disturbed. Thus, dysplasia is not a cellular concept, but a tissue concept.

Depending on the degree of proliferation and the state of cell and tissue atypia, three stages (degrees) of dysplasia are distinguished: I - mild (minor), II - moderate (medium), III - severe (significant). Most often, dysplasia occurs during inflammatory and regenerative processes and reflects a violation of cell proliferation and differentiation.

*Compensation*- the reaction of the organism (system, organ, tissue, cell), the manifestation of which is the correction of impaired functions during the disease. The compensatory process proceeds in stages; three phases are distinguished in it: formation, consolidation and exhaustion. The phase of formation of compensation, which is also called the "emergency" phase, is characterized by the inclusion of all structural reserves and changes in the metabolism of the organ (system) in response to the pathogenic influence. In the fixation phase, the compensatory possibilities are revealed to the fullest - there is a restructuring of the structure and exchange of the organ (system), which ensures their function under conditions of increased load. This phase can last quite a long time. However, depending on many conditions (age of the patient, duration, severity of the disease, nature of treatment, etc.), the insufficiency of compensatory capabilities develops, which characterizes the exhaustion phase of compensation or decompensation (eg, decompensated heart disease, decompensated liver cirrhosis). The development of the phases of the compensated process (establishment, consolidation and depletion of decompensation) is determined by a complex system of reflex acts of the nervous system, as well as humoral influences. In this regard, during decompensation, it is very important to look for its cause not only in the diseased organ, but also outside it, among those mechanisms that regulate its activity.

Morphologically, compensation is mainly manifested by hypertrophy. At the same time, the organs increase in size, but retain their configuration. The cavity of the

organ either becomes wide (eccentric hypertrophy) or decreases (concentric hypertrophy). In the cells of a hypertrophied organ, structural and functional changes are observed, which indicate an increase in the intensity of metabolism. The enhanced function of the hypertrophied organ occurs due to an increase in the number of its specific intracellular formations; and in some cases this process unfolds on the basis of pre-existing cells and leads to an increase in their volume (hypertrophy), in others it is accompanied by the formation of new cells (cellular hyperplasia).

There are two types of compensatory hypertrophy: working (compensatory) and vicarious (replacement).

Working (compensatory) hypertrophy develops with increased work of the organ, while there is an increase in the volume (number) of cells that determine its specialized function. Work-related hypertrophy is observed under increased load and in physiological conditions (hypertrophy of the heart and hypertrophy of skeletal muscles in athletes and people engaged in physical labor). In diseases, increased work of the organ is necessary in cases of defects in it, which are compensated by increased work of parts of the organ that have preserved their structure and function. Working hypertrophy occurs in the heart, gastrointestinal tract, urinary tract and other organs. Hypertrophy of the heart is the most vivid example of compensatory hypertrophy and reaches the highest degrees in congenital and acquired heart defects, which are accompanied by stenosis of the atrioventricular openings and peripheral vascular tracts of the ventricles, with arterial hypertension, narrowing of the aorta, sclerosis of pulmonary vessels, etc. The myocardium is subject to hypertrophy mainly, which performs the main work in specific conditions of impaired blood circulation (left ventricle with aortic valve defects; right ventricle with mitral valve defect). At the same time, the weight of the heart can exceed the normal weight by 3-4 times and reach 900-1000 g. The size of the heart also increases. Hypertrophy of the myocardium occurs due to an increase in the mass of the sarcoplasm of myocytes, the size of their nuclei, the number and size of myofibrils and mitochondria, that is, hyperplasia of intracellular ultrastructures occurs. At the same time, the volume of muscle fibers increases. Simultaneously with the hypertrophy of

the myocardium, there is a concomitant hyperplasia of the fibrous structures of the stroma, intramural vascular branches and the nervous system of the heart. So, at the heart of myocardial hypertrophy are the processes that run together in muscle fibers, stroma of the myocardium, its vascular system and intramural nervous system. Each of them is an integral part of the concept of "hypertrophied heart" and ensures its participation in the development and maintenance of the increased work of the heart over a long, sometimes multi-year period.

With compensated myocardial hypertrophy, the length of the heart increases due to the distal tract (from the base of the semilunar valves of the aorta to the most distant point of the apex of the heart); the supply tract (from the apex of the heart to the place of attachment of the back sail of the bicuspid valve) does not change. There is an expansion of the heart cavities, which is defined as active compensatory or tonogenic.

The development of compensatory hypertrophy is facilitated not only by mechanical factors that impede blood flow, but also by neurohumoral influences. The full implementation of compensatory hypertrophy requires a certain level of innervation of the heart and hormonal balance. Hypertrophy of the wall of the stomach or intestine occurs above the area of narrowing of their lumen. The smooth muscle layer of their wall hypertrophies, functional capacity is preserved. The lumen of the cavity above the narrowing is widened. After some time, the compensation phase is replaced by decompensation due to the failure of the hypertrophied muscle layer. Bladder wall hypertrophy occurs with prostate hyperplasia (adenoma), which narrows the urethra, and other complications of bladder emptying. The bladder wall thickens, muscular trabeculae are visible on the side of the mucous membrane (trabecular hypertrophy).

Vicarious (substitute) hypertrophy is observed when one of the paired organs (lungs, kidneys) dies due to disease or after surgery. Compensation of the impaired function is provided by increased work of the preserved organ, which is subject to hypertrophy. Vicarious hypertrophy is similar to regenerative hypertrophy in its pathogenetic essence and significance for the body. A complex of reflex and humoral

influences plays a significant role in its occurrence, as in the case of compensatory hypertrophy.

*Regeneration*- restoration of tissue structural elements instead of dead ones. In the biological sense, regeneration is an adaptive process developed in the course of evolution and characteristic of all living things. Restoration of structure and function can occur with the help of cellular or intracellular hyperplastic processes. On this basis, cellular and intracellular forms of regeneration are distinguished. The cellular form of regeneration is characterized by mitotic and amitotic cell reproduction; for the intracellular form of regeneration, which can be organoid and intraorganoid - an increase in the number (hyperplasia) and size (hypertrophy) of ultrastructures (nuclei, nucleolus, mitochondria, ribosomes, Golgi complex) and their components. The intracellular form of regeneration is universal, because it is characteristic of all tissues and organs. However, the structural and functional specialization of organs and tissues in phylo- and ontogenesis "selected" for some the predominantly cellular form, for others - predominantly or exclusively intracellular, for the third - equally both forms of regeneration. The advantage of one or another form of regeneration in the relevant organs and tissues is determined by their functional purpose, structural and functional specialization.

The morphogenesis of the regenerative process consists of two phases - proliferation and differentiation. These phases are especially well expressed in the cellular form of regeneration. In the proliferation phase, young, undifferentiated cells multiply. These cells are called cambial cells, stem cells and precursor cells. Each tissue is characterized by its own cambial cells, which differ in the degree of proliferative activity and specialization; however, one stem cell can be the progenitor of several types of cells (stem cell of the hematopoietic system, lymphoid tissue, some cellular representatives of connective tissue).

In the differentiation phase, young cells mature, their structural and functional specialization occurs. The same change in hyperplasia of ultrastructures by their differentiation is the basis of the mechanism of intracellular regeneration.

The development of the regenerative process depends on a number of general

and local conditions or factors. General factors should include age, constitution, nature of nutrition, state of metabolism and hematopoiesis; to local ones - the state of innervation, blood and lymph circulation in the tissue, the proliferative activity of its cells, the nature of the pathological process.

There are three types of regeneration: physiological, reparative and pathological.

*Physiological regeneration* occurs throughout life and is characterized by constant renewal of cells, fibrous structures and the main substance of connective tissue. There are no such structures that are not subject to physiological regeneration. Where the cellular form of regeneration predominates, cell repair takes place. This is how the covering epithelium of the skin and mucous membranes, the secretory epithelium of the exocrine glands, cells that line the serous and synovial membranes, cellular elements of connective tissue, erythrocytes, leukocytes and blood platelets, etc., are constantly changing. In tissues and organs, where the cellular form of regeneration is lost, intracellular structures are restored. Together with the restoration of cells and subcellular structures, there is constant biochemical regeneration, that is, restoration of the molecular composition of all body components.

*Reparative or restorative regeneration* observed in various pathological processes that lead to damage to cells and tissues. The mechanisms of reparative and physiological regeneration are the same; reparative regeneration is nothing more than enhanced physiological regeneration. However, due to the fact that reparative regeneration is stimulated by pathological processes, it has qualitative morphological differences. Reparative regeneration can be complete or incomplete. Full regeneration, or restitution, is characterized by filling the defect with tissue identical to the dead tissue; it develops mainly in tissues where cellular regeneration prevails. In case of incomplete regeneration, i.e. tissue healing with a scar, hypertrophy occurs as an expression of the regenerative process, therefore it is called regenerative; it contains the biological meaning of reparative regeneration.

We are talking about pathological regeneration in cases where, for one reason or another, there is a distortion of the regenerative process, a violation of the change

in the phases of proliferation and differentiation. A manifestation of pathological regeneration is the excessive or insufficient formation of regenerative tissue (hyper- or hyporegeneration), as well as the transformation of one type of tissue into another during the regeneration process, excessive regeneration of peripheral nerves and excessive formation of bone callus during fracture growth, slow wound healing and epithelial metaplasia in the cell chronic inflammation. Pathological regeneration mostly develops in the event of violations of general and local conditions of regeneration (innervation disorders, protein and vitamin starvation, chronic inflammation, etc.).

Pathological regeneration is observed in cases where there is a violation of the phases of cell proliferation and differentiation.

Pathological regeneration is manifested either in excess or insufficient formation of regenerating tissue, as well as transformation during regeneration of one type of tissue into another (metaplasia). Examples of pathological regeneration can be the formation of a colloid scar on the skin, the formation of a bone callus during the fusion of fractures, sluggish wound healing, metaplasia (transformation) of the gastric epithelium into intestinal epithelium in chronic gastritis, etc.

### **Features of regeneration of individual organs and tissues.**

*Blood.* The appearance of red bone marrow in long tubular bones and its replacement by yellow; the appearance of extraosseous (extramedullary) hematopoiesis in the spleen, liver, lymph nodes, mucous membranes, adipose tissue, etc.; sharp inhibition of regeneration. The bone marrow. Has very high plastic properties; restores with significant damage.

*Lymph nodes.* It regenerates well only in those cases when the connections between the vessels that bring and take away the lymph are preserved.

*Spleen.* It regenerates incompletely with the formation of a scar.

*Microvessels.* They are regenerated by budding (the appearance of protrusions on the vessel wall from the sides with the subsequent formation of a lumen in them) or autogenous neoplasm (differentiation of connective tissue cells into endothelium and other elements of the vessel wall).



*Large vessels.* Only the intima regenerates, and the elements of the middle and outer membranes are replaced by connective tissue, which leads to the narrowing and obliteration of the vessel lumen.

*Adipose tissue.* Regenerates at the expense of connective tissue cells, which turn into fat by accumulating lipids in the cytoplasm or at the expense of nuclear-containing cytoplasmic remnants of fat cells.

*Bone tissue.* In an uncomplicated bone fracture (when bone fragments are immobile), primary bone fusion occurs: a preliminary connective tissue callus is formed; after growth and proliferation of osteoblasts, a bone callus is formed; further maturation and formation of the final bone callus occurs, which differs in its composition from bone tissue only in the disorderly arrangement of bone beams. After the bone begins to perform its function, bone tissue is rebuilt, bone marrow appears, innervation and vascularization are restored. In case of a complicated fracture (many fragments, mobile bone fragments), secondary bone fusion occurs: first, cartilage tissue is formed between the fragments, on the basis of which bone (previous osteocartilaginous callus) is built, which later turns into mature bone.

*Cartilaginous tissue.* It regenerates incompletely with the formation of a scar.

*Smooth muscle tissue.* In case of minor defects, it regenerates completely, in case of significant defects, it is replaced by connective tissue. At the same time, the preserved muscle fibers undergo hypertrophy.

*Striated muscle tissue.* Regenerates only if the cell membrane (sarcolemma) is preserved. If the sarcolemma is damaged, a scar appears on the site of the dead muscle cells, and the intact muscle cells nearby undergo hypertrophy. Sometimes satellite cells (cambial) are located next to muscle cells and they ensure the recovery of muscle tissue.

*Epithelium* (skin, mucous membranes, mesothelium). It regenerates in most cases completely because it has a high regenerative capacity. In the event of violations of the regeneration of the epithelium, non-healing ulcers are formed, which often turn into cancer.

*Specialized epithelium of organs* (liver, pancreas, kidneys, endocrine glands,

alveoli). Regenerates according to the type of regenerative hypertrophy - in the areas of damage, the tissue is replaced by a scar, and on the periphery, hyperplasia and hypertrophy of parenchyma cells occurs.

*Nervous System.* Neurons do not regenerate when they are damaged. If the membrane is not destroyed, intracellular regeneration is possible. Neuroglial cells regenerate completely, most often with the formation of glial nodes. Peripheral nerves regenerate completely.

### **Wound healing**

Types of wound healing: 1) direct closure of the epithelial cover defect; 2) healing under the scab; 3) wound healing by primary tension; 4) wound healing by secondary tension (after suppuration).

*Direct closure of the defect of the epithelial cover* is the simplest healing, which consists in "creeping" the epithelium on the surface defect and covering it with an epithelial layer.

*Healing under the scab*- this is healing under a crust (scab) from salted blood and lymph. The crust falls off after 3-5 days, during which time the proliferating epithelium has time to close the defect.

*Healing by primary tension* observed in wounds with damage not only to the skin, but also to the underlying tissue. The edges of the wound should be even. The wound is filled with blood clots, after a day these clots are removed (primary cleansing) and the proliferation of granulation tissue begins, which matures and is covered with epithelium by 10-15 days. A delicate scar remains at the site of such a wound.

*Healing by secondary tension* observed in large wounds, which are accompanied by crushing and death of tissues with the addition of infection. During the first 5-6 days, separation of necrotic masses occurs (secondary cleaning of the wound) and the beginning of the development of granulation tissue, followed by closure of the defect with epithelium. A rough scar forms at the site of such a wound.

*Sclerosis*- this is excessive growth of dense connective tissue, causing diffuse or focal compaction of the organ. In sclerosis, connective tissue replaces parenchymal

elements of internal organs or specialized structures of connective tissue, which leads to a decrease or loss of function of an organ or tissue.

*Cirrhosis* is a pronounced sclerosis of the organ with its deformation and reconstruction.

*Scar* is a local area of sclerosis that replaces a wound or area of necrosis.

The triggering factor of sclerosis is most often hypoxia.

Etiology of sclerosis: 1) chronic productive inflammation of infectious-allergic or immunopathological genesis, as well as caused by foreign objects; 2) systemic (rheumatic diseases, systemic congenital dysplasia, etc.) and local (colloid, Dupuytren's contracture, etc.) disorganization of connective tissue; 3) necrosis and atrophy of organs and tissues followed by their replacement by connective tissue.

The mechanism of sclerosis: 1) new formation of young connective tissue due to the proliferation of fibroblasts and their production of collagen; 2) transformation of young connective tissue into fibrous tissue.

By reversibility, sclerosis is divided into: 1) labile (reversible after the action of a pathogenic factor); 2) stable (irreversible or partially reversible for a long time or as a result of treatment); 3) progressive (irreversible under any circumstances).

**Materials on the activation of students of higher education during the lecture: questions, situational tasks, etc (if necessary):**

The 38-year-old patient died during an attack of bronchial asthma, which could not be stopped. During the histological examination, accumulation of mucus was found in the lumen of the bronchi, in the wall of the bronchi there are many mast cells (mastocytes), many of them in a state of degranulation, as well as many eosinophils. What is the pathogenesis of these changes in the bronchi?

A) Atopy, anaphylaxis

B) Cytotoxic, cytolytic effect of antibodies

C) Immune complex mechanism

D) Cellularly determined cytolysis

E) Granulomatosis

An animal sensitized by tuberculin, intraperitoneally administered tuberculin. After 24 hours, at laparotomy, venous hyperemia and edema of the peritoneum were revealed. There are a large number of lymphocytes and monocytes in smears-prints from the peritoneum. What is the pathological process in the animal?

A) Allergic inflammation

- B Serous inflammation
- Purulent inflammation
- D Fibrinous inflammation
- Aseptic inflammation

In a 31-year-old patient, after the treatment of phlegmon of the cheek (due to a cut during shaving), regional submandibular lymph nodes were enlarged for a long time. A biopsy of one of them revealed full blood, swelling in the cortical and brain layers, and in the expanded follicular centers - macrophage-plasmacytic infiltration. The immunogram shows an increased content of B-lymphocytes with a decrease in the level of T-lymphocytes. What is the pathology in the lymph nodes?

- Lymphadenitis
- B Lymphogranulomatosis
- Lymphosarcoma
- Hyperplasia of the lymph node
- E-

A 23-year-old patient developed a urinary syndrome (hematuria, proteinuria, leukocyturia) after having angina. A puncture biopsy of the kidneys revealed a pattern of intracapillary proliferative glomerulonephritis, and electron microscopy revealed large subepithelial deposits. What is the pathogenesis of this disease?

- A Immunocomplex mechanism
- Atopy, anaphylaxis with the formation of IgE and their fixation on mast cells
- Cytotoxic, cytolytic effect of antibodies
- D Cellularly determined cytolysis
- Granulomatosis

A 10-year-old child underwent a Mantoux test (with tuberculin). After 48 hours, a papule up to 8 mm in diameter appeared at the site of tuberculin injection. What type of hypersensitivity reaction developed after tuberculin administration?:

- Artyus phenomenon
- B Atopic reaction
- Serum sickness
- Hypersensitivity type IV (HRT)
- Anaphylaxis

Women suffering from diabetes turn to a surgeon with complaints about the presence of ulcers on the skin of both lower legs that do not heal for a long time. The surgeon decided that the process is a manifestation of:

- And Atrophy
- B Reparative regeneration
- C Pathological regeneration
- D Metaplasia
- E Organization

The patient has a deep torn wound with uneven edges, covered with pus. Marginal areas of juicy granulation tissue that does not rise above the level of damage. What wound healing:

- And Healing under the scab.
- B Primary tension healing.

- C Focal agglutination
- D Immediate closure of the epithelial tissue defect.
- E Organization of the wound.

In the bronchus biopsy of a patient who abused smoking, chronic inflammation and transformation of a single-layered ciliated epithelium into a multi-layered flat epithelium was revealed in the thickened mucosa. Which process is most likely?:

- A Metaplasia
- B Epithelial hypertrophy
- C Squamous cell carcinoma
- D Epithelial hyperplasia
- E Leukoplakia

When examining from the oral cavity to the mucous membrane of the cheek, a dense whitish spot with a diameter of about 1 cm was found, which is slightly raised above the level of the mucous membrane. What is the name of this painful process?:

- A Leukoplakia
- B Erythroplakia
- C Organization
- D Muroid edema
- E Carnification

After a traumatic injury to the liver, the structure and function of the liver fully recovered over time. What do you call this type of regeneration?:

- A Restitution
- B Pathological regeneration
- C Transformation
- D Normal physiological regeneration
- E Replacement

### **General material and bulk-methodological support of the lecture:**

### **Questions for self-control:**

### **References:**

Main:

1. Atlas of micropreparations in pathomorphology / I.I. Starchenko, B.M. Filenko, N.V. Royko, etc.; VDZU "UMSA". - Poltava, 2018. - 190 p
2. Starchenko, S.O. Bilokon and others.. – Poltava: Tov. "ASMI" - 2018. - 190 p.
3. The basics of pathology according to Robbins: in 2 volumes. Volume 1 /

- Vinay Kumar, Abul K. Abbas, John C. Astaire; translation of the 10th Eng. edition. Publisher: All-Ukrainian specialized publishing house "Medytsyna". – X II. - 2019. - 420 p.
4. The basics of pathology according to Robbins: in 2 volumes. Volume 1 / Vinay Kumar, Abul K. Abbas, John C. Astaire; translation of the 10th Eng. edition. Publisher: All-Ukrainian specialized publishing house "Medytsyna". – X II. - 2019. - 420 p.
  5. Pathomorphology. General pathomorphology: a study guide / edited by Ya. Ya. Bodnara, V.D. Voloshina, A.M. Romanyuk, V.V. Gargin. - New Book, 2020. - 248 p.
  6. Pathomorphology of the main diseases of the cardiovascular system: study guide / I.I. Starchenko, B.M. Filenko, N.V. Royko – Poltava: "UMSA". - 2019. - 150 p.
  7. I.I. Starchenko Pathomorphology of the main diseases of the maxillofacial region: academician. manual / I.I. Starchenko, B.M. Filenko, V.V. Chernyak ; "UMSA". – Vinnytsia: Nova Kniga, 2019. – 128 p.
  8. Starchenko I.I. Special pathomorphology (basic course) for students of medical faculties of higher medical educational institutions of III-IV levels of accreditation / I.I. Starchenko, N.V. Royko, B.M. Filenko. – Poltava, 2017. – 174 p.
  9. Tuffaha S. A. Muin Immunohistochemistry in tumor diagnostics / S. A. Tuffaha Muin, S. G. Hychka, Gusky Hans. - "Book Plus", 2018. - 336 p.
  10. Essentials of pathology: textbook / Ya. Bodnar, A. Romanyuk, V. Voloshyn, V. Gargin - Kharkiv, "Planeta-Print" Ltd, 2020, 219 p.
  11. Pathology: textbook / IVSorokina, VD Markovskyi, DI Halata et al.; edited by IVSorokina, VD Markovskyi, DI Halata. - Kyiv: AUS Medicine Publishing, 2019. - 328p. + 2 color inserts (8p. + 12p.).
  12. Pathology: textbook / IVSorokina, VD Markovskyi, DI Halata et al.; edited by IVSorokina, VD Markovskyi, DI Halata. - 2nd edition. - Kyiv: AUS Medicine Publishing, 2020. - 328p. + 2 color inserts (8p. + 12p.).

Additional:

1. Benign neoplasms of bones of the maxillofacial area in children / P.I. Tkachenko, I.I. Starenko, S.O. Bilokin [and others] - P.: "UMSA", 2016. - 85 p
2. General pathomorphology / I.I. Starchenko, N.V. Royko, B.M. Filenko [et al.] – Poltava, 2016. – 136 p.
3. Zerbino D. D. Pathomorphology and histology: an atlas / D. D. Zerbino,

- M. M. Bagrii, Y. Ya. Bodnar, V. A. Dibrova. – Vinnytsia: Nova Kniga, 2016. – 800 p.
4. Methods of morphological research / M.M. Baghrii, V.A. Dibrova, O.G. Papadynets, M.I. Grischuk; edited by M.M. Baghria, V.A. Dibrov – Vinnytsia: Nova Kniga, 2016. – 328 p.
  5. Novoseltseva T.V. Pathology of sexual and endocrine systems / T.V. Novoseltseva, B.M. Filenko, N.I. Hasiuk - Poltava: LLC "ASMI", 2015. - 199 p.
  6. Pathomorphology: national. / V.D. Markovskiy, V.O. Tumanskyi, I.V. Sorokina [and others]; edited by V.D. Markovsky, V.O. Tumanskyi. - K.: VSV "Medicine", 2015. - 936p.
  7. Workshop on biopsy-sectioning course / I.I. Starchenko, A.P. Hasyuk, S.A. Proskurnya [etc.] – Poltava, 2016. – 160 p.

## Lecture No. 6

**Topic:** WITH general doctrine about tumors. Oncogenesis. Anatomical and microscopic features and types of growth of benign and malignant tumors. Clinical and morphological nomenclature of tumors. Mesenchymal tumors. Sarcoma: features of development and metastasis. Epithelial tumors: benign organ-nonspecific epithelial tumors, cancer (features of development, metastasis, histological forms). Nomenclature and morphological features of tumors of nervous tissue. Nomenclature and morphological features of tumors originating from melanin-producing tissue. Leukoses (leukemias) and lymphomas.

**Actuality of theme:** Oma - a tumor from the Latin General doctrine about tumors. Mechanism. Oncogenesis and its origin. Anatomical-microscopic features and types of growth of benign and malignant tumors. Morphological characteristics of the main stages of development of malignant tumors. Clinical and morphological nomenclature of tumors. Benign and malignant non-epithelial (mesenchymal) tumors. Sarcoma: features of development and metastasis. Epithelial tumors: benign organ-nonspecific epithelial tumors, cancer (features of development, metastasis, histological forms). Nomenclature and morphological features of tumors of nervous tissue. Features of tumors of the central nervous system. Nomenclature and morphological features of tumors originating from melanin-producing tissue. Leukemias (leukemias) and lymphomas.

**Goal:** Get acquainted with the meanings and problems of teaching about tumors, types and stages of development. Concepts of atypism, types, the process of metastasis, clinical-anatomical and histogenetic principles find and understand the difference between a benign and malignant tumor, their types, get acquainted with the types and locations of different types of tumors. Familiarize yourself with the features

of nerve tissue tumors, their types and causes. Get to know subject of nosology, types and classification of leukemias and lymphomas.

**Basic concepts:** Tumor; invasive growth, appositional growth, expansive growth, unicentric growth, multicentric growth, exophyte, endophyte, growth; atypism, morphological atypism, tissue atypism, cellular atypism, anaplasia; metastases Papilloma, adenoma (cystadenoma, myoma, acinar, trabecular adenoma), cancer (adenocarcinoma, ring cell carcinoma, solid cancer, mucosal carcinoma, cirrhosis, medullary carcinoma, squamous cell carcinoma, cellular carcinoma). Sarcoma (fibrosarcoma, liposarcoma, malignant hibernoma, Tangiosarcoma, osteosarcoma, chondrosarcoma, myosarcoma (rhabdomyosarcoma, leiomyosarcoma); fibroma, desmoid, leiomyoma, rhabdomyoma, lipoma, hibernoma, chondroma, osteoma, angioma (lymphangioma, hemangioma), hemopericytoma, glomerular angioma.

### **Plan and organizational structure of the lecture:**

Greetings, verification of those present, announcement of the topic, purpose of the lesson, motivation of higher education seekers to study the topic.

### **Content of lecture material (lecture text)**

*Tumor* is a newly formed heterogeneous tissue, the basis of which is the endless reproduction of cells due to changes in their genetic apparatus. The formed tumor is distinguished by the peculiarities of its growth, metabolism, interaction with other tissues, is characterized by a certain autonomy in relation to the whole organism, which can be considered as a certain independence of its further development.

A tumor can arise from any tissue that is capable of proliferation processes, but it does not arise from highly specialized, mature cells. The level of morbidity and mortality from tumors is different, which is explained by the state of ecology, ethnic customs, heredity, etc. The following theories of tumor growth are the most important: physicochemical theory (theory of carcinogens), virogenetic theory, dysontogenetic, polyetiological theory.

According to the physicochemical theory, the main role belongs to the action of physical and chemical carcinogens, that is, substances capable of causing tumors. Physical carcinogens include: solar, cosmic, ionizing radiation, radioactive substances. Physical carcinogens exert their effect through damage to the cell's



genome. The carcinogenic effect of the indicated factors can also be potentiated by the action of other carcinogenic agents - chemical (tobacco smoking, aniline, asbestos) and viral (human papilloma virus, Abstein-Barr virus, hepatitis B and C virus). Proponents of the viral-genetic theory believe that tumors can be caused by so-called oncogenic viruses, which contain DNA and RNA. DNA viruses cause malignant transformation of cells in 1:10<sup>7</sup> cases, most often they cause infectious diseases (adenovirus, chicken pox virus, hepatitis B virus). RNA viruses more often cause malignant transformation of cells because, leaving the cell, they do not damage its membrane and it does not die, as in the case of DNA viruses. According to the dysontogenetic theory, tumors arise from embryonic cell-tissue shifts and defectively developed tissues under the influence of various provoking factors. The polyetiological theory unites all the remaining existing factors that can change the genome of a cell and cause its malignant transformation.

Patho- and morphogenesis of tumors can be formulated on the basis of the indicated theories. Pathogenesis (carcinogenesis) considers the mechanisms of tumor genesis, types and mechanisms of blastomatous action of various pathogenic agents.

The following stages are distinguished: the initiation stage involves changes in the genome of a somatic cell under the influence of pathogenic (carcinogenic) agents; the intermediate stage is the activation of proto-oncogenes (normal cell genes) with their transition into oncogenes, which code for the production of oncoproteins as a result of the disruption of the function of regulatory genes. Activation of proto-oncogenes is accompanied by suppression of anti-oncogenes; the promotion stage - there is tumor transformation of cells with unlimited, uncontrolled growth and tumor formation.

Mechanisms of activation of proto-oncogenes: insertion mechanism - the appearance of viral genes in the genome of a somatic cell activates nearby proto-oncogenes; chromosomal translocations - observed in Burkitt's lymphoma, chronic myelogenous leukemia; point mutations; amplification - increase in the number of gene copies.

Morphogenesis is the process of formation and development of a tumor in a

morphological display. There are two morphogenetic options for the occurrence of tumors:

The appearance of a tumor does not happen by chance, but gradually, step by step, according to separate stages of changes in the mother's tissue: precancerous stage; diffuse or focal hyperplasia, dysplasia; stage "cancer in situ" - non-invasive cancer, when the integrity of the basement membrane is preserved; the stage of invasive growth - the stage of a formed malignant tumor; metastasis

Some of the tumors can pass the stage of a benign tumor (cancer of the stomach, colon).

The appearance of the tumor is diverse. Most often, it has the appearance of a node with an uneven surface or has a diffuse form, in the form of a thickening of the mother's tissue, differing from it only in color and consistency.

The size of the tumor depends on its "age", although both the nature of the tumor itself and the structure of the parent tissue are important. If the tumor does not have a noticeable harmful effect on the body, it can reach significant sizes, in other cases the body dies much earlier.

The consistency of the tumor is also different: sometimes it is denser (tumors made of bone, cartilage, fibrous tissue), then it is looser, when the parenchyma prevails over the stroma in the tumor.

One of the characteristics of tumors is the autonomy of their development, which has a relative character, because the tumor tissue constantly receives from the macroorganism various nutrients, oxygen, hormones, and cytokines that arrive with the blood stream. In addition, its growth is influenced by the immune system. In other words, tumor autonomy must be understood not as a certain independence of tumor cells from the body, but as their acquisition of self-regulation properties. Autonomy is more pronounced in malignant tumors (cancer, sarcoma). They grow quickly, destroying the parent tissue; it is less pronounced in benign tumors, some of them are subject to regulatory actions of the body, grow slowly, without destroying the parent tissue. In both cases, the cells switch to the autocrine mechanism of regulating their development, producing growth factors or oncoproteins - analogs of growth factors.

The structure of tumors is diverse depending on the tissue from which they are formed, the nature and direction of their growth. Organoid and histoid types of structure are distinguished. In the first case, the tumor consists of two clearly defined elements: parenchyma and stroma. They are not isolated from each other, but closely related to each other biologically and histogenetically. Nutrition of the parenchyma depends on the state of blood supply through the vessels of the stroma, on the other hand, the parenchyma affects the state of the stroma (the amount and nature of the stroma depend on the nature and state of the parenchyma). Otherwise, in some tumors, the stroma may not be sharply expressed and is represented only by vessels with a small amount of connective tissue (histoid type of structure).

Tumor development is characterized by considerable diversity. However, it always grows by itself, that is, due to the reproduction of its own cells, no matter what size and distribution it reaches. As a rule, no new cells are involved in the growth process. In some cases, neoplastic transformation occurs within the tumor field. Different types of tumor growth are distinguished - expansive, infiltrative, exophytic, endophytic, unicentric, multicentric. In case of expansive growth (characteristic of benign tumors), there is no destruction of the surrounding tissues, growth occurs with gradual separation of the tumor and the appearance of a capsule that separates the tumor from the parent tissue. Invasive (infiltrative) growth, on the contrary, is characteristic of malignant tumors. It is characterized by the destruction of surrounding tissues (histolysis). However, invasive growth does not always coincide with tumor malignancy - there is a group of so-called semi-malignant tumors that grow infiltratively, but do not metastasize, but are morphologically mature forms. As a result of invasive growth, malignant tumors are fused with surrounding tissues and are therefore clinically immobile. Their border with the mother part is unclear.

The rate of tumor growth depends on its type. Immature (malignant) tumors, which mainly consist of parenchyma, grow quite quickly, while mature ones, as well as tumors with a relatively developed stroma, grow quite slowly. The speed of tumor growth is one of the most important signs of tumor malignancy, because the degree of

germination and destruction of surrounding tissues depends on it. Therefore, it can be said that the fastest growing malignant swellings, the elements of which are the least mature. Such factors as inflammation, the period of puberty, pregnancy, stress, etc. can have some importance for the growth rate. Invasion is most often observed in the direction of least resistance: along interstitial gaps, along nerve fibers, blood and lymphatic vessels. Exophytic growth is the expansive growth of a tumor into an organ cavity. At the same time, it can fill a significant part of it (cancer of the stomach, intestines, bronchus). Endophytic growth is the infiltrative growth of a tumor deep into the organ wall. At the same time, it can be imperceptible from the outside and can be seen only in the section, in the form of tissue that grows through the wall of the organ. When a tumor arises from a single germ, it is said that its growth is unicentric, when a tumor grows from several tumor germs, it is said to be a multicentric growth. In the latter case, several tumor nodes appear in one organ (chondroma of the fingers), in other cases we can talk about tumors of the same type that arise simultaneously or gradually in different parts of the body, completely independently of each other. Such tumors almost always have a systemic nature, that is, they arise in certain body systems (numerous skin tumors - lipomatosis; of the nervous system - neurofibromatosis or Recklinghausen's disease, hemoblastosis, etc.). In addition, simultaneous formation of several tumors in the same patient is also possible (dimorphic tumors).

One of the important signs of tumors is their progression, i.e., a tendency in the direction of constant clonal evolution of tumor cells. It was determined that most tumors arise from one cell of one tumor embryo, that is, they have a monoclonal growth pattern. Over time, the tumor becomes increasingly heterogeneous, that is, various cell clones appear that "provide" various signs of a growing malignant tumor (recurrences, metastases, invasive growth, atypism).

*Atypicalism* is one of the most important signs of a tumor, which determines the origin of the tumor, its morphology, place in the qualification scheme, features of clinical manifestations and prognosis. This feature is the basis of such manifestations

of tumor growth, which were previously united by the terms anaplasia and cataplasia, which are used to this day.

Morphological atypism tumors can be tissue and cellular. Tissue atypism is characterized by a violation of tissue interactions characteristic of normal tissues or organs. It is based on violations of the ratio of parenchyma and stroma, as well as changes in the size and shape of tissue structures. Cellular atypism at the light-optical level is characterized by polymorphism or, on the contrary, monomorphism of cells, nuclei and nucleoli, hyperchromatosis, a violation (increase) of the karyoplasmic index due to an increase in the size of nuclei, asymmetric hypo- and hyperchromic mitoses, etc. Cellular atypism is sometimes so pronounced that it is impossible to establish the histogenesis of the tumor, and when it reaches the extreme degree of cataplasia, tumor cells become monomorphic. The appearance of unlimited proliferation of cells in the tumor,

At the ultrastructural level, morphological atypism is characterized by changes in the nucleus and cytoplasm of the tumor cell. In the nucleus, there is a violation of the structure and arrangement of chromatin in the form of clusters under the karyolemma: the amount of heterochromatin (containing inactive DNA) increases in relation to euchromatin (containing active DNA). In the nuclei there are various inclusions (vesicles, intussusceptions of the karyolemma), the size of the nucleoli increases. In the cytoplasm, the number of mitochondria decreases, large organelles appear, the number of ribosomes increases, and the number of contacts of the karyolemma with the membranes of the organelles increases.

Biochemically atypism manifested by a number of metabolic features in tumor cells. Tumor tissues are rich in cholesterol, glycogen and nucleic acids, glycolytic processes prevail over oxidative ones, which is accompanied by the accumulation of lactic acid.

Histochemical atypism reflects both morphological and biochemical features of the tumor. It is characterized by the fact that various histochemical changes in the activity of various enzymes, accumulation and redistribution of glycoaminoglycans, proteins and lipids appear in the cells. Specific enzymes were found in some tumors,

which is important for differential morphological diagnosis.

Antigenic atypism characterized by the antigenic diversity of the antigenic composition of the tumor. There are: antigens of viral tumors, antigens of tumors caused by carcinogens, tumor-specific antigens, embryonic antigens, heterogeneous antigens.

Functional disorders in tumor cells depend on the degree of morphological and biochemical atypia. More differentiated tumors retain the functional features of the cells of the parent tissue. low-differentiated, as a rule, lose the functions of the mother tissue (organ), which can have adverse consequences (tumors of the adrenal glands, pancreas).

Any tumor first forms a so-called primary node. Benign tumors remain in the form of a slowly growing nodule. Malignant tumors, on the contrary, due to invasive growth penetrate into lymphatic and blood vessels, their cells are transferred to other organs, where secondary nodes (metastases) are formed, which are hematogenous, lymphogenic, implantation, perineural. The process of metastasis has a cascade character and manifests itself in the form of separate stages: invasion of tumor cells into the vessel lumen; tumor embolus transport; adhesion of cells on the surface of the endothelium and exit into the perivascular space (extravasation); formation of secondary nodes (metastases).

All tumors can be classified according to the two most common principles: clinical and anatomical and histogenetic.

*According to the clinical and anatomical principle* distinguish between mature, homologous or benign tumors and immature, heterologous, or malignant tumors (cancers and sarcomas). Benign tumors consist of more differentiated tissue with signs of tissue (rather than cellular) atypism, grow mainly expansively (the exception is the so-called tumors with locally destructive growth, or semi-malignant tumors from blood vessels, cartilage, fibrous tissue, etc.), not metastasize. As a rule, necrosis (decay) is rarely observed in these tumors, but sometimes amyloidosis or hyalinosis of the stroma, hemorrhages occur. Malignant tumors consist of undifferentiated tissue with signs of cellular and tissue atypism, characterized by infiltrative growth,

occurrence of metastases, recurrences, as well as necrosis (disintegration) with the development of bleeding and hemorrhages.

On the basis of the histogenetic principle, benign and malignant tumors are distinguished:

1. Organ non-specific epithelial tumors
2. Organ-specific epithelial tumors
3. Mesenchymal tumors
4. Tumors of melanin-forming tissues
5. Tumors of the nervous system and meninges
6. Tumors of the blood system
7. Teratomas.

Thus, the problem of tumors is one of the most relevant in modern medicine. This is due to the high frequency of their distribution and the lack of clear ideas in various aspects of the problem (etiology, patho- and morphogenesis, classification, etc.).

In recent years, certain trends have been identified regarding the epidemiology of various tumors. So, for example, there is an increase in the incidence and mortality rates from cancer in all countries of the world; cancer diseases begin to appear in all age groups, although most often - after 50 years; revealed gender differences in the incidence of certain forms of cancer among men and women; and also the structure of morbidity and mortality from cancer is constantly changing due to the increase in the frequency of some diseases and the decrease in the frequency of others.

### **Non-epithelial tumors**

Non-epithelial tumors include neoplasms of mesenchymal and neuroectodermal origin. This is the most numerous and most diverse group of tumors in terms of histological structure. At the end of the 40s of the last century, according to the assumptions of the outstanding American oncologist APStout, a significant part of these tumors, located between the epidermis and the bone system, was separated into a separate group called "soft tissue tumors". After 20 years, this term was adopted in all countries of the world and taken by the WHO as the basis of the

international classification of tumors. Today, this group of soft tissue tumors includes 115 separate nosological forms of tumors and tumor-like processes.

The group of tumors of mesenchymal origin is distinguished by a special number of different histological variants of structures. Mesenchyme in ontogenesis gives rise to connective tissue, blood vessels, muscles, tissues of the musculoskeletal system, serous membranes, which under certain conditions can be the source of tumors.

### **Tumors of soft tissues.**

Classifications of soft tissues differ in complexity and ambiguity. Like all tumors, neoplasms of soft tissues are classified according to histogenesis, degree of maturity and clinical course:

1. Tumors of fibrous tissue: mature, benign (fibroma, dermoid); immature, malignant (fibrosarcoma).

2. Tumors from adipose tissue: mature, benign (lipoma, hibernoma); immature, malignant (liposarcoma, malignant hibernoma).

3. Tumors of muscle tissue (from smooth and striated): mature, benign from smooth muscles (leiomyoma); mature, benign from striated muscles (rhabdomyoma); immature, malignant from smooth muscles (leiomyosarcoma); immature, malignant from striated muscles (rhabdomysarcoma).

4 Tumors of blood and lymphatic vessels: mature, benign (hem-, lymphangioma, hemangiopericytoma, glomusangioma); immature, malignant (hem-, lymphangioendothelioma, malignant hemangiopericytoma).

5. Tumors of synovial tissues: mature, benign (benign synovial oma); immature, malignant (malignant synovioma).

6 Tumors of mesothelial tissue: mature, benign (benign mesothelioma); immature, malignant (malignant mesothelioma).

In addition to soft tissue tumors, non-epithelial tumors include neoplasms of melanin-forming tissue and bones, which are divided into bone-forming and cartilage-forming: mature, benign - chondrosteoma, immature, malignant - chondrosteosarcoma.



### **Mature, benign tumors of the connective tissue itself.**

A fibroma is a mature tumor of fibrous connective tissue. It occurs in all age groups with the same frequency in men and women. It is localized more often between the epidermis and the bone in the subcutaneous fatty tissue, in the tendons and fascia of the upper and lower limbs, trunk. In internal organs, this tumor is extremely rare.

Fibroma has the appearance of a node with clear boundaries, dense or soft consistency depending on the histological structure, pink-white on section with pronounced fibrousness.

Microscopically, the fibroma is represented by bundles of connective tissue fibers, which have different lengths and thicknesses, located in different directions. The polymorphism of fibroblasts is weakly expressed, the nuclei are hyperchromic.

Depending on the predominance of cellular or fibrous components, two types of fibroma are distinguished: dense with a dominance of collagen bundles over cells and soft, which consists of loose fibrous connective tissue with a large number of cells.

Clinically, fibroma grows slowly, does not have a general effect on the body, if it is not localized in vital organs, then its course is benign. The probability of malignancy is small. The exception is soft fibroids, which often recur. Some authors classify soft fibroma as differentiated fibrosarcoma.

Desmoid (desmoid fibroma) is a connective tissue neoplasm that, according to the histological picture, resembles a fibroma. Differs infiltrative growth. Tissue and cellular atypism are weakly expressed. It occurs mostly in women after childbirth. In rare cases, it is observed in men and children. Depending on the localization, the following are distinguished: abdominal desmoid (when localized in the thickness of the anterior abdominal wall); extra-abdominal desmoid.

Abdominal desmoid is relatively benign, not prone to malignancy. Extra-abdominal desmoid or aggressive fibromatosis is often observed at a young age in both men and women. It is localized in places of aponeurosis and fascia on the limbs, in the shoulder girdle, buttocks. It is distinguished by rapid aggressive infiltrative

growth, despite the absence of a large number of mitoses. It often recurs and often becomes malignant.

### **Malignant tumors of the connective tissue itself**

Fibrosarcoma is an immature malignant tumor of fibrous connective tissue. Fibrosarcomas are relatively rare tumors. In the past, they ranked first in frequency among non-epithelial malignant neoplasms. After Stout's proposal, only those malignant tumors that produce mature collagen types I or III and do not form other structures were considered fibrosarcomas. Many tumors that were considered fibrosarcomas were classified as synovial sarcomas, malignant histiocytomas, leiomyosarcomas. Tumors are localized most often on the thigh, shoulder, trunk.

Fibrosarcoma can grow in the form of a node and in the form of an infiltrate

Microscopically, it consists of immature fibroblast-like cells and collagen fibers. There are differentiated and poorly differentiated fibrosarcomas.

Differentiated fibrosarcomas are characterized by pronounced polymorphism and hyperchromia of nuclei. Low-differentiated fibrosarcomas are characterized by monoformism, dyschromia and hypochromia of the nuclei, many atypical mitoses. The two most unfavorable prognostic features of fibrosarcoma are hypochromic nuclei and foci of myxomatosis. Fibrosarcomas metastasize mostly hematogenously to the lungs, less often to the liver, and then lymphogenously to regional lymph nodes. The prognosis for poorly differentiated fibrosarcomas is much worse (about 50% of patients die in the first five years).

### **Mature, benign tumors from adipose tissue.**

Lipoma is one of the most common soft tissue tumors. It occurs more often in women in all age groups. Can occur anywhere there is adipose tissue. It can rarely be localized in internal organs. Often there are multiple.

A lipoma often has the appearance of a node of a partial structure (many layers of connective tissue), soft-elastic consistency, yellow in appearance, resembling adipose tissue in appearance. When localized between muscles, it can be vaguely separated, simulating infiltrative growth. It can reach large sizes (more than 20 cm in diameter), especially with retroperitoneal localization.

Microscopically the tumor is basically built like normal adipose tissue and differs from it in different sizes of lobules and fat cells. Due to the presence of a large number of layers of dense fibrous connective tissue, it indicates a fibrolipoma. A sufficient number of vessels in the tumor in some cases allows us to talk about an angiolipoma.

Clinically, in most cases, lipoma has a benign course. However, in connection with multicentric growth, relapses may occur due to incomplete removal of the tumor field. With retroperitoneal localization, malignancy of the tumor is often noted.

*Hibernoma*- mature benign tumor from brown fat. It is more common in women in all age groups. Brown fat is usually found in humans in the embryonic period. Microscopically, brown fat cells differ in the presence of many fat vacuoles in the cytoplasm, which give it a foamy appearance, the nuclei are located in the center of the cell.

Hibernoma is localized most often on the neck, back, hips, abdominal wall, in the mediastinum, that is, in places where brown fat is normally found during embryogenesis.

It has the form of a node of a lobular structure, brown in color.

Microscopically consists of polygonal and round cells, they form particles that are separated by thin layers of connective tissue. Cell nuclei are centrally located and contain one nucleolus. Cytoplasm is fine-grained, eosinophilic or foamy (multilocular fat cells). The chemical composition of fat differs even in one cell. Cholesterol is often detected, which is clearly visible in polarized light.

Hibernoma does not recur and does not metastasize.

### **Immature, malignant tumors from adipose tissue.**

*Liposarcoma*- an immature malignant tumor from adipose tissue. The tumor is more common in men in all age groups. Most often, it occurs in the soft tissues of the thigh, lower leg, and retroperitoneal region. The tumor can reach large sizes, and its mass can reach several kilograms.

Liposarcoma has the form of a node or a conglomerate of nodes with infiltration of surrounding tissues. The consistency is dense, the cut surface is juicy,

variegated - with foci of oozing, hemorrhages, and necrosis. It is often white, juicy, reminiscent of "fish meat".

Microscopically pronounced tissue and cellular polymorphism. It consists of lipoblasts of various degrees of maturity, there are giant cells with chimeric nuclei. Based on the dominance of certain cell forms that make up the tumor, the following are distinguished: highly differentiated liposarcoma; polymorphic (low-differentiated) liposarcoma.

The latter has the most malignant course. Because liposarcomas can often be multiple, developing simultaneously or sequentially in one or different areas of the body. Most variants of liposarcoma clinically progress slowly and rarely metastasize. Some of them, for example, round cell liposarcoma, do not differ in course from other sarcomas - they grow quickly, recur and metastasize mainly hematogenously in the lungs.

*Malignant hibernoma*- an immature, malignant tumor of brown fat. Tumor localization, sex and age of patients coincide with similar indicators for hibernoma.

Macroscopically malignant hibernoma resembles liposarcoma. When localized under the skin, it is often covered with ulcers.

Microscopically characterized by sharply expressed polymorphism of multilocular cells that have a polygonal shape. There are many giant uninucleate and multinucleate cells with basophilic homogeneous and fine-grained cytoplasm. There are few mitoses.

It very rarely metastasizes - mainly in the lungs by the hematogenous route.

### **Tumors of muscle tissue (smooth and striated).**

*Leiomyoma*- a mature, benign tumor of smooth muscles. It occurs at any age in both men and women.

Leiomyoma is localized in the skin (from the muscles that raise the hair, from the vessel wall), in the uterus, in the muscular shell of the gastrointestinal tract.

Macroscopically the tumor is a clearly separated nodule of dense consistency, fibrous on section. The size of the tumor is very variable, sometimes a leiomyoma can reach a size of 30 cm or more. Leiomyomas are often multiple or isolated, or

form a conglomerate of nodes.

Microscopically leiomyoma formed from spindle-shaped tumor cells that form bundles going in different directions. With special research methods, myofibrils are detected in the cytoplasm. Sometimes the nuclei in myoma form rhythmic structures, the so-called polysad structures, which are an indicator of tumor growth. When the connective tissue component predominates, it is called fibromyoma. The more connective tissue in a tumor, the slower it grows. With a sufficient number of vessels, the tumor is called an angioleiomyoma. Epithelioid leiomyoma is distinguished by the shape of the cells. All variants of leiomyoma are benign. Uterine fibroids have the greatest clinical significance. Uterine leiomyomas often occur in women aged 30-50 years. According to the histological picture, they more often have the structure of fibromyoma.

Depending on the localization in the uterus, leiomyomas are distinguished: submucosal; intramural (in the thickness of the muscle wall); subserous

Intramurally located fibroids are practically asymptomatic, with submucosal localization, frequent minor bleeding is often observed in the clinic, sometimes pronounced uterine bleeding is possible, requiring surgical intervention. Subserosally located nodes can squeeze the ureters with the development of hydronephrosis, pyelonephritis. In the post-menopausal period, the reverse development of tumor nodes is described. It is necessary to know that the rapid growth of the tumor during this period indicates the possible malignancy of the neoplasm.

*Leiomyosarcoma (malignant leiomyoma)*- an immature malignant tumor of smooth muscle tissue. It is localized more often in the gastrointestinal tract, mostly in the colon, after that - in the retroperitoneal space, in the soft tissues of the limbs, and in the uterus. It occurs more often at a young age, very rarely in children.

Macroscopically more often has the form of a node, which can reach more than 30 cm in diameter. Infiltrating growth is not always obvious.

Microscopically there are two types of leiomyosarcoma - highly differentiated and poorly differentiated. Highly differentiated are very difficult to distinguish microscopically from leiomyomas. The most important differential feature is the

presence of many atypical mitoses. Low-differentiated leiomyosarcomas are characterized by sharp cataplasia of tumor cells, the appearance of giant cells, and significant polymorphism.

Leiomyosarcomas metastasize early and widely, mainly by the hematogenous route, giving multiple metastases to the liver, lungs, and often to the brain. Sometimes metastases can be detected in the clinic earlier than the main tumor. Especially with its retroperitoneal localization and localization in the large intestine.

Rhabdomyoma is a mature, benign tumor of striated muscles. It is rare. Described in all age groups, more often in children and newborns. It is localized on the head, neck, trunk, upper and lower limbs. Separate rhabdomyomas of the tongue, heart, and female genital organs.

Macroscopically can have the form of a node and an infiltrate.

Microscopically tumor cells copy different degrees of differentiation muscle elements of different shapes - large oval, striated. Transverse striation is difficult to detect, mainly in elongated striated cells. Glycogen is detected in the cytoplasm of cells. Figures of mitosis are absent.

Clinically are benign, with the exception of rhabdomyomas of the heart and tongue, which are the cause of death of patients.

*Rhabdomyosarcoma*- an immature, malignant tumor of striated muscles. It occurs more often than rhabdomyomas. In children, rhabdomyosarcoma is one of the most common tumors, second only to nephroblastoma (Wilms tumor) and neuroblastoma. It is localized in the thickness of the muscles of the lower, less often - the upper limbs, in the retroperitoneal tissue, mediastinum, on the face, neck, in the nasopharynx, in the genitourinary organs.

Macroscopically the tumor is a node with a diameter of up to 20 cm or more.

Microscopically a characteristic polymorphism due to the fact that tumor cells copy embryonic muscle cells in their structure at various stages of embryogenesis and differ in significant cataplasia. To make a diagnosis, methods are used to detect transverse striations in the cytoplasm of cells, electron microscopy to detect myofibrils, and immunohistochemical typing using monoclonal antibodies.

Rhabdomyosarcoma is characterized by a high degree of malignancy. It often recurs, gives multiple hematogenous metastases in the liver and lungs.

### **Tumors of blood and lymphatic vessels.**

*Hemangioma*- a mature, benign tumor from blood vessels. Some of these tumors refer to malformations of the vascular system of a tumor-like nature, some to true blastomas. Depending on which vessels copy the neoplasm, the following types of hemangioma are distinguished: capillary; venous; cavernous; arterial

*Capillary hemangioma* is a neoplasm with the proliferation of endothelial cells and the formation of atypical capillaries. It is localized most often in the skin, mucous membranes of the gastrointestinal tract. It is often multiple. It is more common in female children.

Macroscopically it is represented by a red or bluish node with a smooth or bumpy surface, it has a porous structure on the cross section. If the tumor is localized in the skin, the node becomes white when pressed.

Microscopically the tumor consists of branched capillary-type vessels with a narrow lumen that is not always filled with blood. The endothelium is swollen, hyperchromic. Capillaries can form indistinctly separated particles, which gives the impression of infiltrating growth.

*Cavernous hemangioma* – neoplasm, which consists of chimeric cavities of the type of sinusoids of different sizes, which are interconnected. It is most often found in the liver, gastrointestinal tract, brain.

Macroscopically has the appearance of a purplish-bluish node clearly separated from the surrounding tissues, which resembles a sponge in cross-section.

Microscopically consists of thin-walled caverns (cavities), covered with a single layer of endothelial cells and filled with blood.

*Arterial angioma*- is a conglomerate of developed vessels of the arterial type, among which there are areas resembling a capillary hemangioma.

*Venous hemangioma*- microscopically represented mostly by vessels of the venous type, next to which there are vessels of the capillary and arterial type. It is located in the depth of soft tissues, between muscles.

*Glomusangioma*(Barre-Masson tumor)– mature benign tumor of vascular origin (myoarterial glomus). They occur with the same frequency in men and women, mostly of mature age.

Macroscopically two types are distinguished: solitary glomusangioma; multiple disseminated (familial glomusangioma).

It occurs more often in the form of a single nodule with a diameter of 0.3–0.8 cm, soft consistency, grayish-pink color. Favorite localization in the hands and feet, mostly on the fingers, in the area of the nail bed. It is clinically manifested by sharp pain due to a large number of nerve endings.

Microscopically consists of slit-like vessels of the sinusoidal type, which are covered with endothelium and surrounded by cuffs of epithelioid cells and resemble glomus cells.

*Hemangiopericytoma*– a tumor of vascular origin, in which, along with the formation of vessels, the proliferation of perivascular cells (Zimmerman pericytes) occurs. It occurs at any age, often in children. As a rule, it has a benign course. It can recur after several years. With a certain localization, for example, in the retroperitoneal region, on the upper limbs, head and neck, regardless of the maturity of the cells that make up the tumor, it can metastasize. Therefore, Stout and other authors suggest considering different variants of hemangiopericytoma as "potentially malignant tumors".

*Lymphoangioma*- a tumor from lymphatic vessels. It occurs more often in children as a developmental defect. It is localized mostly in the mucous membrane of the oral cavity, retroperitoneal space, mesentery. Cystic and cavernous variants of the tumor structure are more common. The microscopic structure is similar to the structure of hemangiomas.

*Hemangioendothelioma*- considered by many authors as the most malignant tumor. It occurs more often at the age of 30–50 years, but can often occur in childhood. It is localized most often in the skin, soft tissues of the limbs, trunk, head, less often in internal organs.

Macroscopically is a node up to 10 cm in diameter, lobular structure, in places



with infiltrative growth. The nodules are soft, juicy, pink or red in color with centers of necrosis.

Microscopically the tumor is built of atypical, randomly anastomosing vessels lined with several layers of atypical endothelial cells. Pronounced cellular polymorphism, nuclear hyperchromia. Hemangioendothelioma metastasizes widely, mostly by the hematogenous route to the lungs, bones, and liver. Metastases to regional lymph nodes can be observed.

*Lymphangioendothelioma*- similar in structure to hemangioendothelioma. It often occurs against the background of chronic lymphostasis.

### **Tumors of synovial tissue.**

*Synovioma* they occur more often at the age of 30-40, mainly in men.

Macroscopically, it looks like a dense nodule measuring 5 cm or more, uniform in section, white-pink in color. It is localized on the limbs in the area of the joints (the area of the knee, forearm, fingers and toes).

Microscopically, the tumor is polymorphic, it contains fissures and cysts of various sizes, lined with oval, cubic, prismatic cells that resemble cells of the glandular epithelium. In addition, there are spindle-shaped cells that form the swollen stroma. They are also polymorphic. There are single giant multinucleated cells. Since the morphological and biological features of synoviomas often do not coincide, and a morphologically mature tumor may turn out to be malignant, today most authors believe that all synoviomas should be considered malignant, regardless of the degree of maturity.

### **Tumors from the mesothelium.**

*Mesothelioma*- a mature, benign tumor, occurs relatively rarely, has the structure of a fibroma, rich in cellular elements, therefore it is called fibrous mesothelioma.

Macroscopically, it is a clearly separated nodule, which grows slowly, most often in the visceral pleura, dense, layered in section.

*Malignant mesothelioma* is a rare neoplasm that develops from mesothelial cells, mainly in the pleura, but can also be observed in the peritoneum and

pericardium. Almost all patients with malignant mesothelioma have a history of working with asbestos.

Macroscopically the tumor has the form of a dense infiltrate, 2-3 cm thick or more, on the serous membranes. In the pericardium and omentum, it may have the appearance of vaguely separated nodes with a villous surface.

Microscopically the tumor resembles adenocarcinoma or hemangioendothelioma. Epithelioid mesothelioma of tubular or papillary structure is most common.

Histological verification of both mature and immature mesothelioma is very difficult. An accurate diagnosis can be made with the help of immunohistochemical typing using monoclonal antibodies, as well as the tissue culture method.

### **Cyst-forming and cartilage-forming tumors.**

*Chondroma* – a mature benign tumor that mimics the morphology of mature hyaline cartilage. It is more often localized in the phalanges of the fingers of the hand, bones of the wrist, but can also be found in large tubular bones (thigh, shoulder, tibia) and in the lungs. It occurs in all age groups, but more often in children. Clinically, it grows slowly over the years.

Macroscopically chondroma is a node of lobular structure, dense, blue and white in color, resembling cartilage.

Microscopically the tumor has the structure of mature hyaline cartilage. Cellular atypism is weakly expressed. Cartilaginous cells vary slightly in size, with one, or sometimes two, small nuclei, located randomly in typical lacunae, separated from each other by a greater or lesser amount of the main substance of the hyaline type. The significance of the tumor is determined by its location. For example, when located in the bronchi, it can cause atelectasis of the lung.

*Osteoma* – mature, benign bone tumor. The predominant localization of osteomas is the bones of the skull, especially the sinuses. Osteoma in tubular bones is rare. Most often, it appears in childhood.

Macroscopically has the appearance of a node, in consistency is denser than normal tissue. In the accessory sinuses of the skull, they are sometimes multiple,

growing in the form of a polyp on a stem. In relation to the bone, the osteoma can be periosteal, cortical or endosteal. In most cases, osteomas are diagnosed accidentally during an X-ray examination.

Microscopically osteomas are divided into compact and spongy. Compact osteoma consists almost entirely of bone mass, thin fibrous or lamellar structure with very narrow vascular channels. A spongy osteoma is represented by a clear mesh of bone beams, but arranged randomly. Interbeam spaces are filled with cellular and fibrous tissue. It does not have clear boundaries with the surrounding bone tissue. The combination of multiple osteomas localized in the lower jaw, skull vault and long tubular bones with intestinal polyposis and soft tissue tumors was named Gardner's syndrome.

*Osteosarcoma* is a collective concept that includes immature malignant tumors of bone and cartilage-forming tissue, such as periosteal chondrosarcoma, peri- and intracortical osteogenic sarcoma, malignant osteoblastoma. It is necessary to know that an X-ray examination is mandatory for the verification of osteogenic tumors. Thus, the diagnosis is X-ray morphological. The age of patients varies from 6 to 60 years, 50% are patients younger than 30 years. Radiologically, thinning and destruction of the cortical bone layer is noted.

Macroscopically tumor of a variegated appearance - from white-gray to brown-red color, loose consistency, despite the presence of focal calcification.

Microscopically the main tissue component of the tumor is represented by bone and osteoid structures lined with atypical osteoblasts, with the presence of thin-walled vessels, many atypical figures of mitosis are found. Metastasis is carried out mainly by the hematogenous route, mainly in the lungs.

## **TUMORS FROM THE EPITHELIUM**

Epithelial tumors are the most common among tumors. The basis of their classification is the features of histogenesis (type of epithelium), degree of differentiation and organ specificity.

Depending on the histogenesis, tumors of the covering epithelium (multilayered flat and transitional) and glandular are distinguished.

According to the course, which is mainly determined by the degree of differentiation, epithelial tumors can be benign or malignant.

Depending on the organ specificity, organ-specific and epithelial tumors without specific localization are distinguished.

Organ-specific tumors arise only in certain organs and have characteristic morphological features, sometimes functional (synthesis of characteristic hormones), which distinguish the tumor from other tumors and easily allow (even in the presence of metastases) to establish its origin from a specific organ.

### **Benign tumors without characteristic localization**

*Papilloma.* Benign tumor of the integumentary epithelium (multilayered flat and transitional). It often occurs in the skin, oral cavity, bladder, etc. Macroscopically, it has a spherical shape on a wide base or on a leg, soft or elastic consistency, mobile.

Microscopically, the tumor is a papillary formation of multilayered flat or transitional epithelium, which is separated by the basement membrane from the connective tissue stroma with vessels. The polarity and complexity of the epithelium is preserved, but there is a thickening of the layers, increased keratinization.

Papilloma can be multiple - papillomatosis of the larynx.

Occasionally, the papilloma recurs and becomes malignant (larynx, bladder).

*Adenoma.* Benign tumor of the glandular epithelium. It develops on mucous membranes covered with glandular epithelium and in organs. Adenomas of mucous membranes in the form of a polyp are called adenomatous polyps. Adenomas of the mucous membrane of the stomach and colon often become malignant. The following morphological variants of adenoma are distinguished: acinar (alveolar), tubular, trabecular, solid, papillary cystadenoma, villous adenoma, fibroadenoma.

*Papillary cystadenoma.* Macroscopically, the tumor has the appearance of a cystic formation (it can be much larger than the ovary) with thin walls and a transparent liquid. The inner surface of the cyst (cyst) is covered with multiple white-pink papillae. The tumor is located within the ovary.

Microscopically, the tumor consists of cystically stretched lumens of the glands. Cubic or cylindrical epithelium, which lines the inner surface of cysts, forms

papillary protrusions, preserves the basement membrane, polarity and complexity. In the ovaries, the tumor has a propensity for malignization, infiltrative growth and malignant course.

### **Benign tumors with characteristic localization.**

*Villous adenoma of the colon.* Macroscopically, it looks like a large polyp (more than 1 cm) on a stalk or a wide base with a villous surface.

Microscopically, the adenoma is formed by elongated numerous papillae, which are formed by a highly differentiated epithelium with a large number of goblet cells. Dysplasia is often noted, multilayering of the epithelium is determined, atypia appears, and goblet cells disappear. In 30% of cases, the tumor becomes malignant.

*Breast fibroadenoma.* Benign tumor, often found in women aged 25-35. In the case of pregnancy, the tumor increases (it has progesterone receptors), regresses with age. It rarely becomes malignant, carcinoma in situ is diagnosed in 0.1% of cases. Macroscopically - a dense, mobile, well-demarcated, painless node, usually up to 3 cm with slit-like cavities on the section. Sometimes it reaches large sizes - a giant fibroadenoma.

Microscopically, the tumor consists of glandular structures (ducts) of various shapes and sizes. The epithelium preserves the basement membrane, complexity and polarity. The stroma is well developed and dominates the parenchyma. Intracanalicular fibroadenoma is distinguished - the stroma is loose, rich in cells, grows into the ducts, compressing them, and pericanalicular fibroadenoma - the fibrous stroma surrounds the ducts and, as a result, they have the appearance of round tubes. Both variants are often found in the tumor.

*Phylloid (leaf-shaped)* the tumor belongs to stromal tumors and can be benign, borderline and malignant.

### **Adenomas of endocrine organs.**

They are characterized by pronounced organ specificity. They can be hormonally active and manifest as a specific hormonal syndrome or without hormonal activity. Tumors that arise from endocrine cells that belong to the APUD system (amine precursor uptake decarboxylation) and produce biogenic amines or

polypeptide hormones are called apudomas.

Apudoms are diverse and are named according to the hormones they produce. Apudomas include adenomas of endocrine glands (pituitary gland, pineal gland, pancreas), paragangliomas (chromaffinous and non-chromaffinous (hemodectoma)), carcinoid. Apudomas have a malignant course, the probability of malignancy increases with the growth of the tumor, so they are classified as potentially malignant.

*Carcinoid.* Traditionally, the term is applied to tumors that arise from enterochromaffin cells of the gastrointestinal tract and produce serotonin (a biogenic amine). Tumors of other locations (lungs, pancreas, etc.) are also called carcinoids. It is most often found in the appendix and small intestine (30%). It can be accompanied by carcinoid syndrome: reddening of the skin, watery diarrhea, bronchospasm, non-infectious thromboendocarditis of the valves of the right half of the heart. Macroscopically, the tumor without clear boundaries is up to 1 cm, it can be larger. It is yellow on section, located in the submucosal layer, and occasionally ulcerates.

Microscopically, the tumor consists of polygonal cells that are located around capillaries and are delimited by groups of connective tissue layers. The cells have a positive argentophine reaction. Occasionally, a carcinoid becomes malignant and can metastasize.

### **Pituitary adenomas.**

*Somatotropic adenoma* consists of eosinophilic cells, produces somatotropin (growth hormone). Gigantism develops in children, and acromegaly in adults (enlargement of arms, legs, jaws, nose, and internal organs; accompanied by hyperglycemia, osteoporosis, and hypertension).

*Corticotropic adenoma* consists mainly of basophilic cells, produces adrenocorticotrophic hormone (ACTH). Causes the development of Itsenko-Cushing's disease, which is accompanied by hypercorticism.

*Prolactinoma* consists mainly of chromophobe cells, causes amenorrhea and galactorrhea in women, impotence and sometimes galactorrhea in men.

**Adenomas of the pancreas** arise from islet cells.

*Insuloma* develops from beta cells, produces insulin, has a trabecular or tubular

structure, is accompanied by hypoglycemic syndrome.

*Glucagonoma* develops from A-cells, produces glucagon, has a trabecular structure, causes hyperglycemic states and secondary diabetes.

*Gastrinoma* develops from G cells, produces gastritis (causes hyperplasia of parietal cells of the gastric mucosa and stimulation of hydrochloric acid production, has a trabecular structure, is accompanied by Zollinger-Ellison syndrome, which is characterized by multiple recurrent ulcers of the stomach and duodenum. It has a malignant course in 70% of cases .

*Noted* develops from D cells, produces vasoactive intestinal peptide, has a solid-trabecular structure, develops watery diarrhea, hypoglycemia and achlorhydria (pancreatic cholera or Werner-Morrison syndrome. Malignant course in 80% of cases.

*Pheochromocytoma* (chromaffin paraganglioma) arises from chromaffin cells of the adrenal medulla, if the tumor arises from extra-adrenal chromaffin tissue, it is called a paraganglioma. The tumor produces adrenaline and norepinephrine, causes secondary hypertension, and in 10% of cases it becomes malignant.

*Multiple endocrine neoplasia syndrome (MEN)*- a number of genetic syndromes, which are accompanied by the development of multiple endocrine tumors, mainly apud.

**Malignant epithelial tumors** called cancer or carcinoma. Diagnosed most often among tumors. Usually associated with precancerous conditions, previous changes in the epithelium: metaplasia, dysplasia, hyperplasia. Epithelial dysplasia progresses from mild to moderate to severe, causing carcinoma in situ and subsequently invasive cancer that grows into surrounding tissues. Carcinoma in situ is an intraepithelial tumor that does not extend beyond the basement membrane. As for the cervix, in many cases it is not possible to distinguish severe dysplasia from carcinoma in situ, so these conditions were combined under the name CIN 3 (cervical intraepithelial neoplasia 3) and a single treatment strategy was chosen. Carcinoma in situ does not metastasize.

Cancer metastasizes mainly lymphogenously, the first metastases occur in regional lymph nodes, later hematogenous and implantation metastases may occur.

*Squamous cell cancer.* It develops from a multi-layered flattened epithelium. It occurs in the lungs as a result of metaplasia of the bronchial epithelium. There may be different degrees of differentiation. The formation of "cancer pearls" is characteristic of highly differentiated cancer, keratin is absent in poorly differentiated cancer, and keratin is determined intracellularly in a moderately differentiated form.

*Adenocarcinoma (glandular cancer).* It develops from the prismatic epithelium of mucous membranes and organs, the presence of glands is characteristic. It has a different degree of differentiation. The lower the degree of differentiation, the fewer glands are determined in the tumor. A special form of low-differentiated adenocarcinoma is a sclerotic adenocarcinoma with an abundant stroma and a nested cluster of hyperchromic cells with a pronounced atypism. The consistency of the tumor is cartilaginous.

*Undifferentiated cancer* (it is impossible to determine from which epithelium the tumor originates without special diagnostic methods). Small cell cancer is found in the stomach, lungs (hormonally active, so it can be attributed to apudom) and other organs. Large cell carcinoma occurs in the stomach and lungs. Signet cell carcinoma is most often found in the stomach. Medullary cancer is most common in the breast. The stroma is sparse, the atypical cells are large, the nuclei are well-defined nucleoli, the cell boundaries are not defined, there are necrosis. Atypical mitoses are defined among numerous mitoses. The tumor reaches large sizes, soft, white-pink color on the section, the surface of the tumor is smooth. Undifferentiated cancer with a scirrhous type of growth occurs mainly in the stomach.

**Cancer with specific localization in organs.** An example of cancer with pronounced organ specificity can be clear cell kidney cancer and chorionic carcinoma.

*Clear cell kidney cancer.* The most common form of renal cell carcinoma, which develops from the tubular epithelium. Men aged 40-60 years are more often affected. It metastasizes hematogenously, the first metastases are determined in the lungs. It is characteristic that the tumor grows into the renal vein and spreads along the vena cava to the heart. The tumor has the appearance of a node with clear borders,



which are formed by a pseudocapsule. On section, the tumor is variegated, yellow with hemorrhages. Microscopically, the tumor is made up of atypical cells with small hyperchromic nuclei and optically empty (light) cytoplasm, which form solid-alveolar structures, has many sinusoidal vessels, hemorrhages. When staining with sudan 3, lipids in the cytoplasm of cells are determined.

*Chorion carcinoma.* A malignant tumor that develops from a trophoblast. Occurs in women after childbirth, abortions, against the background of destructive vesicular snow. It is localized in the uterus, but an ectopic location outside the uterus is possible and vision develops in men. The tumor metastasizes hematogenously in the lungs, liver, brain, etc. Hemorrhages occur in metastases, which explains hemoptysis when the tumor is located in the lungs. The tumor has the appearance of a soft nodule of dark red color. The tumor consists of atypical small cytotrophoblast cells and large syncytial formations (Langhans cells), the stroma is not determined, there are many hemorrhages. The tumor is hormonally active, produces chorionic gonadotropin (HCG), an increase in its level in urine and blood is a diagnostic criterion. Immunohistochemically, HCG can be detected in tumor cells. In connection with the presence of an elevated level of hCG, there may be changes in the genitals: decidual reaction of the endometrium, hyperplasia of the mammary glands, ovarian cysts. With the use of adequate chemotherapy and the absence of metastases, the 5-year survival rate is 100%.

**NOMENCLATURE AND MORPHOLOGICAL FEATURES OF TUMORS OF NERVOUS TISSUE. FEATURES OF TUMORS OF THE CENTRAL NERVOUS SYSTEM. NOMENCLATURE AND MORPHOLOGICAL FEATURES OF TUMORS ORIGINATING FROM MELANIN-PRODUCING TISSUE.**

Tumors of the nervous system differ from tumors of other origin in a wide variety, because they arise from different elements of the nervous system: central, autonomic, peripheral, as well as elements of the mesenchymal system, which are part of the nervous system. According to the degree of differentiation, they can be more or less mature, that is, benign and malignant. However, when localized in the brain or spinal cord, they always turn out to be malignant, because even with slow growth, they exert pressure on vital centers and cause disruption of their functions

Tumors of the nervous system are divided into:

*Tumors of the nervous system and meninges.*

Output cell	Benign tumors	Malignant tumors
Tumors of central nervous tissue		
<u>Neuroectodermal tumors</u>		
<i>Astrocytic tumors</i>		
Astrocyte, astroblast	Astrocytoma	Astroblastoma
<i>Oligodendroglial tumors</i>		
Oligodendrogliaocyte	Oligodendroglioma	Oligodendroglioblastoma
<i>Ependymal tumors and tumors of the choroid epithelium</i>		
Ependymocyte, Ependymoblast, Choroidepithelium	Ependymoma Choroid papilloma	Ependymoblastoma Choroid carcinoma
<i>Neuronal tumors</i>		
Ganglioneurocyte Ganglioneuroblast	Ganglioneuroma (gangliocytoma)	Ganglioneuroblastoma Neuroblastoma
<i>Low differentiation and embryonal tumors</i>		
Medulloblast Glioblast		Medulloblastoma Glioblastoma
<u>Meningovascular tumors</u>		
Meningothelioma	Meningioma	Meningeal sarcoma
Tumors of the autonomic nervous system		

Sympathogonia Ganglioneuroblast Ganglioneurocyte Cells of non-chromaffin paraganglia	Ganglioneuroma Two-grade non-chromaffin paraganglioma (glomus tumor, chemodectoma)	Sympathoblastoma (sympathogonioma) Ganglioneuroblastoma Malignant non-chromaffin paraganglioma (hemodectoma)
Tumors of the peripheral nervous system		
Lemocyte (the so-called Schwann cell)	Neurolemoma (schwannoma), Neurofibromatosis (Recklinghausen's disease)	Malignant neurilema (neurogenic sarcoma)

**Neuroectodermal**(neuroepithelial) tumors of the brain and spinal cord are built from neuroectoderm derivatives. More often than tumors of other organs, they have a dysontogenetic origin, that is, they develop from the remnants of precursor cells of mature elements of the central nervous system, so their histological affiliation is sometimes difficult to establish. The cellular composition of these tumors corresponds to certain phases of development of neuronal and glial elements of the nervous system. Neuroectodermal tumors include: astrocytic, oligodendroglial, ependymal and choroidal epithelium tumors; neuronal, poorly differentiated and embryonic. Malignant neuroectodermal tumors metastasize, as a rule, within the cranial cavity and very rarely - in internal organs.

**Astrocytic tumors**(gliomas) are divided into benign - astrocytoma and malignant - astroblastoma (malignant astrocytoma).

*Astrocytoma*– the most common benign neuroectodermal tumor that develops from astrocytes; observed at a young age, sometimes in children; is localized in all parts of the brain. The size of the tumor reaches 5–10 cm in diameter; it is not always clearly separated from the adjacent tissue; on autopsy it has a homogeneous appearance, sometimes cysts are found in the tumor; the tumor grows slowly, there

are few vessels in it.

Depending on the histological structure of the tumor, three types of astrocytes are distinguished: fibrillar, protoplasmic and fibrillar-protoplasmic (mixed). Fibrillary astrocytoma is rich in glial fibers arranged in the form of parallel bundles; there are few astrocyte-type cells in the tumor. Protoplasmic astrocytoma is made up of astrocyte-like cells of various sizes and shapes with processes that intertwine to form a dense mesh. Fibrillary-protoplasmic (mixed) astrocytoma is characterized by an even arrangement of astrocytes and glial cells with appendages; is rare.

*Astroblastoma*(malignant astrocytoma) differs in cellular polymorphism, possible necrosis and hemorrhage; metastasizes through the cerebrospinal fluid, grows quickly, is rare.

**Oligodendroglial tumors** can be both benign - oligodendroglioma, and malignant - oligodendroglioblastoma.

*Oligodendroglioma*- a mature tumor, more common in women aged 30-40 years. It is localized mostly in the frontal and temporal regions, as well as in subcortical nodes. Oligodendroglioma has the appearance of a cell of homogeneous grayish-white tissue. It is made of small cells with small hyperchromic round nuclei that seem to "hang" in the light cytoplasm, the development of small cysts filled with mucous masses is possible. The tumor is highly vascularized by capillary pressure vessels. Oligodendroglioblastoma (malignant oligodendroglioma) is characterized by both tissue and cellular atypism, pathological mitoses; necroses and hemorrhages occur quite often.

### **Ependymal tumors and tumors of the choroid epithelium**

Benign tumors of the specified origin include ependymoma and choroid papilloma, and malignant tumors include ependymoma and choroid carcinoma.

*Ependymoma*- a mature tumor, observed mostly in childhood and young age, is related to the ependyma of the ventricles of the brain by its origin. It has the appearance of an intra- or extraventricular nodule of gray color, quite often with foci of necrosis and cysts. Typical for this tumor are accumulations of uni- or bipolar round and oval ependymal cells that form pseudo-rosettes around vessels containing chromatin in the form of grains.

*Ependyoblastoma*- this is the largest tumor of the hemispheres in children, is a malignant variant of ependymoma (malignant ependymoma), differs from a benign tumor by sharply expressed cellular polymorphism, many mitoses and vascular reactions. It can resemble glioblastoma in adults, and medulloblastoma in children. The tumor grows rapidly, intensively penetrates into the adjacent tissues and gives metastases in the subarachnoid space.

*Choroid papilloma* (choroid papilloma) is a mature tumor that develops from the epithelium of the vascular plexus of the ventricles of the brain; has the appearance of a villous node in the cavity of the ventricles of the brain; consists of numerous villous structures covered with a layer of epithelial cells similar to the epithelium of a normal vascular plexus.

*Choroid carcinoma*(malignant choroidal papilloma) externally has the appearance of a node located in the cavity of the ventricles, the tumor is connected to the vascular plexus. Built from anaplastic cells of vascular plexus (papillary cancer); is extremely rare.

### **Neuronal tumors**

Cells of neural origin include ganglioneuroma (gangliocytoma), ganglioneuroblastoma (malignant gangliocytoma) and neuroblastoma. Ganglioneuroma (gangliocytoma) is a rare benign tumor that is localized in the region of the floor of the III ventricle; less often - in the cerebral hemispheres. The tumor is made of mature ganglion cells separated by bundles of glial stroma into areas of different sizes.

*Ganglioneuroblastoma* - malignant analogue of ganglioneuroma (malignant gangliocytoma) - an extremely rare tumor of the central nervous system. It is distinguished by sharply expressed cellular polymorphism; similar to malignant glioma.

*Neuroblastoma* – a rare highly malignant brain tumor; occurs in children. Built from large polygonal cells with a vesicular nucleus, numerous mitoses; cells form syncytial structures; there are many thin-walled vessels in the tumor.

### **Low-differentiated and embryonal tumors**

Tumors of this origin include medulloblastoma and glioblastoma. Medulloblastoma is a tumor that is built from the most immature cells - medulloblasts, therefore it is characterized by particularly pronounced immaturity and malignancy; its most frequent localization is the cerebellar worm. The tumor occurs mostly in children, more often in boys aged 2–7 years.

*Glioblastoma* - an immature malignant tumor, the second most common brain tumor after astrocytoma. It occurs most often in people aged 40-60 years; is localized in the white matter of the brain. It has a soft consistency; on autopsy, it is shriveled due to the presence of necrosis and hemorrhages in it. Histologically, the tumor is made up of cells of different sizes, which differ in the shape of the nuclei and the content of chromatin in them. There is a lot of glycogen in the cells, many mitoses. The tumor grows rapidly and can lead the patient to death within several months. Metastases are found only within the brain.

**Meningovascular tumors** develop from the membranes of the brain, as well as from tissue close in structure to the membranes. The most common among them are: meningioma and meningeal sarcoma

*Meningioma* (arachnoidendothelioma) is a benign tumor from the cells of the medulla. In cases where a meningioma is made of arachnoidendothelial cells, i.e. cells that cover the spider web, it is called arachnoidendothelioma. The tumor has the appearance of a dense nodule connected to a hard, less often soft meninges and is made of endothelium-like cells that closely adhere to each other, forming nest-like structures. Often, cells form microconcentric structures (arachnoidendotelioma), where lime can accumulate, which leads to the formation of so-called psamoma bodies. A meningioma can be made up of spindle-shaped cells that form bundles and connective tissue fibers (fibrous arachnoidendothelioma).

*Meningeal sarcoma*- malignant analogue of meningioma.

On histological examination, it resembles fibrosarcoma, polymorphic cell sarcoma, or diffuse membrane sarcomatosis.

**Tumors of the autonomic nervous system** develop from ganglion cells of

different maturity (sympathogonia, sympathoblasts, ganglioneurocytes) of sympathetic ganglia, as well as from cells of non-chromaffin paraganglia (glomus), genetically related to the sympathetic nervous system. This group of tumors includes: benign - ganglioneuroma, benign non-chromaffin paraganglioma (glomus tumor, chemodectoma) and malignant - ganglioneuroblastoma, sympathoblastoma (sympathogonioma) and malignant non-chromaffin paraganglioma (hemodectoma). Some of the described tumors were previously discussed in other sections.

*Benign non-chromaffin paraganglioma*(hemodectoma) is morphologically similar to tumors of the ARUD system (apudomas), capable of synthesizing serotonin and, less often, ACTH. The tumor can reach significant sizes, especially. retroperitoneal In histological examination, the alveolar or trabecular structure is characteristic; it has a large number of sinusoidal vessels.

*Malignant non-chromaffin paraganglioma* is rare; is characterized by cellular polymorphism, infiltrating growth and lymphohematogenic metastases. Sympathoblastoma (sympathogonioma) is an extremely malignant tumor, found mostly in young children.

### **Tumors of the peripheral nervous system.**

This type of tumor arises, as a rule, from nerve sheaths. They include: benign - neurillemmoma (schwannoma), neurofibroma, as well as neurofibromatosis (Recklinghausen's disease) and malignant - malignant schwannoma, or neurogenic sarcoma.

*Neurolemmoma* (schwannoma) is made of spindle-shaped cells with rod-shaped nuclei. The cells and fibers of the tumor form bundles that form rhythmic or "palisade" structures (nuclear palisades, Veroca's bodies) with sections that consist of fibers.

*Neurofibroma* – a tumor associated with nerve sheaths. Histologically, it consists of elements of connective tissue, nerve cells and fibers.

*Neurofibromatosis*(Recklinghausen's disease) is a systemic disease characterized by the development of multiple neurofibromas,

which are often associated with various developmental defects. There are peripheral and central forms of neurofibromatosis.

*Malignant neurilemmoma* (neurogenous sarcoma) is a rare tumor characterized by pronounced cellular atypism and polymorphism, the presence of multinucleated symplasts and "palisade" structures.

## **LEUKEMIA (LEUKEMIA) AND LYMPHOMAS.**

Special pathological anatomy studies the material substrate of the disease, that is, it is a subject of nosology. Nosology (from the Latin *noso* - disease and *logos* - teaching) - the study of diseases, involves knowledge of etiology, pathogenesis, manifestations (clinical and morphological) and consequences of the disease, classification and nomenclature of diseases, variability (pathomorphosis), as well as the construction of a diagnosis, principles treatment and prevention.

A disease is understood as a violation of the vital activity of the body under the influence of a certain cause. The essence of the disease is solved ecologically (from the Greek *oikos* - home, dwelling), that is, in terms of disturbed normal relations of the organism with the environment. This interpretation of the disease developed in the second half of the 19th century. Prominent Russian clinician O.O. Ostroumov - considered the disease as a violation of the normal life of a person with the conditions of his existence in the environment. S.P. Botkin believed that disease is a reaction of the body to the harmful effects of the external environment.

K. Bernard defined the disease as a violation of the physiological balance of the body. The interpretation of the disease in the ecological plan allows us to put forward the following theoretical propositions, which must be taken into account when studying the disease:

1. The disease is not brought from outside, but is a process of coexistence of the human organism with the environment - a conflict between a person and the circumstances of his life and work. Therefore, the opposition of disease to health is not justified. Both are just forms of coexistence of the human body with the environment.



2. External causative factors play a leading role in the etiology of the disease.

Internal causal factors, especially hereditary factors of the disease, had their external causes in the distant past.

3. Illness, as a new quality in the vital activity of the organism, develops on a physiological basis. From this, it should be recognized that the study of pathogenesis is based on the analysis of physiological processes, which acquire only a different quality during illness.

4. In the manifestations of the disease, in addition to damage (fracture according to I.P. Pavlov) under the influence of a certain cause, adaptive and compensatory reactions, which are a component of pathogenesis, are vividly presented.

5. Clinical manifestations of the disease are derived not from morphological ones at all, but from the ratio of destructive processes (damage) and restoration processes (reparation, adaptation, compensation), reflecting either the superiority of the latter over the former (recovery), or the insufficiency of the latter (progression of the disease, transformation into a chronic state ) (D.S. Sarkisov, 1988).

6. The ratio of structural changes and clinical manifestations of the disease in its different periods is not the same (D.S. Sarkisov, 1988): in the first stage of the disease, structural changes in organs and tissues, thanks to the activation of adaptive and compensatory processes, prevent its clinical manifestations (symptomless preclinical period ), during the recovery period, on the contrary, the normalization of the impaired functions occurs before the restoration of the damaged structure, that is, the morphological manifestations of full recovery are delayed compared to the clinical ones (symptomatic post-clinical period).

7. The division of diseases into organic and functional is not carried out nowadays, because any functional disorder finds its material (structural) expression.

8. The disease can undergo a certain evolution, i.e. change (pathomorphosis).

Variability of the disease can be natural (natural pathomorphosis) or induced by man (induced pathomorphosis).

Classification of diseases takes into account the following signs:

1. Etiological, which allows dividing diseases into hereditary (congenital) and acquired, and the latter into non-infectious and infectious.

2. Anatomical and topographic, i.e. localization of the main focus of damage. In this regard, diseases of organ systems (diseases of the cardiovascular system), organs (diseases of cells) and tissues (diseases of connective tissue) are distinguished.

3. The commonality of pathogenetic mechanisms, on the basis of which allergic, autoimmune and rheumatic diseases are distinguished.

4. The commonality of socially mediated influence on the organism of environmental factors, which is the basis of the origin of occupational diseases, geographical and military pathology, etc.

5. Common forms of development and course of diseases make it possible to distinguish the most acute, acute, subacute and chronic, as well as cyclic and acyclic diseases.

6. Sex and age, which are used in the selection of female, male and children's diseases, as well as diseases of the elderly. When classifying diseases, their nomenclature is followed.

**Diseases of the blood system** constitute the content of clinical hematology, the founders of which in our country are I.I. Mechnikov, S.P. Botkin, M.I. Arinkin, O.I. Kryukov, I.O. Kasirskyi. These diseases develop as a result of disturbances in the regulation of hematopoiesis and hematopoiesis, which is reflected in the composition of peripheral blood. Therefore, based on the data of the study of the composition of peripheral blood, it is possible to roughly judge the state of the hematopoietic system as a whole. Yes, we can talk about changes in red and white sprouts, as well as blood plasma, both quantitatively and qualitatively.

Changes in the red germ of the blood system may refer to a decrease in the hemoglobin content and the number of erythrocytes (anemia) or their increase (true, real polycythemia or erythremia); disorders of the shape of

erythrocytes - erythrocytopathy (microspherocytosis, ovalocytosis) or hemoglobin synthesis - hemoglobinopathy or hemoglobinosis (thalassemia, sickle cell anemia), (hemoblastosis). It is equally possible to talk about an increase in the number of platelets (thrombocytosis) or their decrease (thrombocytopenia) in peripheral blood, as well as changes in their quality (thrombocytopathy).

Changes in blood plasma concern mainly its proteins. Their number can increase (hyperproteinemia) or decrease (hypoproteinemia); the quality of plasma proteins can also change, then they speak of dysproteinemia.

The most complete picture of the state of the hematopoietic system is provided by the study of bone marrow punctate (sternum) and trepanobiopsy (iliac crest), which are widely used in the hematological clinic. Diseases of the blood system are extremely diverse. Anemias, hemoblastoses (neoplastic diseases arising from hematopoietic cells), thrombocytopenia and thrombocytopathy are of greatest importance.

Changes in the white germ of the blood system concern both leukocytes and platelets. The number of leukocytes in the peripheral blood may increase.

Tumors of the blood system or hemoblastosis are divided into two groups:

**leukemia**- systemic tumor diseases of hematopoietic tissue;

**lymphomas**– regional tumor diseases of hematopoietic and/or lymphatic tissue.

Classification of hematopoietic and lymphatic tissue tumors:

I. Leukemias are systemic tumor diseases.

A. Acute leukemias: 1) undifferentiated; 2) myeloblastic; 3) lymphoblastic; 4) plasmablastic; 5) monoblastic (myelomonoblastic); 6) erythromyeloblastic; 7) megakaryoblastic.

B. Chronic leukemias.

Myelocytic origin: 1) chronic myeloid; 2) chronic erythromyelosis; 3) erythremia; 4) true polycythemia (Vaquez-Osler syndrome).

Lymphocytic origin: 1) chronic lymphocytic leukemia; 2) lymphomatosis of the skin (Sézary's disease); 3) paraproteinemic leukemias: a) myeloma

disease; b) primary macroglobulinemia (Waldenstrom's disease); c) disease of heavy chains (Franklin's disease).

Monocytic origin: 1) chronic monocytic leukemia; 2) histiocytosis (histiocytosis X).

II. *Lymphomas*- regional tumor diseases.

Lymphosarcoma: lymphocytic, prolymphocytic, lymphoblastic, immunoblastic, lymphoplasmacytic; African lymphoma (Burkitt's tumor). Fungal mycosis. Sézary's disease. Reticulosarcoma. Lymphogranulomatosis (Hodgkin's disease).

Leukemias are systemic tumor diseases of hematopoietic tissue

*Leukosis*(leukemia) are characterized by systemic progressive growth of hematopoietic cells of tumor origin - leukemic cells. At first, tumor cells grow in hematopoietic organs (bone marrow, lymph nodes, spleen), then they are hematogenously migrated to other organs and tissues, forming leukemic (leukemic) infiltrates around blood vessels, in their walls; dystrophy and atrophy develop in the parenchymal elements and then they die. Infiltration by tumor cells can be diffuse (leukemic infiltration of the spleen, liver, kidneys, mesentery), which causes a sharp increase in organs and tissues, or focal - with the formation of tumor nodes that grow into the capsule of organs and adjacent tissues. Quite often, tumor nodes appear against the background of diffuse leukemic infiltration, however,

The appearance of leukemic cells in the peripheral blood is quite typical for leukemias.

Incessant growth of leukemic cells in organs and tissues, their "flooding" of blood leads to anemia and hemorrhagic syndrome, severe dystrophic changes in parenchymal organs. Severe ulcerative-necrotic changes and complications of an infectious nature - sepsis - develop as a result of suppression of immunity in leukemia.

The question of the etiology of leukemias and tumors is closely related, because the tumor origin of leukemias is beyond doubt. Leukemias are polyetiological diseases, various factors are responsible for their occurrence, which can cause mutation of cells of the hematopoietic system.

Mutagens include viruses, ionizing radiation, and some chemicals.

The importance of viruses in the development of leukemia is shown in experiments on animals. In humans, it has been proven in cases of acute endemic T-lymphocytic leukemia (retrovirus HTLV-I), hairy cell leukemia (retrovirus HTLV-II) and Burkitt's lymphoma (Abstein-Barr DNA virus).

It is also known that ionizing radiation can cause the development of leukemia (radiation or radiation leukemia), and the frequency of mutations depends directly on the dose of ionizing radiation. After the atomic explosion in Hiroshima and Nagasaki, the number of patients with acute and chronic leukemia among those irradiated increased by 7.5 times.

Dibenzanthracene, benzpyrene, methylcholanthrene, i.e., blastomogenic substances, are chemicals that can cause leukemia.

The pathogenesis of leukemia is associated with the activation of cellular oncogenes (proto-oncogenes) under the influence of various etiological factors, which leads to impaired proliferation and differentiation of hematopoietic cells with subsequent malignant transformation. Increased expression of a number of proto-oncogenes has been registered in humans: ras (1st chromosome) – in various leukemias; sis (22nd chromosome) – in chronic leukemia; tus (8th chromosome) - in Burkitt's lymphoma.

The importance of hereditary factors in the development of leukemia is emphasized by the family nature of the disease. When studying the karyotypes of leukemic cells, changes in the set of their chromosomes are revealed - chromosomal aberrations. In chronic myeloma leukemia, for example, a decrease in the autosome of the 22nd pair of chromosomes of leukemic cells (Ph' - chromosome or Philadelphia chromosome) is constantly found. Ph' chromosome is also found in children with Down's disease, leukemia is 10-15 times more common among them.

Thus, the mutational theory of leukemia pathogenesis is the most likely. At the same time, the development of leukemia is subject to the rules of tumor progression. The change of monoclonality of leukemic cells to polyclonality is at the basis of the appearance of blast cells, their removal from the bone marrow and the progression of the disease - the blast crisis.

Depending on the degree of increase or decrease in the total number of leukocytes in the peripheral blood, including leukemic cells, leukemic cells are distinguished (tens and hundreds of thousands of leukocytes in 1  $\mu$ l of blood); subleukemic (no more than 15,000–25,000 in 1  $\mu$ l of blood), leukopenic (decrease in the number of leukocytes, but leukemic cells are detected) and leukemic (leukemic cells in the blood are absent) variants of leukemia.

Depending on the degree of differentiation (maturity) of blood tumor cells and the nature of the course (malignant or benign), leukemias are divided into acute and chronic.

Acute leukemia is characterized by the proliferation of undifferentiated or poorly differentiated blast cells ("blast" leukemias) and a malignant course; for chronic leukemia - proliferation of differentiated leukemic cells ("cytary" leukemias) and relative benign course.

Taking into account the histo(cyto)genesis of leukemic cells, histo(cyto)genetic forms of both acute and chronic leukemia are distinguished. In recent years, in connection with new ideas about hematopoiesis, the histogenetic classification of leukemias has undergone significant changes. The main feature of the new hematopoietic scheme is the selection of classes of precursor cells of various hematopoietic germs.

Based on modern ideas about hematopoiesis, the following histogenetic forms are distinguished among acute leukemias: undifferentiated, myeloblastic, lymphoblastic, monoblastic (myelomonoblastic), erythromyeloblastic and megakaryoblastic. Undifferentiated acute leukemia develops from precursor cells of the first three classes, which are devoid of morphological signs of belonging to one or another series of hematopoiesis. Other forms of acute leukemia originate from progenitor cells of class IV, that is, from blast cells.

*Chronic leukemias* depending on the number of maturing cells of hematopoiesis from which they arise, they are divided into: 1) leukemias of myelocytic origin; 2) leukemia of lymphocytic origin; 3) leukemias of monocytic origin. Chronic leukemias of myelocytic origin include: chronic myeloid leukemia, chronic erythromyelosis, erythremia, true polycythemia. Chronic leukemias of lymphocytic origin include: chronic lymphocytic

leukemia, lymphomatosis of the skin (Sézary's disease) and paraproteinemic leukemias (myeloma disease; Waldenström's primary macroglobulinemia; Franklin's heavy chain disease). Leukemias of monocytic origin are monocytic (myelomonocytic) leukemia and histiocytosis (histiocytosis X).

The pathological anatomy of leukemias is peculiar and applies to both acute and chronic forms. There is a certain specificity of various types of them.

*Acute leukemias.* A diagnosis of acute leukemia is possible only when blast cells are found in the bone marrow (punctate from the sternum). Sometimes their number is 10–20%, but then a cluster of dozens of blasts is found in the trepanation from the iliac bone. In acute leukemia, both in the peripheral blood and in the myelogram, the so-called leukemic failure is found - a sharp increase in the number of blasts and single mature elements in the absence of transitional maturing forms.

Acute leukemias are characterized by replacement of the bone marrow with young blast elements and their infiltration of the spleen, liver, lymph nodes, kidneys, brain and its membranes, and other organs, the degree of which varies depending on the form of leukemia. The form of acute leukemia is established by cytochemical examination of blast cells. When treating patients with acute leukemia with cytostatic drugs, bone marrow aplasia and pancytopenia may develop.

Acute leukemias in children have some features. In comparison with acute leukemias in adults, they occur much more often and are characterized by a wider spread of leukemic infiltration in both hematopoietic and non-hematopoietic organs (except gonads). In children, leukemias with nodular (tumor-like) infiltrates are observed more often than in adults, especially in the region of the thymus gland; acute lymphoblastic (T-dependent) leukemia is more common; less often - myeloblastic leukemia. Congenital leukemia and chloroleukosis are special forms of acute leukemia in children.

*Acute undifferentiated leukemia.* This form of leukemia is characterized by infiltration of the bone marrow, spleen, lymph nodes, lymphoid formations (tonsils, group lymphatic and solitary follicles), vessel walls, kidneys and other organs by undifferentiated hematopoietic cells. Leukemic infiltration in such

leukemias is monotonous; the spleen and liver are moderately enlarged. The bone marrow of flat and tubular bones is red, juicy, sometimes with a gray tint. In connection with leukemic infiltration of the mucous membrane of the oral cavity and tonsils, necrotic gingivitis occurs, tonsillitis - necrotic tonsillitis. Sometimes leukemia is joined by a secondary infection, then undifferentiated acute leukemia proceeds as a septic disease.

Leukemic infiltration of tissues and organs is often associated with hemorrhagic syndrome, the development of which can be explained not only by the destruction of blood vessel walls by leukemic cells, but also by anemia, impaired platelet formation due to the replacement of bone marrow by undifferentiated cells of hematopoiesis. Hemorrhages occur in the skin, mucous membranes, internal organs, quite often in the brain.

Patients with this form of leukemia die from brain hemorrhages, gastrointestinal bleeding, necrotic-ulcerative complications, and sepsis.

*Acute myeloblastic leukemia*(acute myelogenous leukemia). In this form of acute leukemia, there is infiltration of the bone marrow, liver, spleen, kidneys, less often lymph nodes and skin by tumor cells of the myeloblastic series with cytochemical features: glycogen, sudanophilic inclusions are found in them; show a positive reaction to peroxidase, anaphtylesterase and chloroacetate esterase.

The bone marrow becomes red or grayish, sometimes it acquires a purulent shade (pyoid bone marrow). The spleen and liver due to leukemic infiltration increase, but slightly; the same changes occur in the lymph nodes. Infiltration by blast cells is quite characteristic not only of the bone marrow, spleen and liver, but also of the mucous membrane of the gastrointestinal tract, as a result of which necrosis occurs in the oral cavity, tonsils, throat, and stomach. Both diffuse and focal (tumorous) infiltrates are found in the kidneys. In 1/3 of cases, leukemic infiltration of the lungs develops ("leukemic pneumonitis"); in 1/4 cases – leukemic infiltration of the meninges ("leukemic meningitis"); pronounced hemorrhagic diathesis. Hemorrhages are observed in mucous and serous membranes, internal organs. Patients die from bleeding,

In recent years, active treatment of patients (cytostatic drugs, antibiotics)



has significantly changed the picture of acute undifferentiated and myeloblastic leukemia. Multiple necrosis in the oral cavity and throat are rare, hemorrhagic diatheses have decreased. At the same time, as a result of the increase in life expectancy, such extraosseous changes as "leukemic pneumonitis" and "leukemic meningitis" are more common in patients with acute leukemia. In connection with the treatment of patients with cytostatic drugs, cases of necrotic-ulcerative changes in the gastrointestinal tract are more common.

*Acute promyelocytic leukemia.* This form of leukemia differs from other acute leukemias in the severity of the course, malignancy and significant hemorrhagic syndrome (thrombocytopenia, hypofibrinogenemia). Leukemic cells infiltrating organs and tissues are characterized by the following morphological features: nuclear and cellular polymorphism, accumulation of pseudopodia and glycosaminoglycan granules in the cytoplasm. Almost all patients with this form of leukemia die from brain hemorrhages or from gastrointestinal bleeding.

*Acute lymphoblastic leukemia* occurs much more often in children (80% of cases) than in adults. Leukemic infiltrates predominate in the bone marrow, lymph nodes, lymphatic apparatus of the gastrointestinal tract, spleen, kidneys, and thymus gland. Bone marrow of cancellous and tubular bones is crimson-red, juicy. The spleen is sharply enlarged, juicy, red. Lymph nodes are also significantly enlarged due to their infiltration by lymphoblastic cells; on dissection, they are white-pink, juicy. The thymus gland, which can reach gigantic sizes, has a similar appearance. Sometimes the leukemic infiltrate goes beyond the gland and spreads to the anterior mediastinum, compressing the organs of the chest cavity.

In this form of leukemia, leukemic infiltrates consist of lymphoblasts, the characteristic feature of which is the accumulation of glycogen around the nucleus. Lymphoblasts belong to the T-system of lymphopoiesis, which can explain both the rapid distribution of blasts in the T-dependent zones of the lymph nodes and the spleen, as well as the increase in the size of the latter simultaneously with leukemic infiltration of the bone marrow. A sign of the progression of leukemia can be considered lymphoblastic infiltrates of

metastatic origin outside the lymphatic tissue. Especially often, such infiltrates are found in the membranes and substance of the brain and spinal cord, which is called neuroleukosis.

Acute lymphoblastic leukemia can be treated with cytostatic drugs. In 90% of sick children, it is possible to obtain a stable long-term (5–10 years) remission. Without treatment, the course of this form, like other acute leukemias, progresses: anemia increases, hemorrhagic syndrome develops, complications of infectious origin appear.

*Acute plasmablastic leukemia.* This form of acute leukemia arises from precursor cells of B-lymphocytes capable of producing immunoglobulins; this ability is also preserved in tumor plasmablasts. Pathological immunoglobulins - paraproteins are formed and then secreted in them, therefore acute plasmablastic leukemia should be classified as paraproteinemic hemoblastoses. Plasmablastic leukemic infiltration is found in the bone marrow, spleen, lymph nodes, liver, skin; a significant number of plasmablasts is also found in peripheral blood.

Acute monoblastic (myelomonoblastic) leukemia is almost indistinguishable from acute myeloblastic leukemia.

*Acute erythromyeloblastic leukemia.* This is a rather rare form (1–3%) among all forms of acute leukemia, in which the growth of both erythroblasts and other nuclear cells of erythropoiesis, as well as myeloblasts, monoblasts, and undifferentiated blasts occurs in the bone marrow. Anemia, leuko- and thrombocytopenia occur as a result of inhibition of hematopoiesis; at the same time, the spleen and liver increase in size.

Acute megakaryoblastic leukemia. One of the rarest forms of acute leukemia, which is characterized by the presence in the blood and bone marrow of undifferentiated blasts as well as megakaryoblasts, distorted megakaryocytes and accumulations of platelets; the number of platelets in the blood increases to 1,000 - 1,500\*10<sup>9</sup>/l.

*Chronic leukemias.*

*Chronic leukemias of myelocytic origin.* Such forms of leukemia are diverse in origin and morphological changes, however, the main place among

them is occupied by chronic myeloid leukemia, chronic erythromyelosis, erythremia and true polycythemia.

*Chronic myeloid leukemia*(chronic myelosis). This form of leukemia runs into two stages: monoclonal benign and polyclonal malignant. The first stage, which takes several years, is characterized by the progressive growth of neutrophilic leukocytes with a shift to myelocytes and myeloblasts, and an increase in the spleen. Bone marrow cells in this stage of leukemia do not differ morphologically and in their ability to phagocytosis from normal cells, however, they contain the so-called Ph-chromosome (Philadelphia), which arises as a result of the deletion of chromosomes of the 22nd pair. In the second stage, which lasts from 3 to 6 months (terminal stage), monoclonality changes to polyclonality. As a result, blast forms appear (myeloblasts, less often erythroblasts, monoblasts and undifferentiated blast cells), the number of which increases both in the bone marrow and in the blood (blast crisis).

At the autopsy of those who died from chronic myeloid leukemia in the terminal stage, changes are found in the bone marrow, spleen, liver, lymph nodes, and blood. Bone marrow of flat bones, epiphyses and diaphyses of tubular bones is juicy, gray-red or gray-yellow purulent (pioid bone marrow). During histological examination, promyelocytes and myelocytes, as well as blast cells, are found in the bone marrow. There are cells with distorted nuclei and altered cytoplasm, phenomena of karyopyknosis and karyolysis. Reactive osteosclerosis is possible in bone tissue. Blood is gray-red; internal organs are anemic.

The spleen is sharply enlarged, sometimes occupying almost the entire abdominal cavity; its weight reaches 6–8 kg. At autopsy, it is dark red in color, sometimes with ischemic heart attacks. The tissue of the spleen is displaced by a leukemic infiltrate, mainly from cells of the myeloid series, among which blasts are visible; follicles are atrophied; sclerosis and hemosiderosis of the pulp are found. Leukemic thrombi are found in blood vessels.

The liver is significantly enlarged (its weight reaches 5–6 kg). The surface is smooth, the tissue is grey-brown on dissection. Leukemic infiltration prevails along the sinusoids, less often in the portal tracts and capsule. Fatty

dystrophy in hepatocytes; sometimes hemosiderosis is possible.

Lymph nodes are significantly enlarged, soft, gray-red in color with leukemic infiltration. The same infiltration is observed in the tonsils, group and solitary lymphatic follicles, intestines, kidneys, skin, sometimes in the brain and meninges (neuroleukemia). A significant number of leukemic cells appear in the vessels, which form leukemic stasis and thrombi and infiltrate the vessel wall. Such changes in blood vessels can be the cause of heart attacks and hemorrhages. Manifestations of autoinfection are quite often found in chronic myeloid leukemia.

A group related to chronic myeloid leukemia consists of osteomyeloleukosis and myelofibrosis, in which, along with the signs of myeloid leukemia, bone marrow is replaced by bone or connective tissue. In such cases, the process is characterized by a long benign course.

Treatment of patients with cytostatic drugs changes the morphological manifestations of chronic myelogenous leukemia. Along with the suppression of leukemic infiltration centers and the development of fibrosis in their place, the rejuvenation of cellular forms, the appearance of metastatic centers and tumor growths or bone marrow aplasia and pancytopenia are noted.

*Chronic erythromyelosis*- a rather rare form of leukemia. This is a tumor of the red and white germ of the hematopoietic tissue, in which erythrocytes, myelocytes, promyelocytes and blasts grow in the bone marrow, spleen and liver. A significant part of these cells is also found in the peripheral blood. Severe splenomegaly. In some cases, myelofibrosis (Vagan's form of chronic erythromyelosis) joins.

*Erythremia*. This form of leukemia mostly occurs in the elderly and is characterized by an increase in the mass of erythrocytes in the peripheral blood, that is, a plethora. The number of platelets and granulocytes also increases, blood pressure rises, tendency to thrombosis, splenomegaly appear. All sprouts grow in the bone marrow, but mainly erythrocyte sprouts. The process is benign for a long time, but often ends with transformation into chronic myeloid leukemia with foci of leukemic infiltration in the organs.

All internal organs are full of blood with the formation of blood clots in

both veins and arteries. Adipose bone marrow of tubular bones becomes red; the spleen increases sharply. There is hypertrophy of the heart, especially the left ventricle. In the spleen, kidneys, and liver in the early stage of erythremia, there are foci of extramedullary hematopoiesis with a significant number of megakaryocytes, and in the late stage, when the process transforms into myeloid leukemia, foci of leukemic infiltration appear.

*Polycythemia vera* (Vakez-Osler disease) is close to erythremia in many morphological features.

*Chronic leukemias of lymphocytic origin.* These forms of leukemia are divided into two groups: the first is chronic lymphocytic leukemia and skin lymphoma bordering on it (Sézary's disease); the second - paraproteinemic leukemias.

*Chronic lymphocytic leukemia.* It often occurs in middle-aged and elderly people, in some cases - in members of the same family; arises from B-lymphocytes and is characterized by a long benign course. The number of leukocytes in the blood increases sharply (up to  $100 \times 10^9/l$ ), lymphocytes predominate among them. Leukemic infiltrates from tumor lymphocytes are most pronounced in the bone marrow, lymph nodes, spleen, and liver with successive enlargement of these organs. Tumor B-lymphocytes almost do not produce immunoglobulins. In this regard, with chronic lymphocytic leukemia, humoral immunity is sharply suppressed, patients often have complications of infectious origin. This form of leukemia is characterized by the development of autoimmune reactions, especially autoimmune hemolytic and thrombopenic states.

Against the background of a benign course of chronic lymphocytic leukemia, the following are possible: blast crisis, generalization of the process leading to death, but more often patients die from infectious diseases or complications of autoimmune origin.

At autopsy, morphological changes are found in the bone marrow, lymph nodes, spleen, liver, and kidneys.

The bone marrow of flat and tubular bones is red in color, however, unlike myeloid leukemia, there are yellow cells in the diaphyses of tubular

bones among the red bone marrow. During histological examination, tumor cells are found in the bone marrow. In extreme cases, the entire myeloid tissue of the bone marrow is squeezed out by leukemic lymphocytic infiltrates, and only minor islands of myeloid hematopoiesis remain.

Lymph nodes of all areas of the body are sharply enlarged and form large soft or dense packages. On dissection, they are juicy, white-pink in color. Tonsils, group and solitary lymphatic follicles of the intestine, which also represent a white-pink juicy tissue, increase. The increase in lymph nodes and formations is associated with their leukemic infiltration, which leads to a sharp violation of the structure of these organs and tissues; quite often, lymphoblasts infiltrate the capsule of the nodes, as well as the tissues adjacent to them.

The spleen reaches significant sizes, its mass increases to 1 kg. On autopsy, the tissue is red in color, fleshy in consistency; follicles are preserved or lost in the pulp. Leukemic lymphocytic infiltrates occur primarily in the follicles, which become enlarged and connect with each other. Later, lymphocytes grow in the red pulp, vessel walls, trabeculae, and capsule.

The liver is enlarged, dense; on dissection, it is light brown with small gray-white nodules on the surface. Leukemic lymphocytic infiltration occurs along the portal tracts. In hepatocytes - protein and fatty dystrophy.

The kidneys are large, dense, gray-brown. Leukemic infiltration so dramatically disrupts the structure of the kidneys that it is even impossible to distinguish its layers.

Leukemic infiltration involves many organs and tissues (myocardium, mediastinum, serous and mucous membranes). It is not only diffuse, but also focal, forming nodes of significant size.

Changes characteristic of chronic lymphocytic leukemia are supplemented by infectious complications, for example, pneumonia, as well as manifestations of hemolytic conditions - hemolytic jaundice, general hemosiderosis, and diapedesis hemorrhages.

It should be borne in mind that in addition to widespread damage to the lymph nodes, moderate enlargement of the spleen and liver in chronic lymphocytic leukemia, there are cases when only some groups of lymph nodes

(mediastinum, mesentery, cervical, inguinal) are sharply enlarged. In such cases, they can squeeze nearby organs (heart, esophagus, trachea and bronchi; portal vein and its branches with the development of portal hypertension and ascites).

*Lymphomatosis of the skin, or Sézary's disease.* This is a peculiar form of chronic lymphocytic leukemia, which is characterized by infiltration of tumor T-lymphocytes, first of all, of the skin. The bone marrow is gradually involved in the pathological process, the number of leukocytes in the blood increases, specific cells (Sézary cells) appear; peripheral lymph nodes and spleen are enlarged.

*Paraproteinemic leukemias.* This group of leukemias includes tumors that develop from cells of the B-lymphocytic system (precursors of plasma cells), with the function of which reactions of humoral immunity are connected. The main feature of paraproteinemic leukemias, which are also called malignant immunoproliferative diseases, is the ability of tumor cells to synthesize homogeneous immunoglobulins or their fragments - paraproteins (monoclonal immunoglobulins). Immunoglobulin pathology determines both the clinical and morphological characteristics of paraproteinemic leukemias, which include myeloma, primary macroglobulinemia (Waldenström), and heavy chain disease (Franklin).

*Myeloma disease* is a fairly common disease that was first described by O.O. Rusticy (1873) and Kaler (1887). With this disease, tumor cells of the lymphoplasmacytic line - myeloma cells grow both in the bone marrow and outside it. Myelomatosis of the bone marrow leads to the destruction of bones.

Depending on the type of cells that grow, plasmacytic, plasmablastic, polymorphic cell and small cell myeloma are distinguished. Polymorphic and small cell myeloma belong to poorly differentiated tumors. Myeloma cells secrete paraproteins, which are found in the blood and urine of patients, as well as in the myeloma cells themselves. In myeloma disease, different types of pathological immunoglobulins are biochemically isolated from blood serum and urine. There are several biochemical variants of myeloma (A-, D-, E-myeloma, Bence-Jones myeloma). Bence-Jones protein found in urine is a type of

paraprotein produced by myeloma cells; it freely penetrates through the glomerular filter of the kidneys because it has a low molecular weight.

Myeloma is mostly of the aleukemic type, but sometimes the appearance of myeloma cells in the peripheral blood is possible.

During morphological examination, depending on the type of myeloma infiltrates that appear in the bone marrow and bones, diffuse, diffuse-nodular and multiple-nodular forms of myeloma disease are distinguished. The diffuse form of myeloma is said to occur when diffuse myeloma infiltration of the bone marrow is combined with osteoporosis. In the diffuse-nodular form, tumor nodes appear against the background of diffuse myelomatosis of the bone marrow, in the multiple-nodular form, there is no diffuse myeloma infiltration.

The growth of myeloma cells is more often observed in flat bones (skull bones, ribs) and spine, less often in tubular bones (shoulder, thigh), which is accompanied by destruction of bone tissue. In the growth centers of myeloma cells in the central channel of the osteon or in the bone beam under the endosteum, the bone substance becomes fine-grained, then thins out; osteoclasts appear in it, then the endosteum exfoliates. Gradually, the entire bone beam turns into a so-called liquid bone and completely dissolves; osteon channels become wide. "Axillary resorption" of bone develops, which explains the osteolysis and osteoporosis characteristic of myeloma disease - the formation of smooth-walled, as if stamped defects in the absence or insufficient bone formation. Bones become brittle, which can explain their frequent fractures in myeloma.

In addition to bone marrow and bones, myeloma infiltration is also observed in internal organs (spleen, liver, kidneys, lungs, lymph nodes).

Some changes in the body in myeloma disease are associated with the secretion of paraprotein by tumor cells. These include: 1) amyloidosis (AL-amyloidosis); 2) deposition of amyloid-like and crystalline substances in tissues; 3) the development of paraproteinemic edema or paraproteinosis of organs (paraproteinosis of the myocardium, lungs, paraproteinemic nephrosis), which is accompanied by their functional insufficiency. Among paraproteinemic changes, paraproteinemic nephrosis or myeloma nephropathy, which can be the



cause of death in 1/3 of myeloma patients, is of great importance. At the heart of paraproteinemic nephrosis is the "clogging" of the kidneys by Bence-Jones paraprotein, which leads to sclerosis of the brain and then the cortical substance and shrinkage of the kidneys (myeloma shrunken kidneys). In some cases, paraproteinemic nephrosis is combined with kidney amyloidosis.

With myeloma disease, in connection with the accumulation of paraproteins in the blood, protein stasis in the vessels, a peculiar syndrome of increased viscosity and paraproteinemic coma develop.

In connection with the immunological defenselessness observed in patients with plasmacytoma, inflammatory changes (pneumonia, pyelonephritis) are possible, arising against the background of tissue paraproteinosis and being a manifestation of autoinfection.

*Primary macroglobulinemia*- a rare disease, which was first described by Waldenström in 1944. It is one of the types of chronic leukemia of lymphocytic origin, in which tumor cells produce and secrete pathological macroglobulin - IgM. In this disease, an increase in the spleen, liver, and lymph nodes is observed, which is associated with their leukemic infiltration; bone destruction is rare. A rather typical hemorrhagic syndrome, as a result of hyperproteinemia, increased blood viscosity, functional deficiency of platelets, slowing of blood flow and stasis in small vessels. Such complications as hemorrhages, paraproteinemic retinopathy, paraproteinemic coma, and possible amyloidosis occur quite often.

*Disease of heavy chains* described by Franklin in 1963. In this disease, tumor cells of the lymphoplasmacytic series produce a peculiar paraprotein corresponding to the Fc fragment of the IgG heavy chain (hence the name of the disease). In this disease, there is an increase in the lymph nodes, liver, and spleen as a result of their infiltration by tumor cells. Bones do not change, bone marrow damage is not necessary. Patients die from joining infectious diseases (sepsis) as a result of hypogammaglobulinemia.

*Lymphomas*- regional tumor diseases of hematopoietic and lymphatic tissue

This group of diseases includes: lymphosarcoma, mycosis fungoides,

Sézary's disease, reticulosarcoma, lymphogranulomatosis (Hodgkin's disease).

By origin, lymphomas can be B-cell and T-cell; it is based on the classification of lymphomas proposed by Lucas and Collins. According to this classification, B-cell lymphomas can be: small-cell (B), centrocytic, immunoblastic (B), plasmalymphopitar, and T-cell lymphomas - small-cell (T), from lymphocytes with twisted nuclei, immunoblastic (T), and also represented mycosis fungoides and Sézary's disease. In addition, unclassified lymphomas are also distinguished. According to this classification, both small cell and immunoblastic lymphomas can develop from either B or T cells. Only B-cells develop centrocytic and plasmalymphocytic lymphomas, and only T-cells develop lymphocyte lymphoma with twisted nuclei, mycosis fungoides, and Sézary's disease.

Lymphomas do not have any features compared to leukemias. It should be emphasized that in the conditions of modern treatment of patients with cytostatic drugs, some lymphomas (lymphosarcoma) quite often "complete" the terminal stage of leukemia. At the same time, they can "transform" into leukemia. The given data show that the division of tumors of the blood system into "diffuse" and "regional", which is necessary for determining the nosology, is quite conditional from the point of view of oncogenesis.

Each lymphoma has its own morphological features.

*Lymphosarcoma*- a malignant tumor that arises from cells of the lymphoid line. With this tumor, morphological changes occur in lymph nodes, mainly mediastinal and extra-abdominal, less often inguinal. Sometimes the tumor develops in the lymphatic tissue of the gastrointestinal tract, spleen and other organs. Initially, the tumor is limited to several lymph nodes; they increase sharply, are connected to each other in packages that squeeze the adjacent organs and tissues. The nodes are dense, gray-pink on autopsy, with areas of necrosis and hemorrhages. In the future, the generalization of the process occurs, that is, lymphogenic and hematogenous spread with the formation of multiple metastases both in the lymph nodes and in other organs - lungs, bones, skin. Tumor cells of the type B- or T-lymphocytes, prolymphocytes, lymphoblasts and immunoblasts grow in the lymph nodes.

Depending on this, the following histo(cyto)-logical variants of lymphoma are distinguished: lymphocytic, prolymphocytic, lymphoblastic, immunoblastic, lymphoplasmacytic, African lymphoma (Burkitt's tumor). Tumors consisting of mature lymphocytes and prolymphocytes are called lymphocytomas; from lymphoblasts and immunoblasts - lymphosarcomas.

African lymphoma or Burkitt's tumor deserve special attention among lymphosarcomas.

*Burkitt's tumor* is an endemic disease that occurs among the population of Equatorial Africa (Uganda, Nigeria, Guinea, Bissau); episodic cases are also possible in other countries. Children aged 4–8 years are more often sick; the tumor is localized in the upper or lower jaw, as well as in the ovaries; less often - in the kidneys, adrenal glands, lymph nodes. Quite often, the spread of the tumor to other organs is observed. The tumor consists of small lymphocyte-like cells, among which there are large macrophages with bright cytoplasm, which gives the impression of a peculiar appearance of the "starry sky". The occurrence of African lymphoma is associated with a herpes-like virus that was found in the lymph nodes of patients. Virus-like inclusions are found in tumor lymphoblasts.

*Fungal mycosis*- a relatively benign T-cell lymphoma of the skin, which belongs to the so-called lymphomatoses of the skin. Multiple tumor nodules consist of proliferating large cells with a significant number of mitoses. Plasma cells, histiocytes, eosinophils, and fibroblasts are also found in the tumor infiltrate. Tumor nodes are soft, protrude above the surface of the skin, resemble the shape of a mushroom, and are easily covered with ulcers. Such nodes are found not only in the skin, but also in the mucous membranes, muscles, and internal organs. Previously, tumor development was associated with fungal mycelium invasion, hence the erroneous name of the disease.

*Sézary's disease*- T-lymphocytic lymphoma of the skin with leukemia; refers to skin lymphomas. Damage to the bone marrow, the appearance of tumor cells in the blood, which is observed in Sézary's disease, served as the basis for its attribution in some cases to chronic lymphocytic leukemia.

Lymphocytic infiltration of the skin ends with the formation of tumor

nodes on the face, back, and legs. Atypical mononuclear cells with sickle-shaped nuclei - Sézary cells - are found in tumor infiltrates of the skin, bone marrow, and blood. Sometimes slight tumor infiltration of lymph nodes, spleen, kidneys, and liver is possible.

*Reticulosarcoma*- a malignant tumor consisting of reticular cells and histiocytes. The main histological distinction between reticulosarcoma and lymphosarcoma is the production by tumor cells of reticular fibers that wrap around reticulosarcoma cells.

*Lymphogranulomatosis*(Hodgkin's disease) is a chronic relapsing, rarely acute disease, in which the growth of the tumor occurs mainly in the lymph nodes.

Isolated and diffuse lymphogranulomatosis are distinguished by morphological features: In isolated (local) lymphogranulomatosis, pathological changes occur in one group of lymph nodes. More often it is cervical, mediastinal or extra-abdominal; less often - inguinal, which increase in size and grow together into packages. At first, they are soft, juicy, gray or gray-pink, on autopsy with an erased structure pattern. Later, the nodes become dense, dry, with centers of necrosis and sclerosis. The primary localization of the tumor is possible not only in the lymph nodes, but also in the spleen, liver, stomach, lungs, and skin. With widespread (generalized) lymphogranulomatosis, growth of tumor tissue is found not only in the centers of primary localization, but also far beyond them; at the same time, first of all, the spleen increases. At autopsy, the pulp is red with multiple white-yellow centers of necrosis and sclerosis; it acquires a mottled "porphyry" appearance ("porphyry spleen"). Some researchers explain the development of generalized lymphogranulomatosis by tumor metastasis from the primary tumor node.

During microscopic examination, proliferation of lymphocytes, histiocytes, and reticular cells, including giant cells, eosinophils, plasma cells, and neutrophilic leukocytes, are found both in the centers of primary localization of the tumor (lymph nodes) and in metastatic screenings. Proliferating polymorphic cellular elements form nodules that are subject to caseous necrosis and sclerosis. The most characteristic feature of

lymphogranulomatosis is the proliferation of atypical cells, which include: 1) small Hodgkin cells (analogous to lymphoblasts); 2) mononuclear giant cells or large Hodgkin cells; 3) multinucleated cells of Reed–Berezovsky–Sternberg, which quite often acquire gigantic sizes. The origin of the latter cells is possibly lymphocytic, although their macrophage nature cannot be ruled out.

Lymphogranulomatous cells undergo a certain evolution, which reflects the progression of the tumor, while the cellular composition of the cells changes. Using biotic research (lymph nodes) it is possible to compare histological and clinical features of lymphogranulomatosis. Such comparisons formed the basis of modern clinical and morphological classifications of lymphogranulomatosis.

Clinical and morphological classification. There are four variants (stages) of the disease: 1) variants with a predominance of lymphoid tissue (lymphohistiocytic); 2) nodular (nodular) sclerosis; 3) mixed-cell variant; 4) variant with suppression of lymphoid tissue.

The variant with a predominance of lymphoid tissue is a manifestation of the early phase of the disease and its localized forms, which corresponds to the I-II stages of the process. Microscopic examination reveals only the proliferation of mature lymphocytes and partially histiocytes, which erases the pattern of the lymph node. In cases of progression of the disease, the histiocytic variant turns into a mixed-cell variant.

Nodular (nodular) sclerosis is characteristic for a relatively benign course of the disease; and the process initially develops in the mediastinum. During microscopic examination, the growth of connective tissue is found, which surrounds cellular accumulations, among which Reed-Berezovsky-Sternberg cells are found, and on the periphery - lymphocytes and other cells.

The mixed-cell variant reflects the spread of the pathological process and corresponds to the I-III stages of the disease. Microscopically, characteristic signs are found: proliferation of lymphoid elements of various degrees of maturity, giant cells of Hodgkin and Reed–Berezovsky–Sternberg; accumulation of lymphocytes, eosinophils, plasma cells, neutrophilic leukocytes; centers of necrosis and fibrosis.

The variant with suppression (displacement) of lymphoid tissue occurs with an unfavorable course of the disease and reflects the generalization of lymphogranulomatosis. At the same time, in some cases, diffuse growths of connective tissue are observed, among the fibers of which there are single atypical cells; in others, lymphoid tissue is displaced by atypical cells, among which Hodgkin cells and Reed–Berezovskyi–Sternberg giant cells predominate; sclerosis does not develop.

The variant with displacement of lymphoid tissue by extremely atypical cells was called Hodgkin's sarcoma. Thus, the spread of lymphogranulomatosis is morphologically reflected by a sequential change of its three variants: with the predominance of lymphoid tissue, mixed-cellular and with suppression of lymphoid tissue. Such clinical and anatomical options can be considered as stages of lymphogranulomatosis.

**Materials on the activation of students of higher education during the lecture: questions, situational tasks, etc(*if necessary*):**

A 40-year-old man was found to have a tumor-like mass measuring 8x7 cm on his neck, which the surgeon removed incompletely due to its intimate connection with large vessels. Microscopically, it shows tissue and cellular atypism, lipoblast-type cells of various degrees of maturity, with polymorphism, nuclear hyperchromia, pathological mitoses, and foci of necrosis. Determine the histological form of the tumor:

AND Liposarcoma

Lipoma

CFibroma

DFibrosarcoma

Hibernoma

A 57-year-old woman underwent an operation to extirpate the uterus with appendages. Macroscopically: in the thickness of the myometrium, a nodule of dense consistency, rounded shape with clear contours, 5x6 cm in size, on a section of the fibrous structure. Histologically, it is represented by randomly arranged bundles of smooth muscle cells and excessively developed stroma. What is the most likely diagnosis?

AND Fibromyoma

Rhabdomyosarcoma

Rhabdomyoma

DFibroma

ELeiomyosarcoma

An ultrasound scan revealed a retroperitoneal tumor in a young woman in the form of

a nodule up to 25 cm in diameter. When examined microscopically, the tumor consists of spindle-shaped cells that form bundles going in different directions. With special research methods, myofibrils are detected in the cytoplasm. Cells differ in pronounced polymorphism, there are giant cells and many atypical figures of mitosis.

Your diagnosis:

AND Rhabdomyosarcoma

BLeiomyoma

C Leiomyosarcoma

Rhabdomyoma

Liposarcoma

A 38-year-old man was found to have a large tumor in the retroperitoneal space. Macroscopically, it had the form of a conglomerate of nodes with infiltration of surrounding tissues. The consistency is dense, the cut surface is white, juicy, reminiscent of "fish meat", variegated in places - with foci of oozing, hemorrhages and necrosis. Microscopically, tissue polymorphism is sharply expressed. It consists of lipoblasts of various degrees of maturity, there are giant cells with chimeric nuclei.

Your diagnosis:

AND Liposarcoma

BMalignant hibernoma

Lipoma

Hibernoma

EFibroma

Computed tomography revealed a tumor in the retroperitoneal space of a young woman, which was surgically removed. Macroscopically, it looked like a nodule with dimensions of 20x15x13 cm, lobular structure (due to the large number of connective tissue layers), soft-elastic consistency of yellow color, resembling adipose tissue in appearance. When examined microscopically, the tumor is built according to the type of adipose tissue, and the sizes of particles and fat cells vary widely. Your diagnosis:

AND Lipoma

BDesmoid

CMalignant hibernoma

Hibernoma

Liposarcoma

A 57-year-old patient developed periodic uterine bleeding. For diagnostic purposes, the uterus was scraped. In the obtained material, glandular complexes of various sizes and shapes formed by atypical cells with hyperchromic nuclei with numerous mitoses (including pathological ones) are observed among the blood elements. What is the most likely diagnosis?

AND Adenocarcinoma

BUterine fibromyoma

Chorionepithelioma

Glandular hyperplasia of the endometrium

Endometritis

During the microscopic examination of the operative material (part of the lip with an ulcer), near the edges and under the bottom of the ulcer defect in the connective

tissue of the mucous membrane, epithelial complexes of atypical multilayered epithelium with figures of pathological mitosis were found. In the center of the complexes is an accumulation of bright pink concentric formations. What pathology developed?

AND Squamous cell carcinoma with keratinization

BSquamous cell carcinoma without keratinization

Transitional cell cancer

Basal cell cancer

EPapilloma

Microscopic examination of a colon biopsy revealed a tumor of prismatic epithelium forming atypical glandular structures of various shapes and sizes. The basal membrane of the glands is destroyed. The tumor cells are polymorphic, the nuclei are hyperchromic, and a large number of pathological mitoses are noted. What is the most likely diagnosis?

AND Adenocarcinoma

B Basal cell cancer

Solid cancer

D. Mucosal cancer

Undifferentiated cancer

During the examination, a tumor in the form of a small dense nodule of gray color without clear borders was found on the hard palate of the patient. After removal, the tumor was examined histologically. It is made of small, cubic-shaped cells with a hyperchromic nucleus, which form alveoli, trabeculae, solid and cribose structures. Tumor growth is invasive. Name the tumor:

AND Adenocystic carcinoma

BMalignant pleomorphic adenoma

Mucoepidermoid cancer

Adenolymphoma

Monomorphic adenoma

In a 69-year-old patient, a small plaque-like formation appeared on the skin in the area of the lower eyelid, with subsequent ulceration, which was surgically removed. Upon microscopic examination of the formation: in the dermis of the skin there are complexes of atypical epithelial cells, on the periphery of the formations the cells are located perpendicular to the basement membrane. Cells are dark, prismatic polygonal; nuclei are hyperchromic with frequent mitoses. Sometimes there are formations similar to a hair follicle. What is the histological form of cancer in the patient?

AND Basal cellular

B Flat-celled with cornification

Flat-celled without cornification

Adenocarcinoma

Undifferentiated

In the region of the auditory nerve, a young woman was found to have a tumor in the form of a node up to 3 cm in diameter, soft-elastic, pinkish-white in color, homogeneous. Microscopically, the tumor is a bunch of cells with oval or curved



nuclei. Fibro-cellular bundles tend to form rhythmic structures in the form of palisade structures, which are formed by parallel rows of correctly oriented cells located in the form of a palisade, between which there is a cell-free homogeneous zone. Such structures were called "Verokai's bodies". Your diagnosis?:

AND Neurinoma (schwannoma, neurilemoma)

B Malignant neurilema

Ganglioneuroma

Neuroblastoma

Ganglioneuroblastoma

In a young man, a tumor in the form of several nodes (multicentric growth) of a soft-elastic consistency, white with large foci of hemorrhages, mucinization, necrosis, and the presence of cystic cavities was found in the chest cavity. Microscopically - sharply expressed polymorphism. Cells with oval and elongated nuclei are characteristic, which are arranged randomly or form bundles in the form of palisades. There are multinucleated symplasts, individual xanthoma cells. Your diagnosis?:

AND Malignant neuroma

B Neurinoma (schwannoma, neurilemoma)

Ganglioneuroma

Neuroblastoma

Ganglioneuroblastoma

A 46-year-old man had a dark spot on his scalp that did not cause discomfort.

Recently, the spot began to increase in size, pain appeared, the color became brown, black-brown. During histological examination of the removed tissue, spindle-shaped and polymorphic cells are revealed, in the cytoplasm of which there is a brown-black pigment. Your diagnosis:

AND Melanoma

B Hematoma

Hemangioma

Basalioma

E Carcinoid

In a 22-year-old man, a tumor was found in the adrenal glands, which has the appearance of a node, in places with infiltrative growth, soft consistency, yellowish color, with large areas of necrosis and hemorrhages. In addition, metastases were found in the liver (Pepper) and in the orbit of the eye (Hutchinson). Microscopically, the tumor consists of two types of cells. Some are small, like sympathogonia, round, with a narrow rim of cytoplasm and a small oval nucleus (bare nucleus), in which chromatin is arranged in the form of grains. Others, like sympathoblasts, are large, with a light nucleus and a large amount of cytoplasm. Tumor cells tend to form true and false rosettes in the form of a corolla of cells, in the center of which a delicate fibrillar substance is found. Your diagnosis?:

AND Neuroblastoma

B Malignant neuroma

Ganglioneuroma

D Neurinoma (schwannoma, neurilemoma)

Ganglioneuroblastoma

In a 7-year-old child, a tumor was found on the neck in the form of a soft-elastic nodule, clearly cleaved from the surrounding tissues with the presence of pronounced secondary changes in the form of ecchymosis, hemorrhages, and necrosis. There are small cysts in the tumor tissues. The microscopic picture is polymorphic. The tumor consists of immature neurocytes of various degrees of differentiation, ranging from sympathogonia and sympathoblasts to highly differentiated ganglion cells. Many active mitoses. Your diagnosis?:

AND Neuroblastoma

B Malignant neuroma

Ganglioneuroma

D Neurinoma (giovannoma, neurinoma)

Ganglioneuroblastoma

During the examination of a 16-year-old boy, enlarged submandibular and cervical lymph nodes were found. A biopsy was performed. Microscopically, the following were found in the lymph nodes: the typical structure was erased, the cell population was heterogeneous, there were large cells with a multilobed nucleus, multiple large unilocular cells, eosinophilic and neutrophilic leukocytes, lymphocytes, and areas of necrosis and foci of sclerosis were also found. What is the most likely diagnosis?

AND Lymphogranulomatosis

B Hyperplasia of the lymph node

Granulomatous lymphadenitis

Purulent lymphadenitis

Non-Hodgkin's lymphoma

During the autopsy of a 35-year-old woman, along with the enlargement of many lymph nodes, an enlarged spleen weighing 600.0 was found; on cross-section, it is heterogeneous, dark red in color, dense, with areas of grayish-yellow necrosis, up to 1 cm in diameter (porphyry spleen). What disease can you think of?

AND Lymphogranulomatosis

B Chronic lymphoid leukemia

Chronic myeloid leukemia

Cancer metastases

Lymphosarcoma

When examining a biopsy of enlarged cervical lymph nodes of a young woman, proliferation of lymphocytes, reticular cells, histiocytes, large and small Hodgkin's cells, Berezovsky-Sternberg's multinucleated cells, numerous eosinophils, single foci of caseous lymph node tissue necrosis were revealed. What is the most likely diagnosis?

AND Lymphogranulomatosis

B Tuberculosis

Acute leukemia

D Lymphosarcoma

Metastasis of lung cancer

When examining a biopsy of an enlarged cervical lymph node, the pattern was blurred, its tissue was represented by a large number of proliferating lymphocytes with an admixture of single Berezovsky-Sternberg cells. These changes indicate such

a disease:

AND Lymphogranulomatosis with predominance of lymphoid tissue

B Lymphogranulomatosis with depletion of lymphoid tissue

C Mixed cellular variant of lymphogranulomatosis

D Lymphosarcoma

E Nodular-sclerotic variant of lymphogranulomatosis

When examining a biopsy of an enlarged cervical lymph node, the pattern was blurred, its tissue was represented by a large number of proliferating lymphocytes with an admixture of single Berezovsky-Sternberg cells. These changes indicate such a disease:

AND Lymphogranulomatosis with predominance of lymphoid tissue

B Lymphogranulomatosis with depletion of lymphoid tissue

C Mixed cellular variant of lymphogranulomatosis

D Lymphosarcoma

E Nodular-sclerotic variant of lymphogranulomatosis

### **General material and bulk-methodological support of the lecture:**

Questions for self-control:

1. Definition of a tumor as a pathological process.
2. Theories of oncogenesis, factors contributing to the development of tumors.
3. Types of tumor growth.
4. Tumor structure, tumor progression, tumor heterogeneity. The concept of proatypism (atypia), types of atypism, morphological atypism (morphological characteristics of tissue and cellular atypism).
5. The effect of the tumor on the body of the host. Secondary changes of the tumor.
6. The concept of metastasis, the path of metastasis, the difference between metastases and a primary tumor.
7. Histogenetic (ontogenetic) classification of tumors.
8. Classification of epithelial tumors. Rules for naming epithelial tumors (nomenclature).
9. Benign epithelial tumors from the covering epithelium - papillomas (classification, morphological characteristics) and from the glandular epithelium - adenomas (classification, morphological characteristics).
10. Malignant epithelial tumors from the squamous covering epithelium cellular carcinomas (classification, morphological characteristics) and from glandular epithelium - adenocarcinomas (classification, morphological characteristics).
11. Classification of tumors formed from mesenchyme.
12. Connective tissue tumors, morphological characteristics.
13. Tumors from adipose tissue (white and brown tissue, morphological characteristics).
14. Tumors of bone tissue, morphological characteristics.
15. Tumors from cartilaginous tissue, morphological characteristics.

16. Tumors of muscle tissue, characteristics.
17. Tumors from tissue vessels, morphological characteristics.

## References:

### Main:

1. Atlas of micropreparations in pathomorphology / I.I. Starchenko, B.M. Filenko, N.V. Royko, etc.; VDZU "UMSA". - Poltava, 2018. - 190 p
2. Starchenko, S.O. Bilokon and others.. – Poltava: Tov. "ASMI" - 2018. - 190 p.
3. The basics of pathology according to Robbins: in 2 volumes. Volume 1 / Vinay Kumar, Abul K. Abbas, John C. Astaire; translation of the 10th Eng. edition. Publisher: All-Ukrainian specialized publishing house "Medytsyna". – X II. - 2019. - 420 p.
4. The basics of pathology according to Robbins: in 2 volumes. Volume 1 / Vinay Kumar, Abul K. Abbas, John C. Astaire; translation of the 10th Eng. edition. Publisher: All-Ukrainian specialized publishing house "Medytsyna". – X II. - 2019. - 420 p.
5. Pathomorphology. General pathomorphology: a study guide / edited by Ya. Ya. Bodnara, V.D. Voloshina, A.M. Romanyuk, V.V. Gargin. - New Book, 2020. - 248 p.
6. Pathomorphology of the main diseases of the cardiovascular system: study guide / I.I. Starchenko, B.M. Filenko, N.V. Royko – Poltava: "UMSA". - 2019. - 150 p.
7. I.I. Starchenko Pathomorphology of the main diseases of the maxillofacial region: academician. manual / I.I. Starchenko, B.M. Filenko, V.V. Chernyak ; "UMSA". – Vinnytsia: Nova Kniga, 2019. – 128 p.
8. Ctarchenko I.I. Special pathomorphology (basic course) for students of medical faculties of higher medical educational institutions of III-IV levels of accreditation / II Starchenko, N.V. Royko, B.M. Filenko. – Poltava, 2017. – 174 p.
9. Tuffaha S. A. Muin Immunohistochemistry in tumor diagnostics / S. A. Tuffaha Muin, S. G. Hychka, Gusky Hans. - "Book Plus", 2018. - 336 p.
10. Essentials of pathology: textbook / Ya. Bodnar, A. Romanyuk, V. Voloshyn, V. Gargin - Kharkiv, "Planeta-Print" Ltd, 2020, 219 p.
11. Pathology: textbook / IVSorokina, VD Markovskiy, DI Halata et al.; edited by IVSorokina, VD Markovskiy, DI Halata. - Kyiv: AUS Medicine Publishing, 2019. - 328p. + 2 color inserts (8p. + 12p.).
12. Pathology: textbook / IVSorokina, VD Markovskiy, DI Halata et al.;

edited by IVSorokina, VD Markovskiy, DI Halata. - 2nd edition. - Kyiv: AUS Medicine Publishing, 2020. - 328p. + 2 color inserts (8p. + 12p.).

**Additional:**

1. Benign neoplasms of bones of the maxillofacial area in children / P.I. Tkachenko, I.I. Starenko, S.O. Bilokin [and others] - P.: "UMSA", 2016. - 85 p
2. General pathomorphology / I.I. Starchenko, N.V. Royko, B.M. Filenko [et al.] – Poltava, 2016. – 136 p.
3. Zerbino D. D. Pathomorphology and histology: an atlas / D. D. Zerbino, M. M. Bagrii, Y. Ya. Bodnar, V. A. Dibrova. – Vinnytsia: Nova Kniga, 2016. – 800 p.
4. Methods of morphological research / M.M. Baghrii, V.A. Dibrova, O.G. Papadynets, M.I. Grischuk; edited by M.M. Baghria, V.A. Dibrov – Vinnytsia: Nova Kniga, 2016. – 328 p.
5. Novoseltseva T.V. Pathology of sexual and endocrine systems / T.V. Novoseltseva, B.M. Filenko, N.I. Hasiuk - Poltava: LLC "ASMI", 2015. - 199 p.
6. Pathomorphology: national. / V.D. Markovskiy, V.O. Tumanskiy, I.V. Sorokina [and others]; edited by V.D. Markovskiy, V.O. Tumanskiy. - K.: VSV "Medicine", 2015. - 936p.
7. Workshop on biopsy-sectioning course / I.I. Starchenko, A.P. Hasyuk, S.A. Proskurnya [etc.] – Poltava, 2016. – 160 p.

## **Lecture No. 7**

**Topic:** ANDatherosclerosis and arteriosclerosis. Coronary heart disease. Systemic connective tissue diseases with autoimmunization: rheumatism, systemic lupus erythematosus, rheumatoid arthritis, systemic scleroderma, dermatomyositis, Bekhterev's disease. Diseases of the endocardium and myocardium: cardiomyopathy, endocarditis, myocarditis, acquired heart defects.

**Actuality of theme:** This topic is about atherosclerosis and arteriosclerosis. Coronary heart disease. (ICH) Systemic diseases of connective tissue with autoimmunization: rheumatism, systemic lupus erythematosus, rheumatoid arthritis, systemic scleroderma, dermatomyositis, Bekhterev's disease. Diseases of the endocardium and myocardium: cardiomyopathy, endocarditis, myocarditis, acquired

heart defects.

**Goal:**

Get acquainted and study all rheumatic diseases, heart diseases, and others.

**Basic concepts:**

Rheumatism, rheumatoid arthritis, Bechterev-Marie-Strümpel disease, systemic lupus erythematosus (SLE), systemic scleroderma, dermatomyositis, pariaarteritis nodosa, Schergren's syndrome, mucoid edema, granulomatosis, endocarditis, myocarditis, rheumatic pericarditis, rheumatic polyarthritis, arthritis.

**Plan and organizational structure of the lecture:**

Greetings, verification of those present, announcement of the topic, purpose of the lesson, motivation of higher education seekers to study the topic.

**Content of lecture material (lecture text)**

**Atherosclerosis**- a chronic disease, the manifestations of which are focal thickening of the intima of arteries of elastic and muscle-elastic types, due to the deposition of lipids (lipoproteins) and reactive growth of connective tissue.

Atherosclerosis is one of the varieties of arteriosclerosis, which includes primary sclerosis with calcification of the middle layer of arteries (Mediacalcinosis of Menkeberg), arteriosclerosis with hyalinosis of small arteries and arterioles, as well as secondary sclerotic (inflammatory, toxic, allergic) vessel damage. Nowadays, atherosclerosis is the most common vascular disease.

The basis of the disease consists of various factors that cause a violation of fat-protein metabolism and damage to the intima of large arteries. Risk factors for atherosclerosis include age, hereditary predisposition, hyperlipidemia, arterial hypertension, diabetes, smoking, psycho-emotional overload, etc. Atherosclerosis occurs in almost all age groups, but a greater number of cases of clinical manifestation of the disease are noted in the elderly. This frequency increases with each new 10-year life. At the age of 40, men get sick much more often than women. After 45-50 years (the period of development of menopause in women), this indicator begins to level off, and after 70 years, the disease occurs with the same frequency in both women and

men. This is explained first of all by the lack of balance in the amount of androgens and estrogens with age of hormonal differences in women and men. There is a family predisposition to the disease due to genetically fixed hyperlipidemia, hypertension, diabetes, as well as the nature of nutrition, lifestyle, etc. Long-standing hyperlipidemia of primary or secondary origin causes severe atherosclerotic lesions. Arterial hypertension causes an increase in vascular permeability, thus damaging the vessel walls and prompting the action of other risk factors. The risk of atherosclerosis (especially in women) is significantly increased by smoking and diabetes. lifestyle, etc. Long-standing hyperlipidemia of primary or secondary origin causes severe atherosclerotic lesions. Arterial hypertension causes an increase in vascular permeability, thus damaging the vessel walls and prompting the action of other risk factors. The risk of atherosclerosis (especially in women) is significantly increased by smoking and diabetes. lifestyle, etc. Long-standing hyperlipidemia of primary or secondary origin causes severe atherosclerotic lesions. Arterial hypertension causes an increase in vascular permeability, thus damaging the vessel walls and prompting the action of other risk factors. The risk of atherosclerosis (especially in women) is significantly increased by smoking and diabetes.

Electron microscopy found that phagocytic macrophages accumulate in places prone to the development of atherosclerosis - this is one of the early morphological signs of the disease. Endothelial cells in areas of atheromatous plaque formation are prone to high expression of adhesive molecules, including ICAM-1 and E-selectin. Perhaps this is one of the early molecular mechanisms of plaque formation. Most progressive atheromatous plaques have infiltrates consisting of macrophages, lymphocytes, and smooth muscle cells surrounded by fibrous tissue. "Growth factors", in particular PDGF, stimulate the proliferation of intimal smooth muscle cells (myointimal cells) and their subsequent production of collagen, elastin and mucopolysaccharides. PDGF is secreted by most cells of connective tissue origin, macrophage and endothelial nature. It has been shown experimentally in tissue culture that PDGF accelerates the growth of smooth muscle cells and fibroblasts, induces DNA duplication and, thus, promotes the acceleration of cell division. Adhesive

molecules contribute to the aggregation of platelets, which is accompanied by damage to endothelial cells. Hemodynamic pressure, especially at the branching points of blood vessels, contributes to the adhesion of platelets and damage to the endothelium. Under certain circumstances, the space between the endothelial cells is widened, and then there are either small or rather large areas devoid of endothelial cells. Further release of growth factors, such as PDGF, contributes to further stimulation of proliferation and activation of secretion of intimal smooth muscle cells. The above relationships between macrophages, platelets,

Even Rudolf Virchow emphasized that lipids are an important component of atheromatous lesions. And now it has been proven that an increase in the level of certain types of lipoproteins significantly increases the risk of developing atherosclerosis in different people.

It has been shown that an increase in blood lipoproteins with a low specific weight, in particular, LDL-cholesterol, is the most important and common cause of the development of atheromatous plaque. Cholesterol levels are regulated by both genetic and environmental factors. The degree of mortality from atherosclerotic damage to the coronary vessels of the heart is closely related to the level of LDL-cholesterol. The increased risk of cardiovascular disease in England and other northern European countries is associated with a high fat content in the diet of the residents of these countries. In Mediterranean countries, where a lower proportion of saturated fat provides energy, mortality from coronary artery disease is low. At the same time, it has been established that dietary consumption of cholesterol has relatively little effect on its level in plasma. Many cells have receptors that recognize the apoprotein part of the LDL molecule. The molecular structure of the LDL receptor has been determined. The mechanism that controls its synthesis and transfer to the cell membrane surface is sufficiently studied. Most of the various molecular abnormalities are inherited as an autosomal dominant trait. It was found that the saturation of LDL-cholesterol is especially increased (more than 8 mmol/l) in heterozygous patients, especially in those who are 40-50 years old and have coronary artery disease. Homozygous patients, who are very rare



(approximately 1 per 1 million inhabitants), with a deficiency of receptors, usually die in childhood and adolescence from atherosclerotic lesions of the coronary vessels of the heart. The exact mechanism by which elevated LDL-cholesterol accelerates the development of atherosclerosis has not yet been determined. A high level of cholesterol circulating in the blood can increase the cholesterol content in the endothelial membranes. Its increase in membrane structures causes a decrease in their elasticity and leads to damage. Nowadays, it has been proven that when LDL-cholesterol is oxidized by macrophages attached to the vascular endothelium, free radicals can damage smooth muscle cells. In addition, chronic hypercholesterolemia promotes endothelial secretion of large amounts of growth factors such as PDGF.

Studies with the exchange of high molecular weight lipoprotein HDL-cholesterol are also interesting. HDL-cholesterol is involved in cholesterol transport, going from peripheral tissues to the liver. Several reliable epidemiological studies are cited in the literature, which show that a high content of HDL-cholesterol in liver cells is associated with a decrease in the risk of developing atherosclerotic changes in the coronary vessels of the heart. Research in this direction is considered promising.

Despite the fact that the content of triglycerides in the blood is one of the weak risk factors for the development of atherosclerosis, it must be taken into account, since hereditary abnormalities of lipid metabolism are associated with elevated levels of cholesterol and triglycerides.

Histological studies of atheromatous changes in humans and animals have shown that fibrin and platelets are important components of early damage. Today, there is strong evidence that the increased risk of coronary heart disease (CHD) is associated with an increase in the level of blood coagulation factor VII. Early changes in thrombotic formation include platelet activation with subsequent adhesion to subendothelial collagen. Agents that stimulate platelet activation are collagen, thrombin, thromboxane A<sub>2</sub>, adenosine phosphate, norepinephrine (ie, vasopressor agents). It is now known that these factors stimulate glycoprotein receptors on platelet membranes. The full name of these receptors is platelet glycoprotein IIB/IIIA. Small doses of aspirin, which are

prescribed to patients with clinical manifestations of atherosclerotic lesions of the coronary vessels and which have an undeniable healing effect, inhibit the action of thromboxane A<sub>2</sub>. Nowadays, the search for other methods of inhibiting glycoprotein IIB/IIIa receptors continues.

With atherosclerosis, mushy fat-protein detritus (athege) and focal growth of connective tissue (sclerosis) appear in the intima of the aorta and arteries, which leads to the formation of an atherosclerotic plaque that narrows the lumen of the vessel. Arteries of the elastic and muscular-elastic type are damaged, that is, arteries of large and medium caliber, small arteries of the muscular type are involved much less often in the process.

The following stages of atherosclerosis morphogenesis are distinguished: dolipid, lipoidosis, liposclerosis, atheromatosis, ulcer, atherocalcinosis.

The lipid stage is not defined macroscopically. Microscopically, it is observed: focal damage (up to complete destruction) of the endothelium and increased permeability of the intima membranes, causing the accumulation of plasma proteins, fibrinogen (fibrin) in the inner membrane, and the formation of flat wall thrombi; accumulation of acidic glycosaminoglycans in the intima, mucoid swelling of the inner membrane, the appearance of very low and low-density lipoproteins, cholesterol, and proteins in it; destruction of elastic and collagen fibers, proliferation of smooth muscle cells.

To identify this stage, it is necessary to use thiazine dyes. Due to the application of coloring of the drug with toluidine blue (thionin), it is possible to observe the appearance of a purple-red color (phenomenon of metachromasia) in areas of early disorganization of connective tissue.

*The stage of lipoidosis* characterized by focal infiltration of the intima with lipids (cholesterol), lipoproteins, which causes the formation of fat (lipid) spots and bands. Macroscopically, such fatty spots have the appearance of areas of yellow color, which can sometimes merge and form flat elongated strips on the surface of the intima, which do not protrude above the surface. In these areas, when dyes are applied to fats (Sudan III, IV, fat red O and others), lipids are detected. Lipids accumulate in smooth muscle cells and macrophages, which are called foamy or xanthomous cells (from the Greek *xanthos* – yellow).

Lipid inclusions also appear in the endothelium, which indicates infiltration by intimate blood plasma lipids. Swelling and destruction of elastic membranes is observed. First of all, fatty spots and streaks appear in the aorta and at the point of departure of its branches, then in the large arteries. The appearance of such spots does not mean the presence of atherosclerosis, since the appearance of lipid spots can be observed in early childhood not only in the aorta, but also in the coronary arteries of the heart. With age, lipid spots, the so-called manifestations of "physiological early lipidosis", in the vast majority of cases disappear and are not a source of the development of further atherosclerotic changes. Similar changes in blood vessels in young people can be detected in some infectious diseases.

In liposclerosis, the proliferation of fibroblasts occurs, the growth of which stimulates the destruction of macrophages (xanthoma cells) and the growth of young connective tissue in the intima. Further maturation of this tissue is accompanied by the formation of a fibrous plaque. Macroscopically, fibrous plaques are dense, round or oval formations of white or yellowish-white color that rise above the surface of the intima. The use of special dyes makes it possible to detect lipids in fibrous plaques. These plaques narrow the lumen of the vessel, which is accompanied by impaired blood flow (ischemia) to the organ or its part. Most often, fibrous plaques are located in the abdominal aorta, in the branches departing from the aorta, in the arteries of the heart, brain, kidneys, lower limbs, carotid arteries, etc.

At atheromatosis, lipid masses located in the central part of the plaque, adjacent collagen and elastic fibers disintegrate. Crystals of cholesterol and fatty acids, pieces of elastic and collagen fibers, droplets of neutral fats (atheromatous detritus) are found in the formed fine-grained amorphous mass. On the periphery of the plaque there are myocytes, macrophages, T-lymphocytes, single leukocytes, in the central part - a large number of xanthoma cells. Atheromatous masses are separated from the vessel lumen by a layer of mature, hyalinized connective tissue (plaque cover). In addition, a large number of vessels are formed on the periphery of the plaque, which encourage further growth due to the influx of lipoproteins and plasma proteins. The

progression of atheromatous changes leads to the destruction of the plaque cover. This period is characterized by a large number of various complications. There is an ulcer stage, which is accompanied by the formation of an atheromatous ulcer. The edges of such an ulcer are undercut, uneven, the bottom is formed by the muscle, and sometimes the adventitial layer of the vessel wall. The intimal defect is often covered by thrombotic layers. As a result of necrosis of the deep layers of the vessel wall, an aneurysm (bulging of the wall) can form. Often, the blood separates the intima from the middle layer, and then there are aneurysms that are delaminated. The danger of these complications is associated with the possibility of rupture of an aneurysm, or a vessel wall in places where atheromatous ulcers occur. Atheromatous masses can be washed away by the blood flow and form emboli. ulcer, and sometimes the adventitial layer of the vessel wall. The intimal defect is often covered by thrombotic layers. As a result of necrosis of the deep layers of the vessel wall, an aneurysm (bulging of the wall) can form. Often, the blood separates the intima from the middle layer, and then there are aneurysms that are delaminated. The danger of these complications is associated with the possibility of rupture of an aneurysm, or a vessel wall in places where atheromatous ulcers occur. Atheromatous masses can be washed away by the blood flow and form emboli. ulcer, and sometimes the adventitial layer of the vessel wall. The intimal defect is often covered by thrombotic layers. As a result of necrosis of the deep layers of the vessel wall, an aneurysm (bulging of the wall) can form. Often, the blood separates the intima from the middle layer, and then there are aneurysms that are delaminated. The danger of these complications is associated with the possibility of rupture of an aneurysm, or a vessel wall in places where atheromatous ulcers occur. Atheromatous masses can be washed away by the blood flow and form emboli. The danger of these complications is associated with the possibility of rupture of an aneurysm, or a vessel wall in places where atheromatous ulcers occur. Atheromatous masses can be washed away by the blood flow and form emboli. The danger of these complications is associated with the possibility of rupture of an aneurysm, or a vessel wall in places where atheromatous ulcers occur. Atheromatous masses

can be washed away by the blood flow and form emboli.

*Atherocalcinosis* is characterized by the deposition of calcium salts in the fibrous plaque, that is, their calcification (petrification). This is the final stage of atherosclerosis. At the same time, it must be remembered that the deposition of calcium salts can also be observed in its earlier stages. Plaques acquire a stony density, the vessel wall at the place of petrification is sharply deformed. Calcium salts accumulate in atheromatous masses, in fibrous tissue, in the intermediate substance between elastic fibers.

Macroscopic stages of the development of atherosclerosis: the stage of fatty spots or strips, the stage of fibrous plaques, the stage of complications due to the disintegration of plaques (atheromatous ulcers and thrombotic layering), the stage of calcinosis.

Complications of atherosclerosis: parenchymal dystrophy and atrophy, sclerosis of organs and tissues due to hypoxia; heart attacks and gangrene due to obliteration or thrombosis of an artery, or embolism by atheromatous masses or thromboemboli; atherosclerotic shrinkage of the kidney; formation of vascular aneurysms; bleeding; diffuse (small-cell) cardiosclerosis, because the load on the left ventricle increases due to a decrease in the elasticity of the vessels of the large blood circulation, it hypertrophies and there is a relative insufficiency of blood supply, and therefore hypoxic growth of connective tissue.

Clinical and morphological forms of atherosclerosis:

1. Atherosclerosis of the aorta. The lesion is most pronounced in the abdominal part of the aorta. Aneurysms are often formed - limited expansion (explosion) of the vessel wall (lat. aneuryo - expand) with its thinning and tiny thrombotic masses in the cavity. Cylindrical, saccular and herniated aneurysms are distinguished. They are further divided into true and pseudoaneurysms depending on the structure of the aneurysm wall. Aneurysm rupture, mural thrombosis, thromboembolism are possible.

2. Atherosclerosis of the coronary arteries of the heart is the basis of coronary heart disease.

3. Atherosclerosis of cerebral arteries is the cause of cerebrovascular

disease. Chronic insufficiency of cerebral blood circulation develops more often with atrophy of the cerebral cortex and the development of atherosclerotic dementia. Acute insufficiency of cerebral circulation can develop in the form of brain strokes: ischemic (gray softening of the brain), occasionally hemorrhagic (red softening of the brain). In other words, a cerebrovascular disease is formed.

4. Atherosclerosis of renal arteries. With chronic blood circulation disorders, wedge-shaped areas of parenchymal atrophy develop in the kidneys with stroma collapse and the subsequent development of connective tissue. Acute renal blood circulation disorders lead to the development of kidney infarctions. A large tuberous, slightly reduced kidney (atherosclerotic nephrosclerosis or primary shrunken kidney) is formed.

5. Atherosclerosis of mesenteric arteries. This form can lead to intestinal gangrene, ischemic colitis.

6. Atherosclerosis of the arteries of the lower extremities - affects a. femoralis is manifested by the syndrome of "intermittent lameness", in connection with tissue atrophy and sclerosis. Gangrene may develop.

**Coronary heart disease**(coronary heart disease) is a group of diseases caused by relative or absolute insufficiency of coronary blood circulation.

This is a cardiac form of atherosclerosis and hypertensive disease, which is ischemic myocardial dystrophy, heart attack or cardiosclerosis.

Acute ischemic heart disease (ACS) includes: angina pectoris, sudden coronary death, myocardial infarction.

Acute myocardial infarction lasts 8 weeks (2 months). This is the period of the scarring process of the necrosis zone.

A repeated heart attack occurs 8 weeks after the first acute myocardial infarction, and a recurrent heart attack occurs within 8 weeks after the first heart attack.

The size of the heart attack depends on: the level of coronary artery occlusion; the degree of its stenosis; possibilities of collateral blood circulation; the functional state of the myocardium (complications with arterial hypertension).

Localization of myocardial infarction:

1) the most common – in the basin of the enveloping left coronary artery (the back wall of the left ventricle and the back parts of the interventricular membrane);

2) less often – in the basin of the enveloping coronary artery (the back wall of the left ventricle and the back parts of the interventricular membrane);

3) occasionally – in the basin of the right coronary artery (wall of the right ventricle)

*Ischemic dystrophy of the myocardium*, or acute focal myocardial dystrophy, develops during relatively short-term episodes of coronary crisis, when characteristic changes in the electrocardiogram occur in the absence of myocardial necrosis (there is no increase in the activity of transaminases, lactate dehydrogenase, etc.). The myocardium is flaccid and pale, sometimes variegated and swollen in areas of ischemia. A fresh thrombus is often found in the coronary artery.

Macroscopically, when the surface of the myocardial section is treated with a solution of tetrazolium salts, potassium tellurite, areas of ischemia appear bright against the dark background of the intact myocardium, because in areas of ischemia the activity of redox enzymes is sharply weakened, and therefore formazan grains, as well as reduced tellurium, are not formed.

Microscopically, dilation of capillaries, stasis and sludge phenomenon of erythrocytes, swelling of interstitial tissue, perivascular hemorrhages, accumulation of leukocytes on the periphery of the ischemia zone are found. Muscle fibers lose transverse striation, are deprived of glycogen, they are intensively stained with eosin, fuchsin, pyronin and Schiff's reagent, which indicates necrobiotic changes. Stained with acridine orange, they emit not an orange, but a green glow under a fluorescent microscope, which makes it possible to distinguish the ischemia zone from the intact myocardium. A large number of contractures is detected by polarization-optics.

Early electron-microscopic and histochemical changes reflect a decrease in the number of glycogen granules, a decrease in the activity of redox enzymes (especially dehydrogenases and diaphorases), swelling and destruction of

mitochondria and the sarcoplasmic network. These changes are associated with impaired tissue respiration and increased anaerobic glycolysis. A complication of ischemic myocardial dystrophy is most often acute heart failure, which also becomes a direct cause of death.

*Acute myocardial infarction* on the first day, it is almost not visible visually - the infarct area has a looser consistency and is somewhat paler than healthy tissue, but it can be variegated due to uneven blood supply.

Demarcation inflammation develops around the area of necrosis, that is, a leukocyte shaft is formed, with inflammatory hyperemia of vessels and diapedesis hemorrhages. In the zone of necrosis, islands of living cardiomyocytes are preserved perivascularly, and in the zone of ischemia, i.e., beyond the demarcation line, there is an uneven blood supply to the tissue and the absence of glycogen in ischemic cardiomyocytes.

Macroscopically, a white infarct with a hemorrhagic crown is revealed. Possible myomalacia of the infarct zone (under the action of leukocyte enzymes) with rupture of the heart and tamponade of the pericardial cavity, aneurysm formation.

The organization occurs in the zone of demarcation and islands of unchanged myocardium, in the zone of necrosis and continues for 7-8 weeks. First, necrotic masses are resorbed by macrophages, then leukocytes are transformed into fibroblasts. The necrosis zone is filled with loose connective tissue, similar to granulation tissue, which matures into scar connective tissue (post-infarction cardiosclerosis). Compensatory hypertrophy of cardiomyocytes develops along the periphery of the scar.

Patients die from acute cardiovascular failure, cardiogenic shock, ventricular fibrillation, asystole.

Chronic CAD is characterized by a wave-like course with coronary crises, that is, episodic acute coronary insufficiency against the background of chronic relative insufficiency of coronary circulation. Its morphological substrate is coronary atherosclerosis and cardiosclerosis. Cardiosclerosis can be diffuse (small focal), developing as a result of chronic hypoxia of the myocardium, or post-infarction (large focal), on the basis of which a chronic aneurysm of the



heart wall is formed.

Aneurysm is a bursting of the thinned heart wall (in the area of a large post-infarction scar after a transmural myocardial infarction). Usually, the aneurysmal sac is filled with layered thrombotic masses.

Postinfarction cardiosclerosis is a large scar field (as a result of replacement of necrosis by connective tissue) with compensatory hypertrophy of cardiomyocytes on its periphery.

Diffuse cardiosclerosis is the morphological equivalent of angina pectoris, which is caused by a constant relative insufficiency of blood supply to the myocardium, that is, chronic hypoxia. Which activates collagen synthesis. Macroscopically, multiple, small cells up to 1–2 mm of whitish connective tissue are determined.

A complication of chronic coronary artery disease can be chronic insufficiency of blood circulation as a result of a decrease in the contractile function of the myocardium in diffuse cardiosclerosis or retention of the residual volume of blood in a heart aneurysm; thromboembolism - as a result of the formation of thromboembolic masses filling the aneurysmal sac; ruptures of a heart aneurysm with tamponade of the pericardial cavity.

**SYSTEMIC DISEASES OF CONNECTIVE TISSUE WITH  
AUTOIMMUNIZATION: RHEUMATISM, SYSTEMIC LUPUS ERYTHOMUS,  
RHEUMATOID ARTHRITIS, SYSTEMIC SCLERODERMIA, DERMATOMYOSITIS,  
BECHTEREV'S DISEASE. DISEASES OF THE ENDOCARD AND MYOCARDIA:  
CARDIOMYOPATHIES, ENDOCARDITIS, MYOCARDITIS, ACQUIRED HEART  
DEFECTS**

**Rheumatic diseases** are united by two features: pathogenesis and features of morphogenesis. The pathogenesis is based on immune damage (antibodies, immune complexes, cytotoxic T-cells that appear during the implementation of immune reactions directed against one's own antigens). Antibodies can be directed against a single organ or tissue, and local damage develops as a result. Antibodies can react with antigens of many tissues, causing damage in many organs.

The presence of a chronic focal infection is important for the

development of rheumatic diseases ( $\beta$ - group A hemolytic streptococcus, mycoplasmas, viruses of Kiryu, Epstein-Barr, Coxsackie, etc.).

Rheumatic diseases are systemic diseases associated primarily with an autoimmune mechanism of damage. Violations of immune homeostasis at the tissue level are realized by immediate-type hypersensitivity reactions (HNT) with the development of exudative-necrotic changes and delayed-type hypersensitivity reactions (HST) with the formation of cellular, diffuse or focal (granulomatous) infiltrates.

There is a family predisposition to some rheumatic diseases. There is a connection of autoimmune diseases with HLA, especially with molecules of the 11th class of GKHS.

At the heart of rheumatic diseases is the systemic disorganization of connective tissue (muroid swelling, fibrinoid swelling, fibrinoid necrosis, inflammatory cellular reactions or hyalinosis, sclerosis.). Muroid swelling is characterized by the accumulation of glycosaminoglycans (mainly hyaluronic acid) in the main substance of the connective tissue, which promotes vascular permeability and the release of albumins from the blood plasma. The so-called chromatropic edema occurs, which microscopically manifests as a phenomenon of metachromasia with such dyes as toluidine blue, methylene blue, etc. A purple-red color appears in areas of muroid swelling, and basophilia is noted when stained with hematoxylin. Fibrinoid swelling is characterized by a more pronounced destruction of the main substance and fibers of the connective tissue. At the same time, there is a sharp increase in vascular permeability and the release of coarsely dispersed plasma proteins, primarily fibrinogen, which turns into fibrin. The process is irreversible and ends with fibrinoid necrosis (necrotic masses are infiltrated with plasma proteins and fibrinogen), hyalinosis and sclerosis.

As a result of damage by circulating immune complexes, generalized vasculitis with the development of fibrinoid necrosis, plasmorrhagia, thrombosis, proliferation of endothelium and perithelium is observed. Morphologically, destructive-proliferative thrombovasculitis can be endo-, meso-, peri- and panvasculitis. Generalized vasculitis is characteristic of all

rheumatic diseases.

Rheumatic diseases have a chronic progressive wave-like course with alternating periods of exacerbation and remission. Features of the structural manifestations of these diseases are determined by the degree of damage to the connective tissue and blood vessels with the predominant damage to one or another organ.

Rheumatic diseases include:

**Rheumatism**– against the background of systemic connective tissue pathology, the heart, musculoskeletal system, and central nervous system suffer the most.

**Rheumatoid arthritis**– joints (joint capsule, synovial membrane, articular cartilage), stroma of visceral organs.

**Bekhterev-Marie-Strümpel disease**(ankylosing spondyloarthritis) is a predominant lesion of the articular-ligamentous apparatus of the spine, as well as the heart and lungs.

**Systemic lupus erythematosus**- vessels, skin, joints, as well as visceral organs (kidneys, liver, myocardium) are affected.

**Systemic scleroderma**-vessels (vasculitis) of the skin, muscles, joints, kidneys, heart are affected ("Scleroderma kidney", heart).

**Dermatomyositis**– skin (dermis) and muscles (striated and smooth).

**Nodular periarteritis**- adventitial membrane of arterioles and veins, manifested by dystrophy and sclerosis in internal organs, up to heart attacks, and hemorrhages.

**Sjogren's syndrome**- skin lesions, xerophthalmia, xerostomia.

*Rheumatism*(Sokolsky-Buillot's disease) - a general infectious-allergic disease associated with sensitization of the body  $\beta$ - hemolytic streptococcus A, characterized by systemic damage to the connective tissue with the predominant localization of the pathology in the cardiovascular system in susceptible individuals (7–15 years old), continuous recurrence with features of autoaggression.

Scheme of the typical development of rheumatism (with the selection of three periods according to Nesterov):

Streptococcal infection (most often sore throat) and the first period of sensitization of the body by streptococcal infection, i.e. the latent period, which is 2–4 weeks, when anti-streptococcal antibodies are produced and the immune complex is formed. II period – hyperergic reaction: as a result of damage by immune complexes, as well as the reaction of cross-reactivity of antibodies from AG-connective tissue, proteases cleave glycoprotein complexes of connective tissue, supporting long-term autoimmune inflammation with granulomatosis (according to the HST type. Clinically, the second period is manifested as a primary rheumatic attack. III period - the period of recurrence of the process. The morphological substrate of rheumatism is a systemic progressive disorganization of connective tissue and a specific proliferative cellular reaction, especially in the endocardium and vessels of the microcirculatory channel.

Mucoid swelling is a superficial reverse disorganization of the connective tissue with the release of acidic glycosaminoglycans (CGAG), which cause metachromasia and also increase vascular tissue permeability, causing tissue impregnation with plasma proteins. The result is a transition to fibrinoid swelling and necrosis.

Fibrinoid necrosis and necrosis is an irreversible disorganization of connective tissue with the formation of a complex fibrinoid complex, which ends in fibrinoid necrosis.

Cellular reactions (granulomatosis). The cycle of granuloma development lasts up to 6 months.

Phase I – accumulation of macrophages in the center of damage;

Phase II – "blooming" ("mature") granuloma - macrophages are fan-shaped around fibrinoid masses;

Phase III – a "withering" granuloma – the cell shrinks due to the lysis of fibrinoid masses by macrophages, fibroblasts appear;

IV phase - "scarring granuloma" - complete resorption of fibrinoid by macrophages, scarring of the organ

Nonspecific cellular reactions develop in the form of lymphohistiocytic infiltration of the interstitial tissue of internal organs or vasculitis in the

microcirculatory channel.

Clinical and anatomical forms of rheumatism: cardiovascular (rheumatic endo-, myo- and pancarditis); polyarthritic (rheumatic polyarthritis); cerebral (small chorea) - movement disorders due to damage to brain vessels; nodular (nodular rheumatism) – granulomas in the subcutaneous tissue, aponeurosis, tendons, fascia and muscles.

With endocarditis, dystrophic changes (mucoïd and fibrinoid swelling), necrosis and proliferative cellular reaction (granulomatosis) of the endocardium are observed. According to the localization, parietal, valvular and chordal endocarditis are distinguished. Chordal endocarditis, accompanied by thickening and shortening, deformation of chords, causes deformation of atrioventricular valves. There are 4 types of valvulitis: diffuse – initial, characterized by diffuse damage to the connective tissue of valve leaflets (with the development of granulomas and subsequent sclerosis); acute warty - dystrophic, and then - necrotic-proliferative reactions in the connective tissue of the valve, accompanied by damage to the endothelium (along the free edge of the leaflets) and thrombotic layers; fibroplastic - as a result of diffuse or acute warty endocarditis, is manifested by cicatricial thickening of the valve, fibrosis of the ring, that is, stenosis of the atrioventricular opening, as well as fusion of the valve leaflets; retro-warty – foci of repeated fresh disorganization of connective tissue and repeated ulcers of the endothelium against the background of cicatricial thickening of the valve, deformation and fusion of its leaflets with further thrombotic layering.

*Myocarditis* with rheumatism there are two types - granulomatous and exudative, and the last type of myocarditis can be both focal and diffuse.

In granulomatous (productive) myocarditis, rheumatic granulomas form in the perivascular connective tissue, causing perivascular cardiosclerosis. The usual localization is the left atrium, the right atrium, the back wall of the left ventricle, and the interventricular septum.

In focal interstitial exudative myocarditis, slight focal lymphocytic infiltration and single granulomas are observed. A latent course is characteristic.

Diffuse interstitial exudative myocarditis is characterized by lymphoid infiltration of the cardiac stroma with isolated granulomas that cause diffuse cardiosclerosis. The myocardium is flaccid, the cavities are enlarged.

*Rheumatic pericarditis* according to the nature of inflammation, they can be serous, fibrinous or serous-fibrinous. The result is intrapericardial adhesions, obliteration of the pericardial cavity, and in case of calcification of the exudate that has been organized, a "shelled" heart.

Rheumatic carditis (rheumocarditis) is characterized by simultaneous damage to two layers of the heart - endo- and myocardium, pancarditis - damage to all layers of the heart at the same time (endo-, myo-, and pericardium).

Rheumatic vasculitis has a systemic nature.

Arteritis and arteriolitis: specific changes (granulomatosis in the walls of vessels), which ends with sclerosis in the form of nodular thickenings, that is, arteriosclerosis with uneven stenosis.

Capillaritis with "rheumatic endotheliosis", that is, proliferation of the endothelium.

Venulitis is accompanied by thrombosis and warty growths on the venous valves.

*Rheumatic polyarthritis*, which affects large joints, in the acute period manifests itself as synovitis (granulomatous in nature), proliferation of synoviocytes and accumulation of aseptic serous-fibrinous exudate in the joint cavity. With the development of granulomatous inflammation periarticularly and along the tendons, large nodes are formed (nodose form of rheumatism).

Skin manifestations of the nodular form of rheumatism are in the form of erythema on the extensor surface of the lower legs and forearms (periarticularly, above nodes in the subcutaneous tissue).

*Nodular (nodular)* the form of rheumatism is characterized by granulomatous inflammation followed by sclerosis in the form of "knots" in aponeuroses (parietal and occipital), fascia, tendons, periosteum and periarticular tissues.

*Cerebral form of rheumatism* is a manifestation of rheumatic vasculitis,

which causes dystrophy and focal necrosis of neurons. Bleeding is also possible. Small chorea in children is a consequence of damage to the striatal system (dystrophy and atrophy in the cells of the striatal body, subthalamic nuclei, and cerebellar cortex).

The consequence of rheumatic endocarditis is thickening and deformation of valve leaflets and chordae, which causes insufficiency of the atrioventricular valve; stenosis of the fibrous ring and fusion of the valves - to stenosis of the atrioventricular opening, that is, heart defects are formed. Rheumatic myocarditis ends with cardiosclerosis and a decrease in the contractile function of the myocardium. Warty endocarditis can be complicated by thromboembolism with heart attacks of the kidneys, spleen, brain, retina, and gangrene of the limbs.

Rheumatic polyserositis can lead to obliteration of cavities. Death occurs from thromboembolism, or more often from decompensation of heart disease.

Mitral valve insufficiency usually develops in children. With rheumatism in adults, both mitral valve insufficiency and stenosis of the atrioventricular opening are formed as a result of sclerotic deformation of the fibrous ring of the heart and fusion of the deformed leaflets of the mitral valve. Along with the mitral valve, with rheumatism, the aortic valve can also be affected.

*Rheumatoid arthritis*- a chronic systemic connective tissue disease with progressive damage to the joints in the type of erosive-destructive polyarthritis.

Damage to connective tissue (mainly joints) is a consequence of immunopathological processes (autoaggression). Attention is drawn to the role of viral infection, especially the Epstein-Barr virus, which has the ability to disrupt the synthesis of immunoglobulins. The cause of immune complex damage in rheumatoid arthritis is considered to be a dysregulation of the immune response as a result of an imbalance in the function of T- and B-lymphocytes (deficiency of the T-lymphocyte system, which leads to the activation of B-lymphocytes and the uncontrolled synthesis of antibodies - IgG by plasma cells). IgG in rheumatoid arthritis is changed, has autoreactivity, as a result of which IgG and IgM antibodies (rheumatoid factors) are produced against it. When rheumatoid factors and IgG interact, immune complexes are

formed that initiate a series of chain reactions (activation of the coagulation system, the complement system,

The pathological process develops mainly in the joints and peri-articular tissues. The inflammatory process in the synovial membrane becomes chronic and is accompanied by the destruction of cartilage with the subsequent development of fibrous and bone ankylosis. The process is staged.

The early stage is characterized by an increase in vascular and tissue permeability, edema, hemoptysis, mucoid swelling, fibrin shedding, and the development of fibrinoid cells. In the vessels - productive vasculitis, thrombovasculitis with predominant damage to venules. There is hyperplasia of synovium villi. Synoviocytes in the process of proliferation sometimes occupy a palisade-like arrangement in relation to layers of fibrin.

The next stage is characterized by the growth of granulation tissue in the subsynovial layer, rich in blood vessels, lymphoid and plasma cells. There is a focal, more often perivascular, location of lymphocytes that form lymphoid follicles with bright centers and a plasma cell reaction on the periphery. The granulation tissue growing from the edges of the synovial membrane crawls onto the cartilage in the form of a pannus. Cartilage is destroyed with the formation of wrinkles, cracks and sequestrations, which sink into the subchondral bone. Dryness, graininess of the cartilage surface, yellowness, sometimes complete destruction of the joint surfaces are noted.

In the final stage, the maturation of the granulation tissue leads to the fact that the damaged joint surfaces are covered with fibrous tissue, converge, the joint gap narrows, and fibrosis is formed. The simultaneous growth of bone beams with their transition from one end of the joint to the other leads to the formation of fibro-osseous ankylosis.

Rheumatoid nodules characteristic of rheumatoid arthritis are limited or merge in the form of foci of fibrinoid necrosis, surrounded by large histiocytes with pyroninophilic cytoplasm; sometimes there is an admixture of giant multinucleated cells. Next, lymphoid and plasma cells, fibroblasts, and neutrophils are located at the periphery of the nodule. A fibrous capsule with newly formed vessels forms around the nodule. The formation of the nodule



ends with sclerosis, often with the deposition of calcium salts.

Vasculitis in rheumatoid arthritis, as in other rheumatic diseases, has a generalized character. Vessels of all calibers are affected, but small vessels of the skin, skeletal muscles, and internal organs are more frequent. Productive vasculitis and thrombovasculitis are very common.

Damage to the heart (rheumatoid carditis) with the development of fibrinoid cells in the connective tissue, nonspecific exudative-proliferative reactions, characteristic rheumatoid nodules, damage to muscle fibers of a dystrophic nature, vascular changes and sclerosis as a possible result of all processes. According to the frequency of damage, the pericardium is in the first place, followed by the myocardium and the endocardium.

Damage to the lungs and pleura is most often manifested by dry pleurisy with minor fibrinous exudate. The organization of fibrin causes the formation of adhesions. In the lung tissue, the process develops according to the type of chronic interstitial pneumonia, focal or diffuse pneumosclerosis, accompanied by the formation of rheumatoid nodules.

Kidneys with rheumatoid arthritis are affected in 60% of cases. Damages are various: amyloidosis, glomerulonephritis (membranous or membranous-proliferative), nephrosclerosis, chronic interstitial nephritis, acute and subacute pyelitis, angiitis. The most frequent manifestation is amyloidosis, the development of which is caused by the appearance of a clone of amyloidoblasts under the action of long-term antigenic stimulation in conditions of suppression of cellular immunity.

Amyloidosis can also affect the liver, gastrointestinal tract, and other internal organs.

Complications are associated with the formation of subluxations and dislocations of small joints, limitation of mobility, fibrous and bone ankylosis, osteoporosis, kidney amyloidosis.

Death often occurs from kidney failure in connection with amyloidosis or from concomitant diseases - pneumonia, tuberculosis, etc.

*Systemic lupus erythematosus*(SLE) is a chronic polysyndromic disease of mainly young women and girls, which develops against the background of

genetically determined imperfection of immunoregulatory processes, which leads to the uncontrolled production of antibodies to one's own tissues and their components with the development of autoimmune and immune complex chronic inflammation.

Among the environmental factors provoking the detection of SLE, excessive insolation, as well as hypothermia, stressful situations, physical overload, etc., are generally recognized. It is also a hereditary predisposition - it occurs more often in the presence of certain types of HLA - DR2, DR3, B9, B18. Hormonal factor: more often in young women (high level of estrogen). Certain medications may play a role. There are indirect data on the role of chronic viral infection (increased titers to a number of RNA and DNA viruses).

A decisive role in pathogenesis is played by immune disorders in the form of a lack of T-suppressors, the predominance of T-helper T-lymphocytes and increased activity of B-lymphocytes. SLE is characterized by the development of an immune response to components of the nuclei and cytoplasm of cells - antinuclear antibodies, especially to native (double-helical) DNA, which are found in 50-60% of patients.

In SLE, there is a systemic disorganization of the connective tissue with a predominance of fibrinoid changes and generalized damage to the vessels of the microcirculatory bed. A feature of SLE is the pronounced pathology of cell nuclei, especially mesenchymal cells, which is manifested by their deformation, depletion of chromatin content, karyopyknosis, karyolysis, karyorrhexis. Impurities of chromatin material to fibrinoid give it a basophilic shade when stained with hematoxylin and eosin. Accumulation of chromatin material in tissues and vessel lumen, formation of hematoxylin bodies and "lupus" (LE) cells is considered pathognomonic for SLE. Hematoxylin bodies are approximately the size of a nucleus, round-oval in shape, structureless, their density is less than that of a normal nucleus, when stained with hematoxylin and eosin, they have a color from purple-red to pink-blue, give a positive reaction when stained by Felgen. Lupus cells are formed as a result of phagocytization by leukocytes and macrophages of cells with damaged nuclei.

The most typical for SLE are erythematous rashes on the face in the area

of the zygomatic arches and the back of the nose ("butterfly"). These rashes are of great diagnostic value. Histologically, some atrophy of the epidermis, the phenomenon of hyperkeratosis with the formation of keratotic plugs is revealed. Hyperkeratosis in the area of hair follicles leads to atrophy and hair loss. In the dermis, disorganization of connective tissue with fibrinoid changes, single hematoxylin bodies, productive and productive-destructive changes, pronounced pathology of nuclei in cells of infiltrates, endothelium of vessels. The deposition of IgG and IgM in the place of the dermo-epidermal junction has not only diagnostic, but also prognostic value, because it correlates with the clinical and laboratory activity of the process and the presence of kidney damage.

Damage to serous membranes is observed in 90% of patients. The pleura, pericardium, and less often the peritoneum are especially often damaged.

Damage to the joints - arthritis (synovitis) - is observed in 80-90% of patients, usually in the form of migrating arthralgias or arthritis, less often - a persistent pain syndrome with painful contractures. Small joints of the hands, lumbar, and ankles are mainly affected. Biopsy of the synovial membrane reveals acute or subacute synovitis with a poor cellular reaction, pronounced nuclear pathology and hematoxylin bodies. In the articular cartilage and bone tissue of the epiphyses, there are changes in the tinctorial properties of the main substance, dystrophic changes in chondrocytes and osteocytes, up to necrosis, but without the lush and active granulation tissue that destroys the cartilage. A number of patients may develop deformation of small joints, accompanied by muscle atrophy. Joint syndrome is usually accompanied by myalgia, myositis.

Damage to the cardiovascular system is very characteristic of SLE (about 50% of patients). With lupus carditis, all heart membranes are damaged (rarely at the same time); inflammation of individual membranes or their sequential involvement in the process is usually recorded. Pericarditis is the most common symptom of SLE. Massive exudate is rarely observed. Atypical warty endocarditis of Liebman-Sachs, which was previously considered only a pathological finding, now, thanks to the echocardiography method, has become diagnosed much more often, is the most characteristic sign of SLE and belongs

to the category of signs of high disease activity. It is characterized by the layering of thrombotic masses not only along the edge of the valve leaflets, but also on its surface, as well as in the places of the transition of the valve endocardium into the parietal one. Endocarditis in SLE is characterized by dystrophy and death of the endothelium and the formation of a pink structureless mass on the surface with an admixture of nuclear detritus, or the presence of thrombotic masses containing a large amount of fibrin. One or another degree of sclerosis of the parietal and valvular endocardium is observed, sometimes with the formation of mitral valve insufficiency, which is diagnosed in the clinic. Myocarditis in SLE is usually focal in nature, the infiltrates contain histiocytes, mononuclear cells, plasma cells, and sometimes leukocytes.

Lung damage. The lungs are compacted, the surface of the incision has a mirror-like shine, in the place of the root, heaviness and reticulation of the lung tissue is observed. Microscopically, diffuse thickening of alveolar septa due to fibrinoid swelling, their infiltration by lymphocytes, and proliferation of septal cells is noted. Hyaline membranes (fibrinoid material) are located on the inner surface of the alveoli. Destructive-productive vasculitis in the microcirculatory system. The combination of changes leads to the development of alveolar-capillary block and respiratory failure. A secondary infection often joins, up to the formation of abscesses.

Damage to the central nervous system and the peripheral nervous system in the form of alterative-exudative meningoencephalomyelitis and alterative-productive radiculitis, neuritis, plexitis are caused mainly by vasculitis. Scattered foci of micronecrosis localized in subcortical nuclei are characteristic of SLE. It is clinically manifested by astheno-vegetative syndrome, polyneuritis, lability of the emotional sphere, sometimes delirious states, auditory or visual hallucinations, epileptiform attacks, etc.

Kidney damage (lupus nephritis, lupus nephritis) - classic immune complex extra- and intracapillary glomerulonephritis, observed in 50% of cases. Clinically, there are various variants of kidney damage - isolated urinary syndrome, nephritic and nephrotic; in patients treated with corticosteroids and

cytostatics - pyelonephritic. Typical lupus nephritis is characterized by the phenomenon of "wire loops", fibrinoid deposition in glomerular loops, hyaline thrombi, and the formation of hematoxylin bodies. Non-specific signs are thickening and splitting of the basal membranes of glomerular capillaries, proliferation of glomerular cells, sclerosis of capillary loops, formation of adhesions (synechiae) between capillaries and glomerular capsule. The relapsing nature of SLE gives the kidneys a variegated appearance with the presence of acute and chronic changes. In the tubules, especially convoluted, different degrees of dystrophy are distinguished, in the lumen - cylinders with a basophilic shade. In the stroma, there are lymphoid cell and plasma cell infiltrates. Renal biopsy is of the greatest importance in recognizing the lupus nature of glomerulonephritis.

Damage to the spleen and lymph nodes - there is generalized lymphadenopathy, enlargement of the spleen and liver, pathognomonic changes in the spleen (atrophy of lymphoid follicles, pronounced plasmation, development of concentric perivascular sclerosis ("onion peel" phenomenon) and deposition of a sometimes homogeneous protein precipitate that does not give a positive reaction on amyloid).

The liver can be involved in the pathological process, which is expressed by the infiltration of the stroma by lymphoid, plasma cells, and macrophages. Fatty dystrophy of the liver, as well as coagulation necrosis of hepatocytes, is often found.

The most dangerous complications are related to the damage to the kidneys - the development of their insufficiency against the background of lupus-nephritis. Complications of steroid and cytostatic therapy are purulent infections, "steroid" tuberculosis, hormonal disorders.

Death occurs most often from kidney failure (uremia) or infection (sepsis, tuberculosis).

*Systemic scleroderma* is a systemic disease of connective tissue and small vessels, characterized by widespread fibro-sclerotic changes in the skin, stroma of internal organs and symptoms of obliterating endarteritis in the form of widespread Raynaud's syndrome.

The etiology of systemic scleroderma is unknown. In the development of systemic scleroderma, work related to long-term cooling, vibration, and polymerization of vinyl chloride is important. Known immunogenetic markers, such as A9, B8 and B27, B40, DR5 (subacute course) and DR3 (chronic course). The central link of the fibrotic process is the fibroblast and other collagen-forming cells (smooth muscle cells of the vascular wall) with increased production of type I and III collagen, fibronectin, biopolymers of connective tissue (proteoglycans and glycoproteins). An important factor in the pathogenesis of systemic scleroderma is a violation of microcirculation caused by damage to the vascular wall and a change in the intravascular, plasma, and cellular properties of blood. As a result, there is an excessive synthesis of soluble forms of collagen, damage to the endothelium and its replacement by smooth muscle collagen-synthesizing cells, increased ability to spasm and hyperplasia of the inner lining of vessels. Damage to the endothelium causes adhesion and aggregation of cellular elements of blood - leukocytes, erythrocytes and platelets, stasis, intravascular coagulation, microthrombosis. All this is realized by generalized Raynaud's syndrome (three-phase vasospastic reaction after cooling, excitement, overwork - pallor, cyanosis, hyperemia). The basis of pathogenesis is uncontrolled collagen formation and vascular processes in combination with inflammation. microthrombosis All this is realized by generalized Raynaud's syndrome (three-phase vasospastic reaction after cooling, excitement, overwork - pallor, cyanosis, hyperemia). The basis of pathogenesis is uncontrolled collagen formation and vascular processes in combination with inflammation. microthrombosis All this is realized by generalized Raynaud's syndrome (three-phase vasospastic reaction after cooling, excitement, overwork - pallor, cyanosis, hyperemia). The basis of pathogenesis is uncontrolled collagen formation and vascular processes in combination with inflammation.

Skin damage usually occurs in stages: the stage of dense swelling; stage of induration (sclerosis); stage of atrophy.

Joint syndrome is one of the most frequent and early signs of systemic scleroderma. A decrease in the amount of synovial fluid is observed. The

synovial membrane is dense with a pale shiny surface. In the early stages, multiple thrombosis of the surface capillary network is noted, a diagnostically informative sign is a band of fibrinoid on the surface of the synovium and swelling of the inner lining of vessels with concentric narrowing of the lumen.

Damage to the heart is the main sign of vascular pathology of systemic scleroderma, observed in 2/3 of patients. Macroscopically, one or another degree of hypertrophy of the heart, expansion of cavities (sometimes with the formation of aneurysms), thickening and whitishness of the parietal endocardium, marginal sclerosis of the valves, mainly the mitral, in the myocardium - cardiosclerosis of various types is noted: small-core, in the form of large whitish cords, subendocardial scars; on the epicardium there are whitish foci of compaction. Microscopically, mucoid and fibrinoid swelling is mainly in the endocardium, weak cellular reaction. Clinical symptoms are determined by atrophy, dystrophy, small centers of necrosis of cardiomyocytes and sclerotic processes (perivascular, diffuse interstitial, focal cardiosclerosis).

Damage to the lungs is the main manifestation - pneumosclerosis, which usually develops in the basal parts of the lungs and is accompanied by the development of bronchiectasis and areas of emphysema. The lungs are dense to the touch, heavy, with a clearly visible heavy pattern. Two types of sclerosis: cystic (with the formation of subpleural cavities) and compact (large fields of sclerosis and hyalinosis).

Kidney damage. With a mild clinical picture of nephropathy, swelling, homogenization, exposure of interlobular vessels, sometimes in combination with pervascular sclerosis, thickening of the interstitium, and focal lymphoid infiltration are morphologically determined. In a severe variant of nephropathy, the substrate of which is a scleroderma kidney, morphologically, atrophic and necrotic changes are noted in the cortical substance, up to the formation of massive areas of necrosis, in the interlobular arteries - mucoid swelling, wall dehiscence, proliferation and exfoliation of endothelial cells into the vessel lumen, intravascular coagulation. Contributing arterioles, as a rule, are in a state of fibrinoid necrosis. In the glomeruli, homogenization and swelling of individual loops, fibrinoid changes, partial sclerosis and hyalinosis. In both

variants, dystrophic and atrophic changes in tubules are observed,

Similar morphological changes are found in the gastrointestinal tract and liver.

Neurological symptoms are associated with the development of scleroderma angiopathy, fibrosis and dystrophic changes.

Complications are associated with the insufficiency of those organs or systems in which sclerotic changes are most developed.

*Dermatomyositis*- a systemic disease characterized by damage to striated and smooth muscles and skin. It is possible to damage only the muscles, and then the disease is designated as myositis. The viral nature of dermatomyositis is allowed. In some patients, structures similar to paramyxoviruses are found in the cytoplasm of myocytes, which are considered to be the triggering factor. There is a connection between dermatomyositis and tumors, and tumor agents can be cross-reactive with muscle antigens, which increases autoaggression. A marked improvement in the condition of patients after tumor removal.

Skeletal muscles, pharynx, eye and diaphragm muscles are most often affected. Skeletal muscles are atrophic: muscles are defined as thin strands with whitish layers, sometimes with foci of calcinosis. With exacerbation of the disease, the muscles are swollen, yellow, with centers of necrosis and hemorrhages. Microscopically, dystrophic changes prevail in the muscles, striations disappear, glycogen content decreases, and the activity of enzymes decreases sharply. Part of muscle fibers with signs of coagulation necrosis with active phagocytosis of necrotized areas. Edema, focal (in some places diffuse) infiltration by lymphocytes, macrophages and single leukocytes is observed in the connective tissue. Over time, with steadily progressing dermatomyositis, massive areas of sclerosis and lipomatosis are defined in the muscles.

The myocardium shows signs of focal or diffuse interstitial myocarditis with productive vasculitis, swelling of the interstitial tissue, and infiltrates consisting of lymphocytes, macrophages, and plasma cells. Dystrophy is detected in cardiomyocytes. In the chronic course of dermatomyositis, diffuse cardiosclerosis and atrophy of cardiomyocytes are noted.

In the lungs, diffuse changes are determined in the form of thickening of



the interalveolar partitions due to the proliferation of septal cells, lymphocytes, and macrophages. Purulent bronchopneumonia can develop, which is often the cause of death.

In the wall of the esophagus, stomach, small and large intestine, dystrophic and atrophic changes of muscle cells, perivascular lymphoid-macrophagic infiltrates, sclerosis of the mucous and submucosal layers are determined.

There are primary (idiopathic) and secondary (tumor) forms of dermatomyositis. The morphological manifestations of these forms are identical. The primary form is more common in children, and the secondary in adults. After removal of the tumor, an improvement in the condition of the patients was noted.

With dermatomyositis, complications are associated with bronchopneumonia, which develops against the background of weakness of the respiratory muscles. Possible cachexia, cardiovascular failure associated with myocarditis or cardiosclerosis. Complications of hormone therapy (bleeding from eroded vessels of gastrointestinal tract ulcers) often occur.

*Nodular periarteritis*- systemic necrotizing vasculitis based on the type of segmental damage of small and medium-sized arteries with the formation of aneurysmal protrusions. Mostly young men are affected, the incidence is 2-3 cases per 1 million population per year.

Nodular periarteritis develops after acute respiratory (including streptococcal) infections, administration of vaccines and sera, drug portability, etc. They give importance to the hepatitis B virus, since 30% of patients have a high titer of HBs-antigen and antibodies to it.

In the pathogenesis of nodular periarteritis, the main role is played by processes of immune complex inflammation, pronounced hemorheological disorders with the development of DIC syndrome.

Periarteritis nodosa usually begins acutely, less often gradually with general symptoms - fever, tachycardia, muscle pain and rapid weight loss, lack of appetite, sweating.

The most characteristic morphological feature of nodular periarteritis is

damage to small and medium-sized muscular arteries in the area of their branching. A feature of nodular periarteritis is simultaneous damage to the endothelium of vessels (deposition of immune complexes), internal elastic membrane (polymorphic cellular inflammation - lymphoid cells, macrophages, epithelioid cells, neutrophils, fibroblasts) and perivascular tissue (cellular infiltration and scarring). These changes eventually lead to vessel obliteration and the development of heart attacks. A characteristic morphological feature of nodular periarteritis is nodular thickening of the affected arteries, which are most often located in the vessels of the kidneys, heart, central nervous system, and organs of the abdominal cavity.

Damage to the vessels of various internal organs determines the clinic. The most common symptom of nodular periarteritis is kidney damage (80-90% of patients). In the kidneys, glomerulonephritis (acute and chronic mesangial), as well as kidney infarctions and aneurysm ruptures are often observed. Kidney damage is the most common cause of death in patients with periarteritis nodosa.

Damage to the nervous system in 50% of patients is manifested by multiple asymmetric sensory and motor neuritis. This is due to the presence of pathological processes in the vessels that feed this or that nerve. Involvement in the CNS process is observed in 25% of patients with periarteritis nodosa. It is clinically manifested by symptoms of meningoencephalitis, as well as focal lesions of the brain in connection with thrombosis of intracranial vessels, aneurysm ruptures. Damage to the eyes (aneurysms of the arteries of the fundus, perivascular infiltrates, thrombosis of the central retinal artery) can be one of the early symptoms of the disease.

Abdominal syndrome is observed in approximately 50% of patients with periarteritis nodosa.

Characteristic sharp abdominal pains associated with the pathology of the mesenteric arteries, which leads to the development of intestinal ischemia or necrosis.

Heart damage is observed in 30-40% of patients. Coronary vessels are most often affected, which is accompanied by angina attacks and myocardial infarction. Occasionally, hemopericardium develops as a result of rupture of an

aneurysm or exudative pericarditis due to damage to small vessels.

*Sjogren's disease*- this disease is characterized by pronounced xerostomia (dry mouth), xerophthalmia (dry eyes) and xeroconjunctivitis. The disease develops more often in middle-aged and elderly women. The main risk factor for the occurrence of Sjögren's disease is considered to be a family predisposition, as well as a connection with certain loci of the histocompatibility antigens of the HLA system. The number of immunoglobulins of all classes increases in the blood. In some patients, antinuclear antibodies and a number of organ-specific autoantibodies to thyroglobulin and lining cells of the stomach are detected. However, the main symptom is the presence of circulating autoantibodies to cells of the epithelium of the ducts of the salivary glands. Bilateral damage to the parotid salivary glands is usually observed, but other large and small salivary glands, lacrimal and bronchial glands can be involved in the process.

Salivary glands are enlarged, dense, bumpy, can be fused with surrounding tissues. Microscopically, a small expansion of the excretory ducts and a weak infiltration mainly by lymphocytes and plasma cells can be noted at first. Over time, pronounced infiltrates appear around the ducts, which consist mainly of lymphocytes penetrating between the acini. Between the particles, the amount of coarse-fiber connective tissue increases. The finale of morphological changes is a sharp increase in the number of lymphocytes (sometimes forming follicles), plasma cells, fibrous connective tissue and a decrease in the number of acini. Hypersecretion is noted in the remaining glandular cells. Simultaneously with the growth of cellular infiltration, focal proliferation of the epithelium and myoepithelium with the formation of epimyoeptithelial islands is observed.

Affection of the salivary glands can also be observed in rheumatoid arthritis, systemic scleroderma and systemic lupus erythematosus. However, an isolated autoimmune process with damage only around the ear salivary glands is also common.

The development of complications is influenced by the development of diseases of the oral cavity (caries, periodontitis, etc.) and malignant lymphomas

in the salivary glands.

**Materials on the activation of students of higher education during the lecture: questions, situational tasks, etc(*if necessary*):**

**General material and bulk-methodological support of the lecture:**

**Questions for self-control:**

1. Definition of atherosclerosis as a disease. General characteristics of atherosclerosis (which vessels are affected, why, epidemiology)
2. Risk factors for atherosclerosis.
3. Microscopic stages of the development of atherosclerosis, morphological characteristics.
4. Stages of atherosclerosis development, macroscopic, morphological characteristics.
5. Clinical and morphological forms of atherosclerosis.
6. Cerebral form of atherosclerosis, morphological characteristics, complications, causes of death.
7. Atherosclerosis of coronary arteries, morphological characteristics, complications, causes of death.
8. Atherosclerosis of the aorta, morphological characteristics, complications, causes of death.
9. Atherosclerosis of mesenteric arteries, morphological characteristics, complications, causes of death.
10. Atherosclerosis of combing arteries, morphological characteristics, complications, causes of death.
11. Atherosclerosis of the arteries of the lower extremities, morphological characteristics, complications, causes of death.
12. Definition of coronary heart disease, causes of development., Classification.
13. Angina
14. Sudden coronary death
15. Myocardial infarction, stages and their morphological characteristics.
16. Consequences and complications of myocardial infarction.
17. Cardiosclerosis.
18. Normal blood pressure indicators of a healthy person. Determination of arterial hypertension (AH). Concept of symptomatic hypertension.
19. Causes of hypertension, risk factors.
20. Classification of hypertension.

21. Clinical and morphological forms of hypertension, morphological characteristics, consequences and complications, causes of death.
22. Stages of the development of hypertension, morphological characteristics of the changes occurring at each of the stages.
23. Concept of cerebrovascular diseases. General characteristics.
24. Ischemic brain damage. Morphological characteristics, complications and consequences.
25. Hemorrhagic lesions of the brain. Morphological characteristics, complications and consequences.
26. Brain damage is associated with redistribution of blood. The concept of encephalopathy. Selective necrosis of neurons, postresuscitation encephalopathy.
27. Concept and morphology of cardiomyopathy.
28. Definition of an autoimmune disease. List of diseases related to those.
29. General characteristics of connective tissue diseases with autoimmunization (rheumatic diseases).
30. Rheumatism. Etiology, pathogenesis, clinical and morphological forms.
31. Rheumatism. Cardiovascular form: types of heart damage (endocarditis, myocarditis, pericarditis, pancarditis, carditis), morphological characteristics, complications and consequences.
32. Rheumatism. Cerebral form, morphological characteristics.
33. Rheumatism. Nodal form, morphological characteristics.
34. Rheumatism. Polyarthritic form. Morphological characteristics.
35. Rheumatoid arthritis. Etiology, pathogenesis, morphological characteristics, consequences and complications, causes of death.
36. Systemic lupus erythematosus. Etiology, pathogenesis, morphological characteristics, consequences and complications, causes of death. Lupus nephritis.
37. Systemic scleroderma. Etiology, pathogenesis, morphological characteristics, consequences and complications, causes of death.
38. Dermatomyositis. Etiology, pathogenesis, morphological characteristics, consequences and complications, causes of death.
39. Bekhterev's disease. Etiology, pathogenesis, morphological characteristics, consequences and complications, causes of death.
40. Periarteritis nodosa. Etiology, pathogenesis, morphological characteristics, consequences and complications, causes of death.

### **References:**

#### **Main:**

1. Atlas of micropreparations in pathomorphology / I.I. Starchenko, B.M. Filenko, N.V. Royko, etc.; VDZU "UMSA". - Poltava, 2018. - 190 p
2. Starchenko, S.O. Bilokon and others.. – Poltava: Tov. "ASMI" - 2018. - 190 p.
3. Fundamentals of pathology according to Robbins: in 2 volumes. Volume 1 / Vinay Kumar, Abul K. Abbas, John C. Astaire; translation of the 10th Eng. edition. Publisher: All-Ukrainian specialized publishing house "Medytsyna". – X II. - 2019. - 420 p.

4. Fundamentals of pathology according to Robbins: in 2 volumes. Volume 1 / Vinay Kumar, Abul K. Abbas, John C. Astaire; translation of the 10th Eng. edition. Publisher: All-Ukrainian specialized publishing house "Medytsyna". – X II. - 2019. - 420 p.
5. Pathomorphology. General pathomorphology: a study guide / edited by Ya. Ya. Bodnara, V.D. Voloshina, A.M. Romanyuk, V.V. Gargin. - New Book, 2020. - 248 p.
6. Pathomorphology of the main diseases of the cardiovascular system: study guide / I.I. Starchenko, B.M. Filenko, N.V. Royko – Poltava: "UMSA". - 2019. - 150 p.
7. Starchenko I.I. Pathomorphology of the main diseases of the maxillofacial region: academician. manual / I.I. Starchenko, B.M. Filenko, V.V. Chernyak ; "UMSA". – Vinnytsia: Nova Kniga, 2019. – 128 p.
8. Ctarchenko I.I. Special pathomorphology (basic course) for students of medical faculties of higher medical educational institutions of III-IV levels of accreditation / I.I. Starchenko, N.V. Royko, B.M. Filenko. – Poltava, 2017. – 174 p.
9. Tuffaha S. A. Muin Immunohistochemistry in the diagnosis of tumors / S. A. Tuffaha Muin, S. G. Hychka, Husky Hans. - "Book Plus", 2018. - 336 p.
10. Essentials of pathology: textbook / Ya. Bodnar, A. Romanyuk, V. Voloshyn, V. Gargin - Kharkiv, "Planeta-Print" Ltd, 2020, 219 p.
11. Pathology: textbook / IVSorokina, VD Markovskiy, DI Halata et al.; edited by IVSorokina, VD Markovskiy, DI Halata. - Kyiv: AUS Medicine Publishing, 2019. - 328p. + 2 color inserts (8p. + 12p.).
12. Pathology: textbook / IVSorokina, VD Markovskiy, DI Halata et al.; edited by IVSorokina, VD Markovskiy, DI Halata. - 2nd edition. - Kyiv: AUS Medicine Publishing, 2020. - 328p. + 2 color inserts (8p. + 12p.).

#### Additional:

1. Benign neoplasms of bones of the maxillofacial area in children / P.I. Tkachenko, I.I. Starenko, S.O. Bilokin [and others] - P.: "UMSA", 2016. - 85 p
2. General pathomorphology / I.I. Starchenko, N.V. Royko, B.M. Filenko [et al.] – Poltava, 2016. – 136 p.
3. Zerbino D. D. Pathomorphology and histology: atlas / D. D. Zerbino, M. M. Bagriy, Y. Ya. Bodnar, V. A. Dibrova. – Vinnytsia: Nova Kniga, 2016. – 800 p.
4. Methods of morphological research / M.M. Baghrii, V.A. Dibrova, O.G. Papadynets, M.I. Grischuk; edited by M.M. Baghria, V.A. Dibrovyy – Vinnytsia: Nova Kniga, 2016. – 328 p.
5. Novoseltseva T.V. Pathology of sexual and endocrine systems / T.V. Novoseltseva, B.M. Filenko, N.I. Hasiuk - Poltava: LLC "ASMI", 2015. - 199 p.
6. Pathomorphology: national. / V.D. Markovskiy, V.O. Tumanskyi, I.V. Sorokina [and others]; edited by V.D. Markovsky, V.O. Tumanskyi. - K.: VSV "Medicine", 2015. - 936p.
7. Practicum on biopsy section course / I.I. Starchenko, A.P. Hasyuk, S.A. Proskurnya [etc.] – Poltava, 2016. – 160 p.

## Lecture No. 8

**Topic:** Disorders of the nervous system. Cerebrovascular disease.

**Actuality of theme:** Diseases of the nervous system or neurological diseases are pathologies that occur in different parts of the nervous system - in the spinal cord and brain, as well as in peripheral nerve trunks and nodes. Cerebrovascular disease.

### Goal:

Get acquainted with cerebrovascular disease, its types. Analyze the question "brain damage during cardiac arrest", "Hypotensive brain damage", "Spontaneous intracranial hemorrhage", "Intracerebral hemorrhage", "Subarachnoid hemorrhage", "Volume intracranial lesions", "Increased intracranial pressure", "Swelling of the brain", "Edema of the brain", and others.

**Basic concepts:** Ischemic stroke, Cerebral infarction, ischemic encephalopathy, internal and external hydrocephalus, craniocerebral trauma, Fractures of skull bones, Brain damage in craniocerebral trauma, contusions, epidural hematoma, Subdural hematoma, parenchymal hematoma, Epilepsy, Alzheimer's disease, Charcot disease, Multiple sclerosis, Axonal degeneration, Segmental demyelination, Peripheral neuropathies, diabetic polyneuropathy, Paraneoplastic neuropathy, Hereditary motor and sensory neuropathies.

### Plan and organizational structure of the lecture:

Greetings, verification of those present, announcement of the topic, purpose of the lesson, motivation of higher education seekers to study the topic.

### Content of lecture material (lecture text)

*Cerebrovascular disease* in the form of cerebral apoplexy stroke, or stroke (insultus - stroke), there is a sudden cerebrovascular blood circulation disorder. It is the cause of death in about 10% of cases among people who die from all known diseases. Among people who survive a stroke, about 15% lose their ability to work. The incidence increases with age, and almost 80% of patients are over 65 years old. Moreover, at least 84% of people with cerebrovascular disease suffer from brain infarctions (53% of them have heart attacks as a result of thrombosis and 31% as a result of embolism). The last 16% of patients have various forms of hemorrhage (in 10% of them, spontaneous hemorrhage

develops, and in 6%, hemorrhage occurs due to the rupture of a vascular aneurysm).

A temporary (transient) attack of ischemia and a complete, as a rule, acute violation of cerebral circulation are distinguished. A transient ischemic attack is a completely reversible neurological disorder that lasts from a few minutes to (extremely rarely) 1 day, during which no structural damage to the brain occurs. In case of an acute violation of cerebral blood circulation, on the contrary, there is a pronounced damage to the brain tissue. There are many risk factors for the development of acute cerebrovascular accident. Atherosclerotic plaques in cerebral arteries and hypertension (in particular, hypertension) play a dominant role. Among other factors, it is worth mentioning: disorders of plasma lipid content, diabetes, atherosclerosis of the coronary arteries of the heart, heart failure, as well as atrial fibrillation. A long-term smoking habit can also be of great etiological importance, obesity, certain features of the diet, alcoholism. Factors contributing to cerebral hemorrhage are hypertension, congenital anomalies and malformations of brain vessels, arteritis and hemorrhagic diathesis.

*Brain infarction*(ischemic stroke). As in other organs, the damage appears as a result of local stagnation or a significant decrease in the blood supply of the brain substance and represents a zone of necrosis, or a small and clearly limited cell, or which occupies a large part of the organ. A heart attack can occur in any part of the brain, but the most common area of damage is the basin of the middle cerebral artery. Here, too, only part of the marked zone or its entire territory can be damaged. Often, a few days before an ischemic stroke, dizziness, headache, general weakness, numbness in an arm or leg are noted. The onset is acute: the limbs on one side of the body cease to function, speech disorders occur. With the development of right-sided hemiplegia (paralysis of the muscles of one half of the body), such disorders are persistent.

The three most common causes of cerebral infarction are: thromboembolism of brain vessels, thrombosis and stenosing atherosclerosis of cerebral arteries, damage to the arterial network of the brain of a local, inflammatory or systemic nature. The sources of cerebral thromboembolism can



be wall thrombi in infectious endocarditis (vegetation), myocardial infarction, severe arrhythmias, in non-bacterial thromboendocarditis in persons with cachexia and severe chronic diseases. Brain damage as a result of embolism can also complicate open heart or coronary artery bypass surgery. Another source of thromboembolism can be an atherosclerotic plaque covered with ulcers in the aorta or neck arteries.

As for thrombosis and atherosclerotic plaques, along with cerebral arteries, lesions are determined in the internal carotid and vertebral arteries. Atherosclerotic plaques in cerebral arteries, as a rule, are combined with the formation of plaques in many other vessels, including the arteries of the extremities. Stenosis caused by marked plaques does not necessarily lead to cerebral infarction, because at normal blood pressure, the caliber of the artery must decrease by 90% before a decrease in blood supply occurs.

However, in many cases, cerebral infarction is the result of a combination of systemic circulatory failure and atherosclerotic stenosis of the arteries of the neck and (or) brain. It can also develop as a result of occlusion (clogging) of intracranial or cervical arteries. The most common site of thrombotic occlusion is the middle cerebral artery. Atherosclerotic narrowing or occlusions can be found in any part of the carotid and vertebral arteries. The most common area of damage is the place where the internal carotid artery begins. However, when the marked section of the artery is blocked, a heart attack develops only if the blood circulation through the collateral pathways is insufficient. In some patients, thrombotic masses spread along the internal carotid artery into the middle and anterior cerebral arteries. In this case, a large part of the hemisphere of the brain undergoes a heart attack.

In addition to all of the above, in the pathogenesis of cerebral infarctions, inflammatory lesions or lesions of a systemic nature play a certain role. These are periarteritis nodosa, systemic lupus erythematosus and large cell arteritis. Cerebrovascular accidents can complicate a number of diseases and conditions of completely different etiology: true red polycythemia and sickle cell anemia, pregnancy and the postpartum period, the use of some oral contraceptives.

*Brain infarction* can be red (hemorrhagic) and white (pale, ischemic).

With a pronounced hemorrhagic component, the lesion resembles a hematoma, but the difference is the preservation of the general architecture of the affected tissue. White heart attack (white or gray softening of the brain) is difficult to determine macroscopically if the process is less than 1 day old. At later times, the dead tissue has a limp consistency, looks swollen, and can stick to the blade of a knife. Internal and external hydrocephalus sometimes develop. The boundary between gray and white matter in the area of such a lesion is usually absent. Microscopically, ischemic necrosis of neurons, pallor of myelin staining and sometimes accumulation of leukocytes around the dead vessels are determined. If the damage is extensive, the swelling of the dead tissue and the swelling surrounding its brain matter, can lead to an increase in intracranial pressure. Within a few days, the tissue at the site of the infarction becomes even wetter with signs of decay. At this stage, you can see many macrophages ("granular balls") filled with fat granules and other inclusions, which are products of the breakdown of myelin and other components of brain tissue. Enlarged astrocytes and proliferation of capillaries are determined around the infarct zone.

During the following weeks, the dead tissue (or rather, the products of its decay) is separated and gliosis develops. Ultimately, at the site of the infarct, the tissue shrinks within the infarct and a cyst is formed. Sometimes such a cyst sprouts with small blood vessels and glial elements. If the infarct was red (hemorrhagic), then many macrophages absorb hemosiderin, the masses of which, lying inside and outside the cells, give the cyst walls a brown color. Wrinkling of the tissue within the infarct is accompanied by expansion of the lateral ventricle on the affected side. In addition to the shrinkage of brain tissue and the formation of a cyst, the consequences of a brain infarction include Wallerian degeneration of those nerve fibers that were destroyed at the site of the injury. If the infarction borders the internal capsule,

*Selective necrosis of neurons*(dyscirculatory or ischemic encephalopathy). Neurons need a constant and adequate supply of oxygen and glucose. Oxygen supply largely depends on the function of the lungs and the level of cerebral circulation. The latter, in turn, is associated with perfusion pressure, the value

of which is the difference between the parameters of systemic (arterial) pressure and cerebral venous pressure. Blood circulation in the brain is controlled by self-regulating mechanisms that maintain the relative constancy of blood volumes, despite changes in perfusion pressure. In other words, blood circulation remains within normal limits even if systemic arterial pressure drops to 50 mm Hg. But with systemic pressure below the noted value, the level of blood supply to the brain drops very quickly. Cerebral blood circulation decreases during cardiac arrest or an attack of hypotension. In the first case, diffuse brain damage is noted, in the second - focal damage. The function of the self-regulatory mechanisms mentioned above can be reduced in chronic hypertension, conditions of hypoxia or hypercapnia (increased content of carbon dioxide in the blood and other tissues), as well as in various acute conditions (craniocerebral injuries) that are accompanied by brain tissue damage.

*Cardiac arrest brain damage.* Many patients with severe diffuse lesions of the brain, which occur as a result of cardiac arrest, die within a few days. Brain damage is usually limited to selective neuronal necrosis (a necrotic process that affects only neurons), while most patients do not have an overt infarction. In people who survive for 12 hours. after cardiac arrest, widespread and pronounced necrosis of neurons is determined under a microscope. As a result of the selective sensitivity of groups of neurons to hypoxia, necrosis is most pronounced in the hippocampus, the third, fifth and sixth layers of the cerebral cortex (in particular, in the furrows of the posterior halves of both hemispheres), some basal nuclei of cerebellar pyriform neurons (Purkinje cells) [according to MacSween RNM , Whaley Do., 1994]. After a few days, the dead neurons disappear and an intense reaction is observed on the part of astrocytes, microglia and capillaries. Similar changes occur with carbon monoxide poisoning, severe forms of epilepsy and hypoglycemia.

*Hypotensive damage to the brain.* They mainly concern the bordering zones between the arterial basins of the cerebrum and the cerebellum. In the parietal-occipital region, where the basins of the anterior, middle, and posterior cerebral arteries meet, heart attacks tend to involve large volumes of lesions. It

is possible to spread such a lesion to the basal nuclei, in particular the head of the caudate nucleus (adjacent to the lateral ventricle, separated by the internal capsule from the lenticular nucleus and the thalamus) and the upper third of the shell (putamen) of the lenticular nucleus. The hippocampus, despite its extreme sensitivity to ischemia during cardiac arrest, remains intact. Hypotensive lesions of the brain occur mainly with a sudden drop in blood pressure, after which the pressure quickly returns to normal. Due to a sharp drop in blood pressure, the self-regulation of cerebral circulation is disturbed. regions, the most distant from the main arterial trunks, experience the greatest insufficiency of blood supply. There are known examples of brain lesions that develop in connection with major surgical operations under general anesthesia, as well as with myocardial infarction or severe hemorrhage.

*Spontaneous intracranial hemorrhage.* The most common variants are intracerebral hemorrhage in hypertension and subarachnoid hemorrhage in rupture of an arterial aneurysm.

*Intracerebral hemorrhage*(hemorrhagic stroke, cerebral apoplexy). A huge number of intracranial hematomas develop in old age in people suffering from hypertension, as a result of the rupture of one of the numerous microaneurysms. Nowadays, it is considered established that such small aneurysms are formed in the vascular network of the brain in most people with hypertension. The most frequent localizations of hypertensive cerebral hemorrhages are the zones of the basal nuclei and the internal capsule, followed by the bridge of the brain (Varovli's bridge) and the cerebellum. Usually, the hematoma quickly increases in volume, leads to a sudden increase in intracranial pressure, rapid deformation of the brain and the formation of internal cavities. The mass of blood that has spilled can break into the ventricular system or into the subarachnoid space.

Clinically, a sudden onset, loss of consciousness, and occasionally the development of a comatose state are determined. A little later, meningeal symptoms may be detected: stiffness (increased tone, tension) of the muscles of the back of the head, Kernig's symptom (V. M. Kernig) (impossibility of passive extension of the leg bent at the hip and knee joints). When blood breaks into the

ventricles of the brain, the patient's condition worsens. Narrowing of the pupils (miosis) is also a characteristic feature of a hemorrhagic stroke. Patients with a large cerebral hemorrhage rarely survive 1–2 days.

The appearance of intracerebral hematomas varies and depends on the age of the process. A recent hemorrhage looks like a cluster of dark red blood clots. If its volume is not so large as to cause quick death, then after about 1 week the peripheral zone of the hematoma acquires a brown color. Microscopically, a hemorrhage is a mass of spilled blood, which can almost not cause (or rather, not have time to cause) a reactive response of glia. Over time, proliferative changes in capillaries and astrocytes appear around the hemorrhage zone, in addition to gliosis and hemosiderosis, the masses of which are determined outside cells and inside macrophages. If the patient continues to live, gliosis turns into a tender capsule. Eventually, hemolyzed blood products are broken down and completely removed by macrophages, a so-called apoplexy cyst is formed,

Another quite frequent cause of spontaneous intracerebral hemorrhage is the rupture of a vascular malformation. We are talking about varicose veins, arteriovenous aneurysms, etc., the sizes of which can vary from small capillary angiomas to massive formations built from large and thick-walled vascular channels. Many malformations do not prevent the long life of the patient, but some of them end with subarachnoid hemorrhage.

*Subarachnoid hemorrhage.* About 65% of patients with spontaneous non-traumatic subarachnoid hemorrhage have at the basis of these intracranial catastrophes ruptures of a saccular aneurysm of any of the main cerebral arteries. About 5% of observations of subarachnoid hemorrhage are associated with cases of rupture of vascular malformations, another approximately 5% - with blood diseases, as well as the spread of intracranial or intraventricular hematoma into the subarachnoid space. In approximately 25% of cases, the cause cannot be identified, despite full cerebral angiography and thorough postmortem examinations.

Subarachnoid hemorrhage develops acutely. Disturbances of consciousness and a dizzy state are noted, there is a short-term loss of

consciousness. 50% of patients develop vomiting, bradycardia, neck muscle stiffness, bilateral Kernig symptom. In the future, a rise in body temperature, moderate leukocytosis, and blood in the cerebrospinal fluid are observed. If the patient continues to live, after a few days xanthomatosis (yellow color) of the cerebrospinal fluid is determined, and after about 3 weeks the cerebrospinal fluid becomes colorless. Approximately 40% of patients with subarachnoid hemorrhage die, especially when blood breaks out of the brain substance into the lateral or IV ventricle.

*Volumetric intracranial lesions.* About 70% of the total intracranial volume is occupied by the brain, approximately 15% by cerebrospinal fluid and blood.

*Increased intracranial pressure.* Any increase in the volume of each of the three specified parts of the skull (in the absence of a compensatory decrease in the volume of one or both other parts) leads to an increase in intracranial pressure.

The temporary period of spatial compensation, during which intracranial pressure does not exceed normal limits, is characterized by a decrease in the volume of cerebrospinal fluid in the ventricles and in the subarachnoid space, a decrease in the volume of blood in the intracranial veins. With slowly growing neoplasms (meningioma) around the tumor node, a small loss of brain tissue is possible. When the reserve space is used, a critical moment comes when the increase in the volume of the contents of the skull causes a sudden increase in intracranial pressure and a rapid deterioration of the patient's condition. The expansion of the arterioles of the brain, due to the increase in the partial pressure of carbon dioxide in the arteries, is of significant importance. With a rapid increase in the volume of the lesion, compensatory mechanisms fail faster,

Spreading intracranial lesions cause deformation and displacement of the brain. The increase in intracranial pressure is more significant than the nature of the primary lesion.

Clinical symptoms of high intracranial pressure are presented by headache, nausea, increased systolic blood pressure, slow pulse, gradual loss of consciousness and the transition to coma (deep suppression of the functions of

the brain and other body systems). Ophthalmoscopically, swelling of the disc (nipple) of the optic nerve is determined (a decrease in the anterograde axoplasmic current in the axons of the optic nerve and compression of the retinal veins in the area where they cross the subarachnoid space in the optic nerve sheath).

The standard sequence of events for spreading (bulky) lesions above the cerebellar tent (supratentorial lesion) is as follows:

- with the increase of the center (node) of the lesion, the volume of the corresponding hemisphere changes, the mass of cerebrospinal fluid shifts in the subarachnoid space, flattening of the convolutions of the brain is observed under the dura mater;

- furrows are progressively narrowed, during pathological examination the surface of the brain is dry;

- cerebrospinal fluid is displaced from the ventricular system, the lateral ventricle on the affected side decreases, the opposite one expands;

- with further spread of the affected area, the deformation of the brain progresses with the shift of midline structures (interventricular septum, anterior cerebral arteries and the third ventricle);

- the development of internal brain hernias is possible. The lumbar gyrus (arc-shaped, the one that encircles the corpus callosum, is located on the medial surface of the hemisphere and enters the vaulted gyrus) protrudes, forming a hernia under the free edge of the sickle of the cerebrum and above the corpus callosum (supracallosal subsickle hernia).

The most important form of internal brain hernia associated with volume damage is tentorial (referring to the tent of the cerebellum). The medial part of the temporal lobe on the side of the lesion is pushed through the hole in the tent, compresses and displaces the midbrain (the roof of the quadrituberous plate and the legs of the cerebrum), which pushes through from the opposite and hard edge of the cerebellar tent.

As a result of the inevitable obstruction of the opening in the tent of the cerebellum and the continuing production of cerebrospinal fluid, the pressure gradient increases with the predominance of supratentorial pressure over

infratentorial pressure, which quickly limits the volume of consciousness in the patient. Structural disorders are associated with a shift in the caudal direction of the brain stem, compression of the III and VI cranial nerves (disruption of the movement of the eyeballs and pupillary reflexes, sometimes there is an infarction of the cortical tissue in the medial-occipital area on the side of the lesion).

*Brain infarction* can develop as a result of compression of the posterior cerebral artery in the area of its passage through the tent of the cerebellum. A typical complication of expanding supratentorial lesions is hemorrhage into the midbrain and pons of the brain (varoliv bridge) involving the roof (tegmentum) of the midbrain (result of a combination of downward displacement of the brainstem, obstruction of venous drainage, and arterial distention).

*Supratentorial lesion*, which expands, can cause cerebellar tonsillar herniation (wedging of the tonsils into the greater occipital foramen), which is most common with expanding infratentorial lesions. The tonsils squeeze the medulla oblongata, which causes deformation of the respiratory center and cessation of breathing (apnea). With the development of obstruction of the flow of cerebrospinal fluid through the IV ventricle, intracranial pressure increases, which causes the appearance of a vicious circle.

In a patient with intracranial lesions that expand (bulky), a spinal tap can accelerate the development of an internal hernia and severe complications. A spinal tap is contraindicated in a patient with increased intracranial pressure.

*Swelling of the brain.* This is an increase in the volume of brain tissue as a result of swelling or an increase in blood mass. The basis of the increase in blood mass is pronounced vasodilatation in hypoxia, hypercapnia (increased carbon dioxide content in the blood and other tissues), loss of vasomotor tone. Swelling of the brain in conditions of vasodilatation is the main factor contributing to an increase in intracranial pressure in acute skull injuries.

*Edema of the brain.* Edema has a vascular (vasogenic) and cytotoxic origin.

Brain swelling of the vasogenic type is combined with swelling of other tissues, caused by an increase in filtration pressure and (or) permeability of



capillaries and venules, prevails in the area of strokes, fresh heart attacks, brain abscesses, tumors and has an interstitial character. The tissue on the cut surface is pale and swollen. Microscopically, the separation of nerve tissue elements with a swollen fluid is determined, swollen astrocytes are found.

Cytotoxic brain edema is less common (fluid accumulates inside the cells), occurs in some metabolic disorders as a result of impaired cellular osmoregulation while maintaining an intact blood-brain barrier.

*Hydrocephalus*. This is an excess accumulation of cerebrospinal fluid in the skull cavity, which occurs in the following variants.

Internal hydrocephalus – increased volumes of cerebrospinal fluid in the ventricular system with their expansion – the most frequent form of hydrocephalus;

External hydrocephalus - the accumulation of an excess amount of cerebrospinal fluid in the subarachnoid space - is divided into open and occlusive (closed) forms. With open external hydrocephalus, the outflow of cerebrospinal fluid from the ventricular system into the subarachnoid space is preserved, and with closed hydrocephalus, it is disturbed. The accumulation of cerebrospinal fluid, which occurs with the loss of brain tissue, is called compensatory, or vacant, hydrocephalus. A frequent cause of the disease is the expansion of the ventricles in conditions of atrophy of brain tissue (in dementia), the intracranial pressure does not increase with it.

Hydrocephalus in the form of an acute condition with increased intracranial pressure is noted when the outflow of cerebrospinal fluid is blocked (obstruction), while a decrease in the volume of white matter in both hemispheres of the brain is detected due to the expansion of the ventricles. With obstructive hydrocephalus, this is of the greatest importance.

Even a small lesion in the area of the aqueduct in the midbrain quickly causes hydrocephalus, while the pathological focus must be adjacent to the ventricular system (primary meningitis, subarachnoid hemorrhage with partial obliteration of the subarachnoid space and blockage of the outflow of cerebrospinal fluid).

Several diseases accompanied by obstruction of the outflow of

cerebrospinal fluid and hydrocephalus have a congenital origin: Chiari malformations (developmental defects) and Dandy-Walker syndrome. A rare cause of hydrocephalus in adolescents and young adults is gliosis in the area of the aqueduct as a result of the proliferation of periaqueductal astrocytes with progressive stenosis of the aqueduct.

Topical diagnosis of cerebrospinal fluid outflow blockage shows that if the blockage develops in the place of the interventricular opening, then the expansion of one lateral ventricle occurs, if in the III ventricle or aqueduct - the expansion of both lateral ventricles, if in the area of the outlet openings of the IV ventricle - the expansion of the entire ventricular system, and if in the subarachnoid space - the expansion of the entire system of ventricles, but in this case the cerebrospinal fluid can enter the subarachnoid space through the outlet openings of the IV ventricle.

Possible causes of hydrocephalus include an increase in the production of cerebrospinal fluid (occurs with a papillary tumor in the vascular plexus) or a decrease in the absorption of cerebrospinal fluid (as a result of subarachnoid hemorrhage).

#### *Brain injury.*

In war zones, in industrialized countries, head injuries occupy a huge share in the mortality structure of people under 45 years of age. The clinical course of injuries is determined by the anatomical localization of the damage and the limited possibilities of functional restoration of brain tissue. Necrosis of brain tissue with a volume of several cubic centimeters may not be accompanied by symptoms (frontal lobes), cause serious condition (spinal cord) or death (brain stem). There are two main types of brain injury.

- the "impact" type is associated with the action of all kinds of damaging objects (bullets, fragments, stones) and represents an open trauma of the skull with a violation of the integrity of the bone covers;

- the "dynamic" type occurs as a result of a sudden shift of the brain relative to the bones of the skull and is accompanied by compression, displacement or tension of some parts of the brain in relation to others, especially during rotational action and a combination of acceleration and

deceleration; is usually a closed skull injury.

*Fractures of skull bones.* There is no complete correlation between the presence of skull bone fractures and significant brain injuries (about 25% of victims of fatal craniocerebral trauma do not have fractures), which does not exclude a high frequency of secondary injuries in the form of intracranial hematoma. A depressed fracture with local pressure on the brain tissue and a scalp wound of the head is considered open, it is a possible source of primary bacterial contamination of the brain membranes. Any type of fracture of the base of the skull contributes to the entry of infection from the nasal passages, paranasal sinuses or the cavity of the middle ear, often accompanied by rhinorrhea or otorrhea cerebrospinal fluid (flow of fluid from the nasal cavity or tympanic cavities).

Complications include: ruptures of the meningeal artery, extradural hematoma, damage to the carotid artery in the cavernous sinus, formation of a carotid-cavernous fistula.

*Brain damage in craniocerebral trauma.* At the time of injury, primary damage to the brain (concussion, contusion, which are closed injuries) and diffuse damage to nerve fibers are possible. In the post-traumatic period, secondary damage to the brain tissue caused by hematomas and increased intracranial pressure may develop.

Primary brain damage. Concussion. This is a clinical syndrome, which is divided into mild, medium and severe degrees according to severity.

The average degree is characterized by rapid development and fleeting neurological disorders (loss of consciousness, nausea or vomiting, headache, breathlessness, loss of reflexes), full neurological recovery is possible. Retrograde amnesia persists for some time (loss of the ability to store and reproduce previously acquired information). The pathogenesis of sudden disturbance of nervous activity is unknown. In the absence of structural lesions and complete reversibility, biochemical and ultrastructural disturbances are detected in the affected brain tissue (depletion of mitochondrial ATP, changes in vascular permeability and damage to axons).

A severe degree is attributed to contusions of the brain.

Brain contusions. Superficial contusions are the most frequent form of damage to brain tissue, directly related to the injury, it is possible in the area of the injury itself (compressed fracture of the bones of the skull). With any variant of "dynamic" craniocerebral injury, the frontal lobes (anterior ends of the hemispheres), the orbital gyrus, the temporal lobes (parts of the temporal lobes outside the nasal furrows), the lower and lateral surfaces of the front halves of the temporal lobes (their vulnerability is explained by the displacement) are more prone to contusion of the brain relative to the skull and forced contact with bone protrusions).

Contusions are more often asymmetric, with more severe damage on the opposite side to the injury zone (damage from "counter-blow"). Severe contusions of the frontal lobes are often associated with trauma to the occipital region (the reverse option does not occur, since the inner surface of the occipital bone is covered with soft tissue).

In case of contusions, the surfaces of the convolutions of the brain are damaged, and in the case of the most severe blows, the entire thickness of the cortex is damaged, with the involvement of white matter in the process, intracerebral hemorrhages and swelling of the brain. Zones of old contusions that have healed are represented by golden-brown areas of shrinkage of the brain substance and gliosis.

*Diffuse damage to axons.* At the moment of damage, nerve fibers are torn as a result of the simultaneous action of acceleration/deceleration forces. This type of brain damage can occur in the absence of superficial contusions.

A pathological examination reveals hemorrhages in the corpus callosum, posterolateral quadrant or quadrants of the rostral (anterior thalamic) zone of the brain stem. In patients who survived, for several weeks (months), expansion of the ventricular system due to a decrease in the mass of white matter is noted. Microscopically, axon bulbs (protrusion of axoplasm at the site of injury) are detected, in the hemispheres of the cerebrum and cerebellum, the stem part of the brain, and the spinal cord, Wallerian degeneration is detected, which develops secondary to the rupture of axons at the time of injury.

*Secondary brain damage.* These are frequent complications of head

injuries. Intracranial hemorrhages are most common in people with skull fractures. They are divided into extradural, subdural and intracerebral.

*Extradural (epidural) hematoma.* It is formed as a result of hemorrhage from meningeal blood vessels (more often from the middle meningeal artery) with the separation of blood masses of the dura mater from the bordering bones of the skull. At the same time, there is a progressive compression of the brain tissue by the blood that pours out (in young children, it develops even without fractures of the bones of the skull). The initial stages are characterized by a relatively mild course of the disease. An increase in the volume of the hematoma causes an increase in intracranial pressure, and then a comatose state. The most frequent localization of extradural hematomas is the frontal and parietal zones or the posterior cranial fossa.

*Subdural hematoma.* This hematoma is formed as a result of the rupture of the venous membranes flowing into the upper sagittal sinus, or in case of severe superficial contusions. The spread of blood masses in the subdural space was noted. With the rapid onset of death, the following are often found at autopsy:

- acute subdural hematoma, which can be large. There are also cells in the form of a thin strip of blood, which also cause an increase in intracranial pressure due to swelling of the bordering brain tissue;

- chronic subdural hematoma - most often a bilateral lesion that lasts several (weeks or months) after a normal craniocerebral injury. In this case, the gradual organization and encapsulation of the lesion is observed. Most often found in elderly people with brain atrophy, spreads slowly, can reach a large volume, and in the case of repeated focal hemorrhages remains asymptomatic.

The fatal outcome is due to secondary damage to brain tissue as a result of high intracranial pressure.

*Intracerebral (parenchymal) hematoma* associated with contusions, is more common in the frontal and temporal lobes. Small and deeply located intracerebral hematomas of the basal nuclei (caudate and lenticular subcortical nuclei of the base of the cerebrum hemispheres) are more common in people with diffuse damage to axons.

*Secondary brain damage* with a craniocerebral injury, they are accompanied by an increase in intracranial pressure, deformation, hernial protrusions, swelling of the brain in the areas of contusions and in the area of subdural hematoma. 90% of people who die from craniocerebral injuries have ischemic brain damage of unknown origin. There is a possible connection with an acute seizure-like violation of the blood supply to the brain tissue as a result of the injury itself, shifts and deformations of the brain with increased intracranial pressure, as a result of delayed cardiac activity and breathing, epilepsy.

*Epilepsy.* As a chronic disease of cerebral origin, it is accompanied by repeated similar seizures, all kinds of changes in the face, develops in persons with serious head injuries in 10% of cases. With open craniocerebral injuries, the incidence of epilepsy reaches 45% with clinical manifestation within the first week after the injury (early epilepsy), less often - after 2-3 months (late epilepsy). Favorable factors for the appearance of late-onset epilepsy are the presence of pressed fractures of the bones of the skull and intracranial hematomas.

*Rare secondary lesions.* Such brain lesions include post-traumatic amnesia and infectious complications associated with open trauma to the skull roof or skull base fracture. They usually manifest as meningitis. The development of meningitis may be delayed, since infectious agents can enter gradually through a small traumatic fistula from the subarachnoid space into one of the main air cavities (sinuses) at the base of the skull. A rare infectious complication is an intracranial (traumatic) brain abscess.

In dystrophic (degenerative) brain diseases, damage to neurons prevails in any localization of the process: cerebral cortex in Alzheimer's disease; basal ganglia and midbrain in Hutchinson's chorea, parkinsonism; motor neurons in amyotrophic lateral sclerosis. Dystrophic diseases are caused by a deficiency of substances (thiamine, vitamin B12), metabolic disorders (primary encephalopathy), exposure to toxic (alcohol) or physical (irradiation) factors.

*Alzheimer's disease.* With this disease, presenile (presenile) insanity or dementia develops. A number of authors include senile (senile) dementia, as

well as Pick's disease. Senile dementia includes progressive dementia in people aged 40-65 years. When the disease appears after the age of 65, we are talking about senile dementia, and when language disorders are added, it is about Pick's disease.

Alzheimer's disease occurs with pronounced intellectual disorders and emotional lability, while focal neurological symptoms are absent. The cause of the disease has not been sufficiently clarified. Previously, the cause of Alzheimer's disease was considered to be a deficiency of acetylcholine and its enzymes in the structures of the cerebral cortex. Recently, a connection with senile cerebral amyloidosis has been established. Pathology in the form of amyloidosis is found in senile plaques, brain vessels, membranes and vascular plexuses. Along with the synthesis of extracellularly located amyloid fibers, which are the main component of senile plaque, in Alzheimer's disease there is a pronounced pathology of intracellular fibrillar structures - proteins of the cytoskeleton. Accumulation of actin microfilaments in the proximal dendrites - Hirano body - is determined.

At autopsy, atrophy of the cerebral cortex is found in the frontal, temporal, and occipital parts, and hydrocephalus often develops. Microscopic examination reveals senile plaques, neurofibrillary tangles (tangles), Hirano bodies in the cortex of atrophied parts of the brain, hippocampus and amygdala. There are no changes in motor and sensitive areas. The cause of death is respiratory infection, bronchopneumonia.

*Amyotrophic lateral sclerosis* (Charcot's disease) is a progressive disease of the nervous system associated with simultaneous damage to motor neurons of the anterior and lateral horns of the spinal cord and peripheral neurons. Characteristic: slow development of spastic paresis, mainly of the muscles of the hands, muscle atrophy, increase of tendon and axial reflexes. Men get sick 2 times more often, mostly middle-aged, it ends in death after 2-6 years.

The cause and mechanism of disease development are unknown. It is assumed that the disease is associated with a chronic viral infection (polio).

Selective atrophy of the anterior motor roots of the spinal cord, posterior ones are normal. Lateral cortico-spinal tracts are compacted, white in color.

Sometimes there is atrophy of the precerebral gyrus, as well as VIII-X and XII pairs of cranial nerves. In all cases - atrophy of skeletal muscles. Microscopic examination reveals pronounced changes in nerve cells: they are wrinkled or in the form of shadows, large fields of neuronal loss. In nerve fibers - demyelination, uneven swelling, then disintegration and death of axial cylinders. Reactive proliferation of glia is observed.

Cause of death: cachexia or aspiration pneumonia.

Demyelinating diseases - in which myelin sheaths are primarily damaged - primary demyelinating diseases; secondary demyelination is associated with axonal damage (for example, multiple sclerosis).

*Multiple sclerosis*(multiple sclerosis) is a chronic disease characterized by the appearance in the brain and spinal cord (white matter) of scattered sclerosis centers - plaques. It usually begins at the age of 20-40, more often in men. The duration is wave-like. The multiple localization of damage centers determines the variety of clinical manifestations of the disease: nystagmus, slurred speech, sharp increase in tendon reflexes, spastic paralysis, visual disturbances. An acute and severe course with the rapid development of blindness and cerebellar disorders and a mild course with minor dysfunction of the central nervous system and its rapid recovery are possible.

It is not possible to find out the reasons, a viral origin of the disease is possible: a virus tropic to oligodendroglia cells.

Well-studied morphogenesis of sclerotic plaques in multiple sclerosis. Fresh foci of demyelination appear around the veins, which are combined with remyelination. The vessels expand and are surrounded by an infiltrate of lymphoid and plasma cells. In response to destruction, the proliferation of glia occurs, myelin breakdown products are phagocytosed by macrophages, then sclerosis develops.

Externally, the brain and spinal cord have changed little. On the sections, a large number of gray plaques are found, which are scattered in the white matter with a diameter of up to several centimeters. There are a lot of plaques, especially around the ventricles of the brain, in the spinal cord and medulla oblongata, brain stem, optic tubercles, white matter of the cerebellum, the



chiasma, optic nerves, optic pathways are often affected.

Microscopically, at an early stage, focal demyelination is found around vessels, especially veins and venules, perivenous demyelination. Vessels are surrounded by lymphocytes, mononuclear cells; axons are relatively preserved. Myelin sheaths swell, their tinctorial properties change, contours are uneven, spherical thickenings along the fibers. Then there is fragmentation and disintegration of myelin sheaths, which are phagocytized by microglia, turning into granular balls.

As the disease progresses (late stage), small perivascular cells are demyelinated, merge, infiltrates from microglial cells appear. At the end, typical plaques are formed in which oligodendrocytes are absent. The cause of death is pneumonia.

*Degenerative changes in peripheral nerves.* There are two types of reactive changes in peripheral nerves in response to damage: segmental demyelination and axonal degeneration, which includes Wallerian degeneration and develops as a result of axon crossing. Often, both types of changes are combined in one patient, but one of them, as a rule, prevails. The basis for their differentiation is a completely different forecast. If the axon remains intact when the pathological process subsides, the restoration of nerve conduction occurs much faster, because leucocytes are capable of rapid remyelination of fibers. However, if the axon is interrupted or crossed, then Wallerian degeneration develops. In this case, the axon can grow only by adding fibers approximately 1 mm in length from the proximal part.

*Axonal degeneration.* It is a consequence of severe damage or death of a neuron or its axon - it develops quickly, starting with the breakdown of myelin. Macrophages then "clean" the affected area from particles of myelin and other structures. Leucocytes proliferate, acquiring the ability to form a new myelin sheath. The most common cause of such an injury is a peripheral nerve injury, and all of the above changes develop distal to the injury site. Proximal to this place, nerve cell bodies undergo swelling, destruction of the endoplasmic reticulum (chromatolysis) occurs. They then repair and support the regeneration of the damaged axon. If the continuity of the endoneurial tubes is preserved, the

prognosis in terms of the possibility of recovery is not bad, despite even the slow pace of axon regeneration. Many axonal processes may not reach the distal part, but will continue the proliferative process in the dense scar tissue. As a result, thickenings are formed, which are called amputation (traumatic) neuromas. With some lesions of peripheral nerves, there is a tendency to primary damage to the axon itself, and it is more severe if it is at the distal end. In this case, axonal degeneration occurs in the opposite direction relative to the neuron, then we are talking about retrograde axon death. Such a process is observed in retrograde neuropathy or distal axonopathy, accompanied by stocking-glove anesthesia (loss of sensitivity in the areas of the extremities, conditionally limited by the tissues of gloves and stockings). Finally, axonal degeneration is also secondary to degeneration of the neuron body. but will continue the proliferative process in dense scar tissue. As a result, thickenings are formed, which are called amputation (traumatic) neuromas. With some lesions of peripheral nerves, there is a tendency to primary damage to the axon itself, and it is more severe if it is at the distal end. In this case, axonal degeneration occurs in the opposite direction relative to the neuron, then we are talking about retrograde axon death. Such a process is observed in retrograde neuropathy or distal axonopathy, accompanied by stocking-glove anesthesia (loss of sensitivity in the areas of the extremities, conditionally limited by the tissues of gloves and stockings). Finally, axonal degeneration is also secondary to degeneration of the neuron body. but will continue the proliferative process in dense scar tissue. As a result, thickenings are formed, which are called amputation (traumatic) neuromas. With some lesions of peripheral nerves, there is a tendency to primary damage to the axon itself, and it is more severe if it is at the distal end. In this case, axonal degeneration occurs in the opposite direction relative to the neuron, then we are talking about retrograde axon death. Such a process is observed in retrograde neuropathy or distal axonopathy, accompanied by stocking-glove anesthesia (loss of sensitivity in the areas of the extremities, conditionally limited by the tissues of gloves and stockings). Finally, axonal degeneration is also secondary to degeneration of the neuron body. which were called amputation (traumatic) neuromas. With some lesions of

peripheral nerves, there is a tendency to primary damage to the axon itself, and it is more severe if it is at the distal end. In this case, axonal degeneration occurs in the opposite direction relative to the neuron, then we are talking about retrograde axon death. Such a process is observed in retrograde neuropathy or distal axonopathy, accompanied by stocking-glove anesthesia (loss of sensitivity in the areas of the extremities, conditionally limited by the tissues of gloves and stockings). Finally, axonal degeneration is also secondary to degeneration of the neuron body. which were called amputation (traumatic) neuromas. With some lesions of peripheral nerves, there is a tendency to primary damage to the axon itself, and it is more severe if it is at the distal end. In this case, axonal degeneration occurs in the opposite direction relative to the neuron, then we are talking about retrograde axon death. Such a process is observed in retrograde neuropathy or distal axonopathy, accompanied by stocking-glove anesthesia (loss of sensitivity in the areas of the extremities, conditionally limited by the tissues of gloves and stockings). Finally, axonal degeneration is also secondary to degeneration of the neuron body. In this case, axonal degeneration occurs in the opposite direction relative to the neuron, then we are talking about retrograde axon death. Such a process is observed in retrograde neuropathy or distal axonopathy, accompanied by stocking-glove anesthesia (loss of sensitivity in the areas of the extremities, conditionally limited by the tissues of gloves and stockings). Finally, axonal degeneration is also secondary to degeneration of the neuron body. In this case, axonal degeneration occurs in the opposite direction relative to the neuron, then we are talking about retrograde axon death. Such a process is observed in retrograde neuropathy or distal axonopathy, accompanied by stocking-glove anesthesia (loss of sensitivity in the areas of the extremities, conditionally limited by the tissues of gloves and stockings). Finally, axonal degeneration is also secondary to degeneration of the neuron body.

*Segmental demyelination.* It occurs when leucocytes and myelin sheaths are damaged, but with an intact (undamaged) axon. As a rule, such a process is focal. Since leucocytes can divide, remyelination develops. Demyelinated areas of nerve fibers are replaced by one or more leucocytes, which is accompanied

by some shortening of the affected segments of the fibers (between the two nearest interceptions of Ranvier). If the damage is renewed or repeated (for example, in hereditary neuropathies), then the impaired repair process turns into macrocyte hyperplasia. Concentric layers of cytoplasmic macrocytes form along the nerve fibers the so-called "onion spheres", which remotely resemble the sensitive nerve cells of Pacini in the dermis.

*Peripheral neuropathies.* They are accompanied by muscle weakness and atrophy, loss or change of sensitivity, as well as vegetative disorders. During the development of axonal degeneration, fasciculation (involuntary contraction of individual bundles of muscle fibers in the area innervated by affected nerves) and exhaustion occur. However, in the case of demyelination, these signs are absent, since there is no denervation, but only insufficient conduction. Diseases that cause peripheral neuropathies are acute, developing over several days, subacute (progressing over several weeks), and chronic, progressing over several months or years. A single nerve (mononeuropathy) or several separate nerves (complex mononeuritis) or several symmetrically located nerves (polyneuropathy) may be affected. At the same time, one or both types of degenerative changes occur. To recognize peripheral neuropathies, electrical research of nerve conduction and morphological study of biopsies are used.

Acute idiopathic inflammatory polyneuropathy (acute ascending polyradiculoneuritis, Guillain–Barre syndrome; G.Guillain, M.J.Barre). This is the most common form of demyelinating peripheral neuropathy, usually starting 1-2 weeks after an acute stroke. Such polyneuropathy can also occur after immunization, surgery, or in the case of mycoplasma infection, HIV infection, or a malignant process. The disease is characterized by a rapid onset. Numbness in the areas innervated by the affected nerves, paresthesias (false sensations of tingling and burning, crawling of ants, etc.) and ascending paralysis (starting from the legs and quickly spreading to the muscles of the trunk, arms, neck, face, tongue, pharynx) are noted and larynx). Due to accompanying respiratory failure, the patient may urgently need artificial lung ventilation. Cranial nerves (especially oculomotor) can be involved in the process, and when the autonomic nervous system is damaged, functional disorders of sphincters and cardiac

arrhythmias are noted. Changes in the cerebrospinal fluid, in which an increase in protein concentration and a very small number of lymphocytes, are quite characteristic. The high content of protein in cerebrospinal fluid is explained by its exudation from blood vessels located in the area of the spinal roots.

Regardless of the localization of the lesion in the peripheral nervous system, in Guillain-Barre syndrome there is segmental demyelination with relative preservation of axons, with endoneural lympho-macrophagic infiltrates. Macrophages provide exfoliation and phagocytosis of myelin surface plates.

After several weeks (sometimes after 1 week), recovery begins. It can become complete, but sometimes the disease acquires a chronic relapsing or wave-like course. In these cases, "onion balls" can be found in the affected nerves. The causes of the development of acute idiopathic inflammatory polyneuropathy are associated with immunological disorders.

*Diabetic neuropathy*(diabetic polyneuropathy). This is damage to the nervous system in diabetes, mainly peripheral nerves. The lesion occurs in fibers of different thicknesses, involving unmyelinated fibers. In peri- and endoneural capillaries, there is a noticeable narrowing of the lumen, thickening and bifurcation of the basal membrane, which indirectly indicates the possible pathogenetic role of chronic ischemia.

Neuropathy in uremia. Predominant changes in the central nervous system caused by the accumulation of toxic products of nitrogenous metabolism. Peripheral nerve damage has a primary and secondary (relative to changes in the central nervous system) character.

*Paraneoplastic neuropathy*. It is one of the complications caused by neoplasm. Sometimes the clinical manifestations of the underlying disease begin with it.

Paraproteinemic neuropathy. Paraproteinemia is the content of monoclonal proteins (immunoglobulins) of any isotope in the blood, but more often IGG. Specific IgM-antibodies to myelinated glycoprotein were detected in affected peripheral nerves [according to MacSween RNM, Whaley Do., 1994]. It was found that their presence is associated with demyelination.

Toxic neuropathy. Many drugs and environmental factors have a harmful

effect on nerve tissue, causing peripheral neuropathies. These include furadonin, diaphenyl sulfone, dierynyl hydantogen, etc. The most common cause of toxic neuropathy is chronic alcoholism. Alcoholic neuropathy can occur with severe degeneration of myelin sheaths. Among the chemical and non-medicinal agents, it is worth mentioning lead and arsenic.

*Hereditary motor (motor) and sensitive (sensory) neuropathies.* These are rare diseases in which there is selective damage to lower motor neurons (Werdnig-Hoffmann atrophy; G. Werdnig, J. Hoffmann; infantile spinal muscular atrophy) or primary sensory neurons (hereditary sensory neuropathy). There are two more diseases in this group. In Charcot–Marie–Tooth disease (JMCharcot, P.Marie, HHTooth) demyelination with "onion spheres" is common. Dejerine-Sotta disease (JJDejerine, J. Sotta) is characterized by axonal degeneration.

Inflammatory diseases are divided into meningitis (for childhood infections) and encephalitis.

**Materials on the activation of students of higher education during the lecture: questions, situational tasks, etc(*if necessary*):**

**General material and bulk-methodological support of the lecture:**

**Questions for self-control:**

1. Cerebrovascular diseases. Vascular dyscirculatory encephalopathy, ischemic cerebral infarction, cerebral hemorrhage, complications and causes of death in cerebrovascular diseases.
2. Post-anoxic encephalopathy and brain death syndrome.
3. Neurodegenerative diseases (Alzheimer's disease). Etiopathogenesis, morphological characteristics, complications, causes of death.
4. Demyelinating diseases (amyotrophic lateral sclerosis, multiple sclerosis). Morphological characteristic
5. Neuropathy. Morphological characteristics.

6. Diseases of the bone system: parathyroid osteodystrophy (Recklinghausen's disease), fibrous bone dysplasia (Lichtenstein-Breitsev disease), osteoporosis, Paget's disease (deforming osteodystrophy), osteomyelitis.
7. Diseases of the joints: Arthritis, spondyloarthritis, osteochondrosis, Shmorlia hernia
8. Osteoarthritis. Etiopathogenesis, morphological characteristics, complications.
9. Diseases of skeletal muscles: progressive muscular dystrophy (myopathy Duchenne, Erb, Leyden) myositis. myotonia

### References:

#### Main:

1. Atlas of micropreparations in pathomorphology / I.I. Starchenko, B.M. Filenko, N.V. Royko, etc.; VDZU "UMSA". - Poltava, 2018. - 190 p
2. Starchenko, S.O. Bilokon and others.. – Poltava: Tov. "ASMI" - 2018. - 190 p.
3. Fundamentals of pathology according to Robbins: in 2 volumes. Volume 1 / Vinay Kumar, Abul K. Abbas, John C. Astaire; translation of the 10th Eng. edition. Publisher: All-Ukrainian specialized publishing house "Medytsyna". – X II. - 2019. - 420 p.
4. Fundamentals of pathology according to Robbins: in 2 volumes. Volume 1 / Vinay Kumar, Abul K. Abbas, John C. Astaire; translation of the 10th Eng. edition. Publisher: All-Ukrainian specialized publishing house "Medytsyna". – X II. - 2019. - 420 p.
5. Pathomorphology. General pathomorphology: a study guide / edited by Ya. Ya. Bodnara, V.D. Voloshina, A.M. Romanyuk, V.V. Gargin. - New Book, 2020. - 248 p.
6. Pathomorphology of the main diseases of the cardiovascular system: study guide / I.I. Starchenko, B.M. Filenko, N.V. Royko – Poltava: "UMSA". - 2019. - 150 p.
7. Starchenko I.I. Pathomorphology of the main diseases of the maxillofacial region: academician. manual / I.I. Starchenko, B.M. Filenko, V.V. Chernyak ; "UMSA". – Vinnytsia: Nova Kniga, 2019. – 128 p.
8. Ctarchenko I.I. Special pathomorphology (basic course) for students of medical faculties of higher medical educational institutions of III-IV levels of accreditation / II Starchenko, N.V. Royko, B.M. Filenko. – Poltava, 2017. – 174 p.
9. Tuffaha S. A. Muin Immunohistochemistry in the diagnosis of tumors / S. A. Tuffaha Muin, S. G. Hychka, Husky Hans. - "Book Plus", 2018. - 336 p.
10. Essentials of pathology: textbook / Ya. Bodnar, A. Romanyuk, V. Voloshyn, V. Gargin - Kharkiv, "Planeta-Print" Ltd, 2020, 219 p.
11. Pathology: textbook / IVSorokina, VD Markovskyi, DI Halata et al.; edited by IVSorokina, VD Markovskyi, DI Halata. - Kyiv: AUS Medicine Publishing, 2019. - 328p. + 2 color inserts (8p. + 12p.).
12. Pathology: textbook / IVSorokina, VD Markovskyi, DI Halata et al.; edited by IVSorokina, VD Markovskyi, DI Halata. - 2nd edition. - Kyiv: AUS Medicine Publishing, 2020. - 328p. + 2 color inserts (8p. + 12p.).

Additional:

1. Benign neoplasms of bones of the maxillofacial area in children / P.I. Tkachenko, I.I. Starenko, S.O. Bilokin [and others] - P.: "UMSA", 2016. - 85 p
2. General pathomorphology / I.I. Starchenko, N.V. Royko, B.M. Filenko [et al.] – Poltava, 2016. – 136 p.
3. Zerbino D. D. Pathomorphology and histology: atlas / D. D. Zerbino, M. M. Bagriy, Y. Ya. Bodnar, V. A. Dibrova. – Vinnytsia: Nova Kniga, 2016. – 800 p.
4. Methods of morphological research / M.M. Baghrii, V.A. Dibrova, O.G. Papadynets, M.I. Grischuk; edited by M.M. Baghria, V.A. Dibrov – Vinnytsia: Nova Kniga, 2016. – 328 p.
5. Novoseltseva T.V. Pathology of sexual and endocrine systems / T.V. Novoseltseva, B.M. Filenko, N.I. Hasiuk - Poltava: LLC "ASMI", 2015. - 199 p.
6. Pathomorphology: national. / V.D. Markovskiy, V.O. Tumanskyi, I.V. Sorokina [and others]; edited by V.D. Markovsky, V.O. Tumanskyi. - K.: VSV "Medicine", 2015. - 936p.
7. Practicum on biopsy section course / I.I. Starchenko, A.P. Hasyuk, S.A. Proskurnya [etc.] – Poltava, 2016. – 160 p.

## Lecture No. 9

**Topic:** Respiratory diseases.

**Actuality of theme:** Respiratory diseases.

- pharyngitis and laryngitis - inflammation of the pharynx;
- tracheitis - inflammation of the trachea;
- bronchitis - inflammation of the bronchi.
- pneumonia - an inflammatory disease of the lungs;
- bronchial asthma;
- pleurisy - inflammation of the lining of the lungs (pleura).

**Goal:** Get acquainted with the diseases caused by certain pathogens in the respiratory organs.

**Basic concepts:**

acute bronchitis, top pneumonia, pleuropneumonia, bronchopneumonia, with streptococcal bronchopneumonia, interstitial pneumonia, interstitial pneumonia, abscess, lung gangrene, chronic bronchitis, bronchiectasis, lung emphysema, pneumofibrosis, epidermoid cancer, pleurisy.

**Plan and organizational structure of the lecture:**



Greetings, verification of those present, announcement of the topic, purpose of the lesson, motivation of higher education seekers to study the topic.

### **Content of lecture material (lecture text)**

The peculiarity of the structure of the respiratory organs, a large number of etiological factors that cause the development of the disease, age characteristics determine the variety of clinical and morphological manifestations of diseases of the respiratory organs. Pathogenic agents, primarily viruses and bacteria, which cause inflammatory processes in the bronchi and lungs (tracheitis, bronchitis, pneumonia) are of great importance in respiratory diseases. No less important in the occurrence of inflammatory, allergic (bronchial asthma) and tumor (cancer) diseases are chemical and physical factors that enter the respiratory tract and lungs together with polluted air. Not the last role in the occurrence of diseases of the respiratory organs belongs to hereditary factors and age characteristics.

However, the occurrence of respiratory diseases is determined not only by the influence of pathogens and the presence of background factors, but also by the state of the protective barriers of the respiratory system, among which are aerodynamic filtration, humoral and cellular factors of general and local protection. Aerodynamic filtration is a mucocellular transport carried out by the ciliated epithelium of the bronchial tree. The humoral factors of local protection of the respiratory system include secretory immunoglobulins (Ig A), complement system, interferon, lactoferrin, protease inhibitors, lysozyme, surfactant, chemotaxis factor, lymphokines; and to the humoral factors of general protection - IgM and IgG. Cellular factors of local protection of the respiratory system include alveolar macrophages, and general protection includes polymorphonuclear leukocytes, macrophages, and lymphocytes.

Modern clinical morphology has many methods of diagnosing diseases of the respiratory system. The most important among them are cytological and bacterioscopic examination of sputum, bronchoalveolar lavage (bronchoalveolar lavage), biopsy of bronchi and lungs.

Among the diseases of the respiratory organs, the most important are:

acute bronchitis, acute inflammatory (pneumonia) and destructive (abscess, gangrene) lung diseases, chronic non-specific lung diseases, pneumoconiosis, bronchial and lung cancer, as well as inflammation of the pleura - prevrit.

*Acute bronchitis*– acute inflammation of the bronchi; can be an independent disease or a manifestation of a number of diseases, especially pneumonia, chronic glomerulonephritis with renal failure (acute uremic bronchitis), etc.

Among the etiological factors, a significant role belongs to viruses and bacteria that cause acute respiratory diseases. Physical (dry or cold air), chemical (chlorine vapors, sulfur gas, nitrogen oxides, etc.) factors, as well as dust, are of great importance in the development of diseases. The pathogenic influence of these factors is facilitated by hereditary insufficiency of the protective barriers of the respiratory system, primarily mucocellular transport and humoral factors of local protection; moreover, damage to mucocellular transport increases as acute bronchitis develops. This is due to the fact that in response to the pathogenic effect, mucus production by the glands and goblet cells of the bronchi increases, and this in turn leads to peeling of the ciliated prismatic epithelium, exposure of the mucous membrane of the bronchi,

With acute bronchitis, the mucous membrane of the bronchi becomes full of blood and swollen, small hemorrhages are possible, and sometimes ulcers; in most cases, there is a lot of mucus in the lumen of the bronchi. Various forms of catarrhal (serous, mucous, purulent, mixed), fibrinous or fibrinous-hemorrhagic inflammation occur in the bronchial mucosa; destruction of the bronchus wall is possible, and sometimes ulceration, then we are talking about destructive-ulcerative bronchitis. In the bronchioles, acute inflammation (bronchiolitis) can be productive, this leads to thickening of the wall due to its infiltration by lymphocytes, macrophages, plasma cells, as well as proliferation of the epithelium. In the proximal parts of the bronchi, the inflammatory reaction occurs only in the mucous membrane (endobronchitis) or mucous and muscular (endomeso-bronchitis). In the distal parts of the bronchi, all layers of the bronchial wall are involved in the pathological process (panbronchitis and panbronchiolitis); at the same time, the transition of inflammation to the

peribronchial tissue (peribronchitis) is possible.

Complications of acute bronchitis are associated with a violation of the drainage function of the bronchi, which contributes to the aspiration of infected mucus into the distal parts of the bronchial tree and the development of lung tissue inflammation (bronchopneumonia). With panbronchitis and panbronchiolitis, the transition of inflammation is possible not only to the peribronchial tissue, but also to the interstitial tissue of the lungs (peribronchial interstitial pneumonia).

The consequence of acute bronchitis depends on the depth of damage to the wall of the bronchus. Serous and mucous bronchial catarrh are reversible. Destruction of the bronchial wall (purulent catarrh, destructive bronchitis and bronchiolitis) contribute to the development of pneumonia. With constant and long exposure to a pathogenic factor, bronchitis takes on chronic features.

Acute pneumonia is a group of inflammatory diseases, diverse in etiology, pathogenesis and clinical and morphological manifestations, which are characterized mainly by damage to the respiratory departments of the lungs.

The etiology of acute pneumonia is diverse, but most often their cause is infectious agents. Among the risk factors of acute pneumonia, in addition to infection (especially viral) of the upper respiratory tract, obstruction of the bronchial tree, immunodeficiency, alcohol, smoking, inhalation of toxic substances, trauma, impaired pulmonary hemodynamics, postoperative period, massive infusion therapy, advanced age, malignant tumors and stress (emotional overstrain, hypothermia, etc.).

Guided by nosological characteristics and pathogenesis, primary and secondary acute pneumonias are distinguished. Primary acute pneumonia includes pneumonia as an independent disease and as a manifestation of another disease with nosological specificity (influenza, plague pneumonia). Secondary acute pneumonia is most often a complication of many diseases.

Features of the clinical and morphological manifestations of acute pneumonia relate to the primary localization of inflammation in the lungs (parenchymal, interstitial and bronchopneumonia), the spread of inflammation (miliary pneumonia or alveolitis, acinous, lobular, lobular draining, segmental,

polysegmental and partial pneumonia of the nature of the inflammatory process (serous, serous desquamative, serous-hemorrhagic, purulent, fibrinous, hemorrhagic).

Croup pneumonia, bronchopneumonia and interstitial pneumonia have the greatest practical importance.

*Croupous pneumonia*— an acute infectious-allergic disease in which the inflammatory process develops in one or more lobes of the lung (partial, lobar pneumonia). During microscopic examination, fibrinous exudate is found in the alveoli and bronchioles (fibrinous or croupous pneumonia); fibrinous film on the pleura (pleuropneumonia). All the listed names of the disease are synonyms and reflect one of the features of the disease. Croupous pneumonia is an independent disease; mostly adults, occasionally older children are affected.

The causative agent of the disease is pneumococci of types I, II, III and IV, in rare cases - Friedlander's diplobacillus. The acute onset of the disease in the midst of complete health and in the absence of contact with patients, as well as the carrying of pneumococci by healthy people, allow us to associate the development of croupous pneumonia with autoinfection. At the same time, the sensitization of the body by pneumococci, the effect of cooling, injuries, etc., are of great importance in the pathogenesis of croup pneumonia. The clinical picture of croupous pneumonia, the stages of its course and the peculiarities of morphological manifestations indicate a hyperergic reaction that takes place in the lungs and acquires the character of hypersensitivity of the immediate type.

Croupous pneumonia, which should be classified as parenchymal, develops in four stages; influx, red hepatization (hepatitis), gray hepatization, resolution; all these stages without treatment of the patient take 9–11 days.

The influx stage lasts one day and is characterized by sharp hyperemia and microbial swelling of the affected part; a large number of pathogens are found in the edematous fluid. At the same time, capillary permeability increases, which leads to the diapedesis of erythrocytes and leukocytes into the alveoli; at the same time, the lungs are enlarged in mass, sharply full of blood.

The stage of red hepatization appears on the 2nd day of the disease. Against the background of full blood and microbial edema, the diapedesis of

erythrocytes increases, which accumulate in large quantities in the alveoli; neutrophils join them; fibrin threads appear between the cells. There is a significant amount of pneumococci in the exudate, and their phagocytosis by neutrophils is revealed. Lymphatic vessels, which are located in the interstitial tissue of the lungs, are expanded, overflowing with lymph. The lung tissue becomes dark red, acquires the density of the liver (red hepatization of the lung). Regional lymph nodes in relation to the affected part of the lung are enlarged, full of blood.

The stage of gray hepatization occurs on the 4th-6th day of the disease. Fibrin and neutrophils accumulate in the alveoli, which, together with macrophages, phagocytize dying pneumococci. At the same time, it is possible to observe how fibrin threads penetrate through the interalveolar pores from one alveolus to another. The number of erythrocytes subject to hemolysis decreases, and the intensity of hyperemia also decreases. There is a fibrinolytic effect of neutrophils on fibrin, which is further intensified. The part of the lung in the stage of gray hepatization is enlarged, dense, heavy, significant fibrinous films on the pleura (pleuropneumonia). On autopsy, the lungs are gray in color; a cloudy liquid flows from the granular surface. Lymphatic nodes of the root of the lung are enlarged, white-pink; acute inflammation is found during their histological examination.

The stage of resolution of inflammation occurs on the 9-11th day of the disease. Under the influence of proteolytic enzymes of neutrophils and macrophages, the exudate melts and dissolves. The lung is cleaned of fibrin and pneumococci: the exudate is eliminated by the lymphatic drainage of the lung, as well as with sputum; the fibrinous film from the pleura dissolves. The stage of resolution of the disease sometimes stretches for several days after the clinically harmless course of the disease.

Sometimes the classic pattern of the course of croupous pneumonia is violated (V.D. Tsinzerling, 1939; Leschke, 1931) - gray hepatization begins before red. In some cases, the center of pneumonia occupies the central part of the lobe of the lung (central pneumonia), in addition, the center of pneumonia can appear in one or the other lobe (migratory pneumonia).

Dystrophic changes in parenchymal organs, pleurisy, hyperplasia of the spleen and bone marrow, pleurisy, and cerebral edema are among the common changes that occur with croupous pneumonia. Sharp hyperemia, leukocyte infiltration around vessels and dystrophic changes of ganglion cells are observed in the cervical sympathetic ganglia (O.I. Abrikosov, 1922).

Complications of croup pneumonia are divided into pulmonary and extrapulmonary.

Pulmonary complications arise in connection with violations of the fibrinolytic function of neutrophils. When this function is insufficient, fibrin masses in the alveoli undergo organization, that is, they grow into granulation tissue, which eventually turns into mature connective tissue; this process of organization of exudate is called carnification (from the Latin *sarno* – meat). At the same time, the lung turns into an airless dense fleshy tissue. With excessive activity of neutrophils, the development of lung abscess or gangrene is possible. Addition of purulent inflammation of the lung to fibrinous pleurisy leads to empyema of the pleura.

Extrapulmonary complications are observed with generalization of the infection. With lymphogenic generalization, purulent mediastinitis and pericarditis occur, with hematogenous – peritonitis, metastatic abscesses in the brain, purulent meningitis, acute ulcerative or polyposis-ulcerative endocarditis, more often of the right heart; purulent arthritis, etc.

Pleuropneumonia, the causative agent of which is Friedlander's bacillus ("Friedlander's pneumonia") has some features. The inflammatory process occurs in a part of the lobe of the lung, more often the upper one; exudate consists of destroyed neutrophils with fibrin threads, as well as mucus and has the appearance of a viscous mucous mass; often, necrosis centers appear in areas of inflammation; abscesses form in their place.

Modern methods of treating patients with croup pneumonia have dramatically changed the clinical and morphological picture of the disease, which allows us to talk about induced pathomorphosis. Under the influence of antibiotics and chemopreparations, croup pneumonia acquires an abortive course, the number of cases of both pulmonary and extrapulmonary

complications decreases.

Death with croupy pneumonia occurs from cardiac decompensation (especially often in old age, as well as in chronic alcoholism) or from complications (brain abscess, meningitis, etc.).

*Bronchopneumonia* called inflammation of the lungs, which occurs in connection with bronchitis or bronchiolitis (bronchoalveolitis). Its prevalence is focal and can be a morphological manifestation of both primary (respiratory viral infections) and secondary (as a complication of many diseases) acute pneumonias.

The etiology is different; causative agents of the disease can be microbial agents - pneumococci, staphylococci, streptococci, enterobacteria, viruses, mycoplasma, pathogenic fungi, etc. Depending on the causative agent, bronchopneumonia acquires both clinical and morphological features. In addition to biological pathogens, bronchopneumonia develops under the influence of chemical and physical factors, which makes it possible to distinguish uremic, lipid, dust, and radiation pneumonia.

Bronchopneumonia is a continuation of acute bronchitis or bronchiolitis, and the inflammatory process spreads to the lung tissue intrabronchially (descending way, most often with catarrhal bronchitis or bronchiolitis); occasionally peribronchially (with destructive bronchitis, bronchiolitis). Bronchopneumonia can be the result of hematogenous spread of pathogens from any septic center (septic pneumonia). In the development of bronchopneumonia, autoinfection with aspiration (aspiration pneumonia), congestion in the lungs (hypostatic pneumonia), aspiration with neuroreflex disorders (postoperative pneumonia) plays a significant role. A special group consists of bronchopneumonia in immunodeficiency states (immunodeficiency pneumonia).

Regardless of the causes of bronchopneumonia, morphological changes have many common features. At the heart of bronchopneumonia of any etiology is acute bronchitis or bronchiolitis in the form of various forms of catarrhal inflammation (serous, mucous, purulent, mixed). At the same time, the mucous membrane becomes full-blooded and swollen, mucus production by glands and goblet cells increases sharply; the covering prismatic epithelium of the mucous

membrane peels off, which leads to damage to the mucocellular mechanism of cleaning the bronchial tree. The wall of the bronchi and bronchioles thickens due to edema and cellular infiltration.

Panbronchitis and panbronchiolitis often occur in the distal bronchi, and endomesobronchitis in the proximal bronchi. Edema and cellular infiltration of the bronchial wall disrupt the drainage function of the bronchi, which causes the aspiration of infected mucus into the distal parts of the bronchial tree; temporary bronchiectasis may occur during coughing fits - transient bronchiectasis.

Foci of inflammation in bronchopneumonia occur mostly in the posterior and posterior lower segments of the lungs - II, VI, VIII, IX, X. They are of different sizes, dense; on autopsy gray-red color. Depending on the size of the inflammatory foci, miliary (alveolitis), acinous, lobular, segmental, and polysegmental bronchopneumonia are distinguished. In the alveoli and bronchioles there is an exudate, in which there is an admixture of mucus, many neutrophils, macrophages, less erythrocytes and exfoliated alveolar epithelium, sometimes fibrin is mixed with the exudate. Exudate is unevenly distributed: in some alveoli it is abundant, in others it is scarce. Inter-alveolar partitions are diffusely permeated with cellular infiltrate.

In different age periods, bronchopneumonia has some features. With pneumonia in newborns, the so-called hyaline membranes, which consist of compacted fibrin, are quite often formed on the surface of the alveoli. In weak children at the age of 1-2 years, the foci of inflammation occur mainly in the posterior, adjacent to the spine and not fully expanded after birth parts of the lungs (II, VI, X segments); such pneumonia is called paravertebral. Due to the sufficient contractility of the lungs and the drainage function of the bronchi, as well as the well-developed lymphatic system, pneumonia centers in children are relatively easily absorbed. Conversely, in people who are over 50 years old, due to the age-related reduction of the lymphatic system, the resorption of the foci of inflammation occurs very slowly.

Bronchopneumonia has some morphological features depending on the type of infectious agent that causes inflammation. The most important clinical



significance is staphylococcal, streptococcal, pneumococcal, viral and fungal focal pneumonia. *Staphylococcus aureus* is the causative agent of staphylococcal bronchopneumonia; it is often found after a viral infection, it is severe, quite often with complications. The inflammatory process is most often localized in the IX and X segments of the lung, where abscesses and necrosis occur. After the discharge of pus through the bronchi, small and larger cavities appear. Serous-hemorrhagic inflammation occurs around the centers of necrosis.

Streptococcal bronchopneumonia - the causative agent of the disease is hemolytic streptococcus, often in combination with a virus; the course is sharp. The lungs are enlarged, bloody liquid flows from the surface of the dissection. Leukocyte infiltration prevails in the bronchi of various calibers, necrosis of the bronchial wall is possible, as well as the formation of abscesses and bronchiectasis. Pneumococcal bronchopneumonia is characterized by the appearance of cells closely related to bronchioles; in exudate - neutrophils, fibrin. On the periphery of the foci of pneumonia, there is a zone of edema, in which there are many microbes. Fungal bronchopneumonia (pneumomycosis) - it can be caused by various types of fungi, but most often the whole type of *Candida*. Pneumonia cells of various sizes (lobular, confluent, segmental), dense; on autopsy gray-pink color. In the center of the pneumonic nodules, decay is found, in which there are many threads of the mycelium of the fungus.

Viral bronchopneumonia is caused by both RNA and DNA viruses that penetrate the epithelium of the respiratory tract. The RNA virus forms colonies in the cytoplasm of cells in the form of basophil inclusions, the cells exfoliate and proliferate, forming cell clusters and giant cells. DNA-containing viruses penetrate into the nuclei, the cells exfoliate, but do not regenerate. Finding exfoliated cells with intracellular inclusions in smears taken from the mucous membrane is of important diagnostic value. Viral bronchopneumonia rarely occurs as an independent disease, because in them the epithelial barrier is broken and a secondary bacterial infection joins. These types of bronchopneumonia occur with viral respiratory infections (influenza, parainfluenza, respiratory syncytial and adenovirus infections), cytomegaly, chickenpox, measles.

Complications of bronchopneumonia largely depend on their etiology, age and general condition of the patient. Pneumonia foci can undergo carnification or an abscess is formed; if the focus of inflammation occurs under the pleura, pleurisy is possible. The death of patients is due to the formation of an abscess or purulent pleurisy. Bronchopneumonia is especially dangerous when it occurs in early childhood or old age.

*Interstitial (intermediate) pneumonia* characterized by the development of an inflammatory process in the interstitial tissue (stroma) of the lung. On the one hand, it can be a characteristic sign of a number of diseases (acute respiratory viral infections), on the other - a complication of inflammatory processes in the lungs.

The causative agents of intermediate (interstitial) pneumonia can be viruses, pyogenic bacteria and pathogenic fungi.

Depending on the localization of the inflammatory process in the interstitial tissue of the lungs, three forms of this pneumonia are distinguished: peribronchial, interlobular and interalveolar. Each of them can be acute or chronic. Morphological changes for each of them are quite characteristic. Peribronchial pneumonia occurs as a manifestation of respiratory viral infections or as a complication of tuberculosis. The inflammatory process that begins in the wall of the bronchus (panbronchitis), passes to the peribronchial tissue and spreads to the adjacent interalveolar partitions; inflammatory infiltration leads to their thickening. Exudate with a large number of alveolar macrophages, individual neutrophils, and sometimes fibrin threads accumulates in the alveoli.

Interlobular pneumonia occurs when the inflammatory process caused by streptococci or staphylococcus spreads to the interlobular septa - from the lung tissue, visceral pleura (with purulent pleurisy), or mediastinal pleura (purulent mediastinitis). Sometimes the inflammation acquires a phlegmonous character and is accompanied by the melting of the interlobular septa, the delamination of the lung into lobules appears - delaminating, or sequestering, intermediate (interstitial) pneumonia. Interlobular pneumonia, which occurs with purulent pleurisy or purulent mediastinitis, is called pleurogenic; its course is chronic.

The inflammatory process spreads to the interalveolar septa, peribronchial and perivascular connective tissue, captures the interlobar pleura, and also spreads to the tissue of the mediastinum. The consequence of such inflammation is chronic interlobitis and mediastinitis, which leads to fibrosis and thickening of the affected tissues. In the chronic course of interlobular pneumonia, coarse-fibrous connective tissue appears at the site of destroyed interlobular septa, which leads to perilobular fibrosis, compression of lobes, development of atelectasis, and further to pneumofibrosis and pneumocirrhosis.

Interlobular interstitial pneumonia often occurs around acute and chronic lung abscesses. In such cases, it develops along the lymphatic vessels of the interlobular septa, which drain infected lymph from abscesses. Lymphangitis and lymphostasis end with interlobular fibrosis.

Interalveolar (interstitial) pneumonia occupies a special place among interstitial pneumonias due to its etiology, pathogenesis, and morphological changes. It can join any acute pneumonia, in such cases it acquires an acute course and a temporary character. With a chronic course, interalveolar (interstitial) pneumonia can be the morphological basis of a group of diseases called interstitial lung diseases.

Acute destructive processes in the lungs include lung abscess and gangrene.

*Abscesslungs* can be of both pneumoniogenic and bronchogenic origin. Pneumonogenic lung abscess occurs as a complication of pneumonia of any etiology, but more often staphylococcal and streptococcal. The suppuration of a pneumonia cell is preceded by necrosis of the inflammatory tissue of the lung, which is followed by purulent melting of the cell. The melted purulent-necrotic mass is released through the bronchi with sputum; an abscess cavity is formed. There is a large number of purulent microbes in the pus and in the inflamed lung tissue. Acute abscess is localized more often in II, VI, VIII, IX and X segments, where the centers of acute bronchopneumonia are mostly located. In most cases, the abscess connects with the lumen of the bronchus (drainage bronchi), through which pus with sputum is released. Bronchogenic lung abscess with appears when the wall of bronchiectasis is destroyed and the

inflammation spreads to the nearby lung tissue with the subsequent development of necrosis, suppuration and the formation of a cavity - an abscess. The wall of the abscess is formed by both bronchiectasis and compacted lung tissue. Bronchogenic abscesses are usually multiple. An acute lung abscess sometimes heals spontaneously, but more often takes a chronic course.

*Lung gangrene*- the most severe type of acute destructive lung processes. More often, it is a severe complication of pneumonia and lung abscess of any genesis with the addition of putrefactive microorganisms. Pulmonary tissue is subject to wet necrosis, becomes gray-dirty with an unpleasant smell. Gangrene of the lungs leads to the death of the patient.

Chronic non-specific lung diseases (CKD) include: chronic bronchitis, bronchiectasis, pulmonary emphysema, bronchial asthma, chronic abscess, chronic pneumonia, interstitial lung diseases, pneumofibrosis (pneumocirrhosis).

Bronchitogenic, pneumonogenic and pneumonitogenic are distinguished among the mechanisms of development of these diseases. At the core of the bronchitogenic mechanism of chronic obstructive pulmonary disease is a violation of the drainage function of the bronchi and bronchial patency.

Diseases that are united by this mechanism, or chronic obstructive lung diseases, are represented by chronic bronchitis, bronchiectasis (bronchiectatic disease), bronchial asthma and emphysema of the lungs (especially chronic diffuse obstructive). The pneumonogenic mechanism of chronic obstructive pulmonary disease is associated with acute pneumonia and its complications. It leads to the development of a group of chronic non-obstructive lung diseases, which includes chronic abscess and chronic pneumonia. The pneumonitogenic mechanism of CKD determines the development of chronic interstitial lung diseases manifested by fibrinous (fibrous) alveolitis or pneumonitis. Further, all three mechanisms of chronic obstructive pulmonary disease end with the development of pneumosclerosis (pneumocirrhosis), secondary pulmonary hypertension, right ventricular hypertrophy, and pulmonary heart failure.

*Chronic bronchitis*- inflammation of the bronchi, which occurs as a result of prolonged acute bronchitis (after typhus or flu) or prolonged exposure to the

mucous membrane of the bronchi by biological, physical and chemical factors (microbes, viruses, cooling of the respiratory tract, smoking, dusting).

Chronic bronchitis of infectious origin, at first the disease is local; occurs more often in bronchial tubes of VI, VIII, IX and X segments, that is, where there are foci of pneumonia and unfavorable conditions for resorption of exudate are created. Such forms of chronic bronchitis become the source of the development of chronic diffuse bronchitis, in which the inflammatory process covers the entire bronchial tree. At the same time, the wall of the bronchi thickens, is surrounded by layers of connective tissue, sometimes deformation of the bronchi can occur. During the long course of bronchitis, saccular or cylindrical bronchiectasis may develop.

When microscopically examined in the wall of the bronchi in some cases, the phenomena of chronic mucous or purulent catarrh with progressive atrophy of the mucous membrane, cystic transformation of the glands, metaplasia of the prismatic epithelium into multilayered flat, and an increase in the number of goblet cells prevail; in others - in the wall of the bronchus and especially in the mucous membrane, there is a pronounced inflammatory cellular infiltration and growth of granulation tissue, which protrudes into the lumen of the bronchus in the form of a polyp - polyposis chronic bronchitis. During maturation of granulation and growth of connective tissue in the wall of the bronchus, the muscular membrane atrophies and the bronchus is deformed (deforming chronic bronchitis).

With chronic bronchitis, the drainage function of the bronchi is disturbed, which leads to the retention of sputum in the distal parts, the closure of the lumen of the small bronchi and bronchioles and the development of bronchopulmonary complications, such as atelectasis (active collapse of the respiratory department of the lungs due to obturation or compression of the bronchi), obstructive emphysema, chronic pneumonia, pneumofibrosis

*Bronchiectasis*- expansion of the bronchi in the form of a cylinder or bag, which can be congenital or acquired. Congenital bronchiectasis are relatively rare (2–3% of the total number of bronchiectasis) and arise in connection with a violation of the formation of the bronchial tree. Sometimes cysts are formed

(the so-called cystic lung) if small bronchi end blindly in the lung parenchyma. A histological feature of congenital bronchiectasis is the chaotic arrangement of structural elements of the bronchus in their wall. Congenital bronchiectasis are usually detected by suppuration of their contents. Acquired bronchiectasis is a consequence of chronic bronchitis. They quite often appear in foci of pneumonia that have not resolved, in the areas of atelectasis (active collapse of the respiratory department of the lungs due to obturation or compression of the bronchi) and collapse (collapse of the respiratory structures of the lung due to mechanical compression from the pleural cavity). The intrabronchial pressure, which increases during coughing, affects the wall of the bronchus, which has changed during chronic inflammation, causes it to explode in the direction of the least resistance, the lumen of the bronchus expands and forms saccular bronchiectasis. Cylindrical bronchiectasis are formed with diffuse expansion of the bronchus. Bronchioles enlarged due to inflammation are defined as bronchiolectasis. Such bronchiolectases are often multiple, and the surface of the lung dissection has a fine-porous appearance. Such a lung is called a honeycomb because it resembles bee honeycombs. which rises during coughing, affects the wall of the bronchus, which has changed during chronic inflammation, causes it to explode in the direction of the least resistance, the lumen of the bronchus expands and forms saccular bronchiectasis. Cylindrical bronchiectasis are formed with diffuse expansion of the bronchus. Bronchioles enlarged due to inflammation are defined as bronchiolectasis. Such bronchiolectases are often multiple, and the surface of the lung dissection has a fine-porous appearance. Such a lung is called a honeycomb because it resembles bee honeycombs. which rises during coughing, affects the wall of the bronchus, which has changed during chronic inflammation, causes it to explode in the direction of the least resistance, the lumen of the bronchus expands and forms saccular bronchiectasis. Cylindrical bronchiectasis are formed with diffuse expansion of the bronchus. Bronchioles enlarged due to inflammation are defined as bronchiolectasis. Such bronchiolectases are often multiple, and the surface of the lung dissection has a fine-porous appearance. Such a lung is called a honeycomb because it resembles bee honeycombs. Such

bronchioloectases are often multiple, and the surface of the lung dissection has a fine-porous appearance. Such a lung is called a honeycomb because it resembles bee honeycombs. Such bronchioloectases are often multiple, and the surface of the lung dissection has a fine-porous appearance. Such a lung is called a honeycomb because it resembles bee honeycombs.

The wall of the bronchiectasis cavity is covered with prismatic epithelium, sometimes flat multi-layered, which appears as a result of metaplasia. Chronic inflammation is observed in the bronchiectasis wall; elastic and muscle fibers are destroyed for a considerable distance and replaced by connective tissue. The content of the bronchiectasis cavity is purulent; lung tissue adjacent to bronchiectasis changes dramatically; foci of inflammation (abscesses, areas of exudate organization), fields of fibrosis appear in it. Sclerosis develops in the vessels, which leads to hypertension in the small circle of blood circulation and hypertrophy of the right ventricle of the heart ("pulmonary" heart). In this connection, hypoxia appears in patients with the subsequent violation of tissue trophism. Its characteristic feature is the thickening of the tissues of the nail phalanges of the fingers and toes: the fingers take on the appearance of drumsticks. With prolonged existence of bronchiectasis, general amyloidosis may develop. The entire complex of pulmonary and extrapulmonary changes in the presence of bronchiectasis is called bronchiectatic disease.

*Lung emphysema*(from the Greek. Emphysao - I inflate) is a disease characterized by an excessive amount of air in the lungs and an increase in their size. The following types of emphysema are distinguished: chronic diffuse obstructive; chronic focal (perifocal, cicatricial); vicar (compensatory); primary (idiopathic) panacea; senile (emphysema in the elderly); intermediate (interstitial).

Chronic diffuse obstructive emphysema is the most common of all the above-mentioned forms.

The development of this type of emphysema is closely related to chronic bronchitis and bronchiolitis and their consequences - multiple bronchiectasis and pneumosclerosis. In emphysema, the elastic and collagen framework of the

lung is affected due to the activation of leukocyte proteases, elastase and collagenase. These enzymes lead to insufficiency of elastic and collagen fibers, because in emphysema there is a genetically determined deficiency of serum antiproteases. In conditions of failure of the stroma of the lung (especially elastic), the so-called valvular (valve) mechanism is activated. Its essence is that the mucous plug that forms in the small bronchi and bronchioles during chronic diffuse bronchitis allows air to pass into the alveoli during inhalation, but does not allow it to exit to him when exhaling. Air accumulates in the acini, expands their cavities,

The lungs are enlarged, cover the anterior mediastinum with their edges, are pale, soft, do not collapse, cut with a crunch. Mucous-purulent exudate is released from the bronchi, the wall of which is thickened. The mucous membrane is full-blooded, diffusely infiltrated with leukocytes, with a large number of goblet cells; uneven hypertrophy of the muscle layer is noted, especially in the small bronchi. If changes in bronchioles prevail, then the proximal parts of the acinus expand (respiratory bronchioles of the 1st and 2nd orders); this type of emphysema is called centroacinar. In the presence of inflammatory changes mainly in larger bronchi (intraalveolar), the entire acinus undergoes expansion; in such cases, we are talking about panacinar emphysema.

Stretching of the walls of the acinus leads to stretching, thinning of elastic fibers, expansion of alveolar passages, changes in alveolar partitions. The walls of the alveoli become thinner and straighten, the interalveolar pores expand, the capillaries become empty. Respiratory bronchioles, through which air enters the lungs, expand, alveolar sacs shrink.

As a result, there is a sharp decrease in the area of gas exchange, the ventilation function of the lungs is disturbed. The capillary network in the respiratory part of the acini is reduced, which leads to the formation of an alveolar-capillary block. Collagen fibers appear in the wall of interalveolar capillaries; intracapillary sclerosis develops. At the same time, the formation of new, not quite typically built capillaries is observed, which has an adaptive value. Thus, with chronic obstructive emphysema, hypertension of the small blood circulation occurs in the lungs, which leads to hypertrophy of the right



heart ("pulmonary" heart). Pulmonary failure is joined by heart failure, which becomes the main one at a certain stage of the disease.

Chronic focal emphysema occurs mostly around old tuberculosis foci, post-infarction scars, more often in I-II segments; therefore, this emphysema is called perifocal or cicatricial. Chronic focal emphysema is, of course, panacinar: in expanded acini, there is complete smoothing of the walls, smooth-walled cavities are formed, which can sometimes be mistaken for tuberculous caverns (in X-ray examination). The presence of several cavities (blisters) is called bullous emphysema. Bubbles located under the pleura can break into the pleural cavity, then a spontaneous pneumothorax occurs.

Reduction of the capillary bed occurs in a limited area of the lung, therefore, in perifocal emphysema, hypertension is not observed in the small circle of blood circulation.

Vicarious (compensatory) emphysema of one lung is observed after removal of part of it or the second lung. This type of emphysema is accompanied by hypertrophy and hyperplasia of the structural elements of the remaining lung tissue.

Primary (idiopathic) panacinar emphysema is very rare; its etiology is unknown. Morphologically, it is manifested by atrophy of the interalveolar septum, reduction of the capillary wall and hypertension in the small circle of blood circulation.

Senile emphysema is considered obstructive, but it occurs in connection with age-related involution of the lungs; therefore, it is called emphysema in the elderly.

Intermediate (interstitial) emphysema is fundamentally different from all types of emphysema. It is characterized by the entry of air into the interstitial tissue of the lung due to ruptures of the alveoli in patients with increased cough. Air bubbles spread in the mediastinum and subcutaneous tissue of the neck and face (subcutaneous emphysema). When pressing on the air-inflated skin area, a characteristic crunch (crepitation) is heard.

Bronchial asthma (from the Greek Asthma - suffocation) is a disease in which attacks of expiratory shortness of breath are observed, which are caused

by an allergic reaction in the bronchial tree with impaired bronchial patency.

The cause of bronchial asthma is considered to be exogenous allergens with a significant role of heredity. Repeated attacks of bronchial asthma occur with infectious diseases, especially of the upper respiratory tract, allergic rhinosinusopathy, the effects of the external environment, as well as substances present in the air (room and industrial dust, smoke, various odorous substances), meteorological effects (high humidity of the atmospheric air, fogs), psychogenic (psychogenic stimuli) factors, consumption of certain food products and medicines. Depending on the predominance of one or another factor that causes the disease, infectious, allergic, occupational, psychogenic bronchial asthma are distinguished; sometimes it can be due to the influence of environmental factors. However, among the many forms of bronchial asthma, the most practical are: atopic (from lat. athopia - hereditary predisposition) and infectious-allergic. Atopic bronchial asthma occurs as a result of exposure to allergens of various origins on the body through the respiratory tract.

Infectious-allergic bronchial asthma is observed under the influence of allergens in patients with acute or chronic bronchopulmonary diseases caused by infectious agents.

The pathogenesis of these forms of bronchial asthma is almost the same. Allergic reactions in bronchial asthma are associated with cellular antibodies - reagins (IgE). An attack of bronchial asthma develops when the allergen binds to antibodies fixed on cells (leucocytes, basophils). The formed antigen-antibody complex leads to the release of biologically active substances (histamine, serotonin, kinins, slow-reacting substance of anaphylaxis) from the effector cells, which cause a vascular-exudative reaction in the bronchi, muscle spasm, increased secretion of mucus by the mucous membrane of the bronchi, which ends in impaired patency bronchi

Changes in the bronchi and lungs in bronchial asthma can be acute, occurring during an attack, and chronic, as a result of repeated attacks and a long course of the disease.

In the acute period (during an attack) of bronchial asthma in the wall of the bronchi there is a sharp expansion of the microcirculatory vessels and an

increase in their permeability. Swelling of the mucous and submucosal membranes occurs; their infiltration by labrocytes, basophils, eosinophils, lymphocytes and plasma cells. The basal membrane is swollen, thickened; hypersecretion of mucus by goblet cells and mucous glands is noted. In the bronchi of all calibers, mucous secretion with an admixture of eosinophils and desquamated epithelial cells accumulates with obturation of the lumen of the bronchi. An immunohistochemical study reveals IgE fluorescence on the surface of cells infiltrating the mucous membrane of the bronchi, as well as on the basal membrane of the mucous membrane. The consequence of allergic inflammation is the occurrence of functional and mechanical obstruction of the respiratory tract with violation of the drainage function of the bronchi and their patency. Acute obstructive emphysema develops in the lung tissue, foci of atelectasis appear, respiratory failure occurs, which can lead the patient to death during a bronchial asthma attack.

With repeated attacks of bronchial asthma, diffuse chronic inflammation, thickening and hyalinosis of the basement membrane, sclerosis of the interalveolar septa, and chronic obstructive pulmonary emphysema develop in the bronchial wall over a period of time. Desolation of the capillary bed occurs, secondary hypertension develops in the small blood circulation, followed by hypertrophy of the right heart with the development of cardiopulmonary failure at the end.

Chronic lung abscess usually develops from acute, is localized more often in II, VI, IX and X segments of the right lung, less often in the left lung, that is, in those parts of the lungs where foci of acute bronchopneumonia and acute abscesses occur. The wall of a chronic lung abscess has the same structure as an abscess of another location (see the Inflammation section). Lymphatic drainage of the lung is involved early in the pathological process. During the outflow of lymph from the wall of a chronic abscess to the root of the lung, whitish layers of connective tissue appear, which leads to fibrosis and deformation of the lung, a chronic abscess can be a source of bronchogenic spread of purulent inflammation in the lungs.

Chronic pneumonia is characterized by a combination of many

pathological processes in the lungs, but the main type of pathology remains the inflammatory process in the respiratory departments of the lungs. Clinical and morphological manifestations of the disease are diverse.

In chronic pneumonia, areas of carnification and fibrosis connect with cavities of chronic pneumonogenic abscesses. Chronic inflammation and fibrosis occurs along the lymphatic vessels in the interlobular septa, in the perivascular and peribronchial tissue, which leads to emphysema, which is supported by chronic bronchitis (panbronchitis, deforming peribronchitis). Inflammatory and sclerotic changes appear in the walls of small and larger vessels, which end with the obliteration of the lumen. Chronic pneumonia quite often occurs on the territory of a segment or lobe in connection with bronchogenic spread; one or both lungs are involved in the process.

One of the features of chronic pneumonia is an unusual ability to exacerbations, which depends on the weakening of the drainage function of the bronchi and insufficiency of lymphatic vessels, the presence of bronchiectasis and suppuration. Each aggravation is accompanied by the appearance of fresh foci of inflammation, an increase in the size of the lesions, an increase in sclerotic changes, which leads to pneumofibrosis with deformation of the lung tissue, obstructive emphysema, a reduction of the capillary bed not only in the lesion, but also far beyond it.

Interstitial lung diseases. Among these diseases, fibrosing (fibrous) alveolitis is important - it is a heterogeneous group of lung diseases characterized by a primary inflammatory process in the interalveolar connective tissue (pneumonitis) with the development of bilateral diffuse pneumofibrosis.

There are three nosological forms of fibrosing alveolitis: 1) idiopathic fibrosing alveolitis, acute forms of which are called Hammen-Rich disease; 2) exogenous allergic alveolitis; 3) toxic fibrosing alveolitis. Fibrosing alveolitis, which can be a manifestation of other diseases, first of all, systemic diseases of connective tissue (rheumatic diseases) and viral chronic active hepatitis, is called Hammen-Rich syndrome.

Idiopathic fibrosing alveolitis accounts for 40–60% of all diffuse pulmonary fibrosis. Chronic forms of the disease predominate, Hammen-Rich

disease is less common. Exogenous allergic alveolitis is widespread among people who work in agriculture ("farmer's lung"), poultry ("poultryman's lung") and animal husbandry, as well as textile and pharmaceutical industries. Toxic fibrosing alveolitis occurs more often in people who are in contact with herbicides, mineral fertilizers, as well as in patients who are being treated in oncological and hematological hospitals.

The cause of idiopathic fibrosing alveolitis has not yet been established, but the viral nature of the disease is assumed. Among the etiological factors of exogenous allergic alveolitis, bacteria and fungi, dust containing antigens of animal and plant origin are of great importance; medicinal preparations. The development of toxic fibrosing alveolitis is mainly associated with the influence of drugs that have a toxic pneumotropic effect (alkylating, cytostatic and immunosuppressive drugs, antitumor antibiotics, as well as antidiabetic drugs).

Immunopathological processes are of primary importance in the pathogenesis of fibrosing alveolitis. They are characterized by immune-complex damage to the capillaries of the interalveolar septa and lung stroma, which is accompanied by cellular immune cytolysis (see Immunopathological processes). In case of idiopathic fibrosing alveolitis in pulmonary interstitium damage, the significance of autoimmunization and hereditary failure of lung stroma collagen cannot be ruled out. In toxic fibrosing alveolitis, the immunopathological mechanism of damage can be combined with a toxic one (direct effect of a pathogenic factor).

In the study of lung biopsies, three stages of morphological changes of the lungs in fibrosing alveolitis (pneumonitis) were established: 1) alveolitis (diffuse or granulomatous); 2) disorganization of alveolar structures and pneumofibrosis; 3) the formation of a cellular lung.

In the stage of alveolitis, which can exist for a long time, there is an increasing infiltration of the interstitium of alveoli, alveolar ducts, and walls of respiratory and terminal bronchioles by neutrophils, lymphocytes, macrophages, and plasma cells. In such cases, we are talking about diffuse alveoli. Often, the process acquires not a diffuse, but a focal granulomatous character. Macrophage granulomas are formed both in the interstitium and in the vessel wall -

granulomatous alveolitis. Cellular infiltration leads to thickening of the alveolar interstitium, capillary compression and hypoxia.

The stage of disorganization of alveolar structures and pneumofibrosis, as its name suggests, is characterized by deep damage to alveolar structures - destruction of endothelial and epithelial membranes, elastic fibers, as well as increased cellular infiltration of the alveolar interstitium, which spreads beyond its borders and affects vessels and perivascular tissue. In the interstitium of the alveoli, the formation of collagen fibers increases, diffuse pneumosclerosis develops.

In the stage of cellular lung formation, alveolar-capillary block and panacinar emphysema, bronchioloetasis develop, and cysts with fibrous-changed walls appear in the place of alveoli. As a rule, hypertension develops in the small circle of blood circulation. Hypertrophy of the right heart, which appears in the second stage, intensifies, and cardiopulmonary insufficiency develops in the final stage.

Pneumofibrosis is a collective concept that defines the growth of connective tissue in the lungs; it completes various pathological processes in the lungs. It often occurs in areas of carnification of pneumonia, along the course of lymph outflow from the focus of inflammation, around the lymphatic vessels of the interlobular septa, in the peribronchial and perivascular tissue, as a final result of pneumonitis, etc.

With pneumofibrosis in connection with vascular sclerosis, the reduction of the capillary channel causes hypoxia of the lung tissue. It activates the collagen-forming function of fibroblasts, which further contributes to the development of pneumofibrosis and complicates blood circulation in the small circle. Hypertrophy of the right heart (pulmonary heart) develops, which ends in cardiac decompensation.

With the progression of pneumofibrosis, exacerbation of bronchitis, the development of obstructive focal or diffuse emphysema, the lung tissue is slowly rebuilt (change in the structure of the acinus, formation of pseudoglandular structures, sclerosis of the walls of bronchioles and vessels, reduction of capillaries), its deformation with the formation of cyst-like

expansions of alveoli and fibrous areas at the site of the destroyed fabrics. In the presence of fibrosis, emphysema, destruction, repair, reconstruction and deformation of the lungs, they speak of pneumocirrhosis.

Lung cancer in most cases develops from the bronchial epithelium and less often from the alveolar epithelium. Therefore, when they talk about lung cancer, they mean first of all bronchogenic lung cancer; pneumoniogenic cancer accounts for no more than 1% of cases. Since 1981, lung cancer ranks first in the world among malignant tumors, both in terms of morbidity and mortality. Morbidity and mortality are highest in economically developed countries.

Peripheral cancer is found in 50–55% of lung cancer cases; It arises in the mucous membrane of the peripheral part of the segmental bronchus, its smaller branches and bronchioles, rarely - from the alveolar epithelium. Peripheral cancer has been growing expansively for a long time in the form of a node, sometimes reaching significant sizes! (diameter up to 5–7 cm). The tumor does not manifest itself clinically until it is detected during a random examination of the patient, does not reach the pleura (pleurisy) or trunk and segmental bronchi, the compression and germination of which causes a violation of the drainage function of the bronchi and compression or obturation atelectasis. Cancer often occurs in the area of a scar (capsule of healed tuberculosis cells, scarred lung infarction, etc.) near the pleura in any part of the lung; can go to the pleura, as a result, it thickens and serous-hemorrhagic or hemorrhagic exudate accumulates in the pleural cavity, which compresses the lung. Sometimes the earliest manifestation of a small peripheral cancer is numerous hematogenous metastases. In histological examination, peripheral cancer has a glandular structure, less often - squamous or undifferentiated.

Mixed (massive) lung cancer is rare (in 2–5% of cases). It is a soft whitish tissue that often disintegrates, can occupy the entire lobe or even the entire lung. It is often impossible to resolve the question of the origin of this type of tumor. Massive cancer often has the structure of undifferentiated or adenocarcinoma.

The microscopic structure of lung cancer is diverse, which is determined both by different sources of its origin (covering and glandular epithelium of the

bronchi, pneumocytes of the second type, endocrine cells), and by the degree of differentiation of the tumor (differentiated and undifferentiated cancer). Differentiated lung cancer, as a rule, preserves the characteristics of the tissue from which it originates: mucin formation is characteristic of adenocarcinoma, keratin formation is characteristic of squamous cell carcinoma.

Squamous cell (epidermoid) cancer can be highly, moderately and poorly differentiated. Highly differentiated cancer is characterized by the formation of keratin by many cells and the formation of cancerous pearls, moderately differentiated cancer is characterized by mitoses and polymorphism of cells, some of them contain keratin; for low-differentiated squamous cell cancer – an even greater polymorphism of cells and nuclei (presence of polygonal and spindle-shaped cells), a greater number of mitoses; keratin is found only in individual cells.

Lung adenocarcinoma can also have different differentiation. Highly differentiated adenocarcinoma is composed of acinar, tubular or papillary structures, the cells of which produce mucus; moderately differentiated adenocarcinoma has a glandular-solid structure, a large number of mitoses are found in it, mucin formation is noted only in part of the cells; poorly differentiated adenocarcinoma consists of solid structures; tumor cells are able to produce mucus. A type of adenocarcinoma is bronchiolar-alveolar cancer.

Undifferentiated anaplastic lung cancer can be small cell or large cell. Small cell lung cancer consists of small lymphocyte-like or oat-like cells with hyperchromic nuclei; cells are located in the form of layers or cords. In a number of cases, they have endocrine activity - capable of producing ACTH, serotonin, calcitonin and other hormones; upon electron microscopic examination, neurosecretory granules are found in the cytoplasm of such cells. Small cell cancer can be accompanied by arterial hypertension. In such cases, small cell cancer can be attributed to malignant apudoma. Large cell carcinoma is made up of large, polymorphic, sometimes giant, multinucleated cells that are capable of producing mucus.

Glandular-squamous lung cancer is also called mixed, because it is a combination of two forms - adenocarcinoma and squamous cell cancer.



Carcinoma of the bronchial glands, which has an adenoid-cystic or mucoepidermoid structure, is rare.

Complications of lung cancer are represented by metastases, which can be attributed both to secondary lung changes and to manifestations of slow progression. Cancer metastases, both lymphogenic and hematogenous, are observed in 70% of cases. The first lymphogenous metastases appear in peribronchial and bifurcation lymph nodes, then cervical, subclavian, etc. Among hematogenous metastases, metastases in the liver, brain, bones (especially often in the vertebra) and adrenal glands are the most characteristic. Radical cancer more often metastasizes lymphogenically; peripheral - hematogenous. It should be emphasized that in patients with peripheral cancer (insignificant in size, with a course without symptoms), the first clinical signs may be caused not by the tumor itself, but by hematogenous metastases.

Secondary pulmonary changes occur in connection with the development of atelectasis, which is more common in basal lung cancer. Secondary changes should also include those changes that occur in connection with tumor necrosis: the formation of cavities, bleeding, suppuration, etc.

The death of patients occurs from metastases, secondary pulmonary complications, as well as from cachexia.

Pleurisy - inflammation of the pleura - has various etiologies. Most often, it is associated with acute or chronic inflammatory processes in the lungs, lung infarction, necrotized tumor, that is, it is a complication of one or another lung disease. Sometimes pleurisy is allergic (in rheumatism) or toxic (in uremia). Visceral pleura with gray speckled hemorrhages, often with the formation of fibrinous films; these changes are minor on the parietal pleura.

With pleurisy, serous, serous-fibrinous, fibrinous, purulent or hemorrhagic exudate accumulates in the pleural cavity. When a fibrinous film is formed on the pleura, we are talking about dry pleurisy. Accumulation of purulent exudate (in case of abscess pneumonia or attachment of infection to serous exudate) is called pleural empyema. Empyema sometimes takes on a chronic course: the sheets of the pleura thicken, lime accumulates, the pus becomes thick, encapsulated, sometimes fistulas form in the chest wall.

With cancerous (cancerous) damage to the pleura, the exudate becomes hemorrhagic in nature.

When fibrinous exudate accumulates in the pleural cavity, adhesions are formed over time, and the sheets of the pleura thicken. Sometimes obliteration of the pleural cavity develops; accumulations of lime appear in the scarred pleura (especially in case of tuberculous pleurisy). When fibroplastic processes develop in the pleural cavity, the developed fibrous tissue can fill the entire pleural cavity; it compresses the lung and causes its collapse. Such a process in the pleura is defined as a fibrothorax.

**Materials on the activation of students of higher education during the lecture: questions, situational tasks, etc(*if necessary*):**

### **General material and bulk-methodological support of the lecture:**

#### **Questions for self-control:**

1. Classification of diseases of the respiratory organs according to various signs (by the nature of the pathological process, by etiology, by the place of development, by duration, by the type of inflammation)
2. Bronchitis: definition, classification, causes of development, morphological characteristics (acute and chronic), consequences, complications.
3. Pneumonia: definition, etiology, classification.
4. Croupous pneumonia: etiology, pathogenesis, morphological characteristics of each stage, complications.
5. Bronchopneumonia: etiology, pathogenesis, classification, morphological characteristics, complications.
6. Interstitial pneumonia. etiology, pathogenesis, morphological characteristics, complications.
7. Chronic (non-specific) obstructive lung diseases: general characteristics, list of diseases included in this group
- . 8. Chronic obstructive bronchitis. Etiology, morphological characteristics (in the stage of exacerbation and stage of remission). 9. Bronchial asthma. Etiology, classification, morphological characteristics (in the stage of exacerbation and remission, asthmatic status).
10. Emphysema of the lung. Classification, morphological characteristics.
11. Bronchiectasis. Pathogenesis, classification, morphological characteristics,

complications, causes of death.

12. Pneumoconiosis. General concept, morphological characteristics.

### References:

Main:

1. Atlas of micropreparations in pathomorphology / I.I. Starchenko, B.M. Filenko, N.V. Royko, etc.; VDZU "UMSA". - Poltava, 2018. - 190 p
2. Starchenko, S.O. Bilokon and others.. – Poltava: Tov. "ASMI" - 2018. - 190 p.
3. Fundamentals of pathology according to Robbins: in 2 volumes. Volume 1 / Vinay Kumar, Abul K. Abbas, John C. Astaire; translation of the 10th Eng. edition. Publisher: All-Ukrainian specialized publishing house "Medytsyna". – X II. - 2019. - 420 p.
4. Fundamentals of pathology according to Robbins: in 2 volumes. Volume 1 / Vinay Kumar, Abul K. Abbas, John C. Astaire; translation of the 10th Eng. edition. Publisher: All-Ukrainian specialized publishing house "Medytsyna". – X II. - 2019. - 420 p.
5. Pathomorphology. General pathomorphology: a study guide / edited by Ya. Ya. Bodnara, V.D. Voloshina, A.M. Romanyuk, V.V. Gargin. - New Book, 2020. - 248 p.
6. Pathomorphology of the main diseases of the cardiovascular system: study guide / I.I. Starchenko, B.M. Filenko, N.V. Royko – Poltava: "UMSA". - 2019. - 150 p.
7. Starchenko I.I. Pathomorphology of the main diseases of the maxillofacial region: academician. manual / I.I. Starchenko, B.M. Filenko, V.V. Chernyak ; "UMSA". – Vinnytsia: Nova Kniga, 2019. – 128 p.
8. Starchenko I.I. Special pathomorphology (basic course) for students of medical faculties of higher medical educational institutions of III-IV levels of accreditation / I.I. Starchenko, N.V. Royko, B.M. Filenko. – Poltava, 2017. – 174 p.
9. Tuffaha S. A. Muin Immunohistochemistry in the diagnosis of tumors / S. A. Tuffaha Muin, S. G. Hychka, Husky Hans. - "Book Plus", 2018. - 336 p.
10. Essentials of pathology: textbook / Ya. Bodnar, A. Romanyuk, V. Voloshyn, V. Gargin - Kharkiv, "Planeta-Print" Ltd, 2020, 219 p.
11. Pathology: textbook / IVSorokina, VD Markovskiy, DI Halata et al.; edited by IVSorokina, VD Markovskiy, DI Halata. - Kyiv: AUS Medicine Publishing, 2019. - 328p. + 2 color inserts (8p. + 12p.).
12. Pathology: textbook / IVSorokina, VD Markovskiy, DI Halata et al.; edited by IVSorokina, VD Markovskiy, DI Halata. - 2nd edition. - Kyiv: AUS Medicine Publishing, 2020. - 328p. + 2 color inserts (8p. + 12p.).

Additional:

1. Benign neoplasms of bones of the maxillofacial area in children / P.I. Tkachenko, I.I. Starenko, S.O. Bilokin [and others] - P.: "UMSA", 2016. - 85 p
2. General pathomorphology / I.I. Starchenko, N.V. Royko, B.M. Filenko [et al.] – Poltava, 2016. – 136 p.

3. Zerbino D. D. Pathomorphology and histology: atlas / D. D. Zerbino, M. M. Bagriy, Y. Ya. Bodnar, V. A. Dibrova. – Vinnytsia: Nova Kniga, 2016. – 800 p.
4. Methods of morphological research / M.M. Baghrii, V.A. Dibrova, O.G. Papadynets, M.I. Grischuk; edited by M.M. Baghria, V.A. Dibrovyy – Vinnytsia: Nova Kniga, 2016. – 328 p.
5. Novoseltseva T.V. Pathology of sexual and endocrine systems / T.V. Novoseltseva, B.M. Filenko, N.I. Hasiuk - Poltava: LLC "ASMI", 2015. - 199 p.
6. Pathomorphology: national. / V.D. Markovskiy, V.O. Tumanskiy, I.V. Sorokina [and others]; edited by V.D. Markovskiy, V.O. Tumanskiy. - K.: VSV "Medicine", 2015. - 936p.
7. Practicum on biopsy section course / I.I. Starchenko, A.P. Hasyuk, S.A. Proskurnya [etc.] – Poltava, 2016. – 160 p.

## **Lecture No. 10**

**Subject:** Khsparrrows of the esophagus, stomach and intestines. Liver disease.

**Actuality of theme:** Diseases of the esophagus such as achalasia of the cardia, stomach and intestines, gastritis ulcers. Liver disease. Hepatitis, what types, stages of development, irreversible stages.

**Goal:** Get acquainted with diseases of the esophagus, stomach, intestines and liver, many diseases of infectious and non-infectious nature, of acquired or hereditary origin.

**Basic concepts:** Esophageal diverticulum, Esophagitis, gastritis, Acute enteritis, Chronic colitis, ulcerative proctocolitis, Crohn's disease, Appendicitis.

### **Plan and organizational structure of the lecture:**

Greetings, verification of those present, announcement of the topic, purpose of the lesson, motivation of higher education seekers to study the topic.

### **Content of lecture material (lecture text)**

Diseases of the organs of the digestive tract differ in the variety of their clinical and morphological signs. They include primary independent diseases, as well as other, secondary ones, which are a manifestation of many diseases of an infectious and non-infectious nature, of acquired or hereditary origin. The basis of these diseases can be various general pathological processes, such as alteration, inflammation, hyper- and dysplastic processes, autoimmune

disorders and, finally, tumors.

Over the past twenty years, significant progress has been made in understanding the morphological essence of the process of most diseases of the digestive system. These achievements are related to the possibility of obtaining and studying biopsy material of almost all departments of the digestive tract with the help of modern morphological means of research, such as immunohistochemistry, electron microscopy. Obtained data on the early structural manifestations of diseased digestive organs, which allows using the results of morphological diagnostics for effective treatment.

Among diseases of the esophagus, diverticula, inflammation (esophagitis) and tumors (cancer) are more common.

Esophageal diverticulum is a limited blind protrusion of its wall, which consists of all membranes of the esophagus wall (true diverticulum) or only mucosa and submucosa, which protrude through the slits of the muscular membrane (muscular diverticulum). Depending on the localization and topography, pharyngoesophageal, bifurcation, epinephric and multiple diverticula are distinguished, and depending on the features of origin - adhesive diverticula, which arise as a result of inflammatory processes in the mediastinum, and relaxation diverticula, which are based on local relaxation of the esophageal wall. Esophageal diverticulum can be complicated by an inflammatory process (diverticulitis).

The causes of diverticulum formation can be congenital (inferiority of the connective and muscular tissues of the wall of the esophagus, pharynx) and acquired (inflammation, sclerosis, cicatricial narrowing, increased pressure in the esophagus).

Esophagitis – inflammation of the esophagus wall occurs secondary to many diseases; rarely - primary; according to the course, acute and chronic are distinguished.

Acute esophagitis, which occurs under the influence of chemical, thermal and mechanical factors, with a number of infectious diseases (diphtheria, scarlet fever, typhus), allergic reactions, can be catarrhal, fibrinous, phlegmonous, ulcerative, gangrenous. Membranous esophagitis is a special form of acute

esophagitis, when the cast of the esophagus mucosa is rejected. After deep membranous esophagitis, which develops with chemical burns, cicatricial stenoses of the esophagus are formed.

In chronic esophagitis, the development of which is associated with chronic irritation of the esophagus (alcohol exposure, tobacco smoking, etc.) or impaired blood circulation in its wall (venous hyperemia in cardiac decompensation, portal hypertension), the mucous membrane is swollen and full of blood with areas of epithelial destruction, leukoplakia and sclerosis. For specific chronic esophagitis, which occurs with tuberculosis and syphilis, the morphology of the corresponding inflammation is characteristic.

There is a special form of reflux esophagitis, in which inflammation, erosions and ulcers (erosive, ulcerative esophagitis) are found in the mucous membrane of the lower esophagus due to regurgitation of stomach contents into it (regurgitation, peptic esophagitis). Cancer of the esophagus most often occurs at the level of the middle and lower third of it, which corresponds to the level of the bifurcation of the trachea. Much less often, it is found in the initial part of the esophagus and its transition into the stomach.

Esophageal cancer accounts for 2–5% of all malignant tumors. The development of esophageal cancer is facilitated by chronic irritation of its mucous membrane (hot coarse food, alcohol, smoking), cicatricial changes after burns, chronic gastrointestinal infections, anatomical disorders (diverticula, ectopy of the cylindrical epithelium and gastric glands, etc.). Among the precancerous changes, leukoplakia and severe dysplasia of the epithelium of the mucous membrane are the most important.

The following macroscopic forms of esophageal cancer are distinguished: annular dense, papillary and ulcerative. Ring-shaped dense cancer is a tumor formation that circularly thickens the walls of the esophagus in a certain area and narrows its lumen; with disintegration (destruction) and ulceration of the tumor, the passage of the esophagus is restored. Papillary cancer of the esophagus is similar to mushroom-shaped cancer of the stomach. It easily disintegrates, as a result of which ulcers are formed, which penetrate into neighboring organs and tissues. Ulcerative cancer is a cancerous ulcer that has

an oval shape and is elongated along the esophagus.

Among the microscopic forms of esophageal cancer, carcinoma in situ, squamous cell carcinoma, adenocarcinoma, glandular-squamous, glandular-cystic, mucoepidermal and undifferentiated cancer are distinguished.

Metastases of these tumors are mainly lymphogenic.

Complications are associated with tumor growth in neighboring organs - trachea, mediastinum, stomach, pleura. At the same time, esophageal-tracheal fistulas are formed, aspiration pneumonia, lung abscess and gangrene, pleural empyema, purulent mediastinitis occur; cachexia develops early.

Inflammatory diseases of the stomach - gastritis - occupy a considerable place in the clinic of internal diseases. The doctrine of acute gastritis originates from Beaumont's observations of one patient who developed a stomach fistula as a result of a gunshot wound. This patient was an excellent object for lifelong study of the physiology and pathology of the stomach. Through the fistula, it was possible to obtain gastric juice, monitor the digestion process and, finally, see the mucous membrane of the organ. When the patient took poorly chewed food and alcohol or fell ill with dysentery, the mucous membrane of the stomach reddened, swelled, and grayish layers appeared on it.

These observations are the basis of modern ideas about the high sensitivity of the stomach and its tendency to react with acute inflammation to various physiological and pathological stimuli.

This stage and subsequent stages in the development of the problem showed that secretory disorders and inflammation in the stomach are two coordinated processes arising under the influence of the same pathogenic factor.

Moreover, the range of variability of the relief of a normal stomach is very wide, and even more so with neurogenic disorders of secretion, therefore the diagnosis of gastritis by morphological criteria is very difficult. It is especially difficult to distinguish leukocyte infiltration of the gastric mucosa in gastritis from leukocyte infiltration in its normal functional state. Inflammation of the stomach is characterized by the following triad:

- 1) predominance of neutrophilic leukocytes over eosinophils,
- 2) the massiveness of the infiltration with the accumulation of leukocytes

mainly around the blood vessels,

3) destructive-proliferative changes in the covering and glandular epithelium and accumulation of exudate of one or another type (serous, purulent, fibrinous).

The above allows us to conclude that the most reliable method of establishing gastritis is the method of biopsy of the stomach with a thorough histological examination of its wall.

Since the time of Beaumont, it has been accepted that various irritating substances play a role in the development of gastritis: alcohol, spices (pepper, mustard), medications, poorly chewed food, taken in large quantities. These factors exert their harmful influence, apparently, only in conditions of increased reactivity of the stomach, since in some individuals the innervation apparatus of the stomach has an increased sensitivity to the perception of local stimuli.

Microorganisms do not play a major role in the development of gastritis, although hematogenous and lymphogenous entry of bacteria into the stomach wall with the development of inflammation is possible in infectious diseases.

According to the course, gastritis is divided into acute and chronic. By localization - on the fundal, affecting the body of the stomach, pyloroantral - the exit part: intermediate zone, pyloric canal and pylorus; pyloroduodenal area - pyloric part and duodenum. Gastritis is further divided according to the mechanism of occurrence. There are 2 groups: exogenous and endogenous gastritis. Exogenous gastritis includes the following types:

1) Corrosive gastritis. Caused by the action of caustic acids and alkalis;

2) Alimentary or food gastritis - from mistakes in the diet, from eating very hot food or very cold food, from poisoning with stale meat or fish products, from excessively fatty food, alcohol, medicines.

Endogenous gastritis is the most common group. These include the following types:

1) Infectious-toxic gastritis. It is caused by lympho-hematogenous entry of microbial toxins into the stomach. For example, with scarlet fever, flu, measles.

2) Gastritis with disorders of blood supply to the stomach. It is also called



stagnant or hypoxic gastritis. For example, with decompensated heart defects.

3) Gastritis in intoxications as a result of uremia, burns, thyrotoxicosis.

4) Allergic gastritis with serum sickness, intolerance to some food products: eggs, strawberries, and the like.

5) Peptic erosive gastritis caused by the action of gastric juice on areas particularly sensitive to it.

In addition, both acute and chronic gastritis are divided according to the nature of inflammation. Thus, among acute gastritis there are serous ones - the lightest; serous-catarrhal - a large amount of mucus is mixed with the serous exudate; fibrinous, when the mucous membrane is covered with a film of fibrin, and phlegmonous, when one part or the entire wall of the stomach is diffusely infiltrated with leukocytes, a very severe form that can cause perforation and peritonitis. These are forms of acute gastritis. The nature of the inflammation is mainly exudative.

Chronic gastritis in a number of cases is connected with acute gastritis, its recurrences; in others, this connection is absent. Chronic gastritis, as well as acute, develops under the influence of primarily exogenous factors on the gastric mucosa: violation of the diet, alcohol abuse, exposure to chemical, thermal and mechanical agents, occupational hazards, etc. A major role of endogenous factors is autoinfection (*Campylobacter pyloridis*), chronic autointoxication, neuroendocrine disorders, chronic cardiovascular insufficiency, allergic reactions, regurgitation of duodenal contents into the stomach (reflux). An important condition for the development of chronic gastritis can be long-term exposure to pathogenic factors of an exogenous or endogenous nature, capable of "breaking" the usual regenerative mechanisms of constant renewal of the epithelium of the gastric mucosa.

Chronic gastritis can be autoimmune (gastritis type A) and non-immune (gastritis type B).

Gastritis type A (autoimmune gastritis) is characterized by the appearance of antibodies to parietal cells, and therefore damage to the fundal part of the stomach, where there are many lining cells (fundal gastritis); the mucous membrane of the antral department is not damaged; at the same time, a high

level of gastrinemia is noted. Due to the damage of the lining cells, the secretion of hydrochloric (hydrochloric) acid is reduced.

In type B gastritis (non-immune gastritis), antibodies to parietal cells are not found, so the fundal part of the stomach is relatively undamaged. The main changes are in the antral region (antral gastritis). At the same time, there is no gastrinemia; secretion of hydrochloric acid is reduced only moderately. Gastritis type B, in the pathogenesis of which there are no autoimmune processes, occurs 4 times more often than gastritis type A.

Guided by the topography of the process in the stomach, chronic gastritis is distinguished - antral, fundal and pangastitis.

Chronic gastritis is characterized by long-term dystrophic and necrobiotic changes in the epithelium of the mucous membrane, as a result of which there are violations of its regeneration and structural restructuring of the mucous membrane, which ends in its atrophy and sclerosis; cellular reactions of the mucous membrane reflect the activity of the process.

Chronic superficial gastritis is characterized by dystrophic changes in the surface (pit) epithelium. In some areas, it flattens, approaches cubic and is characterized by reduced secretion; in others - high prismatic, with increased secretion. Translocation of additional cells from the isthmus to the middle third of the glands takes place, histamine-stimulated secretion of hydrochloric acid by parietal cells and pepsinogen by chief cells decreases. The own layer (plate) of the mucous membrane is swollen, infiltrated with lymphocytes, plasma cells and neutrophils.

With chronic atrophic gastritis, a new and basic quality appears - atrophy of the mucous membrane and its glands, which determines the development of sclerosis. The mucous membrane becomes thinner, the number of glands decreases. Connective tissue grows in place of atrophied glands. Preserved glands are located in groups, their ducts are expanded, individual types of cells in the glands are poorly differentiated. In connection with the mucoidization of the glands, the secretion of pepsin and hydrochloric acid is disturbed. At the same time, the mucous membrane is infiltrated by lymphocytes, plasma cells, and neutrophils. These changes are accompanied by remodeling of the

epithelium, with both superficial and glandular epithelium undergoing metaplasia. Stomach pits resemble the villi of the intestines, they are lined with bordered epitheliocytes, goblet cells and Paneth cells appear (intestinal metaplasia of the epithelium, "enterolization" of the mucous membrane). The main, additional (mucous cells of the glands) and parietal cells of the glands disappear, cubic cells characteristic of the pyloric glands appear; the so-called pseudopyloric glands are formed. Epithelial metaplasia is joined by its dysplasia, the degree of which can be different. Changes in the mucous membrane can be moderate (moderately atrophic gastritis) or sharply expressed (pronounced atrophic gastritis).

A special form of the disease is giant hypertrophic gastritis or Menetriere's disease, in which there is an extremely sharp thickening of the mucous membrane, it takes on the appearance of cobblestones. Morphological examination reveals proliferation of cells of the glandular epithelium and hyperplasia of the glands, as well as infiltration of the mucous membrane by lymphocytes, epithelioid, plasma and giant cells. Depending on the preference of changes in the glands or interstitium, as well as proliferative changes, glandular, interstitial and proliferative variants of this disease are distinguished.

Signs of chronic gastritis activity allow distinguishing between active (exacerbation) and inactive (remission) chronic gastritis. Exacerbation of chronic gastritis is characterized by swelling of the stroma, blood vessels, sharp cellular infiltration with the presence of a large number of neutrophils in the infiltrate, sometimes the formation of crypt abscesses and erosions. In remission, these signs are absent.

The degree of severity of chronic gastritis can be mild, moderate and severe.

Thus, chronic gastritis is based on both inflammatory and adaptive-reparative processes of the gastric mucosa with imperfect regeneration of the epithelium and metaplastic reconstruction of its "profile". Violation of mucosal epithelium regeneration in chronic gastritis is confirmed by electron microscopic examination of gastrobiopsies. It has been established that undifferentiated cells, which are normally located in the deep parts of the

gastric pits and gland necks, in chronic gastritis appear in the gastric ridges, in the area of the body and bottom of the glands. Signs of premature involution are found in immature cells. This indicates profound violations of the coordination of the phases of proliferation and differentiation of the epithelium of the glands during the regeneration of the mucous membrane of the stomach, which leads to cellular atypia, the development of dysplastic processes.

Due to the fact that with chronic gastritis, disturbances in the processes of regeneration and structure formation, leading to cellular atypia (dysplasia), are clearly reflected, it often becomes the background against which stomach cancer occurs.

The value of chronic gastritis is extremely high. In the structure of diseases of the gastroenterological profile, it ranks second after peptic ulcer disease. It is important to note that chronic atrophic gastritis with severe dysplasia is often a precancerous disease of the stomach.

Ulcer disease is one of the common diseases of the digestive organs. It is a general chronic, cyclical, relapsing disease. According to foreign authors, the honorable discovery of gastric ulcer belongs to the French clinician and anatomist Cruvelier (1829). However, it is fair to note that in 1817, in 1817, our compatriot Academician Fyodor Uden published a thorough treatise on peptic ulcer disease, 12 years earlier.

The 20th century is characterized by a steady increase in the frequency of peptic ulcers in all countries in the form of chronic ulcers, mainly of the duodenum, especially in the USA. Ulcer disease is much more common in men. Occurs at any age, but most often from 25 to 50 years.

At the same time, duodenal ulcer has a maximum frequency at the age of 30 to 40 years. And stomach ulcer - from 50 to 60 years.

Elderly people have a large number of complications.

Pathological-anatomical changes in peptic ulcer are manifested in the form of erosion, acute and chronic peptic ulcer.

Surface defects of the mucous membrane that do not reach its own muscle layer are called erosions. They are often numerous and are formed from petechial hemorrhages inside the mucous membrane. Erosions are easily

epithelialized and often disappear without a trace. But erosions can be the center from which a peptic ulcer develops later. The size of the erosion varies from 1 mm to several cm in length. Peptic ulcers differ from erosions in that the mucosal defect reaches the muscle layer itself, and often extends into the submucosa. Acute and chronic ulcers should be distinguished.

An acute ulcer is characterized by little development of connective tissue in its bottom and edges. The healing process is accompanied by mild scarring and after several weeks, the location of the ulcer cannot be established. Acute ulcers can be a source of bleeding and perforation.

A chronic (peptic) ulcer is characterized by a large amount of fibrous tissue and a more massive cellular infiltration at the base and along the edges of the ulcer. The ulcer has a round or oval shape, its bottom is white or gray, and an inflammatory shaft is observed around the ulcer. Healing of chronic peptic ulcer is slow and a large number of scars remain, a wide scar field.

Acute ulcers develop more often on the front wall of the duodenal bulb and most perforations are observed precisely at this location.

90% of chronic duodenal ulcers occur on the anterior and posterior walls of the bulb, 1–2 cm away from the pylorus. 10% of ulcers are localized below the bulb - postbulbar ulcers. Ulcers of the back wall are characterized by a greater tendency to scarring and more easily cause stenosis and penetration into neighboring organs. Ulcers of the front wall do not form a deep scar when healed. Postbulbar ulcers in 60% or more penetrate into the pancreaticoduodenal artery, causing particularly heavy bleeding.

25% have multiple ulcers of the duodenum and are located on the front and back walls of the bulb. A stomach ulcer can form in any part of it, but the favorite places are the lesser curvature and the antrum. The bottom and greater curvature are rarely affected. Acute and chronic ulcers form in the stomach, as well as in the duodenum. The diameter of an acute ulcer does not exceed 1 cm. The healing process can be very fast, but perforations are common.

A chronic stomach ulcer, which in its classical form is described by Uden, Kruevlier and Shemetov, can reach 10 cm in length, but as a rule, its size varies from 1 to 3 cm.

Usually, chronic stomach ulcers are isolated. Multiple ulcers are observed in only 5-10% of cases.

As for the morphological structure of the ulcer itself, they are divided into simple and penetrating. Simple ulcers are relatively shallow, penetrating ones reach the serous layer. The muscle layers at the bottom of the penetrating ulcer are completely destroyed. There is a fusion with neighboring organs and the bottom of the ulcer. Penetrating ulcers are more common than simple ones. Histologically, in the bottom and edges of a chronic ulcer, multiple development of scar tissue is revealed. As a result of hypoxia, a lot of KMPS accumulates in this tissue. Young granulation tissue rich in blood capillaries is located on it. Next, closer to the lumen of the stomach, there is a zone of fibrinoid necrosis, and finally, on the surface, there are tissue fragments mixed with microbes, mucus, leukocytes, fibrin, and hydrochloric acid hematin. So, 4 layers: scar tissue, granulation tissue,

The development of a necrotic layer, which can reach a thickness of several millimeters, is considered characteristic of progressive ulcers. In these ulcers, the granulation tissue is fully involved in the destructive process and the layer of fibrinoid necrosis is directly adjacent to the scar layer.

At the bottom and edges of the ulcer, the arterial vessels have changed dramatically. They are prone to inflammation and sclerosis with a sharp narrowing of the lumen and the formation of blood clots. Fibrinoid necrosis of the arterial walls, which plays a major role in the occurrence of bleeding, is not uncommon. Lympho-venous stagnation occurs, which also contributes to bleeding.

Chronic ulcers of the stomach and duodenum tend to heal, and this tendency is more pronounced in women than in men. The healing process most often ends with the development of a scar.

Quite often, severe complications develop with peptic ulcer disease, which are the cause of not only suffering and loss of working capacity, but also often fatal outcomes. Studying the data of the medical examiners' offices in large cities shows that among every 100 people who died from various diseases, in 2 cases the cause of death is a complication of peptic ulcer disease.

Depending on which process prevails in the ulcer at the time of the complication: necrosis, inflammation or scarring, all complications are divided into complications of ulcer-destructive origin, ulcer-inflammatory and ulcer-scar origin.

Complications of ulcer-destructive origin include ulcer penetration, ulcer breakthrough and bleeding from the ulcer. Penetration of the ulcer occurs when all layers of the wall of the stomach or duodenum are destroyed by the necrotic-destructive process and the bottom of the ulcer reveals a nearby organ. Penetration occurs in approximately 30% of all ulcers. Penetration occurs more often in middle-aged and elderly people with a long ulcer history. Patients with penetrating ulcers are subject to gastric resection. According to most authors, localization of a penetrating ulcer in the duodenum is observed more often than in the stomach. There is the following classification of ulcer penetration, depending on the organ where it penetrates.

1. Penetration into parenchymal organs (pancreas, liver, spleen).
2. Penetration into mesenteric formations (omentum, mesenteric ligaments).
3. Penetration into the anterior abdominal wall.
4. Penetration into the wall of a cavity organ (transverse colon, gall bladder) without the formation of a fistula.
5. Penetration into cavity organs with the formation of fistulas.
6. Penetration of one ulcer into several organs.
7. Plural|numerous| penetration several ulcers|ulcers|.

Ulcer breakthrough can be open or covered.

In the vast majority of cases, an open breakthrough into the free abdominal cavity is observed. Concealed ulcer perforation is much less common. The perforation (after perforation into the free abdominal cavity) is often covered by a nearby organ.

The pyloric part of the stomach and the duodenum together account for 71% of the total number of perforations. At the same time, the ulcer is usually localized in the front wall. There are repeated perforations of the ulcer in one patient. More often it is the same ulcer that has not healed, less often another

new ulcer. The occurrence of preperforative exacerbation of peptic ulcer disease or the perforation itself is associated with alcohol intake, dietary disorders, taking gastric juice with a thick probe, X-ray examination, and the like.

Perforations occur in 25 to 50% of cases (in different surgeons). Progressive necrotization of the ulcer floor, caused by gastric juice, leads to perforation.

Perforation develops peritonitis, which is the most common cause of death in ulcers.

Bleeding from the ulcer is quite a frequent complication. It is observed from 10 to 15%. Bleeding from a stomach and duodenal ulcer occurs in people of various ages, but most often after 40 years.

Sometimes bleeding is the first manifestation of latent ulcer disease. Recurrent bleeding is especially dangerous.

Localization of a bleeding ulcer prevails in the stomach, mainly on its small curvature, where the largest blood vessels pass. Usually, patients have "coffee grounds" vomiting and tarry feces. Bleeding occurs more often from a chronic ulcer, often penetrating, but sometimes from acute ulcers and erosions. The source of bleeding is an artery destroyed by the ulcer process. Inflammation and fibrinoid necrosis are found in the artery.

At the bottom of the ulcer, an autopsy reveals a destroyed blood vessel, the lumen of which is gaping or filled with a fresh blood clot.

Complications of ulcer-inflammatory origin include: gastritis, duodenitis, perigastritis, periduodenitis, inflammatory process of biliary tract and liver. Very serious complications of this group include purulent, usually phlegmatic, inflammation of the stomach and duodenum. Fibrinous exudate near the ulcer on the serous membrane in perigastritis and periduodenitis undergoes organization, and adhesions, adhesions, even infected ones are formed.

Stenosis of the duodenum, deformation of the stomach in the shape of an hourglass, and diverticula are among the complications of ulcer-scar origin.

One of the most frequent reasons for surgical treatment of patients with peptic ulcer is pyloro-duodenal stenosis of ulcer origin. These stenoses are usually partial. They are accompanied by a violation of the motor evacuation



function of the stomach - food does not pass well into the intestines. Narrowing occurs as a result of growth and shrinkage of connective tissue, especially in combination with tightening of the serous membrane as a result of perigastritis and periduodenitis. The muscular shell of the stomach with stenoses hypertrophies, but in the later stages there is an acute expansion of the stomach with gastrogenic tetany and death.

With cicatricial narrowing of the stomach, a two-cavity stomach is formed in the body or in the antral region, resembling an hourglass in shape. In most cases, in the region of the constricting isthmus, penetrating ulcers remain that do not heal for a long time, which can cause bleeding and perforation.

One of the most serious complications of peptic ulcer disease is malignant transformation of the ulcer or malignancy of the ulcer. According to the literature of recent years, ulcer malignancy occurs in the elderly in 6% of cases. It can be in children. Cancer develops from the covering epithelium during its metaplasia. Gastric ulcer of the greater curvature of the stomach is more often malignant.

Squamous cell carcinoma – 1–5% of cases, is asymptomatic, discovered accidentally at autopsy.

Polyposis cancer - 5% of cases, has the form of a node on the leg. Fungal - 10% species nodes on a wide base with erosions, hemorrhages. Ulcerative cancer - 50% of cases - cancer-ulcer, ulcer-cancer. Infiltrative-ulcerative cancer - cancerous infiltration of the wall, tumor ulcer. Diffuse cancer - 20%, endophytic growth. Types of cancer are distinguished: adenocarcinoma, undifferentiated, squamous cell, glandular squamous cell, unclassified. Unclassified (solid, scirrhous, ring-shaped). Metastases: lympho-hematogenous, implantation. Complications - necrotic, inflammatory, perforation, bleeding, peritumorous inflammation, phlegmon of the stomach, exhaustion of the patient.

Acute enteritis is an acute inflammation of the small intestine. It often occurs in many infectious diseases (cholera, typhoid, colibacillary, staphylococcal and viral infections, giardiasis, sepsis, opisthorchosis, etc.), food toxic infections (botulism, salmonellosis), poisoning (chemical poisons,

poisonous mushrooms).

Acute enteritis of alimentary (abuse of strong alcoholic beverages, coarse food, seasonings) and allergic (idiosyncrasy to food products, medicines) origin is known.

Depending on the nature of the inflammatory reaction, enteritis can be catarrhal, fibrinous, purulent, necrotic-ulcerative.

With catarrhal enteritis, which occurs most often, the mucous membrane of the intestine swells, becomes full of blood, covered with serous, serous-mucous, or serous-purulent exudate. Edema and inflammatory infiltration cover not only the mucous membrane, but also the submucosa. At the same time, there is dystrophy and desquamation of the epithelium, especially at the tips of the villi (catarrhal desquamative enteritis), hyperplasia of goblet cells ("goblet transformation"), small erosions and hemorrhages.

With fibrinous enteritis, more often ileitis, the intestinal mucosa is necrotized and soaked with fibrinous exudate, as a result of which gray or gray-brown films appear on its surface. Depending on the depth of necrosis, the inflammation can be croupous or diphtheritic, in which deep ulcers are formed after the detachment of fibrinous films.

Purulent enteritis is characterized by impregnation of the intestinal wall with pus (phlegmonous enteritis).

In case of necrotic-ulcerative enteritis, the destructive processes concern, mainly, group and solitary follicles of the intestine, which is observed in typhoid fever, or cover the mucous membrane without connection with the lymphatic apparatus of the intestine. At the same time, necrosis and ulceration acquire a widespread (sepsis, flu) or focal (nodular periarteritis, allergic vasculitis) character.

In acute enteritis, regardless of the type of inflammatory changes in the mucous membrane, there is hyperplasia and reticulomacrophagic transformation of the lymphatic apparatus of the intestine. Sometimes it is extremely pronounced (cerebral swelling of group and solitary follicles in typhoid fever) and causes further destructive changes in the intestinal wall.

Reactive processes in the form of hyperplasia of lymphoid elements,

plasmacytic and reticulomacrophagic transformation, and often inflammation are observed in mesenteric lymph nodes.

Complications of acute enteritis include bleeding, perforation of the intestinal wall with the development of peritonitis (with typhoid fever), as well as dehydration and demineralization (with cholera).

In a number of cases, acute enteritis turns into chronic.

Chronic enteritis can be an independent disease or a manifestation of other chronic diseases (gastritis, hepatitis, liver cirrhosis, rheumatic diseases, etc.).

At the heart of chronic enteritis is not only inflammation, but also a violation of the physiological regeneration of the mucous membrane: proliferation of the crypt epithelium, differentiation of cells, their "movement" along the villi and separation from the mucous membrane into the lumen of the intestine.

At first, such disorders represent an increased proliferation of the crypt epithelium with the "goal" of restoring exfoliated, damaged enterocytes of the villi, but the differentiation of this epithelium into functionally complete enterocytes is delayed. As a result, a significant part of the villi is lined with undifferentiated, functionally inferior enterocytes, which quickly die. Villi adapt their shape to a moderate number of epithelial cells - they become shorter, atrophy. After some time, the crypts (cambial zone) are unable to provide a pool of enterocytes, undergo cystic transformation and sclerosis. These changes become the final stage of impaired physiological regeneration of the mucous membrane of the small intestine.

In recent years, changes in the intestinal wall during chronic enteritis have been well studied on the material of enterobiopsies. It has been shown that the basis of chronic enteritis, like gastritis, is the process of impaired regeneration of the epithelium, which ends in atrophy and structural restructuring of the mucous membrane.

There are two forms of chronic enteritis: without mucosal atrophy and atrophic enteritis.

Chronic enteritis without mucosal atrophy is characterized by varying

thickness of villi and the appearance of mace-like thickenings in their distal parts, where the destruction of the basal membranes of the epithelial lining is noted. The cytoplasm of enterocytes lining the villi is vacuolated (vacuolar dystrophy). The activity of redox and hydrolytic (alkaline phosphatase) enzymes of the cytoplasm of such enterocytes is reduced, which indicates a violation of their adsorption capacity. Adhesions, "arcades" appear between the enterocytes of the apical sections of the villi, which is probably connected with the formation of surface erosions; the stroma of the villi is infiltrated with plasma cells, lymphocytes, and eosinophils. The cellular infiltrate descends into the crypts, which are cystically expanded; the infiltrate separates the crypts and reaches the muscular layer of the mucous membrane.

Chronic atrophic enteritis is characterized primarily by the shortening of villi, their deformation, and the appearance of a large number of fused villi. Collapse of argyrophilic fibers occurs in shortened villi. Enterocytes are vacuolated, alkaline phosphatase activity is reduced in the brush border; a significant number of goblet cells appear, cystic expansions are very common, their infiltration by lymphocytic elements and their replacement by growths of muscle and collagen fibers is observed.

With prolonged severe chronic enteritis, anemia, cachexia, hypoproteinemic edema, osteoporosis, vitamin deficiency, endocrine disorders, malabsorption syndrome may occur.

Enteropathies are chronic diseases of the small intestine, which are based on hereditary or acquired enzyme disorders of enterocytes (intestinal enzymopathies). Decreased activity or loss of certain enzymes is accompanied by insufficient absorption of substances that are normally broken down by these enzymes. As a result, there is a syndrome of impaired absorption of certain food substances.

Enteropathies include: 1) disaccharidase deficiency (alactasia); 2) hypercatabolic hypoproteinemic enteropathy (intestinal lymphangiectasia); 3) non-tropical sprue (idiopathic, endogenous, sprue-celiac disease, including gluten enteropathy).

Whipple's disease (intestinal lipodystrophy) is a rather rare chronic

disease of the small intestine, which is characterized by malabsorption syndrome, hypoproteinemia and hypolipidemia, progressive lethargy and exhaustion, and weight loss.

The inflammatory process in colitis mainly covers the caecum (typhlitis), transverse colon (transversitis), sigmoid (sigmoiditis) or rectum (proctitis), and in some cases it spreads to the entire intestine (pancolitis). Inflammation can be both acute and chronic.

Acute colitis is an acute inflammation of the colon. There are infectious, toxic and toxic-allergic colitis. Infectious colitis includes dysenteric, typhoid, colibacillary, staphylococcal, fungal, protozoal, septic (tuberculous, syphilitic); to toxic - uremic, sulem medicinal; and to the toxic-allergic – alimentary and coprostatic.

The following forms of acute colitis are distinguished: catarrhal, fibrinous, purulent, hemorrhagic, necrotic, gangrenous, ulcerative.

With catarrhal colitis, the mucous membrane of the intestine is full of blood, swollen, on its surface there is an accumulation of exudate, which is serous, mucous, and purulent in composition. The inflammatory infiltrate is located not only in the mucous membrane, but also in the submucosa, where hemorrhages appear quite often. Epithelial dystrophy and necrobiosis are associated with desquamation of the surface epithelium and hypersecretion of glands.

Depending on the depth of mucosal necrosis and the penetration of fibrinous exudate, fibrinous colitis is divided into croupous and diphtheritic.

Purulent colitis is characterized by phlegmonous inflammation (phlegmonous colitis, phlegmon of the colon). In those cases when hemorrhages occur in the intestinal wall, areas of hemorrhagic impregnation appear, we are talking about hemorrhagic colitis.

With necrotic colitis, necrosis occurs not only in the mucous membrane, but also in the submucosa. Gangrenous colitis is a variant of necrotic colitis.

Acute ulcerative colitis usually ends with diphtheritic and necrotic changes in the colon wall. In a number of cases, for example, with amebiasis, ulcers in the colon appear at the beginning of the disease.

Complications of acute colitis: bleeding, perforation and peritonitis, paraproctitis with pararectal fistulae; sometimes acute proctitis turns into chronic.

Chronic colitis - chronic inflammation of the large intestine can be primary or secondary. In some cases, it is genetically related to acute, in others - no such connection is observed.

Chronic colitis, like acute, occurs under the influence of infectious, toxic and toxicoallergic factors. The time during which the factors continue to act in conditions of increased local (intestinal) reactivity acquires great importance.

Morphological changes in the wall of the large intestine in chronic colitis, studied on biopsies, do not differ from the changes that occur in chronic enteritis, although inflammatory processes are more pronounced in colitis, which are combined with dysregenerative processes and end in atrophy and sclerosis of the mucous membrane. Depending on the changes that occur, a distinction is made between: chronic colitis without mucosal atrophy and chronic atrophic colitis.

In chronic colitis without atrophy of the mucous membrane, the latter is swollen, dull, granular, gray-red or red, often with multiple hemorrhages and erosions; prismatic epithelium is flattened, desquamated; the number of goblet cells increases in the crypts. The crypts themselves are short, extended. The own plate of the mucous membrane, in which hemorrhages occur, is diffusely infiltrated with lymphocytes, plasma cells, and eosinophils, which quite often penetrate the muscle membrane.

The degree of inflammatory infiltration can be different - from moderate focal to sharply pronounced diffuse with the formation of abscesses in the crypts (crypt abscesses) and ulceration.

Chronic atrophic colitis is characterized by flattening of the prismatic epithelium, a decrease in the number of crypts, and hyperplasia of smooth muscle elements. Histiolympocytic infiltration and growth of connective tissue prevail in the mucous membrane; in a number of cases there are ulcers with epithelialization and scarring.

Possible complications of colitis are parasigmoiditis and paraproctitis,

sometimes hypovitaminosis due to a change in the intestinal flora and a violation of vitamin synthesis.

Nonspecific ulcerative colitis (idiopathic ulcerative colitis, ulcerative proctocolitis) is a chronic relapsing disease, the basis of which is inflammation of the large intestine with suppuration, ulceration, hemorrhages, with successive sclerosis and deformation of the wall. This disease is quite widespread and most often occurs in young women.

Crohn's disease is a chronic recurrent disease of the gastrointestinal tract, which is characterized by nonspecific granulomatosis, necrosis, and scarring of the wall of the intestinal tube, which occurs quite rarely.

This disease was previously understood as a non-specific granulomatous lesion of only the terminal part of the small intestine, therefore it was called terminal (regional) ileitis. Later, it was established that changes characteristic of this disease can occur in any department of the gastrointestinal tract. New descriptions of Crohn's disease of the stomach, colon, appendix, etc. appeared.

Appendicitis is inflammation of the appendix, which is accompanied by a characteristic clinical syndrome. From the above, it follows that in clinical and anatomical terms, not every inflammation of the appendix (tuberculosis, dysentery) can be interpreted as appendicitis. Appendicitis is a widespread disease that requires surgical intervention.

There are two clinical and anatomical forms of appendicitis: acute and chronic; each of them has a certain morphological characteristic.

Acute appendicitis. Depending on the morphological changes and type of inflammation, the following morphological forms of acute appendicitis are distinguished: 1) simple; 2) superficial; C) destructive (phlegmonous, apostematous, phlegmonous-ulcerative, gangrenous). These forms are a morphological reflection of the phases of acute inflammation of the appendix, which ends in destruction and necrosis. Such an inflammatory process takes place within 2-4 days. Changes characteristic of acute simple appendicitis develop in the first hours after the onset of the attack. They are accompanied by disorders of blood and lymph circulation in the form of stasis in capillaries and venules, edema, hemorrhages, accumulation of siderophages, as well as

marginal standing of leukocytes and leukodiapedesis. Such changes occur mainly in the distal part of the process.

Later, against the background of dyscirculatory changes in the distal part of the appendix, foci of exudative purulent inflammation of the mucous membrane appear, which is called primary affect (Aschoff). At the top of such a cone-shaped focus, turned into the lumen of the process, surface defects of the epithelium appear. Such morphological changes are characteristic of acute superficial appendicitis, in which the appendix swells, and its serous membrane becomes full-blooded and dull. Changes characteristic of simple or superficial appendicitis are reversible, and if they progress, acute destructive appendicitis develops.

At the end of the first day, the leukocyte infiltrate spreads throughout the thickness of the appendage wall - phlegmonous appendicitis develops. The size of the appendage increases, its serous membrane becomes dull and full-blooded, fibrinous layers appear on its surface: the wall is thickened at the autopsy, the lumen is filled with pus; the mesentery is swollen, hyperemic. In cases where multiple small abscesses appear against the background of diffuse purulent inflammation of the appendix, we are talking about apostematous appendicitis; if phlegmonous appendicitis is accompanied by ulceration of the mucous membrane - about phlegmonous-ulcerative appendicitis. Purulent-destructive changes in the appendix culminate in gangrenous appendicitis, which is called secondary because it is a consequence of the spread of purulent inflammation to adjacent tissues (periappendicitis).

Secondary gangrenous appendicitis should be distinguished from gangrene of the appendix, which develops with primary thrombosis or thromboembolism of its artery. Perhaps that is why gangrene of the appendage is not quite successfully called primary gangrenous appendicitis.

The appearance of the appendix in gangrenous appendicitis is quite characteristic - it is thickened, the serous membrane is covered with a dirty-green, fibrinous-purulent film; its wall is also thickened, gray and dirty, pus is released from the lumen. During microscopic examination, significant foci of necrosis with bacterial colonies are found in them, as well as hemorrhages and



blood clots in blood vessels. Mucous membrane - with many ulcers. The most pronounced destructive changes up to perforation of the wall and self-amputation are observed in the distal part of the process.

In acute appendicitis, complications are associated with the destruction of the appendage and the spread of pus. Quite often, with phlegmonous-ulcerative appendicitis, perforation of the wall occurs with the subsequent development of peritonitis, which can also occur during self-amputation of a gangrenous-changed appendage. If the proximal part is closed during phlegmonous appendicitis, then the lumen of the distal part is stretched and empyema of the appendage develops. The spread of pus to adjacent tissues and the cecum (periappendicitis, perityphlitis) is accompanied by the formation of abscesses and the transition of inflammation to the extraperitoneal tissue. The development of purulent thrombophlebitis of the mesenteric vessels with its spread to the branches of the portal vein with the subsequent development of pylephlebitis is quite dangerous.

Chronic appendicitis. It develops after a previous acute appendicitis and is characterized by sclerotic and atrophic processes, against the background of which inflammatory and destructive changes in the appendage may develop. Inflammation and destruction are replaced by the growth of granulation tissue in the wall of the process. At the same time, there is a sharp sclerosis and atrophy of all layers of the wall, obliteration of the lumen of the process; adhesions appear between it and adjacent tissues. These changes can be associated with granulomatous and acute ulcers, histiolympocytic and leukocytic infiltration of the appendage wall.

Sometimes, when the proximal part of the appendage is obliterated, serous fluid accumulates in its cavity, and then it turns into a cyst - dropsy of the appendage develops. If the secret of the glands - mucus - appears in the cyst, then it turns into a mucocele. Sometimes, as a result of the peristalsis of the appendage, the mucus collects in spherical formations (myxoglobules), which ends in myxoglobulosis of the appendage. When the cyst wall is perforated and mucus enters the abdominal cavity together with the cells that form it, implantation of these cells in the peritoneum is possible with the

development of changes resembling a tumor - a myxoma (pseudomyxoma of the peritoneum).

In those cases when the clinical signs of an appendicitis attack are caused not by an inflammatory process, but by dyskinetic disorders, we are talking about false appendicitis. In cases of hyperkinesis of the appendage, the muscle layer of its wall is shortened, the follicles are enlarged, and the lumen is sharply narrowed. With atony, the lumen is expanded, filled with fecal masses (coprostasis); the wall of the appendage is thin, the mucous membrane is atrophic.

Polyps and cancer are the most important among intestinal tumors. A polyp is a common epithelial benign tumor of the intestine. It is usually localized in the rectum, followed by the sigmoid, cecum, and small intestines. The main importance is edematous polyp. Its variety is a villous tumor (papillary adenoma). The tumor is round, soft, pink-red, with a villous surface; grows exophytically, has a glandular papillary structure. Cancer can occur in a villous tumor. Diffuse intestinal polyposis is a family disease.

Cancer occurs in both the small and large intestines. Cancer of the small intestine is rare and is usually observed in the duodenum in the place of its large so-called Vater nipple. The tumor does not reach large sizes, very early causes difficulty in the outflow of bile, which is the cause of subhepatic jaundice complicated by inflammation of the bile ducts. Histologically, it has the structure of adenocarcinoma or undifferentiated cancer.

Colon cancer tends to increase in frequency, and mortality from it increases. Of the various parts of the colon, cancer is most often found in the rectum, less often in the sigmoid, cecum, hepatic and splenic corners of the transverse colon.

Rectal cancer usually develops against the background of chronic ulcerative colitis, polyposis or chronic rectal fistulas, which are considered precancerous diseases.

Depending on the nature of growth, the following macroscopic forms of rectal cancer are distinguished: 1) exophytic cancer - polypous and villous form; 2) endophytic cancer - ulcerative and diffuse forms.

In the ampullary department there is a polypous or villous tumor, as well as a cancer covered with ulcers in the form of a huge ulcer crater with roller-like edges. Diffuse cancer in the form of a whitish dense ring narrowing the intestinal lumen is more often found in the rectosigmoid region.

Microscopic types of rectal cancer include: 1) differentiated dark cell adenocarcinoma; 2) undifferentiated cancer in two variants - ring-shaped cell and solid.

Exophytic forms more often have the structure of differentiated adenocarcinoma, and endophytic forms of undifferentiated cancer.

Rectal cancer metastasizes to regional lymph nodes and hematogenously to the liver.

Peritonitis, or inflammation of the peritoneum, is quite often a complication of diseases of the digestive tract: perforation of a stomach or duodenal ulcer, intestinal ulcers in typhoid fever, nonspecific ulcerative colitis, dysentery, as well as appendicitis, cholecystitis, acute pancreatitis, etc.

**Materials on the activation of students of higher education during the lecture: questions, situational tasks, etc(*if necessary*):**

### **General material and bulk-methodological support of the lecture:**

#### **Questions for self-control:**

1. Esophageal disease. Diverticula: definition, classification, morphological characteristics, complications.
2. Esophagitis: definition, classification, morphological characteristics, complications.
3. Esophageal cancer and precancerous conditions.
4. Stomach disease. Gastritis: definition, causes of development, classification according to various criteria.
  - acute gastritis: definition, classification, morphological characteristics, complications;
  - chronic gastritis: definition, classification, morphological characteristics,

complications.

5. Erosions and acute stomach ulcers: definition, classification, morphological characteristics, complications.

6. Chronic ulcer: definition, classification, morphological characteristics (in the stage of remission and the stage of exacerbation).

7. Complications of chronic gastric ulcer (bleeding, perforation, penetration, inflammation, stenosis, malignancy).

8. Stomach cancer. Definition, classification, morphological characteristics.

9. Intestinal disease. Appendicitis: definition, classification;

- morphological characteristics of acute appendicitis,

- morphological characteristics of chronic appendicitis,

- complication of appendicitis.

10. Crohn's disease. Morphological characteristics.

11. Nonspecific ulcerative colitis. morphological characteristic.

12. Liver disease. Hepatitis: definition, classification, morphological characteristics, complications.

13. Hepatosis: definition, classification, morphological characteristics, complications.

14. Massive progressive necrosis of the liver. Causes of development, stages, consequences.

15. Liver cirrhosis: definition, classification, morphological characteristics.

16. Gallstone disease.

17. Pancreatic disease. Pancreatitis: definition, classification, morphological characteristics, complications and consequences.

## **References:**

Main:

1. Atlas of micropreparations in pathomorphology / I.I. Starchenko, B.M. Filenko, N.V. Royko, etc.; VDZU "UMSA". - Poltava, 2018. - 190 p

2. Starchenko, S.O. Bilokon and others.. – Poltava: Tov. "ASMI" - 2018. - 190 p.

3. Fundamentals of pathology according to Robbins: in 2 volumes. Volume 1 / Vinay Kumar, Abul K. Abbas, John C. Astaire; translation of the 10th Eng. edition. Publisher: All-Ukrainian specialized publishing house "Medytsyna". – X II. - 2019. - 420 p.

4. Fundamentals of pathology according to Robbins: in 2 volumes. Volume 1 / Vinay Kumar, Abul K. Abbas, John C. Astaire; translation of the 10th Eng. edition. Publisher: All-Ukrainian specialized publishing house "Medytsyna". – X II. - 2019. - 420 p.

5. Pathomorphology. General pathomorphology: a study guide / edited by Ya. Ya. Bodnara, V.D. Voloshina, A.M. Romanyuk, V.V. Gargin. - New Book, 2020. - 248 p.

6. Pathomorphology of the main diseases of the cardiovascular system: study guide / I.I. Starchenko, B.M. Filenko, N.V. Royko – Poltava: "UMSA". - 2019. - 150 p.

7. Starchenko I.I. Pathomorphology of the main diseases of the maxillofacial region:

academician. manual / I.I. Starchenko, B.M. Filenko, V.V. Chernyak ; "UMSA". – Vinnytsia: Nova Kniga, 2019. – 128 p.

8. Ctarchenko I.I. Special pathomorphology (basic course) for students of medical faculties of higher medical educational institutions of III-IV levels of accreditation / I.I. Starchenko, N.V. Royko, B.M. Filenko. – Poltava, 2017. – 174 p.

9. Tuffaha S. A. Muin Immunohistochemistry in the diagnosis of tumors / S. A. Tuffaha Muin, S. G. Hychka, Husky Hans. - "Book Plus", 2018. - 336 p.

10. Essentials of pathology: textbook / Ya. Bodnar, A. Romanyuk, V. Voloshyn, V. Gargin - Kharkiv, "Planeta-Print" Ltd, 2020, 219 p.

11. Pathology: textbook / IVSorokina, VD Markovskiy, DI Halata et al.; edited by IVSorokina, VD Markovskiy, DI Halata. - Kyiv: AUS Medicine Publishing, 2019. - 328p. + 2 color inserts (8p. + 12p.).

12. Pathology: textbook / IVSorokina, VD Markovskiy, DI Halata et al.; edited by IVSorokina, VD Markovskiy, DI Halata. - 2nd edition. - Kyiv: AUS Medicine Publishing, 2020. - 328p. + 2 color inserts (8p. + 12p.).

Additional:

1. Benign neoplasms of bones of the maxillofacial area in children / P.I. Tkachenko, I.I. Starchenko, S.O. Bilokin [and others] - P.: "UMSA", 2016. - 85 p

2. General pathomorphology / I.I. Starchenko, N.V. Royko, B.M. Filenko [et al.] – Poltava, 2016. – 136 p.

3. Zerbino D. D. Pathomorphology and histology: atlas / D. D. Zerbino, M. M. Bagriy, Y. Ya. Bodnar, V. A. Dibrova. – Vinnytsia: Nova Kniga, 2016. – 800 p.

4. Methods of morphological research / M.M. Baghrii, V.A. Dibrova, O.G. Papadynets, M.I. Grischuk; edited by M.M. Baghria, V.A. Dibrovyy – Vinnytsia: Nova Kniga, 2016. – 328 p.

5. Novoseltseva T.V. Pathology of sexual and endocrine systems / T.V. Novoseltseva, B.M. Filenko, N.I. Hasiuk - Poltava: LLC "ASMI", 2015. - 199 p.

6. Pathomorphology: national. / V.D. Markovskiy, V.O. Tumanskyi, I.V. Sorokina [and others]; edited by V.D. Markovskiy, V.O. Tumanskyi. - K.: VSV "Medicine", 2015. - 936p.

7. Practicum on biopsy section course / I.I. Starchenko, A.P. Hasyuk, S.A. Proskurnya [etc.] – Poltava, 2016. – 160 p.

## Lecture No. 11

**Subject:** Khkidney sparrows

**Actuality of theme:** Kidney diseases. pyelonephritis; · urolithiasis; · kidney failure; · lowering of the kidney (nephroptosis) how this disease differs from all others, etc.

**Goal:** Analyze clinical and morphological manifestations and,

groups and diseases, principle and, genetically transmitted diseases, and the main patients kidney

**Basic concepts:** Glomerulonephritis ((poststreptococcal, (rapidly progressive, Fibroplastic, chronic, Membranous, ARF, "myeloma kidney", "gouty kidney", Pyelonephritis, pyonephrosis, perinephritis, paranephritis, papillonecrosis, nephrolithiasis, polycystic, hydroureteronephrosis, pyoureteronephrosis, purulent, armored paranephritis, fatty kidney replacement, nephrosclerosis.

### **Plan and organizational structure of the lecture:**

Greetings, verification of those present, announcement of the topic, purpose of the lesson, motivation of higher education seekers to study the topic.

### **Content of lecture material (lecture text)**

Kidney diseases or nephropathy represent a numerous and diverse group of diseases both in clinical and morphological manifestations. Guided by the structural-functional principle, two main groups of kidney diseases are distinguished - glomerulopathy and tubulopathy, which can be both acquired and hereditary.

At the heart of glomerulopathies with primary and predominant defeat of the glomerular apparatus are violations of glomerular filtration. Acquired glomerulopathies include glomerulonephritis, renal amyloidosis, diabetic and hepatic glomerulosclerosis, and idiopathic nephrotic syndrome, and hereditary nephritis with deafness (Alport syndrome), hereditary nephrotic syndrome, and forms of familial nephropathic amyloidosis.

For tubulopathies, with a predominant defeat of the tubules, violations of the concentration, reabsorption and secretory function of the tubules are characteristic. Acquired tubulopathies are represented by acute renal failure (ARF) and chronic tubulopathies (gouty kidney and myeloma kidney), and hereditary – by various forms of tubular enzyme diseases.

There is also a group of diseases in which inflammation occurs mainly in the interstitial tissue with subsequent damage to the entire nephron. This group includes tubulointerstitial nephritis and pyelonephritis. A special group consists of kidney malformations - polycystic kidney disease and kidney tumors.

## Glomerulopathy.

Glomerulonephritis is an infectious-allergic disease based on bilateral diffuse or focal non-purulent inflammation of the glomerular apparatus of the kidneys with characteristic renal and extrarenal symptoms. Renal symptoms include: oliguria, proteinuria, hematuria, cylindruria. To extrarenal - arterial hypertension, hypertrophy of the left heart, dysproteinemia, edema, hyperazotemia and uremia. In the clinic, nephrotic, hypertensive and mixed forms of glomerulonephritis are distinguished.

The classification of glomerulonephritis takes into account: nosological affiliation (primary - kidney damage is the main manifestation of the disease and secondary - as a manifestation of another disease); etiology (established or unestablished); pathogenesis; course (acute, subacute, chronic); morphology (topography, nature and spread of inflammation).

The development of glomerulonephritis is often associated with an infection (bacterial glomerulonephritis). It is also abacterial. The main role among pathogens is played by  $\beta$ -hemolytic streptococcus, less important are staphylococcus, pneumococcus, malaria plasmodia, and viruses. Often, bacterial glomerulonephritis develops after an infectious disease, as an allergic reaction of the body to an infection. Most often, it is angina, scarlet fever, prolonged septic endocarditis, malaria, syphilis.

The sensitization of the organism by a bacterial or non-bacterial antigen with localization of manifestations of hypersensitivity in the vessels of the kidney glomeruli is of great importance. A special role is played by cooling (cold injury), which is evidenced by the seasonal nature of the disease.

If the development of nephritis is associated with antigenic stimulation, the formation of antibodies and immune complexes, we are talking about immunologically determined glomerulonephritis. The immunological mechanism of development of glomerulonephritis is associated with the action of immune complexes, less often with the action of antibodies.

Immune complexes can contain a heterologous (bacterial) antigen. This is connected with the development of immune inflammation in the glomeruli, which reflects a hypersensitivity reaction of the immediate type, which is

characteristic of acute and subacute glomerulonephritis. In complex immune complexes, there may be an antigen of one's own organs and tissues. Then morphological manifestations of hypersensitivity of the delayed type appear in the glomeruli of the kidneys - these are mesangial forms of glomerulonephritis.

The antibody mechanism leads to the development of autoimmunization due to the connection with antirenal autoantibodies. Glomerulonephritis in such cases has extracapillary proliferative or mesangial-proliferative morphology.

A classic example of this is glomerulonephritis in Goodpasture's pneumorenal syndrome.

According to the topography of the process, the following are distinguished: intracapillary forms; extracapillary forms.

According to the nature of the inflammation, there can be exudative, proliferative or mixed forms of glomerulonephritis.

Based on the prevalence of the inflammatory process in the glomeruli, diffuse and focal glomerulonephritis are distinguished.

Morphological changes in the kidneys with glomerulonephritis are observed not only in the glomeruli, but also in other structural elements, so glomerulonephritis is distinguished: with a tubular component; with a tubulo-interstitial component; with a tubulo-interstitial-vascular component.

Acute (post-streptococcal, bacterial) glomerulonephritis is a common disease in children, less common in adults. The cause of the disease is nephritogenic strains of  $\beta$ -hemolytic streptococcus group A, especially serological types 1, 4, 12 and 49. The primary infection manifests itself in the form of sore throat, pharyngitis, otitis. Pathogenesis is associated with circulating immune complexes. The duration of the disease is 10, 12 months. Glomerulonephritis begins acutely. In the first days of the disease, glomerular hyperemia with infiltration of the mesangium and capillaries by neutrophils occurs. Later, proliferation of endothelial and mesangial cells occurs. Fibrinoid necrosis with thrombosis of glomerular capillaries is sometimes involved. Macroscopically, the kidneys are slightly enlarged, the capsule is easily removed, the pyramids are dark red, bark is gray-brown with small hemorrhages on the surface (trout kidney). When using anti-inflammatory and



immunosuppressive therapy, 95% of patients recover within 6 weeks, kidney function normalizes within 1 year. Sometimes kidney failure develops quickly or turns into chronic glomerulonephritis.

Subacute (rapidly progressive) glomerulonephritis develops in connection with damage to the glomeruli by both circulating immune complexes and antibodies. In 40% of cases, rapidly progressive glomerulonephritis is associated with systemic diseases, in 60% - primary kidney damage. Clinically, renal failure, malignant arterial hypertension, edema, and proteinuria develop. Subacute glomerulonephritis is characterized by the proliferation of the epithelium of the glomerulus capsule (nephrothelium), podocytes and macrophages, which proliferate in response to fibrin effusion, as a result of which hemilocal formations appear (extracapillary productive glomerulonephritis). Crescents can occupy only separate segments of the cavity of the glomerular capsule or completely surround it. Necrosis occurs in the capillaries of the glomerulus, fibrin thrombi are formed. Sclerosis, hyalinosis of the glomeruli quickly follows, leading to kidney failure (malignant glomerulonephritis). The kidneys are enlarged, flabby, the cortical layer is dull, yellow-gray, with a red spot and is well separated from the dark red medulla (big kidney).

Chronic glomerulonephritis is an independent disease, possibly with a latent or relapsing course, lasting for many years and ending in chronic renal failure. The cause of chronic glomerulonephritis is unknown, its mechanism is associated in most cases with circulating immune complexes. There are two morphological varieties - mesangial and fibroplastic. Depending on the degree of severity and nature of changes in the mesangium and the walls of the glomerular capillaries, mesangioproliferative and mesangiocapillary variants of glomerulonephritis are distinguished.

The clinical course of mesangioproliferative glomerulonephritis is relatively benign; proliferation of mesangiocytes without significant changes in capillary walls is noted. Mesangiocapillary glomerulonephritis is characterized by a significant proliferation of mesangiocytes and diffuse damage to the membranes of glomerular capillaries.

Fibroplastic glomerulonephritis is a collective form in which sclerosis and hyalinosis of capillary loops, adhesions in the capsule cavity complete the changes characteristic of other forms of nephritis. Diffuse fibroplastic glomerulonephritis is characterized by significant dystrophic and atrophic changes in the tubules, sclerosis of the renal stroma and vessels.

Chronic glomerulonephritis evolves into secondary shrunken kidneys. The size of the kidneys decreases, they are compacted, the surface is fine-grained. At autopsy, the cortex is unevenly thin, the boundary between the cortex and the medulla is unclear, the kidney tissue is dry, gray. Microscopic examination reveals a decrease in the number of nephrons, diffuse sclerosis of the glomeruli, some of which turn into hyalinized balls (glomerulohyalinosis). The ducts atrophy, some sometimes dilate and fill with pink protein material ("thyroidization").

Extrarenal changes in glomerulonephritis occur in the heart (hypertrophy of the left ventricle in connection with arterial hypertension); in arteries (atherosclerosis, elastofibrosis); arterioles of the brain, heart, retina, etc. (arteriolosclerosis).

Acute renal failure can be a complication of acute and subacute glomerulonephritis. The chronic course is characterized by chronic renal failure with manifestations of azotemic uremia. Cardiovascular failure or brain hemorrhage are also possible.

Nephrotic syndrome is characterized by high proteinuria, dysproteinemia, hypoproteinemia, hyperlipidemia, edema; hematuria, hypertension and azotemia are absent.

Primary nephrotic syndrome is represented by the following diseases: lipoid, nephrosis, membranous nephropathy, focal segmental sclerosis.

Lipoid or idiopathic nephrosis most often develops in children under the age of 8 (80%) and rarely in adults. Boys get sick more often. This ailment is known by the name lipoid nephritis, because fats are often found in the tubular cells.

In this disease, the filtration barrier for anionic plasma molecules (albumins) weakens, so glomerular disease with minimal changes is

characterized by "selective" proteinuria. The cause of the chemical changes in the membrane is unknown. In some patients, the disease develops after respiratory infections and preventive vaccinations.

With global microscopy, no changes can be traced, only with electron microscopy, the fusion of podocyte processes is revealed. During remission, these changes disappear. The basal membrane is unchanged, there is no reaction of glomerular cells, immune complexes are not detected in the glomeruli. Kidneys with lipoid nephrosis are sharply enlarged, flabby, the capsule is easily removed. The cortical layer is wide, pale gray, the pyramids are gray-red ("big white" kidneys). The prognosis in children is favorable, in adults the development of nephrosclerosis and chronic renal failure is possible.

Membranous glomerulonephritis - (membranous nephropathy). The disease is characterized by a chronic course, nephrotic syndrome or only proteinuria, a characteristic diffuse thickening of the walls of glomerular capillaries due to the neoplasm of the basement membrane substance by podocytes without signs of proliferation and inflammation. It is determined in the form of membrane growths towards podocytes between deposits of immune complexes. Membranous glomerulonephritis is found in all age groups, but it is more common to get sick at the age of around 35 years. Men are affected more often. Proteinuria is non-selective, hematuria is mostly absent, hypertension is observed in half of the patients. In most patients, the disease progresses slowly with the development of CKD. The prognosis is better in women and even better in children.

Tubulopathies.

Acute renal failure. This syndrome is morphologically characterized by necrosis of the epithelium of tubules and deep disorders of renal blood and lymph flow. Acute renal failure (ARF) is equated with necrotic nephrosis and has a cyclical course.

The main causes of its development are ischemia and toxic damage, infections, poisoning with salts of heavy metals, acids, alcohols, drugs, sulfonamides; traumatic injuries, extensive burns, hemolysis, dehydration, dechlorination, severe infections (cholera, typhoid, diphtheria, sepsis) and as a

complication of other diseases.

The development of ARF is associated with mechanisms of shock of any etiology - traumatic, toxic, hemolytic, bacterial. But in the development of dystrophy and necrosis of tubules, the effect on the epithelium of toxic substances circulating in the blood plays a major role.

The appearance of the kidneys, regardless of the stage, is the same: enlarged, swollen, the fibrous capsule is tense, easily removed. The pale gray cortical layer is sharply separated from the dark red pyramids, in the intermediate zone of the kidney there are hemorrhages.

In the initial stage – sharp venous congestion of the intermediate zone and pyramids with focal ischemia of the cortical layer. The epithelium of tubules is in a state of hyaline-droplet, vacuolar or fatty dystrophy. The lumen of the tubules is unevenly expanded, contains cylinders, myoglobin crystals. In the oligo-anuric stage, there are necrotic changes in the tubules of the main sections, which may be accompanied by a rupture of the basement membrane (tubulorhexis). In the stage of restoration of diuresis - the glomeruli are full of blood, swelling decreases. Necrotized tubules, the membrane of which is preserved, regenerate completely. When the basement membrane is destroyed, connective tissue grows on the membrane of the dead nephron.

Complications of ARF: segmental or total necrosis of the cortical substance of the kidneys. Result: recovery with hemodialysis treatment. Sometimes: death from uremia, cicatricial shrinkage of the kidneys and death from chronic renal failure.

Chronic tubulopathy.

This includes "myeloma kidney" and "gouty kidney". At the heart of the changes characteristic of a myeloma kidney are paraproteinemic nephrosis, which develops as a result of clogging of tubules by proteins - paraproteins.

Kidney damage in gout occurs due to the high content of uric acid in the blood. Uric acid crystallizes in an acidic environment, which is observed in the distal tubules, collecting tubules, and papillary interstitium. Crystals in the lumen of tubules are the cause of chronic obstruction and tubulointerstitial nephritis in the cortex, which leads to its atrophy.

Pyelonephritis is an infectious disease with predominant damage to the interstitial tissue, as well as the calyces and bowls of the kidney. It can be unilateral and bilateral, acute and chronic, the latter has a recurrent course in the form of attacks of acute pyelonephritis.

Infection of the kidneys can occur by a hematogenous (descending) or urinogenic (ascending) route. Hematogenous spread of infection occurs - with infectious endocarditis or bacteremia from other sources. The causative agents of infection can be bacteria, fungi, and viruses. Most often, pyelonephritis develops as a result of the upward spread of infection - *Escherichia coli*, *Proteus*, *Enterobacter*, etc.

With acute pyelonephritis, the kidneys are enlarged, areas of suppuration (abscesses) are found in the cortex. Inflammation of the cups and bowls can also be observed, which is accompanied by the accumulation of pus in the lumen of the bowls. Histological examination reveals polymorphonuclear leukocytes in the lumen of the tubules, swelling and inflammation of the interstitium.

Changes in kidney tissue in chronic pyelonephritis are focal in nature: areas of intermediate inflammation, atrophy, and sclerosis are surrounded by relatively preserved kidney tissue, in which signs of regenerative hypertrophy can be found. This ability of the process determines the characteristic appearance of the kidneys in chronic pyelonephritis: the sizes of the kidneys are not the same, their surface is large-bumpy, on the section, fields of scar tissue are found, which alternate with relatively preserved renal parenchyma; bowls are expanded, their walls are thickened, whitish.

In the end of chronic pyelonephritis, a pyelonephritic shrunken kidney develops. At the same time, uneven scar wrinkles, the formation of dense adhesions between the kidney tissue and the capsule, and asymmetry of the process in both kidneys are characteristic. These signs, although relative, make it possible to distinguish pyelonephritic nephrosclerosis from nephrosclerosis and nephrocirrhosis of other etiology.

In acute pyelonephritis, the progression of the purulent process leads to the fusion of large abscesses and the formation of a carbuncle of the kidney, the

connection of purulent cavities with the bowl (pyonephrosis), the transition of the process to the fibrous capsule (perinephritis) and perirenal tissue (paranephritis). Acute pyelonephritis can be complicated by necrosis of the papillae of the pyramids (papillonecrosis), which develops as a result of the toxic effect of bacteria in conditions of urinary stasis. This complication of pyelonephritis occurs more often in patients with diabetes. Sometimes pyelonephritis becomes a source of sepsis. When the purulent process is limited during the scarring period, chronic kidney abscesses may form. With chronic pyelonephritis, especially unilateral, the development of nephrogenic arterial hypertension and arteriolosclerosis in the second (unchanged) kidney is possible.

In acute pyelonephritis, recovery is usually the result. Serious complications (pyonephrosis, sepsis, papillonecrosis) can be the cause of death. Chronic pyelonephritis with shrinkage of the kidneys often ends with azotemic uremia. With the development of nephrogenic arterial hypertension, the fatal outcome is sometimes associated with those complications that occur in hypertensive disease (hemorrhage in the brain, myocardial infarction, etc.)

Kidney stone disease (nephrolithiasis) is a disease in which stones of different sizes, structures, and chemical composition (phosphates, urates, oxalates, carbonates, etc.) are formed in the kidney cups and ureters. The disease has a chronic course; one or both kidneys are involved in the process.

The formation of stones in the kidneys and urinary tract is insufficiently studied, hereditary and acquired disorders of mineral metabolism (calcium, phosphorus, uric acid, oxalic acid) and acid-alkaline state (development of acidosis), the nature of nutrition (predominance of carbohydrates and animal proteins in food), mineral composition of drinking water (endemic nephrolithiasis), as well as vitamin deficiency (vitaminosis A). The local factors of stone formation include those that can change the physical and chemical state of urine and thereby contribute to the precipitation of salts from it. Inflammatory processes in the urinary tract and urinary stasis play an important role. These factors can lead to an increase in the concentration of salts in the urine, a change in the pH and colloidal balance of the urine, and the formation

of a colloidal (protein) base of the stone. Of great importance in the development of nephrolithiasis are trophic and motor disorders of the function of the cups,

Changes in nephrolithiasis are extremely diverse and depend on the localization of stones, their size, the age of the process, the presence of infection, etc.

A kidney stone that disrupts the outflow of urine leads to pyeloectasia, and later to hydronephrosis with atrophy of the renal parenchyma; the kidney turns into a thin-walled bag filled with urine. If the stone is in the calyx, then impaired outflow from it leads to the expansion of only this calyx - hydrocalycosis, and only part of the renal parenchyma undergoes atrophy. A stone that obstructs the ureter causes expansion of both the bowl and the cavity of the ureter above the obstruction - hydroureteronephrosis. At the same time, inflammation of the wall of the ureter occurs - ureteritis, which can lead to strictures; occasionally a pressure ulcer with perforation of the ureter is formed at the site of its obstruction.

Joining the infection dramatically changes the morphological picture of nephrolithiasis. When infected, calculous hydronephrosis (hydroureteronephrosis) becomes pyonephrosis (pyoureteronephrosis). The infection leads to the development of pyelitis, pyelonephritis, apostematous (purulent) nephritis, and purulent melting of the parenchyma. Inflammation often spreads to the perirenal tissue, leading to chronic paranephritis. In such cases, the kidney is encased in a thick capsule of granulation, fatty and fibrous tissue (armor paranephritis), and sometimes it is completely replaced by sclerosed fatty tissue (fatty replacement of the kidney).

A complication of urolithiasis, and the most frequent, is pyelonephritis. Especially dangerous are pyonephrosis and purulent melting of the kidney, which in some cases ends in sepsis. Acute renal failure is rare. With a long course of kidney stone disease, atrophy, fibrous and fatty replacement of the kidneys, chronic kidney failure develops.

The death of patients with nephrolithiasis most often occurs from uremia and complications associated with purulent melting of the kidneys.

Polycystic kidney disease is a hereditary disease of the kidneys with bilateral cystosis, part of the relatively developed parenchyma of tubules and collecting tubes.

Polycystic kidney disease in children is inherited according to the autosomal recessive type; Polycystic kidney disease in adults is autosomal dominant. The development of polycystic kidney disease is associated with embryogenesis disorders in the first weeks, which is accompanied by the formation of glomerular, tubular and excretory cysts. Glomerular cysts do not have a connection with renal tubules, which determines the early development of renal failure. Tubular cysts, formed from tubules, excretory cysts arising from collecting tubes, slowly increase due to difficulty in emptying them, and can reach large sizes. Cysts squeeze the renal parenchyma, in which atrophic, sclerotic and inflammatory processes occur. The cyst wall thins and sometimes ruptures, which contributes to the maintenance of inflammation in the kidney parenchyma. It should be noted that the earlier polycystosis is detected, the more malignant it runs. Usually, the disease is asymptomatic for a long time.

Polycystic kidneys look more like a bunch of grapes. Their tissue consists of many cysts of different sizes and shapes, filled with serous fluid, colloidal masses, or semi-liquid contents of chocolate color. Sometimes a shriveled vascular glomerulus is found in the cyst wall. The kidney tissue between the cysts is atrophied. It is often associated with polycystic liver, pancreas and ovaries.

The most common complications are pyelonephritis, cyst suppuration; occasionally a tumor (cancer) develops in the cyst wall.

The prognosis for polycystic kidney disease is unfavorable. Patients die from progressive renal failure and azotemic uremia.

Nephrosclerosis - compaction and deformation (shrinking) of the kidneys due to the development of connective tissue.

The causes of nephrosclerosis are diverse. In hypertensive disease and symptomatic hypertension, vascular changes lead to the development of arteriosclerotic nephrosclerosis (nephrocirrhosis) or primary kidney shrinkage (primarily shrunken kidneys); in atherosclerosis, atherosclerotic nephrosclerosis



(nephrocirrhosis) occurs. Sclerosis and shrinkage of the kidneys can also develop secondarily, as a result of inflammatory and dystrophic changes in the glomeruli, tubules and stroma - secondary shrinkage of the kidneys, or secondarily - shrunken kidneys. Most often, secondary kidney shrinkage is a consequence of chronic glomerulonephritis (secondary nephrotic shrinkage, kidneys), less often - pyelonephritis (pyelonephritic shrinkage of the kidney or kidney), amyloid nephrosis (amyloid shrinkage of the kidney, or amyloid-shrunken kidneys), kidney stone disease, tuberculosis of the kidneys, diabetic glomerulosclerosis, kidney infarctions, etc. Nephrosclerosis (nephrocirrhosis) of any etiology leads to the development of chronic kidney failure.

Two phases can be distinguished in the patho- and morphogenesis of nephrosclerosis: the first (nosological) and the second (syndromic). In the first phase, sclerosis of the kidneys is due to the peculiarities of the patho- and morphogenesis of the disease, in which nephrosclerosis develops. In the second phase, the pathomorphological clinical and morphological features of the nosology are smoothed out, and sometimes they are lost, the syndrome of chronic renal failure becomes the leading one. Nephrosclerosis in the first phase, which covers the period before the formation of a block of renal blood flow, at one of the structural levels of the kidney (arteriolar, glomerular, interstitial), is a component of the morphological manifestations of the main disease. Its nosological specificity is determined by the predominant involvement of one of the structural elements of the kidney (arterioles, glomeruli interstitium) in the sclerotic process, as well as the qualitative features of sclerotic changes in the kidney. In the second phase, nephrosclerosis is associated with the formation of a renal blood flow block at the level of one or another structure (arteriolar, glomerular, capillary-parenchymal block), which includes the factor of hypoxia, which determines the further progress of nephrosclerosis. All structural elements of the kidney undergo sclerosis to an equal extent, due to which the morphological signs of nosology are smoothed out.

With nephrosclerosis, the kidneys are dense, their surface is uneven, large or small bumpy; structural rearrangement of kidney tissue is observed. When

clarifying the origin and type of nephrosclerosis, the nature of the shrinkage (fine-grained - in hypertension and glomerulonephritis, large-grained - in atherosclerosis, pyelonephritis, amyloidosis) and the process that is the basis of nephrosclerosis are important

Chronic renal failure is a syndrome whose morphological basis is nephrosclerosis (shrunken kidneys), and the most striking clinical manifestation is uremia. The occurrence of uremia is explained by an increase in the concentration of nitrogenous impurities in the blood (urea, uric acid, creatinine), acidosis, and profound electrolyte imbalance. These shifts in protein and electrolyte metabolism, as well as the acid-alkaline state, lead to autointoxication and profound disruption of cellular metabolism.

The smell of urine is felt during the autopsy of the corpse of a person who died from uremia.

The skin has an earthy gray hue as a result of the accumulation of urochrome. Sometimes, especially on the face, it is as if powdered with a whitish powder (chlorides, crystals of urea and uric acid), which is caused by hypersecretion of sweat glands. Rashes and hemorrhages are often observed on the skin as an expression of hemorrhagic diathesis. Uremic laryngitis, tracheitis, and pneumonia are observed, which are often fibrinous-necrotic or fibrinous-hemorrhagic in nature. Fatty dystrophy occurs in the liver. Polyserositis, pharyngitis, gastritis, catarrhal, fibrinous or fibrinous-hemorrhagic enterocolitis are also found.

Very often serous, serous-fibrinous pericarditis, uremic myocarditis is detected; less often, warty endocarditis. The development of uremic pleurisy and peritonitis is possible. The brain in uremia is pale and swollen, sometimes there are foci of softening and hemorrhage. The spleen is enlarged, resembling a septic one.

Uremia develops not only with chronic, but also with acute renal failure. It is also observed in eclampsia (eclamptic uremia) and chlorohydropenia (chlorhydropenic uremia).

In connection with the use of regular hemodialysis, chronic renal failure can last for many years, while patients are in a state of chronic suburemia. In

such cases, the pathological anatomy of uremia becomes different. Exudative-necrotic changes recede into the background. Metabolic damage (myocardial necrosis), productive inflammation (adhesive pericarditis, obliteration of the pericardial sac cavity), bone changes (osteoporosis), amyloidosis and endocrine system (parathyroid hyperplasia) dominate. Atrophy and sclerosis of the kidneys reach an extreme degree (kidney weight 20–25 g).

Kidney tumors. Epithelial kidney tumors include: adenoma (dark cell, clear cell, acidophilic) and renal cell (hypernephroid) cancer (clear cell, granular cell, glandular, sarcoma-like, mixed cell), as well as nephroblastoma, or Wilms' tumor. Renal cell carcinoma accounts for 90% of all kidney tumors in adults, and nephroblastoma accounts for 20% of all malignant tumors in children.

Mesenchymal kidney tumors are rare: they are benign and malignant tumors from connective and muscle tissue, from blood and lymphatic vessels.

A large group consists of tumors of the kidney bowls, although they are many times less common than kidney tumors. Among the benign tumors of the pelvis, transitional cell papilloma, which can be solitary or multiple, is often found.

Pelvic cancer is more common after papilloma. According to histological structure, it can be transitional cell and glandular (adenocarcinoma). Transitional cell cancer is more common than others. It has a papillary structure, is often subject to necrosis, in connection with which inflammation develops. The tumor grows through the wall of the bowl, spreads to the surrounding tissue (fiber), into the ureter and bladder.

**Materials on the activation of students of higher education during the lecture: questions, situational tasks, etc(*if necessary*):**

**General material and bulk-methodological support of the lecture:**

## Questions for self-control:

1. The main renal syndromes (nephrotic syndrome, nephritic syndrome, asymptomatic hematuria or proteinuria, acute renal failure, chronic renal failure, etc.)
2. The main mechanisms of damage to glomeruli: immune and non-immune.
3. Acute glomerulonephritis. Definition, basic principles of classification, causes of occurrence and development
4. Acute poststreptococcal glomerulonephritis. Morphological characteristics (macroscopic and microscopic changes). The results.
5. Rapidly progressing (semi-monthly) glomerulonephritis. Morphological characteristics (macroscopic and microscopic changes). The results.
6. Membranous glomerulonephritis (MGN). Morphological characteristics.
7. Membranoproliferative glomerulonephritis (MPGN). Morphological characteristics.
8. Minimal change disease (MCD) (Lipoid nephrosis). Morphological characteristics.
9. Chronic glomerulonephritis (CGN). Morphological characteristics (macroscopic and microscopic changes). The results.
10. Acute renal failure, causes of its development. Morphological characteristics (macroscopic and microscopic changes). The results.
11. Acute tubular necrosis: ischemic and nephrotoxic. Morphological characteristics (macroscopic and microscopic changes). The results.
12. Stages of acute tubular necrosis. Morphological characteristics.
13. Tubulointerstitial disease. Morphological characteristics (macroscopic and microscopic changes). The results.
14. Pyelonephritis (acute and chronic). Morphological characteristics (macroscopic and microscopic changes). The results.
15. Urinary stones and nephrolithiasis. Types of urinary calculi. Morphological characteristics. Complications.
16. Hydronephrosis. Definition. Morphological characteristics.
17. Cystic kidney disease.
18. Chronic kidney failure. Nephrosclerosis as a morphological basis of chronic kidney disease.

## References:

### Main:

1. Atlas of micropreparations in pathomorphology / I.I. Starchenko, B.M. Filenko, N.V. Royko, etc.; VDZU "UMSA". - Poltava, 2018. - 190 p
2. Starchenko, S.O. Bilokon and others.. – Poltava: Tov. "ASMI" - 2018. - 190 p.
3. Fundamentals of pathology according to Robbins: in 2 volumes. Volume 1 / Vinay Kumar, Abul K. Abbas, John C. Astaire; translation of the 10th Eng. edition.

Publisher: All-Ukrainian specialized publishing house "Medytsyna". – X II. - 2019. - 420 p.

4. Fundamentals of pathology according to Robbins: in 2 volumes. Volume 1 / Vinay Kumar, Abul K. Abbas, John C. Astaire; translation of the 10th Eng. edition.

Publisher: All-Ukrainian specialized publishing house "Medytsyna". – X II. - 2019. - 420 p.

5. Pathomorphology. General pathomorphology: a study guide / edited by Ya. Ya. Bodnara, V.D. Voloshina, A.M. Romanyuk, V.V. Gargin. - New Book, 2020. - 248 p.

6. Pathomorphology of the main diseases of the cardiovascular system: study guide / I.I. Starchenko, B.M. Filenko, N.V. Royko – Poltava: "UMSA". - 2019. - 150 p.

7. Starchenko I.I. Pathomorphology of the main diseases of the maxillofacial region: academician. manual / I.I. Starchenko, B.M. Filenko, V.V. Chernyak ; "UMSA". – Vinnytsia: Nova Kniga, 2019. – 128 p.

8. Ctarchenko I.I. Special pathomorphology (basic course) for students of medical faculties of higher medical educational institutions of III-IV levels of accreditation / II Starchenko, N.V. Royko, B.M. Filenko. – Poltava, 2017. – 174 p.

9. Tuffaha S. A. Muin Immunohistochemistry in the diagnosis of tumors / S. A. Tuffaha Muin, S. G. Hychka, Husky Hans. - "Book Plus", 2018. - 336 p.

10. Essentials of pathology: textbook / Ya. Bodnar, A. Romanyuk, V. Voloshyn, V. Gargin - Kharkiv, "Planeta-Print" Ltd, 2020, 219 p.

11. Pathology: textbook / IVSorokina, VD Markovskiy, DI Halata et al.; edited by IVSorokina, VD Markovskiy, DI Halata. - Kyiv: AUS Medicine Publishing, 2019. - 328p. + 2 color inserts (8p. + 12p.).

12. Pathology: textbook / IVSorokina, VD Markovskiy, DI Halata et al.; edited by IVSorokina, VD Markovskiy, DI Halata. - 2nd edition. - Kyiv: AUS Medicine Publishing, 2020. - 328p. + 2 color inserts (8p. + 12p.).

#### Additional:

1. Benign neoplasms of bones of the maxillofacial area in children / P.I.

Tkachenko, I.I. Starenko, S.O. Bilokin [and others] - P.: "UMSA", 2016. - 85 p

2. General pathomorphology / I.I. Starchenko, N.V. Royko, B.M. Filenko [et al.] – Poltava, 2016. – 136 p.

3. Zerbino D. D. Pathomorphology and histology: atlas / D. D. Zerbino, M. M. Bagriy, Y. Ya. Bodnar, V. A. Dibrova. – Vinnytsia: Nova Kniga, 2016. – 800 p.

4. Methods of morphological research / M.M. Baghrii, V.A. Dibrova, O.G.

Papadynets, M.I. Grischuk; edited by M.M. Baghria, V.A. Dibrovyy – Vinnytsia: Nova Kniga, 2016. – 328 p.

5. Novoseltseva T.V. Pathology of sexual and endocrine systems / T.V. Novoseltseva, B.M. Filenko, N.I. Hasiuk - Poltava: LLC "ASMI", 2015. - 199 p.

6. Pathomorphology: national. / V.D. Markovskiy, V.O. Tumanskyi, I.V. Sorokina [and others]; edited by V.D. Markovsky, V.O. Tumanskyi. - K.: VSV "Medicine", 2015. - 936p.

7. Practicum on biopsy section course / I.I. Starchenko, A.P. Hasyuk, S.A. Proskurnya

[etc.] – Poltava, 2016. – 160 p.

## Lecture No. 12

**Topic:** Hypothalamic-pituitary disorders. Adrenal gland pathology. Pathology of the thyroid gland. Pathology of the endocrine apparatus of the pancreas.

**Actuality of theme:** Hypothalamic-pituitary disorders, pituitary dwarfism. Pathology of the adrenal glands, Pathology of the thyroid gland, endemic goiter, Pathology of the endocrine apparatus of the pancreas.

**Goal:** To understand how and thanks to which systems the stability of the body is regulated, the causes and types of diseases associated with hypothalamic-pituitary regulation disorders, diseases with pathologies of such glands as: thyroid, pancreatic and endocrine apparatus.

**Basic concepts:** Cerebro-pituitary cachexia, Sheehan syndrome, and hypogonadal dystrophy, microsomia, N blood sugar and c diabetes mellitus, insulin-dependent and non-insulin-dependent diabetes, goiter, toretinism, hyperparathyroidism, hyperadrenalism, hyperaldosteronism, Waterhouse syndrome, bronze disease, pheochromoblastoma.

### Plan and organizational structure of the lecture:

Greetings, verification of those present, announcement of the topic, purpose of the lesson, motivation of higher education seekers to study the topic.

### Content of lecture material (lecture text)

Cell homeostasis is regulated by the nervous and endocrine systems integrated through the hypothalamus. The latter modulates the activity of the pituitary gland and neuroendocrine cells common in the body, which are part of the so-called APUD system.

The function of the endocrine glands is controlled by the interaction of stimulating and inhibitory hormones produced in the hypothalamus (pituitary gland) and by means of a feedback mechanism (peripheral endocrine glands that are under the control of the pituitary gland).

The pituitary gland consists of two lobes, which differ in embryogenesis, morphology and function.

The anterior lobe of the pituitary gland (adenohypophysis) is made of

secretory epithelial cells. According to the features of staining the cytoplasm of cells with hematoxylin and eosin, they are divided into three types: acidophiles, basophils (chromophiles) and chromophores. Immunohistochemically, using monoclonal antibodies, five types of cells producing tropic hormones can be detected: 1) somatotropes (produce growth hormone); 2) mammatropics (prolactin producing) - acidophilus; 3) melanocorticotropes (precursor of ACTH, etc.); 4) thyrotropes (produce thyroid-stimulating hormone); 5) gonadotropes (produce follicle-stimulating and luteinizing hormone) - basophils. Chromophobes, cells with weakly stained cytoplasm, contain a small number of secretory granules, so it is difficult to determine hormones in them by the immunohistochemical method.

The posterior lobe of the pituitary gland (neurohypophysis) consists of intertwined unmyelinated nerve fibers that contain secretory granules filled with the hormones vasopressin, or antidiuretic hormone (ADH), and oxytocin. These hormones are synthesized in the supraoptic and paraventricular nuclei of the hypothalamus and are transported along nerve fibers to the posterior lobe of the pituitary gland.

Hormonally active diseases of the anterior lobe of the pituitary gland are divided into two large groups: with hyperpituitarism - hormonally active tumors of the anterior lobe, and diseases accompanied by hypopituitarism.

Hyperpituitarism.

Acromegaly. The reason for the development of this disease is hypothalamic-pituitary disorders or somatotropic (usually eosinophilic) adenoma, occasionally adenocarcinoma of the anterior lobe of the pituitary gland. An excess of somatotropic hormone stimulates the growth of tissues, mainly derived from mesenchyme: connective, cartilage, bone, as well as parenchyma and stroma of internal organs (heart, liver, kidneys), etc. An especially noticeable increase in the size of the nose, lips, ears, eyebrow arches, lower jaw, bones and feet. The growth of bones is combined with their reconstruction, restoration of enchondral osteogenesis. If the disease develops at a young age, gigantism occurs. Acromegaly is accompanied by changes in other endocrine glands, goiter, hyperplasia of the thymus and pineal gland,

adrenal cortex, and atrophy of the gonads. These changes have corresponding clinical manifestations.

Itsenko-Cushing's disease. This disease is associated with the development of hypothalamic disorders or with adrenocorticotrophic (usually basophilic) adenoma, less often – adenocarcinoma of the anterior lobe of the pituitary gland. Due to the hypersecretion of ACTH, bilateral hyperplasia of the adrenal cortex occurs mainly due to the bundle zone with excessive production of glucocorticosteroids (cortisol), which plays the main role in the pathogenesis of the disease. The specific mechanism of action of excess cortisol is carried out through the effect on protein metabolism by increasing the catabolism of proteins and increasing lipolysis in connection with the blockade of glycolysis and the violation of the use of glucose by tissues (increasing the level of free fatty acids in the blood). The disease occurs more often in women, is manifested by progressive dysplastic obesity of the upper type (face and trunk), arterial hypertension, hypertrophy of the myocardium of the left ventricle, fatty dystrophy of the liver, muscat cirrhosis of the liver, steroid diabetes and secondary ovarian dysfunction. Osteoporosis with spontaneous bone fractures, hypertrichosis and hirsutism, purplish-blue stretch marks (stretch marks) on the skin of the thighs and abdomen are also characteristic. Nephrolithiasis and chronic pyelonephritis are often detected.

#### Hypopituitarism.

Cerebro-pituitary cachexia (Symonds disease, panhypopituitarism). It manifests itself in increasing cachexia, atrophy of internal organs, decreased function of the gonads. It is observed mainly in women at a young age and often after childbirth (Sheehan's syndrome). In the pituitary gland, especially in the anterior lobe, there are centers of necrosis that appear on the ground of vascular embolism, or a scar at the site of these centers. In a number of cases, the destruction of the anterior lobe of the pituitary gland is associated with a syphilitic, tubercular or tumor process. In addition to changes in the pituitary gland, dystrophic changes in the diencephalon are noted. Sometimes changes in the brain prevail over changes in the pituitary gland. In such cases, we are talking about cerebral cachexia. Deficiency of tropic hormones of the pituitary



gland causes a sharp decrease in the function of peripheral endocrine glands. Failure of the gonadotropic function of the pituitary gland is the cause of ovarian failure, amenorrhea, atrophy of the uterus, vagina, and mammary glands. Thyrotropin deficiency causes the development of pituitary myxedema. Chronic insufficiency of the cortex of the adrenal glands is the result of a decrease in cortisol production.

Sheehan's disease (Sheehan's syndrome). Postpartum hypopituitarism. It is characterized by insufficient function of the adenohypophysis and partially the thyroid gland, adrenal glands, and gonads.

It develops as a result of acute ischemia of the anterior lobe of the pituitary gland during uterine bleeding or shock. During pregnancy, the pituitary gland almost doubles in size, squeezing the blood vessels that supply it. A sudden systemic decrease in blood pressure leads to spasm of blood vessels with subsequent necrosis of most or all of the anterior lobe of the pituitary gland. At the same time, the posterior lobe remains intact, as it is less sensitive to anoxia.

Other pathogenetic mechanisms may be involved in the development of Sheehan's disease, such as disseminated intravascular coagulation or (rarely) sickle cell anemia, cavernous sinus thrombosis, temporal arteritis, or traumatic vascular injury. The risk of developing Sheehan's syndrome increases in patients with diabetes for a long time.

The adenohypophysis is soft, pale, ischemic or with hemorrhages during pathological examination. The ischemic zone eventually dissolves and is replaced by fibrous tissue. Weight loss, dryness and pallor of the skin, tendency to swelling, skin depigmentation, brittleness and hair loss are determined. Atrophy of mammary glands. Decreased sexual function. In some cases, the clinic of hypothyroidism comes to the fore, in others, insufficiency of the adrenal cortex.

Unlike Symonds' hypothalamic-pituitary cachexia, Sheehan's disease is not characterized by sharp exhaustion and severe metabolic and trophic disorders.

Adiposogenital dystrophy (Pehkrantz–Babinsky–Frelich disease).

The disease is characterized by obesity and hypogonadism. Occurs in teenagers. Genital hypoplasia is detected earlier in boys than in girls. If the disease develops in adults on the basis of trauma, inflammation or tumor and is accompanied by obesity and secondary genital atrophy, we should talk about hypothalamic syndrome.

The main role in etiology belongs to tumors; dystrophic changes in the hypothalamus, intrauterine encephalitis, syphilis, birth trauma, infectious and traumatic brain injuries in the post-embryonic period are important.

A pathogenetic connection with damage to the hypothalamic-pituitary region is revealed, and changes in the pituitary gland, according to most researchers, are often secondary. Insufficient secretion of follicle-stimulating and luteinizing hormones causes hypogonadism. Against the background of a decrease in the production of these hormones, there is a relatively excessive secretion of luteotropic hormone, which in conditions of damage to the trophic centers of the hypothalamus (responsible for the mobilization of fat from adipose tissue) and hyperinsulism (a decrease in the secretion of THG and ACTH) contributes to the development of obesity.

Insufficient secretion of THG causes growth retardation in children with adiposogenital dystrophy. Hypogonadism develops, obesity with a predominant accumulation of fat in the area of the mammary glands, back, lower abdomen, pelvis and hips of the "breeches" type, growth retardation, increased tolerance to carbohydrates, and a tendency to hypoglycemia. Children's mental development usually corresponds to their age.

Pituitary dwarfism (pituitary dwarfism, microsomia) is a disease characterized by dwarfism (in men up to 130 cm, in women up to 120 cm) due to an absolute or relative deficiency of somatotropin. Slowing or stopping growth can be an independent disease or a symptom of another disease. Among the causes of pituitary dwarfism are a genetic defect in the synthesis of somatotropin, infection, intoxication, injuries in the prenatal period, a vascular or tumor process localized in the hypothalamic-pituitary region, birth craniocerebral trauma (in childbirth, short-term strong compression and sudden decompression of the skull (especially in the presentation of the buttocks) cause

significant tension and possible damage to the pituitary stalk). In the development of secondary dwarfism as a symptom of any disease, chronic infections are important, intoxication (tuberculosis, helminthiasis, etc.), poor nutrition. A genetic defect with a deficiency of somatotropin often causes delayed growth of the skeleton and its age-related differentiation, impaired growth and development of all organs and tissues (microsomia). Pathological examination reveals atrophic and dystrophic processes in the adenohypophysis, as well as hypoplasia of the peripheral endocrine glands (gonadal, thyroid, adrenal cortex). Late appearance of ossification centers and late ossification of epiphyseal cartilages, reduction of the size of internal organs are noted. The physique remains proportional throughout life, the skin in childhood is thin and delicate, in adults it is pale and wrinkled, with a yellowish tint. Due to the children's structure of the larynx, the voice in adults remains high. The muscular system is underdeveloped, muscle strength is reduced in the joint due to a decrease in the anabolic effect of somatotropin and androgens. The hair on the head is thin, sparse, there is no hair on other areas.

Intelligence usually does not suffer, but rapid physical and mental fatigue is noted. The psyche of patients is very vulnerable, frequent neurotic disorders. Genital organs are underdeveloped, patients are incapable of sexual life.

Damage to the neurohypophysis.

Diabetes insipidus. The disease occurs when the posterior lobe of the pituitary gland is damaged (tumor, inflammation, necrosis, trauma). It develops at any age and is usually benign. Along with damage to the posterior lobe of the pituitary gland, there are constant changes in the diencephalon. It manifests itself in non-diabetic urination, which is associated with the elimination of the function of the antidiuretic hormone and the loss of the ability of the kidneys to concentrate urine, which causes the release of a large amount of urine (polyuria) and increased thirst (polydipsia). Severe consequences of diabetes insipidus are associated with water loss and mineral metabolism disorders. In children, the first symptom of the disease may be enuresis. A feature of the course of diabetes insipidus in childhood is a delay in physical and sexual development, which is caused by damage to the hypothalamus.

## Diseases of the insular apparatus of the pancreas

Diabetes mellitus is a disease caused by an absolute or relative lack of insulin, which causes the development of chronic hyperglycemia. It is the cause of serious violations of all types of metabolism, but primarily carbohydrate metabolism.

### Classification of diabetes mellitus:

#### A. Primary diabetes.

Insulin-dependent diabetes mellitus - type 1 usually develops before the age of 30; occurs much less frequently than type 2 diabetes. Damage mechanism  $\beta$ - cells associated with autoantibodies; at the same time, immune inflammation occurs in the islets of Langerhans of the pancreas - insulinitis. Hereditary predisposition and viral infection (which triggers the autoimmune process) are important in development. The disease is caused by an absolute lack of insulin; without replenishing insulin, hyperglycemia, polyuria, weight loss, ketoacidosis, and coma occur, which is the cause of death. Ketoacidosis develops as a result of increased catabolism of lipids with the production of "ketone bodies".

Non-insulin-dependent diabetes mellitus - type 2 occurs much more often than type 1 diabetes; usually develops in middle age; development is associated with either an increase in cell resistance to insulin, due to a decrease in the number of cell receptors for insulin (or post-receptor dysfunction), or a violation of the transformation of proinsulin into insulin, a decrease in sensitivity  $\beta$ -cells to insulin or a violation of the function of intracellular transport proteins. Family predisposition (genetically determined), general obesity is important in development. The concentration of insulin in the plasma is normal, often elevated; hyperglycemia is usually corrected by diet, taking antidiabetic drugs. No insulin is required. Ketoacidosis is not characteristic; its occurrence is usually associated with infectious diseases and surgical interventions.

B. Secondary diabetes is caused by other conditions and syndromes: it develops secondary to various diseases of the pancreas (idiopathic hemochromatosis ("bronze diabetes"), pancreatitis, cancer, as well as Cushing's

disease or syndrome, acromegaly, pregnancy, etc.).

The morphology of diabetes consists of changes not only in the pancreas itself, but also in other organs as a result of metabolic disorders. But of these changes, diabetic angiopathy is the most important.

The pancreas is reduced, dense, on cross-section it is represented by masses of whitish connective tissue and growths of adipose tissue - lipomatosis (characteristic of type 2 diabetes).

Type 1 diabetes is characterized by numerous small islands with sclerosis and lymphocytic infiltration (insulinitis); number  $\beta$ -cells are reduced, their denaturation is noted; type 2 diabetes is characterized by sclerosis (hyalinosis) and islet amyloidosis (deposition of amylin - islet amyloid polypeptide),  $\beta$ - cells are small, degranulated; preserved islets may be hypertrophied.

Diabetic macroangiopathy has the morphology of atherosclerosis, which occurs in vessels of elastic and muscle-elastic types. Diabetes is a risk factor for the development of atherosclerosis; atherosclerotic complications in diabetes appear at a much younger age.

Diabetic microangiopathy occurs in arterioles and capillaries as a result of plasmatic impregnation and is represented by hyalinosis, often with proliferation of endothelium and perithelium; has a generalized character: it is found in the kidneys, retina, skin, skeletal muscles, pancreas, brain, peripheral nervous system, etc. Specific diabetic glomerulosclerosis develops in the kidneys, which is clinically manifested by the Kimelstiel-Wilson syndrome, which is accompanied by high proteinuria, edema, arterial hypertension, and eventually uremia develops.

Kidneys are reduced, dense, fine-grained. According to the microscopic changes, two forms are distinguished: a) in the nodular (nodular) form, focal clusters of eosinophilic hyaline masses appear in the glomerular mesangium; b) in the diffuse form, diffuse thickening of the basal membranes of glomerular capillaries and expansion of the mesangium is noted. The process is better revealed when using the SHIK reaction.

In the epithelium of the renal tubules (Henle's loop) - glycogen infiltration.

Electron microscopic examination reveals an accumulation of membrane-like substance in the mesangium. Basal membranes of capillaries are thickened, proliferation of mesangial cells is noted.

In the retina of the eye, retinopathy with the development of edema, hemorrhages, microaneurysm of vessels is noted; blindness may develop.

Fatty hepatosis develops in the liver with diabetes; in the nuclei of hepatocytes – vacuolization due to the accumulation of glycogen.

In the skin – xanthelasma (focal clusters of xanthoma cells), lipid necrobiosis.

Gallbladder - the risk of stone formation increases sharply.

Complications of diabetes are associated with the possible development of diabetic coma; in connection with macro- and microangiopathy, gangrene of the lower extremities and other complications (loss of vision, etc.) often occur; with the progression of diabetic glomerulosclerosis - chronic renal failure.

Characteristic infectious complications: purulent pyoderma, furunculosis, purulent pyelonephritis, septicopyemia, bronchopneumonia, candidiasis, tuberculosis.

Diseases of the thyroid gland

Diseases of the thyroid gland can be accompanied by hyperthyroidism and hypothyroidism. An increase in the size of the gland, visible during examination of the patient or determined by palpation, is called a goiter. Goiter can be accompanied by an increase or decrease in the function of the thyroid gland. Sometimes with goiter, the function of the thyroid gland is not changed (euthyroid goiter).

Goitre (current):

A) Congenital, i.e. associated with genetic defects (enzymopathies) of thyroid hormone metabolism (synthesis, secretion, transport, reception).

B) Associated with iodine deficiency in food.

B) Associated with autoimmune mechanisms.

D) Physiological (during puberty and during pregnancy).

D) The reason may remain unknown.

The function of the thyroid gland in goiter may: a) not change (euthyroid,

non-toxic, simple goiter); b) increase (hyperthyroid, toxic goiter); c) decrease (hypothyroid goiter): in adults it is accompanied by the development of myxedema, in children - cretinism and impaired physical development.

Myxedema occurs in adolescents or adults. Clinical manifestations depend on the age at which hormone deficiency was detected. In adults, the disease develops slowly, and years may pass before the clinical picture develops. Myxedema is characterized by slowing down of physical and mental activity. The initial symptoms of myxedema are increased fatigue, drowsiness, cold intolerance, general lethargy and apathy. Language slows down, intelligence is reduced. Over time, periorbital edema develops. The skin is thickened, dry, rough. With severe myxedema, the heart is sluggish, enlarged, and the chambers are dilated. Microscopically, swelling of cardiomyocytes with disappearance of striations is observed. At the same time, the content of interstitial fluid, rich in glycosaminoglycans, increases. Such a liquid sometimes accumulates in the pericardial cavity. These changes are called myxedematous heart, or hypothyroid cardiomyopathy. It is also possible to slow down the growth of the skeleton and the development of the central nervous system.

Cretinism. A rare disease, characterized by a violation of both physical and intellectual development. Cretinism is rarely immediately apparent at birth. Usually, the diagnosis can be made a few weeks or months after birth. Over time, changes become absolutely obvious, usually they are irreversible. With this disease, the skin becomes dry and rough, the eyes are widely spaced, periorbital edema, a wide flat nose, and a large bulging tongue are characteristic. If a deficiency of thyroid hormones is detected in the early period of fetal development, it may be associated with a pronounced iodine deficiency, agenesis of the thyroid gland or a congenital defect in hormone synthesis, skeletal growth disorders and delayed brain development are observed. Endemic cretinism develops with endemic goiter and is usually associated with the lack of iodine in food. On the contrary, sporadic cretinism is more often caused by congenital abnormalities of the development of the thyroid gland or defects in the synthesis of thyroid hormones.

Morphological classification of goiter:

A) According to the macroscopic appearance: nodular goiter (nodular hyperplasia); diffuse goiter (diffuse hyperplasia); mixed zob.

B) According to the microscopic structure: colloid goiter: macrofollicular, microfollicular, macromicrofollicular, proliferating; parenchymal goiter.

Congenital goiter is characterized by nodular or diffuse (rarely) hyperplasia; microscopically, it has a solid-trabecular (parenchymal goiter) or microfollicular structure; accompanied by hypothyroidism.

Endemic goiter develops in residents of certain geographic areas; associated with iodine deficiency in food; iodine deficiency causes a decrease in the synthesis of thyroid hormones, an increase in the synthesis of thyroid-stimulating hormone of the pituitary gland and the development of hyperplasia. A significant amount of colloid accumulates inside the stretched follicles, which leads to atrophy of the epithelium. The insufficient function of the follicular epithelium is compensated by an increase in the mass of the gland; function is usually euthyroid, hypothyroidism may be noted.

Nodular goiter: the gland is enlarged, its mass can reach 250 g, the consistency is dense, the surface is nodular; cavities of different sizes filled with brownish-yellow colloidal contents are determined on the section.

Microscopically, the gland consists of follicles of a rounded shape, many of them are cystically stretched, filled with oxyphilic thick colloid, which turns crimson in the case of the SHIK reaction. The epithelium in follicles and cysts is flattened.

Sporadic goiter: cause unknown; arises out of connection with endemic areas, but in terms of morphological manifestations and functional state it is identical to endemic goiter.

Macroscopically, this is a nodular goiter. Microscopically, it has a macro- or microfollicular structure, the function of the gland is usually not changed, but hypothyroidism can be observed in rare cases.

Diffuse toxic goiter (Basedow's disease or Graves' disease) is the most common cause of hyperthyroidism (thyrotoxicosis): an autoimmune disease associated with the appearance of thyroid-stimulating immunoglobulin and



thyroid growth immunoglobulin - IgG - autoantibodies that react with different domains of receptors of the follicular epithelium to thyroid-stimulating hormone, which leads to an increase in the synthesis of thyroid-stimulating hormones and to the proliferation of the epithelium, to an increase in the gland; young women get sick more often.

Clinical manifestations: goiter, exophthalmos, tachycardia, nervousness, weight loss, sweating.

Macroscopically, the gland is enlarged 2–4 times, the tissue is juicy, homogeneous, gray-red. Microscopically, follicles of different sizes and irregular shapes are found. The epithelium is high, proliferating, forming papillae. The colloid in the follicles is liquid, vacuolated. In the stroma there is a cluster of lymphoid elements.

In connection with thyrotoxicosis, a thyrotoxic heart develops, which is characterized by: hypertrophy, serous edema, lymphoid infiltration of the stroma, swelling of cardiomyocytes. Diffuse interstitial sclerosis develops as a result of this process; serous edema occurs in the liver, sometimes leading to fibrosis; death can occur from heart failure, exhaustion, acute adrenal insufficiency (during goitre removal surgery).

According to etiology, thyroiditis is divided into:

A. Infectious (non-specific, associated with bacteria and fungi, tuberculous).

B. Autoimmunity (Hashimoto's thyroiditis, Riedel's fibrous thyroiditis)

B. Caused by physical factors: radiation, traumatic.

D. Of unknown etiology: subacute (giant cell granulomatous) de Quervain thyroiditis.

During the course:

A. Acute thyroiditis (abscesses): of infectious origin; are more often caused by staphylococci, streptococci, as well as gram-negative microorganisms; characteristic infiltration by polymorphonuclear leukocytes, dystrophic and necrotic changes.

B. Subacute (granulomatous) de Quervain's thyroiditis: the etiology is unknown (a viral infection initiates the process); middle-aged women get sick

more often; macroscopically, the gland is enlarged (2 times or more), dense, not fused with the surrounding tissues; microscopically, granulomatosis with giant cells is detected (colloid may be detected in the cytoplasm).

#### V. Chronic thyroiditis: Hashimoto's and Riedel's.

Hashimoto's thyroiditis (autoimmune thyroiditis, lymphomatous current) refers to chronic thyroiditis; one of the most common causes of hypothyroidism; more common in women; an autoimmune disease caused by several antithyroid autoantibodies (the most important ones are to thyroglobulin and microsomes of the follicular epithelium); can be combined with other autoimmune diseases (type 1 diabetes, Sjögren's disease, pernicious anemia, etc.); characterized by slow development with gradual enlargement of the thyroid gland and a long euthyroid period.

Microscopically, dense lymphocytic infiltration with the formation of follicles with light centers is determined in the gland; epithelial follicles atrophy. In the end, the thyroid gland shrinks and becomes sclerosed, which is accompanied by the development of hypothyroidism and myxedema.

Riedel's fibrous thyroiditis (Riedel's goiter) is characterized by the replacement of glandular tissue by fibrous tissue; the thyroid gland is very dense ("iron goiter"), fused with the surrounding tissues; compression of the trachea can cause breathing difficulties; accompanied by hypothyroidism.

#### Diseases of the parathyroid glands

Parathyroid glands develop from the third and fourth gill arches in close connection with the thymus; four small glands are located at the upper and lower poles of the thyroid gland. During surgical intervention on the thyroid gland, it should be remembered that agenesis of one or two glands or their atypical location is relatively often observed. Parathyroid glands consist of chief cells, the cytoplasm of which, when stained with hematoxylin-eosin, has a color from pale to dark pink, depending on the glycogen content. They also contain lipofuscin and secretory granules. The chief cell is the main source of parathyroid hormone. Oxyphilic cells are found in small numbers, they are larger than the main ones, have acidophilic cytoplasm, in which glycogen granules are found, they have little or no secretory granules. In early childhood,

single fat cells appear in the parathyroid glands; by the age of 25, adipose tissue makes up to 35% of the volume of the glands.

All diseases of the parathyroid glands are divided into two large groups depending on their effect on the function of the glands - hyperparathyroidism and hypoparathyroidism. Hyperparathyroidism is divided into primary, which develops as a result of damage to the gland itself and is accompanied by autonomous hypersecretion of parathyroid hormone, which leads to hypercalcemia and hypophosphatemia, and secondary, associated with increased production of parathyroid hormone, but only in response to some diseases that cause hypocalcemia .

Primary hyperparathyroidism is characterized by changes in the parathyroid glands, which are accompanied by an increase in the secretion of parathyroid hormone and, as a result, the development of hypercalcemia and hypophosphatemia. The most common cause of primary hyperparathyroidism is adenomas, their percentage reaches 80%. The second most frequent cause (10-15%) is primary hyperplasia of the parathyroid glands. Carcinomas account for less than 5%.

Secondary hyperparathyroidism. It is most often found in patients with renal failure (uraemic hyperparathyroidism), as well as in severe vitamin D deficiency and osteomalacia.

Pathological-anatomical changes in secondary hyperparathyroidism are the same as in primary hyperplasia. Usually all glands are affected, rarely one, two or even three. As with the primary disease, hyperplasia can be diffuse or nodular and affect mainly chief cells interspersed with areas of clear watery and oxyphilic cells. The amount of fat usually decreases or the adipose tissue is replaced by hyperplastic cells. As with primary hyperparathyroidism, metastatic calcification may develop.

Manifestations of hyperparathyroidism are diverse, the most characteristic are the following: kidney damage due to the formation of stones and calcification of the renal parenchyma due to an excess of calcium in the urine. The resulting kidney failure is the most serious complication of hyperparathyroidism; resorption of calcium from bones leads to the

development of osteoporosis and fibrocystic osteitis, which threatens the occurrence of pathological fractures. Hypercalcemia causes the accumulation of calcium salts in internal organs (metastatic calcification), this complication is more pronounced in secondary hyperparathyroidism; changes from the gastrointestinal tract include anorexia, nausea, peptic ulcers; characteristic neurological and neuromuscular manifestations (lethargy, weakness, convulsions, memory loss); eye damage is characterized by the development of cataracts and corneal calcifications.

Hypoparathyroidism. There are a number of possible causes of hypoparathyroid hormone secretion that cause hypocalcemia. The main ones are the following: erroneous removal of all glands during thyroidectomy, removal of parathyroid glands by mistake instead of lymph nodes during radical neck surgery for some forms of malignant tumors, removal of a very large part of the parathyroid gland during the treatment of primary hyperparathyroidism (removal of three glands in a patient who additional 4th gland is absent); congenital absence of all glands in Di Giorgi syndrome, autoimmune disease - polyglanduloautoimmune syndrome with simultaneous insufficiency of adrenal glands and ovaries, mucocutaneous candidiasis, pernicious anemia; rare hereditary syndromes; syndromes,

Hypoparathyroidism, which has developed acutely, is accompanied by a sharp drop in the level of calcium in the blood serum and an increase in neuromuscular excitability, which leads to tetanic convulsions; death may occur as a result of laryngospasm. With long-term hypoparathyroidism, in addition to tetany, hypercalcification of bones, cataracts, and hypoplasia of teeth develop due to defective formation of the enamel matrix and nail abnormalities.

Diseases of the adrenal glands.

Mineralocorticosteroids (aldosterone), glucocorticosteroids and sex hormones are formed in the cortex of the adrenal glands, the secretion of which is controlled by the adrenocorticotrophic hormone of the anterior lobe of the pituitary gland. Strengthening of the trophic effects of the pituitary gland or the development of a hormonally active tumor of the cortex of the adrenal glands leads to their hyperfunction, and the weakening of these effects or the

destruction of the cortex of the adrenal glands leads to their hypofunction. The secretion of hormones of the medulla of the adrenal glands (adrenaline, norepinephrine) is stimulated by the sympathetic nervous system. Hypofunction is well compensated by chromaffin tissue, hyperfunction is associated with a tumor (pheochromocytoma).

Diseases of the cortical substance of the adrenal glands.

Hyperfunction of the cortical substance of the adrenal glands (hyperadrenalism).

There are three main hyperadrenal syndromes: Cushing's syndrome, characterized by hyperproduction of cortisol; hyperaldosteronism; adrenogenital syndromes associated with hyperproduction of androgens.

1. Cushing's syndrome is characterized by the production of excessive amounts of cortisol, so the disease is also characterized as hypercortisolism. Most of its manifestations are directly related to an excessive amount of cortisol, but some of them, for example, hirsutism, acne and menstrual cycle disorders, may reflect hypersecretion of androgens at the same time.

2. Primary hyperaldosteronism is a small group of closely related, relatively rare syndromes characterized by chronic excessive secretion of aldosterone independent of the renin-angiotensin system. The production of renin-angiotensin increases under the influence of renal ischemia or any chronic edematous condition, while the secretion of aldosterone increases secondarily (secondary hyperaldosteronism). Primary hyperaldosteronism is characterized by inhibition of plasma renin activity, hypokalemia, sodium retention, and hypertension. The causes of primary hyperaldosteronism are as follows: the presence of a solitary adenoma secreting aldosterone (Kon's syndrome) - about 65% of cases; bilateral idiopathic hyperplasia of the adrenal glands - about 30% of cases; the result of the suppressive action of glucocorticoids; carcinoma of the cortical substance of the adrenal glands; familial variant of non-glucocorticoid suppression. Aldosterone-producing adenomas are almost always solitary, small (up to 2 cm in diameter), encapsulated, and are more often found in the left adrenal gland. They usually occur in women in the 4th-5th decade of life. On section, adenomas are light yellow in color and consist of cells

containing lipids. All cells have the same size and shape, resemble mature cells of the cortical substance, although nuclear polymorphism is usually observed.

3. Adrenogenital syndrome, as a rule, appears in childhood, often from birth, sometimes in adults with an androgen-producing tumor of the adrenal glands. Two forms of this syndrome are most common: simple virilizing and lacremic. With the virilizing form, an excess of testosterone leads to the virilization of the fetus. In girls, there is an increase in the clitoris, an increase and fusion of the labia majora (pseudohermaphroditism), in boys - macrogenitosomia. In the future, in the absence of treatment, acceleration of growth, excessive development of muscles is noted. Skeletal maturation also accelerates, so such patients stop growing early. Early male hair growth is observed, girls do not have menstruation.

Hypofunction of the cortical substance of the adrenal glands (hypocorticism). It can be primary, that is, caused by any anatomical or metabolic damage to the cortical substance, disrupting the release of cortical steroids, or secondary, in relation to ACTH deficiency. Primary cortical insufficiency can be acute (adrenal crisis) or chronic (Addison's disease).

Causes of primary insufficiency of the cortical substance: autoimmune damage, infections, bilateral adrenalectomy, tumor metastases, amyloidosis, hemochromatosis, sarcoidosis, hemorrhages in the adrenal glands, congenital hypoplasia, medicinal inhibition of ACTH synthesis.

Waterhouse-Friedrichsen syndrome is a rare but catastrophic syndrome in severe septic infection with rapidly progressive hypotension leading to shock and CVD syndrome with massive bilateral adrenal hemorrhage. The adrenal glands turn into bags filled with clotted blood. Hemorrhages occur first in the medulla due to the presence of thin-walled venous sinuses there, and then spread to the cortex.

Nelson's syndrome is a disease characterized by the occurrence and progression of an ACTH-secreting macroadenoma of the pituitary gland in patients who have undergone bilateral adrenalectomy (adrenalectomy) for Cushing's syndrome. An extremely high level of ACTH in the plasma and the intensive growth of a tumor - basophilic adenoma of the pituitary gland - arise

in connection with a pronounced decrease in the production of steroid hormones in the adrenal gland and is explained by the exclusion of negative feedback, which regulates the mechanism of normal functioning of the hypothalamic-pituitary-adrenal system. Manifested by hyperpigmentation, compression of the oculomotor nerve, neurological disorders.

Primary chronic insufficiency of the cortical substance of the adrenal glands.

Addison's disease (bronze disease). The disease is caused by bilateral damage mainly to the cortical substance of the adrenal glands and the exclusion (acorticism) or decrease (hypoadrenocorticism) of the production of its hormones. The most common cause of bronze disease is tumor metastases in both adrenal glands, autoimmune damage (primary Addison's disease), amyloidosis (epinephric amyloidosis), hemorrhage, necrosis due to vascular thrombosis, tuberculosis. In some cases, the disease is caused by disturbances in the hypothalamic-pituitary system (decrease in the secretion of ACTH or cortico-releasing factor) or is hereditary.

In Addison's disease, hyperpigmentation of the skin (melanoderma) and mucous membranes is found due to hyperproduction of ACTH and melanostimulating hormone, myocardial atrophy, and a decrease in the lumen of the aorta and main vessels. Adaptive hyperplasia of the cells of the islet apparatus of the pancreas (hypoglycemia), atrophy of the mucous membrane of the stomach, especially the lining cells, is revealed. Hyperplasia of lymphoid tissue and thymus is also found.

Death in Addison's disease occurs from acute adrenal insufficiency, cachexia (suprarenal cachexia), or cardiovascular failure.

Diseases of the medulla of the adrenal glands.

The brain substance of the adrenal glands consists of specialized nerve cells (neuroendocrine), it is the main source of catecholamines.

The most significant diseases of the medulla of the adrenal glands are tumors - pheochromocytomas, neuroblastomas, ganglioneuromas and their variants.

Benign tumor of the medulla of the adrenal glands - pheochromocytoma -

a hormonally active tumor, usually unilateral, gray-red or brown on section. It is made of polymorphic cells with light cytoplasm (cells of chromaffin tissue), which secrete a large amount of catecholamines, which causes an increase in blood pressure and a number of other disorders.

Malignant tumor of the medulla of the adrenal glands - malignant pheochromocytoma (malignant pheochromoblastoma) - differs in pronounced cellular atypism, is extremely rare.

The dominant clinical feature of pheochromocytoma is hypertension. Changes in the heart are called catecholamine cardiomyopathy, associated with myocardial ischemia after vasospasm caused by catecholamines. Areas of myocytosis, interstitial fibrosis, and sometimes an inflammatory infiltrate of mononuclear leukocytes are microscopically determined.

**Materials on the activation of students of higher education during the lecture: questions, situational tasks, etc(*if necessary*):**

**General material and bulk-methodological support of the lecture:**

**Questions for self-control:**

**References:**

Main:

1. Atlas of micropreparations in pathomorphology / I.I. Starchenko, B.M. Filenko, N.V. Royko, etc.; VDZU "UMSA". - Poltava, 2018. - 190 p
2. Starchenko, S.O. Bilokon and others.. – Poltava: Tov. "ASMI" - 2018. - 190 p.
3. Fundamentals of pathology according to Robbins: in 2 volumes. Volume 1 / Vinay Kumar, Abul K. Abbas, John C. Astaire; translation of the 10th Eng. edition. Publisher: All-Ukrainian specialized publishing house "Medytsyna". – X II. - 2019. - 420 p.
4. Fundamentals of pathology according to Robbins: in 2 volumes. Volume 1 / Vinay Kumar, Abul K. Abbas, John C. Astaire; translation of the 10th Eng. edition.



Publisher: All-Ukrainian specialized publishing house "Medytsyna". – X II. - 2019. - 420 p.

5. Pathomorphology. General pathomorphology: a study guide / edited by Ya. Ya. Bodnara, V.D. Voloshina, A.M. Romanyuk, V.V. Gargin. - New Book, 2020. - 248 p.

6. Pathomorphology of the main diseases of the cardiovascular system: study guide / I.I. Starchenko, B.M. Filenko, N.V. Royko – Poltava: "UMSA". - 2019. - 150 p.

7. Starchenko I.I. Pathomorphology of the main diseases of the maxillofacial region: academician. manual / I.I. Starchenko, B.M. Filenko, V.V. Chernyak ; "UMSA". – Vinnytsia: Nova Kniga, 2019. – 128 p.

8. Starchenko I.I. Special pathomorphology (basic course) for students of medical faculties of higher medical educational institutions of III-IV levels of accreditation / I.I. Starchenko, N.V. Royko, B.M. Filenko. – Poltava, 2017. – 174 p.

9. Tuffaha S. A. Muin Immunohistochemistry in the diagnosis of tumors / S. A. Tuffaha Muin, S. G. Hychka, Husky Hans. - "Book Plus", 2018. - 336 p.

10. Essentials of pathology: textbook / Ya. Bodnar, A. Romanyuk, V. Voloshyn, V. Gargin - Kharkiv, "Planeta-Print" Ltd, 2020, 219 p.

11. Pathology: textbook / IVSorokina, VD Markovskiy, DI Halata et al.; edited by IVSorokina, VD Markovskiy, DI Halata. - Kyiv: AUS Medicine Publishing, 2019. - 328p. + 2 color inserts (8p. + 12p.).

12. Pathology: textbook / IVSorokina, VD Markovskiy, DI Halata et al.; edited by IVSorokina, VD Markovskiy, DI Halata. - 2nd edition. - Kyiv: AUS Medicine Publishing, 2020. - 328p. + 2 color inserts (8p. + 12p.).

#### Additional:

1. Benign neoplasms of bones of the maxillofacial area in children / P.I. Tkachenko, I.I. Starenko, S.O. Bilokin [and others] - P.: "UMSA", 2016. - 85 p

2. General pathomorphology / I.I. Starchenko, N.V. Royko, B.M. Filenko [et al.] – Poltava, 2016. – 136 p.

3. Zerbino D. D. Pathomorphology and histology: atlas / D. D. Zerbino, M. M. Bagriy, Y. Ya. Bodnar, V. A. Dibrova. – Vinnytsia: Nova Kniga, 2016. – 800 p.

4. Methods of morphological research / M.M. Baghrii, V.A. Dibrova, O.G. Papadynets, M.I. Grischuk; edited by M.M. Baghria, V.A. Dibrovyy – Vinnytsia: Nova Kniga, 2016. – 328 p.

5. Novoseltseva T.V. Pathology of sexual and endocrine systems / T.V. Novoseltseva, B.M. Filenko, N.I. Hasiuk - Poltava: LLC "ASMI", 2015. - 199 p.

6. Pathomorphology: national. / V.D. Markovskiy, V.O. Tumanskyi, I.V. Sorokina [and others]; edited by V.D. Markovsky, V.O. Tumanskyi. - K.: VSV "Medicine", 2015. - 936p.

7. Practicum on biopsy section course / I.I. Starchenko, A.P. Hasyuk, S.A. Proskurnya [etc.] – Poltava, 2016. – 160 p.

**Topic:** AND infectious and parasitic diseases. Characteristics of the infectious process. Intestinal infectious diseases. Viral airborne infections. Corona virus disease. HIV infection. Rabies. Rickettsioses. Prion infections. Tuberculosis.

**Actuality of theme:** Infectious and parasitic diseases. Infectious eye diseases such as viral conjunctivitis. Characteristics of the infectious process. Intestinal infectious diseases. Viral airborne infections. HIV infection. Rabies. Rickettsioses. Prion infections. Tuberculosis, etc.

**Goal:** Understand the ways of infection, be able to characterize these diseases, stages and problems of these diseases. Know the possible sources of infection with these infections, the stages and problems of the diseases they cause, and the protection with the help of which it is possible to mimic or completely avoid these diseases.

**Basic concepts:** Typhoid, with salmonellosis, yersiniosis enterocolitis, ARVI, parainfluenza and adenovirus infection, pericardial syndyctial infection, pectus excavatus, epidemic typhus, endemic typhus, AIDS, HIV, with Kaposi's sarcoma, with scrofula tuberculosis, fibrous-focal tuberculosis, tuberculema, M. tuberculosis, fibrous-cavernous tuberculosis.

#### **Plan and organizational structure of the lecture:**

Greetings, verification of those present, announcement of the topic, purpose of the lesson, motivation of higher education seekers to study the topic.

#### **Content of lecture material (lecture text)**

Diseases caused by infectious agents - viruses, bacteria, fungi - are called infectious. When simple worms are introduced into the body, they talk about invasive diseases. Some infectious diseases have now been eliminated, many, especially viral ones, still pose a significant threat to the population. In addition, there are still endemic foci of a number of infectious diseases that can easily be transferred to other countries at the speed inherent in modern means of transportation. The infectious process is very complex, and its development is determined by the characteristics of the pathogen, such as the reactive state of the microorganism.

Features of a microorganism, the causative agent of an infectious disease, are determined not only by its structure, chemical structure, antigenic

properties, but also by the nature of interaction with the host's organism. The result of this interaction largely depends on the state of the body's phagocytic (neutrophils and monocyte phagocytes) and immune systems, especially the humoral system immunity

The coexistence of micro- and macroorganism can be of 3 types: 1) symbiosis - coexistence of a microbe and a macroorganism for the benefit of each (for example, *Escherichia coli* in the intestine); 2) commensalism (from the French commensal – fellow diner), in which the microbe and the macroorganism do not interact with each other; 3) parasitism – the life of a microbe at the expense of a macroorganism, which leads to the development of a disease. Under the influence of various exogenous and endogenous factors, the relationship between the micro- and macroorganism can be disrupted in favor of the microorganism, which acquires pathogenic properties. Under these conditions, an indifferent commensal, or harmless symbiont, becomes a parasite and causes disease. Such situations arise during treatment with many drugs, but primarily with antibiotics; which disrupt the stable balance of the microbial flora.

Most pathogens enter the human body from the external environment through entrance gates, for example, through the intestines with food, through the lungs with air, through insect bites, through damaged skin or mucous membranes, etc. In such cases, they speak of an exogenous infection.

However, the infection can be endogenous, then it is an endogenous infection, or autoinfection.

Different infectious agents cause different tissue reactions, which is especially evident in bacterial and viral infections. Bacteria, having penetrated into tissues, usually cause inflammation. Viruses, subordinating the cells of the host to the mechanism of their reproduction (reproduction), can lead to dystrophy and necrosis of cells, as well as to their proliferation and transformation; the reaction is largely secondary.

During the infectious process, regardless of the nature of the causative agent, immune reactions appear aimed at the destruction and elimination of the infection. Antibodies circulating in the blood are formed in response to

antigenic stimulation of the immune system. The combination of an antigen with an antibody in the presence of complement has an antimicrobial and antitoxic effect, provides post-infectious humoral immunity. At the same time, long-term antigenic action in infectious diseases leads to sensitization of the body, the appearance of hypersensitivity reactions, both immediate and delayed (allergic reactions). From this it follows that tissue damage in infectious diseases can develop not only under the influence of infection, but also in connection with hypersensitivity reactions.

Infectious diseases are characterized by a number of common features:

Each infectious disease has its pathogen, which is found in the patient's blood or excreta.

The causative agent of an infectious disease has an entrance gate characteristic of each infection.

With an infectious disease, the formation of a primary affect (cell) is observed, which usually appears in the entrance gate. The primary affect is the focus of inflammation. In the case of lymphogenic spread of infection, inflammation of both draining lymphatic vessels (lymphangitis) and regional lymph nodes (lymphadenitis) occurs. The combination of primary affect, lymphangitis and lymphadenitis in an infectious disease allows us to talk about a primary infectious complex. In some infections, it is determined (tuberculosis), in others, the process immediately takes on a generalized character (rash and reverse typhus, malaria).

4.) the way of spread of infection from the primary site or complex can be lymphogenic, hematogenous, intracanalicular, perineural or contact.

Each infectious disease is characterized by local changes that develop in a certain tissue or organ (in the large intestine in dysentery, in the cells of the anterior horns of the spinal cord in poliomyelitis, in the walls of small vessels in typhoid fever) and to one degree or another are typical for this disease.

In infectious diseases, a number of general changes develop: skin rashes, vasculitis, hyperplastic processes in lymph nodes, spleen, bone marrow, inflammatory processes in interstitial tissue and dystrophic changes in parenchymal organs.

Infectious disease often has a cyclical nature. In its course, incubation, prodromal periods and the period of the main manifestations of the disease (phases of increasing symptoms of the disease, flare-up and its fading) are distinguished. An infectious disease can end in recovery, acquire a chronic course, and be the cause of bacillus carriage. Very often it is accompanied by various complications that can cause death.

Infectious diseases are classified according to several characteristics.

By biological feature: 1) anthroponoses – infectious diseases found only in humans; 2) anthroozoonoses – infectious diseases that occur in humans and animals; 3) biocenoses – a group of anthroponoses and anthroozoonoses transmitted through insect bites, which are the breeding ground of the causative agent. According to the etiological sign: 1) viral infections; 2) year-ketsios; 3) bacterial infections; 4) fungal; 5) protozoan; 6) parasitic. Infections can be exogenous or endogenous.

According to the mechanism of transmission: 1) intestinal infections that occur when the infection enters the digestive tract through the mouth; 2) respiratory tract infections transmitted by airborne droplets; 3) "blood infections" (transmissible), transmitted through blood-sucking arthropods; 4) infections of the outer coverings, tissue and muscles of the body (infection occurs through the action of some infected factors of the external environment; trauma with an infected object); 5) infections with different mechanisms of transmission.

According to the nature of clinical and anatomical manifestations, infections with a predominant lesion are distinguished: 1) covers (skin and its appendages, external mucous membranes), tissue and muscles of the body; 2) respiratory tract; 3) digestive tract; 4) nervous system; 5) cardiovascular system; 6) the blood system and other tissues of the body's internal environment; 7) genitourinary tract.

According to the nature of the course, infections are distinguished: 1) acute; 2) chronic; 3) latent (hidden); 4) slow.

Typhoid fever is an acute infectious disease, a classic intestinal infection, a typical anthroponosis.

It is caused by the typhoid bacillus (*Salmonella typhi*). The source of infection is a sick person or a bacillus carrier whose secretions (feces, urine, sweat) contain microbes. Infection occurs when the pathogen enters the digestive tract through the mouth. The incubation period is 10–14 days. In the lower intestine, bacilli multiply and release endotoxins. From the intestine, along the lymphatic pathways, they enter group lymphatic follicles, and then regional nodes. Having passed the lymphatic barrier, the pathogen enters the blood. Bacteremia develops, especially clearly expressed during the first Sunday when the typhoid bacillus can be isolated from the blood (hemoculture). Bacteremia is associated with the generalization of infection and the development of immunity. Starting from the second Sunday, antibodies are detected in the blood with the help of an agglutination reaction. 3 bacteremia is associated with the elimination of the causative agent, which is released from the second Sunday with sweat, urine, feces, bile. Further reproduction takes place in bile (bacteriocholia) and group lymphatic and solitary follicles. This reaction ends with necrosis of the lymphatic apparatus of the small intestine.

Local changes occur in the mucous membrane and lymphatic apparatus of group lymphatic and solitary intestinal follicles. In those cases, when they increase, they protrude above the surface of the follicles in the small intestine - they speak of iliomyphus, in the large intestine - colomyphus, in the small and large intestines - about iliokolomyphus. The most characteristic changes are found in the plaques of the long intestine - iliomyphus. Changes occur in 5 stages (periods): brain swelling, necrosis, formation of ulcers, clean ulcers and healing. Each stage takes about a week of illness.

The first stage is characterized by a medullary swelling of group follicles, furrows and convolutions are formed on their surface, which resembles the surface of the brain, they are juicy, red in section. Most of the proliferating cells, especially monocytes, turn into macrophages that phagocytose typhoid bacilli and are called typhoid cells. These cells go beyond the group follicles and the mucous membrane, penetrate the muscle layer and sometimes reach the serous cover. Accumulations of these cells form typhoid granulomas.

Similar changes occur in solitary follicles. Cerebral swelling in group and

solitary follicles is associated with the phenomena of catarrhal enteritis.

The second stage is necrosis of group follicles, which is based on necrosis of typhoid granulomas. Necrosis begins in the surface layers of group follicles, gradually deepens, sometimes reaching the muscle layer and peritoneum. Around - demarcation inflammation. The dead tissue of the plaques acquires a greenish color. The same changes are observed in solitary follicles.

The third stage is the formation of ulcers as a result of sequestration and rejection of necrotic masses. Ulcers appear in the lower segment of the long intestine, then in the upper sections.

The fourth stage is the stage of pure ulcers, which have a characteristic appearance: they are located along the length of the intestine, the edges are even, rounded, the bottom is formed by a muscle layer, less often by a serous membrane. In this stage, there is a great danger of perforation of the intestinal wall.

The fifth stage is the healing of ulcers from the appearance of a number of scars. The tissue of the plaque is partially or completely restored and becomes only slightly pigmented. You can simultaneously see the compatibility of two or three stages. The more proximally placed the changes, the "younger" they are. The stage of typhoid fever is judged by the oldest changes in the lower part of the long intestine.

In the lymph nodes of the mesentery, especially in the ileocecal angle, changes are noted, which develop in the same sequence as in the lymphatic apparatus of the intestine.

General changes in typhoid fever have signs that are typical only for it, as well as typical for any infectious disease.

The former include rashes, the formation of typhoid granulomas in various organs, and the latter include hyperplastic processes in organs of the lymphatic system and dystrophic changes in parenchymal organs.

Typhoid rashes appear on the 7-11th day on the skin of the body, on the abdomen. They have a roseolous-papular character, disappear when pressed. In the papillary layer - hyperemia of vessels, inflammatory infiltrates, the epidermis is loosened with phenomena of hyperkeratosis.

Proliferation of monocytes and histiocytes occurs in the spleen, lymph nodes, bone marrow, gall bladder, and kidneys.

The spleen is enlarged 3–4 times, the capsule is tense, dark red in color, and the scraping of the pulp is enlarged. Dystrophic changes were found in the myocardium, liver, and kidneys, and cholecystitis in some cases.

Among the intestinal complications, the most frequent and dangerous are intestinal bleeding and ulcer perforation. Bleeding occurs in the third week and can be fatal. Perforation of the ulcer leads to peritonitis.

Among extraintestinal complications, the most important are: pneumonia, purulent perichondritis of the larynx, waxy necrosis of rectus: abdominal muscles, osteomyelitis, intramuscular abscesses.

Death of patients occurs from complications.

Salmonellosis is an intestinal infection caused by salmonella. They belong to anthroozoonoses.

Pathogenesis is determined by the characteristics of the causative agent, the amount of endotoxins released when salmonella breaks down in the intestine. The route of transmission is food.

There are three forms of salmonellosis: intestinal, (toxic) septic, typhoid.

The intestinal form develops with food poisoning, it is characterized by a picture of acute gastroenteritis, which leads to severe dehydration of the body (domestic cholera). The septic form is distinguished by the fact that with minor changes in the small intestine (hyperemia, edema, hyperplasia of the lymphatic system) there is hematogenous generalization of the causative agent with the formation of metastatic abscesses in many organs (lungs, brain).

The typhoid form (paratyphoid A and B according to the old terminology) resembles typhoid fever. Changes appear in the intestines, lymph nodes, and spleen, similar to typhoid fever, but less pronounced. Intestinal complications are rare. Complications: toxicosis, infectious shock, purulent complications, dysbiosis.

Dysentery is an acute infectious disease, with a predominant lesion of the large intestine. It is stitched together by a group of related Shigella bacteria. The most common causative agents are Shigella Flexner and Sonne.



The source of the infection is a sick person, especially one who suffered from the disease in a mild form and did not consult a doctor. The route of infection is fecal-oral, through food and water. Flies play a role in the contamination of products. Epidemic alarms are known in connection with the infection of products during their manufacture and transportation. Children get sick more often.

As a result of vital activity, microbes exhibit a toxic effect, which leads to characteristic morphological changes in the intestines and reactive changes in regional lymph nodes. Absorbed from the intestine, into the blood, toxic products of the decay of microbes cause direct damage to tissue and organs of the central nervous system, especially in children under the first year. Circulating in the blood, toxins return with the blood flow to the walls of the intestines, where a repeated interaction reaction takes place. It can have the character of hyperergic inflammation.

The incubation period for dysentery is up to 3 days. Bacteria find favorable conditions for their development in the epithelial cells of the mucous membrane of the colon. As a result of the cytopathic action of *Shigella*, desquamation of cells occurs, desquamative catarrh of the colon develops. In connection with the release of endotoxin, a vasoneuroparalytic effect occurs (paralysis of blood vessels, damage to the intramural ganglia of the intestine). Destruction of the epithelium and paralysis of blood vessels, which are associated with increased exudation, determine the change of catarrh to fibrinous inflammation and the development of ulcers during the rejection of fibrinous films.

Local and general changes are observed. Local changes are divided into 4 stages:

The first stage is catarrhal colitis. The wall of the intestine is thickened, the mucosa and submucosa are swollen, the mucosa is hyperemic, a thick layer of mucus is mixed with serous exudate, desquamated epithelium or serous-bloody exudate. On the surface of the mucous membrane, centers of necrosis, hemorrhages. The lumen of the intestine is sharply narrowed. The duration of the stage is 2–3 days.

The second stage is fibrinous (diphtheritic) colitis. This stage is characterized by more widespread necrotization of the mucous membrane with the formation of plaques (films) on its surface. Necrosis is deep and captures the entire mucous and submucous layers, up to the muscle. Necrotic masses are permeated with fibrinous exudate with the formation of films tightly attached to the mucous membrane. These films are grayish-green in color, sometimes brown-black. Microscopically - necrotic detritus, fibrin, leukocytes. The submucosal, muscular and serous layers of the wall are permeated with serous or serous-hemorrhagic fluid. Infiltrates from leukocytes and lymphoid cells around the vessels. In the cells of blood vessels - fibrinoid necrosis. The lumen of the intestine is narrowed as a result of spasm of the muscle layer.

The third stage is the formation of ulcers, ulcerative colitis, on the 10th–12th day of the disease. At this stage, ulcers of different sizes, depths and shapes appear. The deeper the necrosis was, the deeper the ulcers will be. Ulcers can be on the tops of the folds, and in severe cases they merge together and form a large ulcer surface.

The fourth stage - the stage of healing, lasts for 3-4 weeks of the disease. Ulcers heal slowly. Small ulcers regenerate completely, they are covered with epithelium and the glands are restored. Large ulcers are not covered by a mucous membrane for a long time - scar tissue grows at the bottom. Numerous and rough scars can narrow the lumen of the intestine and deform its inner surface.

Patients die from intestinal and extraintestinal complications.

In children, a catarrhal form of dysentery, similar to typhoid fever, is more common. With this form, there are sharp changes in the follicles of the colon and sometimes in the plaques of the lower part of the long intestine. In the lymphoid formations, necrosis and suppuration occur.

In rare cases, dysentery can be accompanied by an anaerobic infection, and then fibrinous-diphtheritic inflammation turns into gangrenous decay. This is a very severe so-called gangrenous form of dysentery. The intestine turns black, tears easily, the mucous membrane disintegrates, the process deepens, and the phenomena of fibrinoid necrosis are sharply expressed in the walls of

the vessels of the small intestine.

Changes in internal organs: sometimes slight enlargement of the spleen, hyperplasia of splenic follicles. In the liver, kidneys, myocardium - dystrophic changes.

Intestinal complications are associated with microperforation of ulcers with the development of limited or diffuse peritonitis. This can cause the formation of an abscess or phlegmon of pelvic tissue - phlegmous paraproctitis.

Narrowing - strictures of the rectum on the basis of deep scarring of ulcers.

Relapses of necrotic-ulcerative processes of the intestinal wall with the transition of the disease into a chronic form. At present, the question of the existence of chronic dysentery is resolved in a positive way and this explains the alarm of the disease all year round.

Bleeding from dysenteric ulcers is very rare.

Extraintestinal complications: focal pneumonia, purulent otitis, liver abscesses, thrombophlebitis of branches of the portal vein and, against this background, liver abscess, serous arthritis and synovitis, exhaustion of the body, dropsy of serous cavities, tissue edema. In the chronic form of dysentery, amyloidosis develops.

*Yersinia enterocolitis* is an acute infectious disease with a predominant lesion of the distal part of the ileum and cecum, with a tendency to generalization of the process.

The causative agents are *Yersinia enterocolitica* and *Yersinia pseudotuberculosis*, which are gram-negative intracellular bacteria related to *Yersinia pestis* (the causative agent of the plague).

Yersiniosis belongs to anthroponoses. The source of infection can be patients with yersiniosis, bacteria carriers and animals (rodents, cats, dogs, pigs, large and small cattle). The disease occurs in all age groups, but more often in children.

*Yersinia enterocolitica* and *Yersinia pseudotuberculosis* enter the human body through the fecal-oral route through infected vegetables, fruits, meat, and milk.

The clinical and morphological manifestations of yersiniosis caused by *Yersinia enterocolitica* and *Yersinia pseudotuberculosis* are approximately the same, but there are indications that yersiniosis caused by *Yersinia enterocolitica* is clinically more severe and more often prone to generalization of the process.

There are two forms: localized (enteritis, enterocolitis in combination with mesenteric lymphadenitis); generalized (enterocolitis in combination with septicemia and damage to internal organs).

After multiplying in the intestine, the pathogen penetrates its mucous membrane, mostly in the area of the ileocecal angle. Terminal catarrhal or catarrhal-ulcerative enteritis predominates. The mucous membrane of the terminal part of the ileum is swollen, its lumen is narrowed, round ulcers are defined in the area of hyperplastic group lymphoid follicles. *Yersinia* and polymorphonuclear leukocytes are found at the bottom of ulcers. Sometimes the cecum is involved in the process, where pseudomembranous colitis type changes are detected. Characteristic infiltration of all layers of the intestinal wall by neutrophils, mononuclear cells, eosinophils, and plasma cells. The germinal centers of lymphoid follicles increase in size, numerous mitoses are visible in them, and the disintegration of lymphocytes is also often noted. There is mainly a spiteloid transformation of the reticular cells of the germinal center of the follicles and histiocytes of the lamina propria of the mucous membrane. In the central part of such epithelioid granulomas, clusters of disintegrating neutrophilic leukocytes are noted. The appendix is often involved in the process with the development of acute appendicitis. In the wall of the appendix, a significant infiltration of polymorphonuclear leukocytes, eosinophils, histiocytes, sometimes yersiniosis granulomas from macrophages, epithelioid cells, single giant cells of the Pirogov-Langhans type is found; granulomas are characterized by karyorrhesis and purulent melting. The appendix is often involved in the process with the development of acute appendicitis. In the wall of the appendix, a significant infiltration of polymorphonuclear leukocytes, eosinophils, histiocytes, sometimes yersiniosis granulomas from macrophages, epithelioid cells, single giant cells of the Pirogov-Langhans type is found; granulomas are characterized by karyorrhesis and purulent melting. The

appendix is often involved in the process with the development of acute appendicitis. In the wall of the appendix, a significant infiltration of polymorphonuclear leukocytes, eosinophils, histiocytes, sometimes yersiniosis granulomas from macrophages, epithelioid cells, single giant cells of the Pirogov-Langhans type is found; granulomas are characterized by karyorrhexis and purulent melting

Regional lymph nodes, more often mesenteric ones, are affected even more regularly. Lymph nodes appear to be enlarged 10-30 times. They are soldered into packages, their tissue is infiltrated with polymorphonuclear leukocytes, eosinophils, and histiocytes. Micro abscesses surrounded by active macrophages are sometimes identified. In some children, mostly with a longer course of the disease, among the epithelial cells, giant cells of the Langhans type can be detected. Granulomas appear that resemble venereal granulomas and "cat scratch disease" granulomas

Along with the lymphogenic dissemination of the pathogen, its hematogenous (septic) spread with the formation of foci of generalization in internal organs, which has a structure similar to the one described above, is also possible.

Complications are infectious and allergic in nature. In the early period of the disease, perforation of intestinal ulcers with the development of peritonitis, jaundice, and pneumonia are possible. In the late period, polyarthrititis, erythema nodosum, Reiter's syndrome, myocarditis are more often found.

The outcome is usually reversible, but the disease can recur and become chronic. The fatal outcome is noted in the primary case of the septic form.

Campylobacteriosis is caused by two species of *Campylobacter*, *jejuni* and *coli*.

*Campylobacter* is a gram-negative microorganism in the form of a flagellum. Initially, it was classified as a vibrio, but after special cultivation it was identified, and it was called *Campylobacteria*, it is very often confused with banal enterobacteria.

In the United States, *Campylobacteria* is found twice as often as *Salmonella* and four times as often as *Shigella*. Most often, there are sporadic

cases of infection when eating spoiled Var chickens, which are often infected with campylobacter and salmonella. Sporadic cases can be observed in close contact with infected dogs. Epidemics can develop when milk and water infected with Campylobacter are consumed.

Due to the peculiar shape in the form of a comma or a spiral, campylobacter is able to penetrate through the erythrocyte membrane. Their invasive ability depends on the chemical composition of the cytoplasmic membrane of the host's enterocytes, G-proteins or phosphatidylinositol-3-kinase inhibit or block this invasion.

Possible clinical manifestations of campylobacter infection: banal diarrhea that does not depend on the invasion; dysentery-like diarrhea with blood and mucus in the excrement, if the bacteria invade the intestinal epitheliocytes; intestinal fever caused by the penetration of bacteria through the lamina propria of the mucous membrane and into the mesenteric lymph nodes and the development of sepsis.

Inflammation of the mucous membrane of all the intestines, from the small intestine to the anus, can be observed. The most frequent manifestation of campylobacteriosis is enterocolitis with the most typical lesion of the large intestine, particularly the colon. Macroscopic changes are minor. Campylobacter is often found in the glycocalyx and cytoplasm of the surface epithelium. In addition, there is infiltration of the surface epithelium of the intestinal mucosa by neutrophilic leukocytes, areas with ulcers, edema and diffuse infiltration of the lamina propria by lymphocytes and plasma cells with an admixture of granulocytes and macrophages. Crypt abscesses and ulcers similar to those seen in chronic ulcerative colitis may also occur.

In the small intestine, the ratio of crypts and villi slightly decreases. Later, regeneration of the epithelium and hyperplasia of lymphatic follicles occur. In the stage of recovery, only slight lymphoplasmacytic infiltration is noted.

**VIRAL AIR-DROPLET INFECTIONS. HIV INFECTION. RABIES.  
RICKETTSIOSES. PRION INFECTIONS**

The most studied human viral diseases are influenza, measles, smallpox, chickenpox, Botkin's disease, poliomyelitis, herpes, rabies, yellow fever, and others. In total, about 200 viral diseases of humans and warm-blooded animals are known nowadays.

1. Some features of the pathogenesis and immunity of viral diseases associated with nature, viruses as severe intracellular parasites are noted. Viruses are intracellular parasites of animal, plant and bacterial cells.

2. The second feature of viruses is tissue tropism – selective damage to cells, tissues and organs. Yes, the rabies virus can multiply only in nerve cells and moves through the body along nerve fibers. In poliomyelitis, the anterior horns of the spinal cord are selectively affected. Dermatropic viruses (smallpox, herpes, trachoma) selectively affect certain areas of the skin.

3. Many viral diseases are characterized by a long asymptomatic period. An example can be the latent form of Botkin's disease. Some people are carriers of the Botkin disease virus while remaining healthy. Administration of small doses (0.01 ml) of blood serum of such carriers to healthy people causes them to develop Botkin's disease. Asymptomatic carriage occurs in poliomyelitis, tick-borne and mosquito-borne encephalitis, tumor viruses, and adenoviruses.

4. In viral diseases, immunity also has some features. Leukocytes do not play such a role in immunity as is observed in bacterial infections. Leukocytes usually do not destroy viruses, they can adsorb and phagocytize them.

Viral diseases occupy a leading place in human infectious pathology.

Acute respiratory viral infections (ARVI) are a group of diseases, diverse in etiology, but similar in clinical and morphological features. In the past, they were united under the name flu.

The highest mortality from SARS is observed in groups of younger children and among the elderly.

The source of infection is a sick person, who is dangerous from the first hours of illness and up to 3-5 days of illness.

The way of transmission is airborne. Rapid spread is facilitated by: high sensitivity to influenza, short-term immunity, variability of the virus. There is also a way of intrauterine transmission of the influenza virus. As a result:

intrauterine death of the fetus, prematurity, functional immaturity of children, congenital anomalies. Perinatal mortality of children is also high. They may develop intrauterine pneumonia if the mother has an influenza infection. The influenza virus is characterized by a pronounced tropism to the epithelium of the respiratory tract.

The entrance gates are cells of the cylindrical epithelium of the lower nasal concha and trachea. The vascular network is involved in the pathological process, the virus has a toxic effect on the body, and increases vascular permeability. Viremia leads to dissemination of the virus in the body. Now it has been established that the virus penetrates into alveolar cells, which ensures the rise of influenza infection.

The flu virus can suppress the body's immune system.

There are mild, moderate and severe forms of influenza with the release of a toxic form. The pathological process begins with severe hyperemia of the mucous membrane of the nose, throat, and larynx. On the 2nd day from the onset of the disease, a picture of catarrhal inflammation develops: hypersecretion of mucous glands, edema and lymphocytic infiltration of the subepithelial layer develop. With flu of moderate severity - dilated blood vessels of the mucous membrane of the trachea and large bronchi, spotty hemorrhages, diffuse full blood. Sometimes - the formation of necrosis.

Hemorrhagic tracheobronchitis is considered a morphological sign of influenza. The formation of arcade-like structures in the epithelium of the trachea and bronchi, the cytoplasm is vacuolated, is considered typical for influenza.

Microscopically, the airiness of the lung tissue is reduced due to dystelectasis. Alveolocytes are enlarged, the cytoplasm is granular, the nuclei are homogeneous, then lyse.

The destruction of osmophilic bodies leads to a decrease in surfactant activity. Atelectasis centers in the lungs. In children, the phenomena of general intoxication, sharp hemodynamic disorders in all internal organs. The mucous membrane of the respiratory tract is full of blood, desquamation of the epithelium, foci of necrosis. In the epithelium of the trachea and bronchi -



antigen of the influenza virus. In the lungs against the background of pronounced disorders - atelectasis, thickening of the interalveolar membranes. With a particularly severe course of the flu - toxic hemorrhagic pulmonary edema.

Flu-like changes in the brain and internal organs are a result of the multiplication of the virus in organs that have epithelium and endothelium. In the brain - full blood, stasis, hyaline thrombi, dystrophy of nerve cells. The biggest changes are in the diencephalic region and in the vegetative ganglia.

In the liver – dystrophy of hepatocytes, swelling and desquamation of capillary endothelium, moderate intra- and interlobular infiltration by lymphocytes, histiocytes. Some children have hemorrhages in the adrenal glands. Accidental involution in the thymus gland. In the intestines - alterative enteritis or enterocolitis.

Parainfluenza is an acute respiratory disease, the causative agent of which is hsevmotropic viruses of types 1–4.

The source of parainfluenza is a sick person, the infection spreads by airborne droplets. It is more common in children. Lethal consequences of uncomplicated parainfluenza are now very rare and occur in children of the 1st year of life in connection with the generalization of the infection.

Macroscopically – catarrhal tracheobronchitis with changes in the larynx. Small red-bluish cells are found in the lungs.

Microscopically - proliferation of the epithelium of the trachea and bronchi with the formation of tuber-like growths. It is most often found in small bronchi and bronchioles.

Changes in internal organs are common circulatory disorders, dystrophic and inflammatory processes. Changes in the epithelium of the kidneys, pancreas, and small intestine. No changes were detected in the liver and central nervous system. In the thymus is the second phase of accidental involution.

Complications - asphyxia caused by croup, viral pneumonia, pulmonary complications, sinusitis, otitis.

Adenovirus infection

Adenoviruses were isolated in 1953 from surgically removed adenoids

and tonsils. Etiology - DNA viruses.

The size of adenovirus parts is 50-85 nm, they are mixed in the nucleus of epithelial cells, resistant to external temperature influences.

The source is patients, convalescents and healthy virus carriers. The way of transmission is airborne.

There is an infection in the form of epidemic outbreaks and sporadic diseases. Clinical manifestations of adenovirus infection are rhinitis, pharyngitis, tonsillitis, bronchitis, bronchiolitis, pneumonia.

Adenoviruses have a tropism for epithelial cells of the respiratory tract and lymphoid tissue. They affect the mucous membranes of the respiratory tract, disrupt the activity of the vegetative and endocrine systems with metabolic disorders.

Macroscopically, with a mild form, acute catarrhal laryngotracheobronchitis is detected, which manifests itself in moderate fullness of the mucous membranes and mucous deposits on them. The necrotic nature of the process is noted, small dark red foci with a smooth, moist cut surface are found in the lungs in the posterior regions. Acute emphysema is detected in the anterior parts of the lungs

Microscopically, epithelial cells undergo characteristic changes; their nuclei are painted unevenly, sometimes enlarged, serous liquid with impurities of erythrocytes accumulates under the epithelial layer.

Specific morphological changes in adenovirus infection are hypertrophy of the nuclei of epithelial cells, formation of so-called adenovirus cells, mononuclear nature of infiltration and necrotic changes in the exudate in the lumen of the alveoli. A severe form of the disease is due to the generalization of the virus and the addition of a secondary infection.

In the intestines, mainly in the proximal parts, giant cell transformation of individual epithelial cells, villi and crypts takes place, cytoplasmic fuchsinophilic inclusions appear.

Individual hepatocytes and endothelial cells with hyperchromic nuclei resembling adenovirus cells in the lungs are sometimes found in the liver. Adrenal insufficiency is important in the pathogenesis of adenovirus infection.

## Respiratory syndyctial infection

PC virus belongs to the group of RNA viruses.

The source of infection is sick people or virus carriers. The infection is spread by airborne droplets. Outbreaks are local in nature and are observed annually in autumn and spring.

Not only the epithelium of the upper respiratory tract is affected, but also the entire respiratory tract, including the alveoli, the maximum changes develop in the small and medium bronchi, bronchioles.

Macroscopically, the mucous membrane of the larynx, trachea, and large bronchi is unchanged, sometimes hyperemic. In the lungs there are small compacted dark red foci. The front parts of the lungs are emphysematous, on the pleura there are spotty hemorrhages.

Histologically - proliferation of the epithelium of small bronchi, bronchioles and alveolar ducts with the formation of papilla-like outgrowths, which consist of 3-8 large cells with light large oval or rounded nuclei. In the lumen of the bronchi - lymphocytic infiltrates, thick exudate. When the infection is generalized, characteristic changes in the internal organs are revealed.

Complications – pneumonia, pulmonary complications with secondary infection, generalization of infection.

Rickettsioses are groups of infections of humans, many warm-blooded animals, and some arthropods.

The reservoir of rickettsial infection in nature is wild and domestic animals, they are a source of infection of arthropod bloodsuckers - fleas, ticks.

People develop febrile diseases with characteristic rashes on the skin and peculiar impressions of vessels in the form of vasculitis and thrombovasculitis of varying severity. The infection passes through slightly damaged skin, into which the causative agents of lice and fleas are rubbed with feces.

Classification of rickettsioses (6 groups) according to Zdrodovsky P.F. and E.K. Golinevych:

- 1) typhus group, which includes epidemic typhus, transmitted by lice, and endemic or rat typhus, transmitted by fleas;

2) a group of tick-borne spotted fevers (rocky mountain spotted fever, Marseilles, North Australian tick-borne typhus and North Asian tick-borne typhus);

3) a group of endemic fevers, the causative agents of which are transmitted by the larvae of ticks - erysipelas (Ttsutsugamushi fever);

4) group of pneumotropic rickettsioses or Ku-fever group;

5) group of paroxysmal rickettsioses (Volyn or trench fever);

6) a group of animal rickettsioses.

These rickettsioses are characterized by the following signs: 1) severe vascular pathology; 2) febrile state; 3) rash.

#### Epidemic typhus

The first description was made by the Italian scientist Fracastro. Typhoid fever was isolated for the first time by the Russian doctor Shchyrovsky and Govorev in 1811-1812 pp.

Mortality is 5–20%. Nowadays, sporadic cases rarely occur. In 1976, the resident of Odesa City Hospital O.O. Mochutkovsky proved that the transmission of pathogens occurs by bed lice. The incubation period is 10–12 days.

The disease begins with a rise in temperature. Rashes appear on the 5-8th day. Early symptoms include: "ferry eyes", Godelier's symptom, marbling of the skin, Rumpel-Leide's symptom.

Rickettsia develop in the endothelium of vessels, it swells, proliferates and peels off.

An elementary form of vascular impression is: warty endovasculitis (destruction of the endothelium, necrosis, formation of a wall coagulation thrombus in the form of a wart); proliferation of endothelial and intimal cells; necrosis of the entire thickness of the vessel wall, when all three membranes are necrotized. The vessel collapses, obstructs, thromboses. This is destructive thrombovasculitis.

Such changes are more common in the brain. Nodes or granulomas formed from neuroglia (Popov nodules) are formed around the affected blood vessels from the brain tissue.

In the autonomic nervous system - changes in the upper cervical nodes.

The skin is hyperemic, roseolous-petechial rashes. Smears from typhoid exanthema reveal rickettsiae. On the conjunctivae of the eyelids - spots of Chiarina - Avtsina.

In the adrenal glands - dystrophic changes, decrease in lipids, edema, hyperemia. Such patients have a tendency to collapse.

In the myocardium – acute focal interstitial myocarditis or mixed parenchymal-interstitial myocarditis.

Spleen - increases 3-4 times, weighs 300-500 g. The pulp is hyperplastic.

Pneumonia in the lungs.

Granulomas of lymphocytes, macrophages, and plasma cells are formed around the lesions of vessels.

The cause of death is intoxication with severe circulatory and central nervous system disorders, heart paralysis against the background of collapse. Complications of typhoid fever - hypostatic or aspiration pneumonia, gangrene and bedsores, purulent inflammatory processes in the salivary glands - parotitis, phlegmon, abscesses, purulent otitis, septicopyemia, toxic neuritis of the auditory nerve.

Endemic typhus.

The disease is benign, rashes occur in 75% of cases, petechiae are rare. The nervous system suffers little. Mortality is almost absent, pathological anatomy is poorly studied.

Acquired immunodeficiency syndrome (AIDS) is a disease caused by the human immunodeficiency virus (HIV). It got its name in connection with the development in the end of the disease of total suppression of the immune system, accompanied by the development of opportunistic infections and tumors (Kaposh's sarcoma, malignant lymphomas). Opportunistic infections are called infections, the causative agents of which are mostly opportunistic (less virulent) microbes or viruses, the infection of which in a healthy person is not accompanied by pathological changes. SHD always ends fatally.

The first cases of AIDS appeared in the USA in 1979, but the disease was officially registered only two years later. In the following years, the spread of

AIDS became a pandemic. By March 1988, 81,433 cases of the disease were registered in 133 countries, however, taking into account the fact that the disease is diagnosed only in a small percentage of cases, according to the WHO, the real number of patients is 250,000. The total number of infected is 5–10 million, of which up to 1991 year, at least 1 million people were to fall ill. Most of the patients were found in the USA, countries of Western Europe, and Africa. In Central Africa, a catastrophic situation has developed due to the fact that 5–20% of the adult population is infected in some of its regions. Approximately every 8-10 months, the number of AIDS patients doubles; half of them die within 5 years. The majority of patients are aged 20–50 years (the peak of the disease occurs at the age of 30–40); often children also get sick.

The source of infection is a sick person and a virus carrier. The highest concentration of the virus is found in blood, semen, cerebrospinal fluid; in smaller quantities, the virus is found in the tears, saliva, cervical and vaginal secretions of patients. Currently, three ways of transmission of the virus have been proven: 1) sexual (with homosexual and heterosexual contacts); 2) through parenteral introduction of the virus with blood products or when using infected instruments; 3) from mother to child - transplacental or with milk. Other ways of transmission of the virus (air-droplet, contact-household, fecal-oral, transmissible - through the bite of blood-sucking insects) have not received convincing evidence.

Among the population of the USA, Canada, as well as European countries, population contingents are clearly defined, among which the AIDS disease is particularly high, which made it possible to identify risk groups. They include: 1) homosexuals; 2) drug addicts who use intravenous drug administration; 3) patients with hemophilia; 4) recipients of blood; 5) heterosexual partners of AIDS patients and virus carriers, as well as persons belonging to the risk group; 6) children whose parents belong to one of the risk groups.

The AIDS pandemic is characterized by uneven geographic, racial and gender distribution of cases. In the United States and other industrialized countries with a significant number of diseases, the main ways of spreading the

virus are homosexuality and intravenous drug use, and among the sick there are approximately 10-15 times more men. In Central, Eastern and Southern Africa, as well as in some countries of the Caribbean, AIDS spreads mainly through heterosexual means, while the number of infected men and women is approximately the same. In these areas, perinatal (from mother to child) transmission of the virus, as well as infection by donor blood I Few cases of AIDS have been registered in Western Europe, the Middle East, and Asia. In these regions, cases of infection during sexual contact and intravenous injections were registered, in some cases the disease was caused by imported donor blood. The current epidemiological situation on AIDS does not allow us to expect an optimistic forecast for the future.

The AIDS virus was first isolated in 1983 by L. Montagnier (France) and R. Gallo (USA). It turned out to be a virus of T-lymphotropic retroviruses, which was named "HIV" in 1986. Recently, this virus began to be labeled as "HIV-1", because another virus was discovered - "VSh-2" (virus of the "African CIS"), which is more often found in the aborigines of West Africa. Many different strains of the virus have been discovered, thanks to its phenomenal propensity for mutations. The diameter of mature viral particles is 100–140 nm. Nucleoid contains two RNA molecules (viral genome) and reverse transcriptase. The capsid contains two glycoproteins - 41 and 120, and the latter provides specific binding of the virus to cells bearing the CD4 antigen on their surface. Such cells are primarily Td lymphocytes (helpers), to a lesser extent monocytes and macrophages, as well as microglia. HIV is not stable in the external environment and dies at a temperature of 56°C within 30 minutes, at 70–80°C – within 10 minutes; it is quickly inactivated by ethyl alcohol, acetone, ether, 1% glutaraldehyde solution, etc., but is relatively resistant to ionizing radiation and ultraviolet radiation.

The origin of the virus is controversial. The most likely is the "theory of African origin", according to which HIV existed for a long time in Central Africa, where AIDS was an endemic disease. In the mid-70s of our century, in connection with the increased migration of the population from Central Africa, due to drought and famine, HIV was introduced to the USA and Western

Europe, where it circulated for a long time among homosexuals, and then began to spread to other layers of the population .

When infected, HIV enters the blood directly (with injections) or through damaged mucous membranes of the genital tract (with sexual contact) and binds to cells to which it has a tropism. When the virus interacts with the target cell, its envelope merges with the cell membrane, the virus ends up in the middle of the cell. A DNA copy (provirus) is removed from the RNA virus using reverse transcriptase, which is incorporated into the chromosomal DNA of the target cell. Viral genetic material remains in the cell for life, when the cell divides, it is transmitted to its descendants. HIV behaves differently depending on the type of damaged cell, the level of its activity, as well as the state of the immune system. In T4-lymphocytes, it can be in a latent state for quite a long time, which explains the possibility of long-term latent virus-carrying in AIDS. Activation of T4-lymphocytes (in case of infection with another antigen) can provoke violent replication of HIV, which leads to massive cell death. In monocytes and macrophages, replication occurs very slowly, without a pronounced cytopathic effect, but changing the functional state of the cell. The diverse behavior of the virus in target cells is determined by the complex organization of its genome, which includes not only structural genes (the synthesis of virus-specific proteins is associated with them), but also regulatory genes, the interaction of which determines the start of replication and its intensity. The complex mechanisms of HIV replication regulation are in close interaction with the metabolism of the host cell. In monocytes and macrophages, replication occurs very slowly, without a pronounced cytopathic effect, but changing the



functional state of the cell. The diverse behavior of the virus in target cells is determined by the complex organization of its genome, which includes not only structural genes (the synthesis of virus-specific proteins is associated with them), but also regulatory genes, the interaction of which determines the start of replication and its intensity. The complex mechanisms of HIV replication regulation are in close interaction with the metabolism of the host cell. the interaction of which determines the beginning of replication and its intensity. The complex mechanisms of HIV replication regulation are in close interaction with the metabolism of the host cell. the interaction of which determines the beginning of replication and its intensity. The complex mechanisms of HIV replication regulation are in close interaction with the metabolism of the host cell.

The leading chain in the development of immunodeficiency is considered to be damage to T4 lymphocytes (helpers), which is confirmed by progressive lymphopenia in AIDS patients. Not only does the number of T-helpers decrease, but also the ratio of T4/T8 (helper-suppressor ratio), which in AIDS is always less than 1. A decrease in T/T8 is the main feature of the immunological defect of the AIDS game and is determined in all its clinical variants.

The mechanism of death of T4 lymphocytes depends not only on the cytopathic effect of the virus. The formation of non-viable multinucleated cell symplasts associated with an infected cell is of great importance, and one infected cell can associate more than 500 normal ones. Viral antigens expressed on the surface of infected cells stimulate the immune response in the form of production of anti-HIV antibodies and cytotoxic lymphocytes, causing cytolysis of both damaged and undamaged T4 cells. The death of intact T4 lymphocytes is associated with their ability to bind free viral glycoprotein molecules that have separated from infected cells and circulate in the blood. Recently, it has been established that HIV not only leads to a decrease in the number of T4 lymphocytes, but also causes the release of soluble suppression factor residues,

Quantitative and qualitative changes in T4-lymphocytes, which are the "conductors" of the immune process, as well as virus damage to macrophages lead to gross destruction of primarily cellular and humoral immunity. Damage

to cellular immunity in AIDS patients is manifested by a sharp decrease, and in the end of the disease, a complete loss of the response of HRT to various antigens, as well as a decrease in the response of blast transformation in vitro. Damage to humoral immunity is represented by nonspecific polyclonal activation of B cells, which is accompanied by an increase in the level of serum immunoglobulins. However, the ability to form a specific humoral response decreases as the disease progresses. In the finale, suppression of the humoral link of immunity develops.

Peculiarities of the interaction of HIV with the cell, as well as early and progressive damage to the immune system, lead to the fact that the body becomes unable to eliminate HIV and counteract secondary infection. It becomes defenseless against the action of many viruses, fungi, and some bacteria (in particular, mycobacterium tuberculosis). Opportunistic infections and tumors are leading in the clinic of the State University of Medical Sciences.

According to many researchers, sooner or later all those infected with HIV develop AIDS. The disease develops for a long time (from 1 to 15 years), progresses slowly, passing through several periods (stages) with certain clinical and morphological manifestations. The following periods of AIDS are distinguished: 1) incubation; 2) persistent, generalized lymphadenopathy; 3) preAIDS, or AIDS-associated complex; 4) AIDS.

The incubation period, its duration depends on the ways and nature of infection, the size of the infecting dose, the initial state of the immune system; it can last from a few weeks to 10-15 years. During this period, the very fact of infection can be established by the presence of antigen or anti-HIV antibodies in the blood. The amount of virus antigen in the blood first increases sharply, then, starting from week 6-8, when anti-HIV antibodies appear, it decreases, that is, seroconversion occurs. Some researchers single out seroconversion as an independent period of AIDS.

In most cases, there are no symptoms of the disease during the incubation period, however, some have a syndrome similar to mononucleosis: fever, enlargement of various groups of lymph nodes, sometimes acute encephalitis. But the manifestations of this syndrome pass over several weeks.

The second period - the period of persistent generalized lymphadenopathy - is characterized by a steady, over several months, increase in various groups of lymph nodes. The basis of lymphadenopathy can be considered nonspecific hyperreactivity of B-cells, manifested by follicular hyperplasia of lymph nodes (enlargement of follicles and their light centers). The duration of the stage is 3–5 years.

The third period of the disease, which occurs against the background of moderate immunodeficiency, is called preAIDS, or AIDS-associated complex. It is characterized by fever, lymphadenopathy, diarrhea, slight loss of body weight. Against this background, there is a tendency to develop secondary infections - acute viral respiratory infections, shingles, pyoderma, etc. This period continues for several years.

The fourth period of the disease lasts about two years - this is the period of acquired immunodeficiency syndrome (AIDS). It is characterized by the occurrence of opportunistic infections and tumors, exhaustion and dementia. In this final period, as a rule, the number of anti-HIV antibodies decreases (they may not be detected at all), and the number of viral antigens increases, which must be taken into account when diagnosing AIDS.

The pathologic anatomy of AIDS consists of lymph node changes, characteristic CNS lesions, and changes typical of opportunistic infections and tumors. Follicular hyperplasia of lymph nodes is replaced by complete depletion of lymphoid tissue in them. Lymph nodes are sharply reduced, difficult to determine. The damage to the central nervous system consists in the development of HIV encephalomyelitis, while the main changes are found mainly in the white matter and subcortical nodes of the brain. Microglial nodules, multinucleated symplasts, in which HIV particles can be detected, are found under microscopic examination. Centers of softening and vacuolization of white matter are found in the lateral and posterior columns of the spinal cord. Due to demyelination, the white matter takes on a grayish hue. Opportunistic infections in AIDS are characterized by a severe recurrent course, often with generalization of the process and resistance to therapy. Protozoa (pneumocystis, toxoplasma, cryptosporidia), fungi (Candida, cryptococci), viruses

(cytomegaloviruses, herpes viruses, some viruses of slow infections), bacteria (*Mycobacterium avium intracellulare*, legionella, salmonella) can be the causative agents of opportunistic infections. One of the most frequent and characteristic infections in AIDS is caused by pneumocysts. It leads to the development of severe pneumonia with the formation of a large number of foamy eosinophilic masses in the alveoli, in which pneumocysts are identified. Toxoplasmosis infection, which causes encephalitis, also occurs quite often; it is characterized by foci of necrosis and suppuration. In case of cryptosporidiosis, the intestines are affected, enteritis and colitis develop, which are manifested by prolonged profuse diarrhea. Among fungal lesions, candidiasis with damage to the esophagus, trachea, bronchi, lungs, as well as cryptococcosis, which has a tendency to disseminate the process, is common. Regarding viral infections, cytomegalovirus infection with the development of rhinitis, pneumonitis, colitis, and encephalitis is the most typical. Herpetic infection is characterized by long-term damage to the mucous membranes and skin. Among bacterial infections, the most characteristic is the atypical mycobacterial infection *Mycobacteria avium intracellulare*, which leads to the development of a disseminated process with damage to lymph nodes and internal organs. Herpetic infection is characterized by long-term damage to the mucous membranes and skin. Among bacterial infections, the most characteristic is the atypical mycobacterial infection *Mycobacteria avium intracellulare*, which leads to the development of a disseminated process with damage to lymph nodes and internal organs. Herpetic infection is characterized by long-term damage to the mucous membranes and skin. Among bacterial infections, the most characteristic is the atypical mycobacterial infection *Mycobacteria avium intracellulare*, which leads to the development of a disseminated process with damage to lymph nodes and internal organs.

Malignant tumors in AIDS occur in 40% of cases. Kaposi's sarcoma (in 30% of patients) and malignant lymphomas are the most characteristic.

Kaposi's sarcoma (multiple idiopathic hemorrhagic sarcoma) is a rare disease that occurs mainly among men after the age of 60, characterized by a slow, fairly benign course. Manifestations of the tumor are reddish-red spots,

plaques and nodes, which are located mostly on the skin of the distal parts of the lower extremities; characteristic ulceration. Spontaneous evolution is possible with the appearance of scars and depigmented spots at the site of the tumor. Microscopically, the tumor consists of many newly formed randomly arranged thin-walled vessels with a well-defined endothelium and bundles of spindle-shaped cells. Haemorrhages and accumulation of hemosiderin are often observed in the loose stroma. In patients with SHD, Kaposi's sarcoma has a malignant nature and differs from the classic variant in the generalization of the process with damage to the lymph nodes, gastrointestinal tract,

Malignant lymphomas in AIDS are mainly B-cell. Burkitt's lymphoma is common.

The variety of opportunistic infections, which often combine with each other, as well as with tumors, makes the clinical picture of AIDS extremely polymorphic. In this regard, several of the most typical variants of AIDS are distinguished: pulmonary, CNS damage syndrome, gastrointestinal syndrome, fever of unclear origin.

The pulmonary variant is the most common (in 80% of patients). It is a combination of pneumocystis pneumonia, cytomegalovirus and atypical mycobacterial infection and Kaposi's sarcoma. CNS damage syndrome includes HIV encephalitis, lesions associated with toxoplasmosis, cryptococcosis, cytomegalovirus infection, and lymphoma; leads to the development of dementia. Gastrointestinal syndrome is a combination of candidiasis, cytomegalovirus infection, cryptosporidiosis, and atypical mycobacterial infection; accompanied by diarrhea and the development of cachexia at the end. Fever of unclear origin - in some cases, it is possible to detect an atypical mycobacterial infection or malignant lymphoma.

Death occurs more often from opportunistic infections and generalization of tumors. In developed countries, 50% of patients die during the course of the disease within 18 months from the day of diagnosis, and 80% within 36 months; mortality reaches 100%.

Rabies is an acute infectious disease affecting humans and animals, characterized by damage to the central nervous system.

The causative agent of the infection is the rabies virus from the rhabdovirus family. Infection occurs when bitten by a sick animal, further along the perineural space it reaches the nerve cells of the brain. The incubation period lasts 30–40 days, the duration of the disease is 5–7 days.

Chromatolysis, hydropic dystrophy, and necrosis develop in nerve cells. Clusters of microglial and lymphoid cells that form rabies nodules are observed around the necrosis. They are mainly found in the medulla oblongata, the sylvian aqueduct. Babesh-Negra bodies are detected in the nerve cells of the hippocampus.

Death without the use of antirabies serum is observed in 100% of cases.

Prion infections. One of the outstanding scientific achievements of the 20th century in the field of biology and medicine was the discovery in 1982 by the American molecular biologist, Professor Stanley Pruziner, of a new type of infectious agent - prions. This is not just an important stage in the development of molecular biology. This is a new era of the development of biology and medicine, as a fundamentally new type of infectious diseases has been discovered, which differs in its nature of occurrence and development. According to the degree of complexity of their structure, prions are among the simplest infectious agents known today.

Prions are an unprecedented class of infectious agents that consist only of altered host protein molecules. Prions do not contain nucleic acids and thus differ from all known microorganisms such as bacteria, fungi, viruses and virus-like particles. After multiple passages in culture, it was proven that pathogenic prion proteins capable of transmission are mutants of the cellular isoform of the normal prion protein. To date, 18 different mutations of the human RgR gene have been identified, which are associated with various prion diseases.

The prion protein (PrP) is a sialoglycoprotein with a molecular weight of 33,000-35,000 Daltons, or 33-35 kD, which is encoded by a single gene located in human chromosome 20. It consists of approximately 254 amino acids in humans, including a 22-membered N-terminal signal peptide. The RgR-c prion is found in all mammals. Its half-life is several hours, but it is well preserved during development. Prions are very resistant to various physical and chemical

influences.

Prions are resistant to boiling for 30-60 minutes, drying for up to 2 years, freezing - 3 times more than known viruses, chemical treatment with alcohols, formaldehyde, acids, UV irradiation, gamma radiation, hydrolysis by enzymes. The most effective effect is found in doses that denature almost all proteins. In other words, of all living things, the prion is the last to die.

PP-c is part of the outer cell membranes, is connected to the outer surface of cells by a glycolipid anchor and participates in endocytosis and cell catabolism. Despite the fact that the highest concentration of PP is found in neurons, it can be synthesized by many other cells of the body. The role of the normal prion protein (PrP) in healthy individuals is not fully known. Prion protein is necessary for normal synaptic function. It is assumed that prions are involved in intercellular recognition and cellular activation. Some believe that their function is to suppress age-related processes, and therefore prion diseases are similar in their clinical and morphological characteristics to gerontological diseases. The prion protein (PrP) exists in two forms: a normal, non-infectious form that occurs in the brain as normal, as well as in infected patients. This form is designated as a cellular prion protein, or P<sub>g</sub>P<sub>s</sub>; isoform, or PrP-Sc (from "scrapie" - a disease of sheep), which is a pathological, infectious form and accumulates in the brain only of susceptible people and animals suffering from spongiform transmissible encephalopathy.

Classification. Today, there are two groups of human diseases that are caused by prions:

- spongiform transmissible encephalopathies;
- spongiform myositis with prion-associated inclusions. The most studied to date are spongiform transmissible encephalopathies.

Based on the established fact that prion diseases are unique from the genetic and infectious point of view, Pruziner proposed in 1991 the modern concept of the pathogenesis of spongiform transmissible encephalopathies. Its essence is that a person can be infected with prions in two ways:

1. Mendelian inheritance (autosomal dominant type of inheritance). However, this is not *prima facie* inheritance, but sequential - due to previous

genetic autoreplication of the infectious agent.

## 2. Transmission of an infectious agent by alimentary or iatrogenic means.

Prion diseases are both infectious and hereditary diseases. They can also be sporadic in the sense that there are cases when no known risk factor is detected, although the infection was most definitely acquired in one of the two previously indicated ways. Based on current knowledge, the transmission of prion encephalopathies is determined by three factors: the dose of infection, the route of infection, and the species barrier.

The dose of the infectious agent received by the host depends on the amount of infected tissue and its virulence (infectious titer). But it is always necessary to remember that with repeated exposure there is necessarily a risk of a cumulative effect.

The route of prion infection plays an important role in developmental diseases and has its own hierarchy. According to the degree of significance, the ways of infection can be divided in the following sequence: intracerebral; intravenous; intraperitoneal; subcutaneous; oral.

An example of the dependence on the dose and route of infection is served by experiments that showed that the dose required for prion infection of mice by the oral route should be 200,000 times higher than by the intracerebral route.

The transmission of prion spongiform encephalitis in laboratory and wild animals has been the subject of numerous studies for a long time. It has been noticed that at the first manifestation of the disease in a certain animal species, the incubation period is very long, while after the first passage to a new host within the same species, it shortens. In subsequent passages, the period decreases even more until it reaches the stable period characteristic of the species. This resistance to prion infection in different species has been called the "species barrier". It has been established that very high doses of infection are required to overcome the species barrier and spread infection within the species itself. However, researchers drew attention to the fact that with the same dose of infection, the transmissibility of subacute spongiform encephalitis in some cases (sheep scrapie) depends on the sources of the agent,



It was found that with various methods of introducing pathological prions through various peripheral routes, including the abdominal cavity, stomach, the infectious agent first appears in the cells of the lympho-reticular system of the tonsils, thymus, lymph nodes, and especially the spleen. First of all, the infection is determined in the B-cell zones. The authors showed that differentiated B-lymphocytes take part in the neuroinvasion of prions. This, in their opinion, can be important for disease prevention and be used in therapeutic measures.

In the case of alimentary infection, prions in Peyer's patches of the small intestine penetrate through cell membranes into the internal structures of lymphoid cells, from where they subsequently enter other organs of the immune system: lymph nodes, spleen, tonsils. Partial replication of prions is possible in these organs. It is assumed that dendritic cells are permissive for peripheral reproduction of prions. From the organs of immunogenesis, prions reach the nearest axons along the nerves. In the area of the axon, their significant replication can occur. Upon reaching a critical concentration, prions move toward the spinal cord, and then toward the brain.

After subcutaneous infection of rodents, prions are released from the spleen (1st week after infection), from the spleen and lymph nodes (5–13th week), from the spinal cord (13–17th week), and from the brain (17–19 th week). It was established that pathological changes in the brain appear on the 25th week, and clinical manifestations begin to be registered from the 34th week. All the affected organs contain up to 10 million infectious units per 1 g, but they, with the exception of the brain, do not show any pathological changes. According to some data, the maximum infectivity is reached before the 40th day, that is, long before the clinical disease in an outwardly completely healthy animal, when it is not yet possible to recognize the disease and carry out preventive measures and treatment. From this circumstance arise the difficulties of early diagnosis and the danger of transmission of infection with food products.

It has been experimentally proven that replication of the prion agent can occur both in neurons and in glial elements. Some authors believe that

astrocytes and other glial cells may play a key role in the pathogenesis of prion infection. This is confirmed by the high level of cytokines in the late stage of the disease. In addition, the morphological pattern of spongiform encephalopathy was obtained on linear mice in which only glial cells were infected.

Infectivity of organs of immunogenesis implies the transfer of an infectious agent with blood. However, neither in the incubation period, nor in the preclinical stage, nor even in the height of the disease, are biological changes found in the peripheral blood.

After the intracerebral introduction of the PrP-Sc prion protein into the animal body, it begins to selectively accumulate in the brain. There is evidence for the existence of PrP-c and PrP-Sc transport along axons. Most of the cellular protein prions are attached to the outer surface of the cell membrane by a glycoprotein anchor after passing through the Golgi complex. Like other proteins, the isoform of the prion protein PrP-Sc passes into the cell through slits on the cell surface. Unlike the cellular isoform of the prion protein, PrP-Sc accumulates in the cell.

Immunoelectron microscopic studies indicate that PrP-Sc accumulation occurs in secondary lysosomal structures that contain phospholipid-rich myelin figures. After damage to lysosomes and cell death, prions inhabit other cells. Intracellular accumulation of PrP-Sc in the brain is manifested by spongiform dystrophy of neurons, death of nerve cells and reactive astrocytic gliosis, which determines the neuromorphology of prion diseases.

The neuropathology of human prion diseases is characterized by 4 classic microscopic signs: spongy changes; loss of neurons; astrocytosis; formation of amyloid plaques.

Macroscopically, in all cases of prion encephalopathies, an insignificant decrease in the mass of the brain was noted, in some observations there was a moderate atrophy of the gyri, mainly in people with a prolonged course of the disease.

Microscopically, prion spongiform encephalopathy is characterized by the presence of many oval vacuoles (spongiosis) from 1 to 50 microns in diameter in the neuropil of the gray matter of the terminal brain. Vacuoles can be found

in any layer of the cerebral cortex. These can be individual vacuoles or groups divided into sections. On paraffin sections, vacuoles appear optically empty, however, in some of them, when stained with hematoxylin and eosin, small granularity is often revealed. Vacuoles can merge into microcysts (200 microns or more), as a result of which the cytoarchitectonics of the cortex is significantly distorted. Vacuolation can also be detected in the cytoplasm of large cortical neurons.

In addition to the cortex, spongy changes in the neuropil and vacuolization of the cytoplasm of neurons are noted along the course of all fields of Ammon's horns, along the course of the dentate fascia, in the subcortical nuclei, thalamus, and cerebellar cortex. Involvement of the cerebellum in the pathological process is the most characteristic manifestation of this disease, although the degree of spongiosis in it is very variable. Fusion of vacuoles is not characteristic of cerebellar lesions. Spongiosis is more often represented by microvacuoles with a diameter of 1-50 microns, which are located in the molecular layer.

Spongiform changes are constantly accompanied by a decrease in the number of neurons in various sections of the cortex. Neurons of the SH-UI layer are mainly affected. Vacuolation of the cytoplasm is noted in some preserved neurons, some neurons are wrinkled, hyperchromic. The degree of neuron loss correlates with the severity of spongiform changes and corresponds to the duration of the disease. The described signs are combined with the proliferation of astroglial cells. Various dystrophic changes were detected in proliferating astrocytes, starting with vacuolization of the cytoplasm and ending with the appearance of ossified forms followed by clasmatodendrosis. Myelin fibers of the cortex remain preserved.

With a long course of the disease, the most pronounced vacuolization and loss of neurons, accompanied by spongy status, with widespread gross vacuolization in all departments, complete collapse of the cerebral cortex in the form of an irregularly distorted framework of glial tissue with small interspersions of preserved neurons. In general, the longer the course of the disease, the clearer the microscopic changes will be. In the basal ganglia and

thalamus, severe neuronal death can be combined with gliosis and atrophy. Sharp dystrophic changes are observed in the cerebellum up to the death of granule cells and Purkinje cells. Preserved Purkinje cells are hyperchromic, swollen, with phenomena of tigrolysis and nuclear lysis. Myelin fibers, which are adjacent to the cortex and nuclear groups of the cerebellum, are often varicosely swollen, with fragmentation phenomena. However, it must be emphasized that

One of the morphological features of prion encephalopathies is the presence of prion-protein (PrP) plaques, which have the appearance of rounded eosinophilic structures. The study of the structure and topography of PP plaques is of great theoretical and practical importance. The number, localization and even microscopic signs of plaques vary in different forms and types of prion encephalopathies. Such plaques are characteristic of Kuru disease. Many authors call them Kuru plaques. They occur less frequently in sporadic and familial forms of Creutzfeldt–Jakob disease, but very often (more than 70%) in its new form. In isolated observations, they are described in familial fatal insomnia.

Very often, PrP-amyloid plaques are localized in the cells of the granular layer of the cerebellar cortex, but they can also be located in the molecular layer and in the white matter. They are usually surrounded by a pale pink halo. The intensity of plaque coloring is different. Perhaps that is why it is not always possible to detect them. For this, standard immunohistochemical methods with PPr-antibodies are used. Green birefringence is observed in the detected protein polymers after congo-rot staining under polarizing microscopy.

Visually, the spinal cord is practically preserved. Only sometimes a significant decrease in the number of motoneurons is noted. No demyelination of the white matter of the spinal cord was detected in any of the observations. Despite the relatively high concentration of prions observed in peripheral nerves, there are no pronounced structural changes in them.

The clinic of all forms of prion encephalopathy can be represented by various neurological symptoms caused by vacuolization and death of neurons (the main mechanism of action of prions at the cellular level) in almost any part

of the gray matter of the brain, including the cerebellum. Typical are:

- Disorders of the sensitive sphere: varying degrees of amnesia, loss and distortion of sensitivity, loss of sensory functions.

- Disorders in the motor sphere: ataxia, immobility, muscle atrophy, including respiratory muscles, paralysis.

- Mental disorders: loss of professional skills, depression, drowsiness, aggressiveness, reduced intelligence up to complete dementia.

With the development of clinical manifestations, there are no signs of inflammation, no biological abnormalities in the blood or in the cerebrospinal fluid, no non-invasive, direct, or indirect tests that would allow a confident diagnosis. The electroencephalogram is questionable. The clinical diagnosis is confirmed only by histological examination of the central nervous system: spongiosis with vacuolization of neurons, proliferation of astrocytes and glia without signs of inflammation and demyelination.

The group of human prion subacute transmissible spongiform encephalopathies includes: Creutzfeldt–Jakob disease; Herstmann-Straussler-Sheinker disease; "fatal familial insomnia" syndrome; Kuru disease; chronic progressive encephalopathy of childhood, or Alpers disease.

## **Tuberculosis**

Tuberculosis is a chronic disease that affects all human organs, most often the lungs.

Tuberculosis remains a fairly common disease. Around the world, every year 2-3 million people get sick with tuberculosis, 3-5 million people die; the total number of patients reaches 15-20 million, and half of them are over 45 years old. 75% of patients and deaths from tuberculosis occur in the countries of Asia, Africa, and South America, where tuberculosis is classified as an epidemic disease with no tendency to decrease. The fight against tuberculosis is carried out by the World Health Organization within the framework of international cooperation.

Tuberculosis has a number of features that distinguish it from other infections. They are represented by: 1) ubiquity of the infection in epidemic,

clinical and morphological terms; 2) the duplicity of tuberculosis, which, depending on the ratio of immunity and allergy, can be a manifestation of infection or disease; 3) polymorphism of clinical and morphological manifestations; 4) chronic wave-like course - alternating exacerbations and remissions of the disease.

The causative agent of tuberculosis is mycobacterium tuberculosis, discovered by R. Koch in 1882. There are four types of mycobacterium tuberculosis: human, bovine, avian and cold-blooded. The first two types are pathogenic for humans. Tuberculosis mycobacteria are characterized by: optimal growth in conditions of significant saturation of tissues with oxygen and, at the same time, the possibility of growth in an oxygen-free environment (facultative anaerobe); pronounced variability of the causative agent - branched, coccoid, L-forms, which can lose their cell membrane under the influence of chemotherapy drugs and persist in the body for a long time.

The entry of mycobacteria into the body and interaction with it, tissues, and organs constitute the pathogenesis of tuberculosis. The occurrence, course and consequence of the disease largely depends on the immunological state and reactivity of the body. Reactivity determines the unusual variety of clinical and morphological manifestations of tuberculosis, which is one of its striking features as a disease and causes difficulties in clinical diagnosis.

There are three main types of clinical and morphological manifestations of tuberculosis: primary, hematogenous and secondary tuberculosis.

Primary tuberculosis is characterized by: 1) the development of the disease during the period of infection, that is, at the first meeting of the organism with the infection; 2) sensitization and allergy, hypersensitivity reactions of the immediate type; 3) the advantage of exudative-necrotic changes; 4) a tendency towards hematogenous and lymphogenic (lymphoglandular) generalization; 5) a couple of specific reactions in the form of vasculitis, arthritis, serositis, etc.

As a rule, an aerogenic route of infection is observed, an alimentary route is also possible. Mostly children get sick, but now, thanks to the successful prevention of tuberculosis in childhood, primary tuberculosis develops in

teenagers and adults.

The morphological manifestation of primary tuberculosis is the primary tuberculosis complex. It consists of three components: a focus of damage in the organ (primary focus, or affect), tuberculous inflammation of draining lymphatic vessels (lymphangitis) and tuberculous inflammation of regional lymph nodes (lymphadenitis).

With aerogenous infection in the lungs, the primary tuberculous focus (affect) occurs subpleurally in the most oxygenated segments, most often the right lung - III, VIII, IX, X (especially often in III). It represents a focus of exudative inflammation, and the exudate quickly undergoes necrosis. A cell of caseous pneumonia appears, surrounded by a zone of personal inflammation. The dimensions of the affect are different: from microscopically barely visible alveolitis to inflammation of the acinus or lobe, and possibly a segment or lobe. In the caseous masses of primary affection, elastic and argerophilic fibers of the lung framework are preserved for a long time. The inflammatory process takes over the pleura with further development of fibrinous or serogonous-fibrinous pleurisy.

Very quickly, the specific inflammatory process spreads to the lymphatic vessels adjacent to the primary affect - tuberculous lymphangitis develops. It is represented by lymphostasis and the formation along the course of lymphatic vessels in the perivascular swollen tissue of tubercular nodules.

Further, the inflammatory process quickly moves to the regional bronchopulmonary, bronchial and bifurcation lymph nodes, in which a specific inflammatory process with rapidly occurring caseous necrosis develops. This is total tuberculous lymphadenitis. Lymph nodes increase several times and are presented as caseous masses at autopsy. Changes in regional lymph nodes are always more significant compared to the primary affect.

In the tissue of the mediastinum, adjacent to the caseous lymph nodes, pronounced peri-focal inflammation develops to one degree or another; in the most severe cases, there are even foci of cheesy necrosis.

With alimentary infection, the primary tuberculosis complex develops in the intestines and also consists of three components. In the lymphoid tissue of

the lower part of the jejunum or cecum, tubercular nodules are formed with necrosis and the subsequent formation of an ulcer in the mucous membrane, which is considered as a primary affect. Tuberculous lymphangitis with the formation of nodules along the lymphatic vessels and regional caseous lymphadenitis in relation to the primary affectation of the lymphatic nodes occur next. Similarly, a primary tuberculosis complex is formed in the tonsils (primary affection in the tonsils, lymphangitis and caseous necrosis of the lymph nodes of the neck), skin (skin ulcer, lymphangitis, regional brech lymphadenitis).

Three variants of the course of primary tuberculosis are possible: 1) extinction of primary tuberculosis and healing of primary complex cells; 2) progression of primary tuberculosis with generalization of the process; 3) chronic course.

Extinction of primary tuberculosis and healing of the cells of the primary complex begins in the primary lung cell. First, the peri-focal inflammation resolves, the exudative tissue reaction is replaced by a productive one: a shaft of epithelioid and lymphoid cells is formed around the cell, caseous pneumonia, as if separating the cell from the surrounding lung tissue. On the outside of this shaft, fibrosing tuberculous granulomas appear. A capsule is formed around the primary lesion, the surface layers of which consist of loose connective tissue with small vessels surrounded by lymphoid cells. The inner layer of the capsule, adjacent directly to the caseous masses, is gradually enriched with fibrous structures and merges with the surface layer. Vessels grow from the side of the surface layer of the capsule of the primary affect, which can reach the inner layers of the capsule and directly contact the caseous masses. The latter gradually dehydrate, become dense, and become calcified (petrification). Over time, in the inner layer, which touches the foamy caseous masses, multinucleated cells appear, which dissolve these masses. In their place, through metaplasia, bone beams are formed with bone marrow cells in the beam spaces. Thus, the petrified primary cell turns into an ossified one. Such a healed primary cell is called a Gon cell, named after the Czech pathologist who described it. At the site of tuberculous lymphangitis, as a result of fibrosis of



tuberculous granulomas, a fibrous mass is formed. Over time, in the inner layer, which touches the foamy caseous masses, multinucleated cells appear, which dissolve these masses. In their place, through metaplasia, bone beams are formed with bone marrow cells in the beam spaces. Thus, the petrified primary cell turns into an ossified one. Such a healed primary cell is called a Gon cell, named after the Czech pathologist who described it. At the site of tuberculous lymphangitis, as a result of fibrosis of tuberculous granulomas, a fibrous mass is formed. Over time, in the inner layer, which touches the foamy caseous masses, multinucleated cells appear, which dissolve these masses. In their place, through metaplasia, bone beams are formed with bone marrow cells in the beam spaces. Thus, the petrified primary cell turns into an ossified one. Such a healed primary cell is called a Gon cell, named after the Czech pathologist who described it. At the site of tuberculous lymphangitis, as a result of fibrosis of tuberculous granulomas, a fibrous mass is formed. Such a healed primary cell is called a Gon cell, named after the Czech pathologist who described it. At the site of tuberculous lymphangitis, as a result of fibrosis of tuberculous granulomas, a fibrous mass is formed. Such a healed primary cell is called a Gon cell, named after the Czech pathologist who described it. At the site of tuberculous lymphangitis, as a result of fibrosis of tuberculous granulomas, a fibrous mass is formed. Such a healed primary cell is called a Gon cell, named after the Czech pathologist who described it. At the site of tuberculous lymphangitis, as a result of fibrosis of tuberculous granulomas, a fibrous mass is formed.

Healing in the lymph nodes takes place in the same way as in the lung cell. But due to the significant size of the lesion in the lymph nodes, it acquires a slower character than in the lung cell. The cell of caseosis in the lymph node is dehydrated, thickened and ossified.

Calcified cells in the lungs are found in many practically healthy individuals. At the age of 10, they are found in 6% of autopsies; from 10 to 15 years - 25%; from 20 to 30 years old - 45%; and after 40 years - in almost every person. Thus, the penetration of tuberculosis mycobacteria into the human body leads not only to the disease, but also to infection, which has a beneficial effect on the development of immunity and prevents new infection. It has been proven that anti-tuberculosis immunity is infectious, non-sterile, that is, it is carried out in the body in the presence of weakly virulent mycobacteria. They can be

isolated even from calcified cells of the primary tuberculosis complex. Vaccination of infants and young children with BCG vaccine made from weakened mycobacterium tuberculosis has been carried out for a long time. Mandatory vaccination against tuberculosis has led in recent years to a sharp decrease in infection in childhood, which has pushed back the period of infection for older people, whose protective powers are more pronounced. But it should be borne in mind that in caseous calcified and even partially ossified masses, less virulent mycobacteria or their L-forms accumulate, which can manifest their vital activity when the body's defenses are reduced.

A scar forms in the intestine at the site of the primary ulcer during healing, and petrification occurs in the lymph nodes. Their ossification is very slow.

The progression of primary tuberculosis with generalization of the process manifests itself in four forms: hematogenous, lymphogenic (lymphoglandular), growth of the primary affect, and mixed.

The hematogenous form of progression (generalization) develops in connection with the early entry of mycobacteria into the blood (dissemination) from the primary affect or from caseous lymph nodes. Mycobacteria settle in various organs and cause the formation of nodules in them ranging in size from miliary (proso-like) - miliary tuberculosis - to large cells the size of a pea or larger. In this regard, miliary and large focal forms of hematogenous generalization are distinguished. It is especially dangerous to cover soft meninges with miliary tuberculous nodules with the development of tuberculous leptomeningitis. Sometimes, with hematogenous generalization, single nodules of various sizes appear in various organs, including in the apex of the lungs (Simon's cells),

The lymphogenic (lymphoglandular) form of progression (generalization) in primary tuberculosis is manifested by the involvement of bronchial, bifurcation, paratracheal, supra- and subclavian cervical and other lymph nodes in the process of specific inflammation. Tuberculous bronchoadenitis is of particular importance in the clinic. In those cases, when the packages of lymph nodes resemble a tumor, they speak of tumor-like bronchoadenitis. At the same

time, the enlarged lymph nodes, which have changed in a caseous manner, compress the lumen of the bronchi, which leads to the development of foci of lung atelectasis and pneumonia.

In primary intestinal tuberculosis, lymphogenic (lymphoglandular) generalization leads to an increase in all groups of mesenteric lymph nodes. Tuberculous mesadenitis develops, dominating the clinical picture of the disease.

The growth of the primary affect is the most severe form of progression of primary tuberculosis. With it, caseous necrosis of the zone of peri-focal inflammation occurs, fresh areas of exudative inflammation are formed around the primary affect, which are subject to necrosis and merge with each other. The primary cell is transformed from acenose to lobular, then to confluent globular, segmental, lobar - lobar-caseous pneumonia occurs. This is the most severe form of primary tuberculosis, which quickly ends in the death of the patient ("quick-flow tuberculosis"). In other cases, the primary center of globular or segmental caseous pneumonia melts and a primary pulmonary cavity forms in its place. The process takes a chronic course, primary pulmonary tuberculosis develops, which is associated with secondary fibro-caseous tuberculosis,

The primary intestinal affect increases due to the increase of the tubercular ulcer, as a rule, in the region of the cecum. There are limited tuberculous peritonitis, adhesions, packages of caseous-changed iliocecal lymph nodes. A dense conglomerate of tissues is formed, which clinically is sometimes perceived as a tumor (tumor-like primary intestinal tuberculosis) with a chronic course.

A mixed form of progression in primary tuberculosis is observed when the body is weakened after acute infections, for example, after measles, during vitamin deficiency, starvation, etc. In such cases, there is a large primary affect, caseous bronchoadenitis, often complicated by the melting of necrotic masses and the formation of fistulas (fistulas). Numerous tuberculous rashes are observed in the lungs and all organs.

Exacerbation of tuberculosis on the part of healed petrified lymph nodes occurs with long-term use of steroid hormones and immunosuppressants, which

reduce the body's resistance. A massive tuberculous bronchoadenitis develops with lymphogenic hematogenous generalization, very weak general signs and a slight cellular reaction. This so-called medicinal (steroid) tuberculosis is considered as a manifestation of endogenous infection.

The consequences of progressive primary tuberculosis are different. In unfavorable cases, the death of the patient occurs from the general generalized process and tuberculous meningitis. With a favorable course of the disease and the use of effective drugs, the progression of primary tuberculosis can be stopped, it is possible to turn the exudative reaction into a productive one, stimulate encapsulation, calcification of the cells of the primary complex and scarring of its exudates.

The chronic course of primary tuberculosis appears first of all in cases of slow progression of a specific inflammatory process in the lymph gland component of the primary complex with alternating outbreaks and remissions with a healed primary affect. At the same time, sensitization of the body occurs - increased sensitivity to foreign, non-specific influences. The increased reactivity of the body is clinically detected by tuberculin skin tests and the appearance of vapor-specific changes in tissues and organs, which are understood as various mesenchymal cell reactions in the form of diffuse and nodular proliferation of lymphocytes and macrophages, hyperplastic processes in hematopoietic tissue, fibrinoid changes in connective tissue and arteriole walls in organs, dysproteinosis, sometimes even the development of amyloidosis.

Paraspecific reactions, proceeding according to the type of hypersensitivity of the immediate or delayed type, in the joints give chronic primary tuberculosis similarities with rheumatism and are described under the name of Ponce's rheumatism.

The chronic course of primary tuberculosis is also discussed in cases of the formation of a primary pulmonary cavity and the development of primary pulmonary tuberculosis.

Hematogenous tuberculosis combines a number of manifestations of the disease, which occurs and develops in the human body after a significant period

of time after the primary infection - post-primary tuberculosis. In these cases, we are talking about people who are clinically healthy, but who have retained increased sensitivity to tuberculin and who have significant immunity to mycobacterium tuberculosis. Hematogenous tuberculosis occurs in patients with changes in the form of foci of elimination in various organs or incompletely healed foci in lymph nodes after primary infection. These cells can remain latent for a long time, their exacerbation occurs under the influence of any adverse factors in the presence of increased reactivity (increased sensitivity to tuberculin against the background of developed immunity to mycobacteria). So,

There are 3 types of hematogenous tuberculosis: 1) generalized hematogenous tuberculosis; 2) hematogenous tuberculosis with predominant lung damage; 3) hematogenous tuberculosis with predominant non-pulmonary lesions.

Generalized hematogenous tuberculosis, which is very rare nowadays. It is the most severe form of the disease, with an even rash of tubercular nodules and foci in many organs. In some cases, necrotic foci without proliferative or with a weak exudative reaction (the so-called necrotic form of generalized tuberculosis) are formed in all organs. This is the most acute tuberculous sepsis. In other cases, small (miliary) productive nodules appear. This form is designated as acute general miliary tuberculosis. It often ends with meningitis. Sometimes there is acute general large-cell tuberculosis, which is most often observed in debilitated patients and is characterized by the development of large (up to 1 cm in diameter) tuberculosis cells in various organs.

In each case of generalized hematogenous tuberculosis, it is necessary to find a source - a source of insemination, of course, it can be an unhealed source of primary infection in a lymph node, genitals, bones and other organs.

Hematogenous tuberculosis with a predominant lesion of the lungs is characterized by numerous inseminations in them, while in other organs they are absent or single. If there are many small (miliary) nodules in the lungs, it is called miliary tuberculosis of the lungs, which can be both acute and chronic.

In acute miliary tuberculosis, which is rare, the lungs are swollen, fluffy, small nodules can be felt in them like grains of sand, more densely scattered in

the upper segments. Often this form of tuberculosis ends with meningitis. With chronic miliary tuberculosis, scarring of nodules and the development of persistent emphysema of the lungs are possible, in connection with which the load on the heart increases and hypertrophy of the right ventricle (pulmonary heart) occurs. In addition, chronic large-focal or hematogenously disseminated pulmonary tuberculosis, which occurs in adults, is distinguished. It is characterized mainly by the corticopleural localization of foci in both lungs and a productive tissue reaction, the development of reticular pneumosclerosis, emphysema of the pulmonary heart, and the presence of a non-pulmonary tuberculosis foci.

Hematogenous tuberculosis, mainly with extrapulmonary lesions, arises from screening cells introduced into one or another organ by the hematogenous route during the period of primary infection. The bones of the skeleton (bone-joint tuberculosis) and the genitourinary system (tuberculosis of the kidneys, genitals), skin and other organs are mainly affected. Focal and destructive forms are distinguished, which have an acute or chronic course, that is, the forms of tuberculosis become phases of its development.

Tuberculosis of bones and joints occurs more often in children, less often in adults. It develops from screening cells in the bone marrow (tuberculous osteomyelitis). The most frequent localization is the bodies of the vertebrae (tuberculous spondylitis: the epiphyses of the bones that form the hip (tuberculous coxitis) and knee (tuberculous gonith) joints. Diaphyses are rarely affected. The synovial membranes are involved in the process secondary to its transition from the bone epiphysis to the joint tissues. with tuberculosis of the bones and joints, there is the formation of sequestrations, that is, areas of dead bone, its destruction, the formation of a hump and deformation of the joints. From the bone, a specific process spreads to the soft tissues adjacent to the joints, which is accompanied by the appearance of acute abscesses and fistulas.

Tuberculosis of the kidneys is usually unilateral, it develops more often in young people of puberty, as well as in the elderly. Early cells arise in the cortical layer, as the process progresses, they appear in the papillae of the pyramids, where the destructive process begins with the formation of cavities.

Outside the caverns, the interstitium of the kidney tissue is infiltrated with lymphocytes, histiocytes with an admixture of epithelioid cells. Closure of the lumen of the ureter by caseous masses causes the development of pyonephrosis. Gradually, the specific inflammatory process moves to the urinary tract, bladder, prostate gland, and testicles. In women, the mucous membrane of the uterus, tubes, and rarely the ovaries are affected.

Endocrine glands, the central nervous system, the liver, and serous membranes are also affected with hematogenous tuberculosis (in these cases, tuberculosis may arise as a result of the transition of a specific process from the affected lymph nodes).

Secondary, re-infectious, tuberculosis develops in the body of an adult after a primary infection, which provided him with relative specific immunity, but did not protect him from the possibility of repeated disease (post-primary tuberculosis). It is characterized by: 1) mainly pulmonary localization of the process; 2) contact and intracanalicular (bronchial tree, gastrointestinal tract) spread; 3) change in clinical and morphological forms, which are phases of the tuberculosis process in the lungs.

Regarding the origin of secondary tuberculosis, there are two theories: exogenous origin, i.e. new infection, and endogenous origin. The fact that anatomical findings make it possible to follow a long chain of cases, starting from the foci of primary infection to the formation of fresh foci of re-infection, makes it possible for most researchers to join the theory of endogenous origin.

There are eight forms of secondary tuberculosis, each of them is a further development of the previous form. In this connection, the forms of secondary tuberculosis are at the same time phases of its development (forms-phases). Among the forms-phases of secondary tuberculosis, the following are distinguished: 1) acute focal; 2) fibrinous-cellular; 3) infiltrative; 4) tuberculosis; 5) caseous pneumonia; 6) acute cavernous; 7) fibrinous-cavernous; 8) cirrhotic.

Acute focal tuberculosis occurs in people aged 20-25 years and older. Morphologically, it is characterized by the presence of one or two cells in the I and II segments of the right (rarely left) lung. They received the name of

Abrikosov reinfection centers.

O.I. Abrikosov in 1904 showed for the first time that these initial manifestations of secondary tuberculosis consist of specific endobronchitis, mesobronchitis, and panbronchitis of the intralobular bronchus. A specific process along the bronchioles passes to the lung parenchyma, as a result of which acinous or globular cheesy bronchopneumonia develops, around which a shaft of epithelioid cells with an admixture of lymphoid and giant Pirogov-Langhans cells quickly forms. A reactive non-specific process develops in the lymph nodes of the root of the lungs. With timely treatment of the patient, and in a large number of cases spontaneously, the process subsides, the exudative tissue reaction changes to a productive one, the foci of caseous necrosis are encapsulated and petrified, Ashoff-Pulev foci of reinfection appear, and the process may end there.

Fibrocellular tuberculosis is a phase of the course of acute focal tuberculosis, when after a period of attenuation of the disease (healing of Abrikosov's cells), the process flares up again. During the healing of Abrikosov cells, sufficiently large encapsulated and partially petrified cells appear, described by German scientists Ashoff and Poole (Ashoff-Pulev cells), they are given importance in the healing process, which is characterized by the appearance of acinous, lobular cells of caseous pneumonia, which are again partially encapsulated are petrified and turn into ashof-pulevstki. However, the tendency to exacerbation remains. The process remains one-sided, does not go beyond the I and II segments. It should be remembered that in the I and II segments, among the aggregated and calcified tuberculosis cells, there are, in addition to the Aashoff-Pulev cells, also which were formed from hematogenous screenings during the period of primary infection. They are described by Simon and bear his name. Simonov cells are smaller than Ashof-Pulev cells and are located symmetrically in the tops of the lungs.

Infiltrative tuberculosis develops during the progression of acute focal or exacerbation of fibro-focal tuberculosis, and exudative changes around caseous foci extend beyond the limits of a lobe or segment. Perifocal inflammation prevails over subtle changes, which may be insignificant. Such a cell is called



an Asman-Redeker infiltrate cell (named after the scientists who first described the X-ray picture). Non-specific perifocal inflammation can resolve, and then during the healing period there are only one or two small caseous foci that have not resolved, which are later encapsulated, and the disease again acquires the character of fibro-focal tuberculosis. In those cases, when perifocal inflammation covers the entire lobe, they talk about lobitis, as a special form of infiltrative tuberculosis.

Tuberculoma is a form of secondary tuberculosis, arising as a peculiar phase of the evolution of infiltrative tuberculosis, when the peri-focal inflammation resolves and a center of cheesy necrosis surrounded by a capsule remains. The tuberculoma reaches 2–5 cm in diameter, located in the I or II segment, more often on the right. It is often mistaken for peripheral lung cancer during X-ray examination due to clearly defined boundaries.

Caseous pneumonia, as a rule, is observed during the progression of infiltrative tuberculosis, as a result of which caseous changes begin to prevail over perifocal ones. Acinous, globular, segmental caseous-pneumonic cells are formed, which when merged can occupy a larger area of the lungs, even the entire lobe. Caseous pneumonia, which develops against the background of lobar, has a lobar character. Caseous pneumonia is observed mostly in debilitated patients and always against the background of older changes (fibro-focal, infiltrative-pneumonic tuberculosis or tuberculosis). It often occurs in the terminal period of each form of tuberculosis due to the weakening of the body's protective forces. The lung with caseous pneumonia is enlarged, dense on autopsy - yellow, on the pleura - fibrinous overlays.

Acute cavernous tuberculosis is a form of secondary tuberculosis, which is characterized by the rapid formation of a decay cavity, and then a cavern at the site of the infiltrate or tuberculoma. The decay cavity occurs after purulent melting and liquefaction of the cavernous masses that are secreted with mycobacteria together with sputum. This causes the danger of bronchogenic insemination of the lungs, as well as the release of mycobacteria into the environment. The cavern formed in this case is localized, as a rule, in the I or II segment (at the site of the cells from which it was formed), has an oval or round

shape, with a diameter of 2-5 cm, connects with the lumen of the segmental bronchus. The wall of the cavern is heterogeneous: the inner layer consists of caseous masses, the outer layer consists of dense lung tissue due to inflammation.

Fibrous-cavernous tuberculosis, or chronic pulmonary tuberculosis, arises from acute cavernous tuberculosis in cases of chronic course of the process. The wall of the cavern is dense, has three layers: the inner one is pyogenic (necrotic), rich in disintegrating leukocytes; middle – a layer of tuberculous granulation tissue; external - connective tissue, and among the layers of connective tissue there are areas of lung atelectasis. The inner surface is uneven, with beams crossing the cavity of the cavern; each beam is an obliterated bronchus or a thrombosed vessel. The changes are most pronounced in one, more often in the right, lung. In the I and II segments, the changes are older, the pleura is thickened. The cavern occupies one or two segments. There are various cells around it (depending on the type of tissue reaction of bronchiectasis. The process gradually spreads in the apicocaudal direction, descends from the upper segments to the lower ones both by contact and behind the bronchi, occupying new areas of the lung. Therefore, older changes in fibro-cavernous tuberculosis are observed in the upper parts of the lungs, and more recent changes in the lower parts. Over time, the process moves through the bronchi to the opposite lung. First of all, bronchogenic metastatic foci appear in it in the III segment, where acinous, globular tuberculous foci appear. When they disintegrate, the formation of caverns and further bronchogenic spread of the process is possible. Over time, the process moves through the bronchi to the opposite lung. First of all, bronchogenic metastatic foci appear in it in the III segment, where acinous, globular tuberculous foci appear. When they disintegrate, the formation of caverns and further bronchogenic spread of the process is possible. Over time, the process moves through the bronchi to the opposite lung. First of all, bronchogenic metastatic foci appear in it in the III segment, where acinous, globular tuberculous foci appear. When they disintegrate, the formation of caverns and further bronchogenic spread of the process is possible.

Cirrhotic tuberculosis is considered a variant of the development of fibrous-cavernous tuberculosis, when connective tissue develops in the affected lungs around the caverns, a linear scar forms at the site of the healed cavern, and numerous bronchiectasis appear. In case of secondary pulmonary tuberculosis, with an intracanalicular or contact path of spread, a specific lesion of the bronchi, trachea, larynx, oral cavity, and intestines may develop. Hematogenous spread is rarely observed, it is possible in the terminal period of the disease when the body's defenses are reduced. In these cases, tuberculous meningitis, extrapulmonary organ damage and other lesions are found.

Complications of tuberculosis are diverse and were already mentioned when describing some of its forms. With primary tuberculosis, the development of tuberculous meningitis, pleurisy, pericarditis, and peritonitis is possible. With bone tuberculosis, the development of sequestrations, deformations, lesions of soft tissues, abscesses, and fistulas is possible. In secondary tuberculosis, the greatest number of complications is associated with the cavern: bleeding, breakthrough of the contents of the cavern into the pleural cavity, which leads to pneumothorax and purulent pleurisy (pleural empyema). Due to the long course of the disease, each form of tuberculosis can be complicated by amyloidosis (especially often with fibrinous-cavernous tuberculosis). The cause of death of patients with pulmonary tuberculosis nowadays is pulmonary heart failure, bleeding,

In recent years, the clinical and morphological picture of tuberculosis in economically developed countries has changed significantly. The changes are caused mainly by social progress, the achievement of medical antibacterial therapy and are considered as natural and induced pathomorphosis. There is a sharp decrease and the practical disappearance of progressive forms of the disease - primary tuberculosis, hematogenous tuberculosis, and insidious pneumonias. Common to all clinico-anatomical forms of modern tuberculosis include the reduction of specific exudative changes and generalization of the process, strengthening of the non-specific component of tuberculous inflammation and fibroblastic reaction.

**Materials on the activation of students of higher education during the lecture: questions, situational tasks, etc(*if necessary*):**

**General material and bulk-methodological support of the lecture:**

**Questions for self-control:**

1. General characteristic of the infectious process: entrance gate of infection, primary infectious complex, spread and spread, ways of transmission infectious diseases.
2. Variants of local and general reactions to infections.
3. Morphological characteristics, complications, consequences, causes of death in bacterial dysentery.
4. Morphological characteristics, complications, consequences, causes of death in typhoid.
5. Morphological characteristics, complications, consequences, causes of death in salmonellosis
6. Morphological characteristics, complications, consequences, causes of death in yersiniosis
7. Cholera: clinical and morphological forms, complications, causes of death.  
Bacterial infections: diphtheria, scarlet fever, meningococcal infection, whooping cough  
cough and viral childhood diseases.
1. Morphological characteristics, complications, consequences, causes of death in respiratory viral infections.
2. Morphological characteristics, complications, consequences, causes of death in flu.
3. Morphological characteristics, complications, consequences, causes of death in parainfluenza
4. Morphological characteristics, complications, consequences, causes of death in adenovirus infection, RC infection.
5. Morphological characteristics, complications, consequences, causes of death in typhus.
6. Morphological characteristics, complications of infectious diseases of the brain (viral, tick-borne encephalitis).
7. Morphological characteristics, complications of prion lesions of the central nervous system.
8. Morphological characteristics, complications, causes of death in AIDS.
9. Morphological characteristics, complications, consequences, causes of death in corona virus infection.

10. Tissue reactions in tuberculosis.
11. Pathological anatomy of the primary tuberculosis complex.
12. Morphology of progression of primary tuberculosis.
13. Pathological anatomy of chronic primary tuberculosis.
14. Morphological characteristics, complications, consequences, causes of death in hematogenous tuberculosis with predominant lung damage.
15. Morphological characteristics, complications, consequences, causes of death in hematogenous tuberculosis with predominant damage to internal organs and the skeleton system.
16. Morphological characteristics, complications, consequences, causes of death in secondary tuberculosis.
17. Modern pathomorphosis of tuberculosis.
18. Clinical and anatomical forms of sepsis: septicemia, septicopyemia, septic (infectious) endocarditis.
19. Pathomorphology of congenital syphilis.
20. Pathomorphology of acquired syphilis.
21. Plague: clinical and morphological forms, complications, causes of death.
22. Tularemia: clinical and morphological forms, causes of death.
23. Anthrax: clinical and morphological forms, causes of death.
24. Morphological characteristics, complications, consequences, causes of death at malaria

### **References:**

Main:

1. Atlas of micropreparations in pathomorphology / I.I. Starchenko, B.M. Filenko, N.V. Royko, etc.; VDZU "UMSA". - Poltava, 2018.-190 p
2. Starchenko, S.O. Bilokon and others.. – Poltava: Tov. "ASMI" - 2018. - 190 p.
3. Fundamentals of pathology according to Robbins: in 2 volumes. Volume 1 / Vinay Kumar, Abul K. Abbas, John C. Astaire; translation of the 10th Eng. edition. Publisher: All-Ukrainian specialized publishing house "Medytsyna". – X II. - 2019. - 420 p.
4. Fundamentals of pathology according to Robbins: in 2 volumes. Volume 1 / Vinay Kumar, Abul K. Abbas, John C. Astaire; translation of the 10th Eng. edition. Publisher: All-Ukrainian specialized publishing house "Medytsyna". – X II. - 2019. - 420 p.
5. Pathomorphology. General pathomorphology: a study guide / edited by Ya. Ya. Bodnara, V.D. Voloshina, A.M. Romanyuk, V.V. Gargin. - New Book, 2020. - 248 p.
6. Pathomorphology of the main diseases of the cardiovascular system: study guide / I.I. Starchenko, B.M. Filenko, N.V. Royko – Poltava: "UMSA". - 2019. - 150 p.
7. Starchenko I.I. Pathomorphology of the main diseases of the maxillofacial region: academician. manual / I.I. Starchenko, B.M. Filenko, V.V. Chernyak ; "UMSA". – Vinnytsia: Nova Kniga, 2019. – 128 p.

8. Ctarchenko I.I. Special pathomorphology (basic course) for students of medical faculties of higher medical educational institutions of III-IV levels of accreditation / II Starchenko, N.V. Royko, B.M. Filenko. – Poltava, 2017. – 174 p.
9. Tuffaha S. A. Muin Immunohistochemistry in the diagnosis of tumors / S. A. Tuffaha Muin, S. G. Hychka, Husky Hans. - "Book Plus", 2018. - 336 p.
10. Essentials of pathology: textbook / Ya. Bodnar, A. Romanyuk, V. Voloshyn, V. Gargin - Kharkiv, "Planeta-Print" Ltd, 2020, 219 p.
11. Pathology: textbook / IVSorokina, VD Markovskiy, DI Halata et al.; edited by IVSorokina, VD Markovskiy, DI Halata. - Kyiv: AUS Medicine Publishing, 2019. - 328p. + 2 color inserts (8p. + 12p.).
12. Pathology: textbook / IVSorokina, VD Markovskiy, DI Halata et al.; edited by IVSorokina, VD Markovskiy, DI Halata. - 2nd edition. - Kyiv: AUS Medicine Publishing, 2020. - 328p. + 2 color inserts (8p. + 12p.).

Additional:

1. Benign neoplasms of bones of the maxillofacial area in children / P.I. Tkachenko, I.I. Starenko, S.O. Bilokin [and others] - P.: "UMSA", 2016. - 85 p
2. General pathomorphology / I.I. Starchenko, N.V. Royko, B.M. Filenko [et al.] – Poltava, 2016. – 136 p.
3. Zerbino D. D. Pathomorphology and histology: atlas / D. D. Zerbino, M. M. Bagriy, Y. Ya. Bodnar, V. A. Dibrova. – Vinnytsia: Nova Kniga, 2016. – 800 p.
4. Methods of morphological research / M.M. Baghrii, V.A. Dibrova, O.G. Papadynets, M.I. Grischuk; edited by M.M. Baghria, V.A. Dibrovyy – Vinnytsia: Nova Kniga, 2016. – 328 p.
5. Novoseltseva T.V. Pathology of sexual and endocrine systems / T.V. Novoseltseva, B.M. Filenko, N.I. Hasiuk - Poltava: LLC "ASMI", 2015. - 199 p.
6. Pathomorphology: national. / V.D. Markovskiy, V.O. Tumanskyi, I.V. Sorokina [and others]; edited by V.D. Markovsky, V.O. Tumanskyi. - K.: VSV "Medicine", 2015. - 936p.
7. Practicum on biopsy section course / I.I. Starchenko, A.P. Hasyuk, S.A. Proskurnya [etc.] – Poltava, 2016. – 160 p.