

ISSN 2414-634X

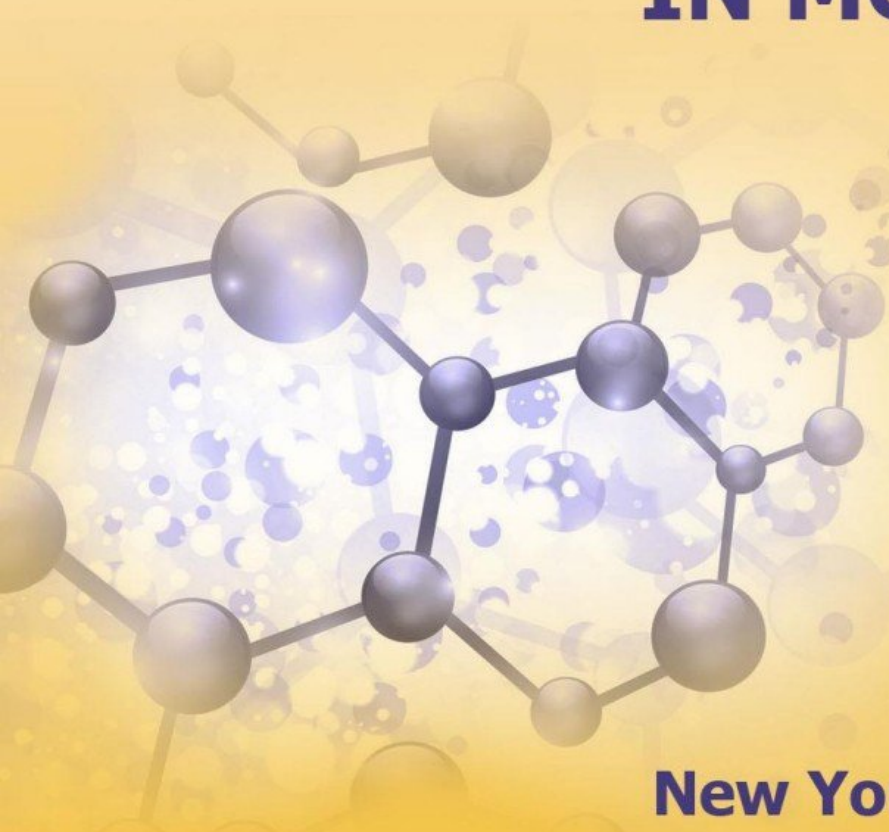
**scientific journal**

**INNOVATIVE  
SOLUTIONS  
IN MODERN  
SCIENCE**

**N 4(59)**

**New York 2023**

**publisher TK Meganom, LLC**



Innovative Solutions In Modern Science № 4(59), 2023

---

**ISSN 2414-634X**

**DOI 10.26886/ISMS.2414-634X.4(59)2023**

**SCIENTIFIC JOURNAL  
INNOVATIVE SOLUTIONS IN MODERN SCIENCE  
No. 4(59), 2023  
November 18, 2023**

FOUNDERS: CENTER FOR  
INTERNATIONAL COOPERATION  
TK MEGANOM, LLC  
WAS FOUNDED IN 2016  
IT IS ISSUED TEN TIMES A YEAR  
*<http://naukajournal.org/index.php/ISMSD>*

Edition address: 901 Dick Rm 238  
City Buffalo, State of New York  
14225  
Edition e-mail: [isms.publish@gmail.com](mailto:isms.publish@gmail.com)  
Phone: +16266394741  
© Center for international scientific  
cooperation TK Meganom LLC

Reprint of materials without the written permission of edition forbidden

Ulrichsweb™ Global Serials Directory



DOI (Digital object identifier)



Publishing house is a member of CrossRef



## Indexing:

CORE



WORLDCAT



BIELEFELD ACADEMIC SEARCH ENGINE



RESEARCHBIB



CITEFACTOR



GOOGLE SCHOLAR



## I. MEDICAL SCIENCES

DOI 10.26886/2414-634X.4(59)2023.1

UDC 616.5-006.39

### DIAGNOSTIC SIGNS AND METHODS OF TREATMENT OF PATIENTS WITH MALIGNANT NEOPLASMS OF THE SKIN OF THE EXTERNAL NOSE AND EAR

\*Fedir Yevchev, MD, PhD, DSc, Professor

<https://orcid.org/0000-0002-1630-811X>

\*Olga Titarenko, PhD

<https://orcid.org/0000-0002-6024-0757>

\*\*Anatolii Maletskyi, PhD

<https://orcid.org/0000-0002-7135-5218>

\*\*\*Vasily Bocharov, MD, PhD, DSc, Professor

<http://orcid.org/0000-0002-9786-6665>

\*\*\*Lyudmila Zubkova, MD, PhD, DSc, Professor

<http://orcid.org/0000-0001-7643-9317>

[dr.yevchev@ukr.net](mailto:dr.yevchev@ukr.net)

\*Odesa National Medical University, Ukraine, Odesa

\*\*SI The Filatov Institute of Eye Diseases and Tissue Therapy of NAMS of Ukraine, Ukraine, Odesa

\*\*\*Lviv Medical University, Ukraine, Lviv

*Today, the problem of diagnosing malignant diseases of the skin of the face, the medial corner of the eye and the trunk worries many researchers. This is due to the increase in recent years in the number of patients with malignant neoplasms of the skin, not only of the face, but also of the body. Malignant skin tumors are: squamous cell carcinoma, basal cell carcinoma, cylindroma (adenocystic carcinoma, basal cell carcinoma with hyaline stroma, cystadenoid carcinoma). Melanoma is a*

*skin tumor that develops from pigment (color) cells - melanoblasts. Cylindroma is an epithelial tumor characterized by the formation of cylindrical structures with stroma hyalinosis. The tumor is prone to infiltrating growth along nerve branches and trunks.*

*Objectively, in patients with BCC, it looks like a red formation protruding above the surface of the skin, which is covered with scales and has become hard over time. A bleeding ulcer forms in the center of the skin lesion. In patients with PKR, it objectively looks like a yellow scaly part, with a tender surface, which also bleeds when touched. An ulcer also forms at the site of such a lesion.*

*Conclusion. The effectiveness of treatment and 5-year survival of patients with malignant skin tumors depends on G, the stage of the disease and the spread of the process. To reduce the number of skin cancer diseases, it is necessary to carry out prevention, that is, to exclude the effects of harmful factors, to conduct sanitary and preventive conversations. Today it is known that the main method of treatment of patients with skin cancer is surgical with determination of the border of the tumor lesion.*

**Key words:** *skin cancer, diagnosis, treatment methods, malignant diseases, eye diseases*

**Introduction.** Today, the problem of diagnosing malignant diseases of the skin of the face, medial angle of eye and trunk worries many researchers. This is due to the increase in the number of patients with malignant neoplasms of the skin in recent years, not only of the face, but also of the trunk. Malignant skin tumors are: squamous cell carcinoma, basal cell carcinoma, cylindroma (adenocystic carcinoma, basal cell carcinoma with hyaline stroma, cystadenoid carcinoma). Cylindroma is an epithelial tumor characterized by the formation of cylindrical structures

with stroma hyalinosis. The tumor is prone to infiltrating growth along nerve branches and trunks.

Clinically and morphologically, three main types of malignant skin tumors are most common. The first two arise from a multi-layered squamous epithelium. Depending on the degree of maturity of the epithelial cells, squamous cell keratinizing and nonkeratinizing cancer are distinguished. Melanoma is a skin tumor that develops from pigment (color) cells - melanoblasts. According to the histological structure, several types of tumor are distinguished: spindle cell, epithelioid cell and polymorphous cell. Pigmentless (colorless) melanoma is rarely observed.

Codes of malignant formations - Basal cell (BCC) (C44) and squamous cell (SCC) (C44) skin cancer of the face and trunk. These tumors are often combined under the term "non-melanoma skin cancer" (NMSC). And the third is melanoma (M) (C43), which consists of melanocyte cells. The tumor is extremely aggressive, quickly and often metastasizes.

The main point in the differential diagnosis of malignant neoplasms of the skin is their determination by objective signs and subjective clinical symptoms. This will help to establish a clinical diagnosis, and a morphological conclusion will allow to establish a final diagnosis.

In recent years, there has been an increase in the number of superficial epithelial malignant neoplasms of the face and body in all countries of the world. Data from world literature show that the peak incidence of skin cancer occurs at the age of 60-70, but data from recent years indicate about its rejuvenation in connection with the spread of prolonged action exogenous and endogenous factors [1-5].

According to the National Cancer Registry of Ukraine, more than 20,000 new cases of non-melanoma disease are registered every year. It should be especially emphasized that, practical observations show that

the number of patients with tumor-like neoplasms of the skin of various origins has not only remained but also increased in recent years, therefore there is a threat that under certain conditions their morphological structure and clinical course may change [1, 3 , 6].

The standardized incidence rate of this pathology in Ukraine among men is 40.6 per 100,000 population and ranks first among all malignant neoplasms, and among women it is 49.7 per 100,000 population and ranks second after breast cancer. Of these, almost 70% of non-melanoma skin cancers are patients diagnosed with basal cell skin cancer. Thus, in Ukraine, according to the National Cancer Registry of Ukraine, in 2015, 1,362 new cases of malignant neoplasms of the head and neck were registered, and in 2017, 1,373 new cases of malignant neoplasms of the skin were registered. In general, in Ukraine, there are about 100 new cases per 100,000 population [1, 2, 3, 4, 5]. Compared to other regions, 471 cases of NMSC were registered in Odesa in 2020, and 894 cases in Kyiv [4]. That is, these data testify to the growth of malignant skin formations in Ukraine as a whole. At the same time, the incidence of skin cancer is increasing all over the world. Thus, according to Schart F.M., Gabbe C, the incidence of skin cancer in Germany among men is second only to lung cancer, and among women to breast cancer and is 93.4 and 55.8 per 100,000 population, respectively [5].

Thus, in Ukraine, as well as throughout the world, we have a steady increase in morbidity rates, in particular, the aging of the population is accompanied by an increase in the total number of skin cancers due to the increase in ultraviolet exposure.

It is known that BCC and SCC consist of abnormal cells of the squamous epithelium of the outer layer of the skin. SCC is divided into four types, which are marked with the letter G and reflect the differentiation of the tumor.

When examining a neoplasm, it is necessary to take into account the diagnostic criteria that are characteristic of a malignant neoplasm: size - more than 6 mm; uneven and blurred and jagged borders of the neoplasm; uneven colors of the affected part (from white to pink-brown or blue-black) and aggressive growth.

All patients with suspicion of malignant skin formations should consult a family doctor, who should know the objective clinical signs in order to make the right decision in the further examination. Therefore, we present the main clinical signs. Although one of the important prerequisites for improving the early diagnosis of tumors is increasing the oncological vigilance of doctors.

The process of diagnosing malignant skin tumors can be divided into the following stages. At the first stage, on the basis of minor complaints and weakly expressed signs of the disease with increasing symptoms, the doctor should suspect, that is, determine the suspicion of a tumor formation. The second stage is a targeted examination with the desired histological examination. And at the third stage, it is necessary to conduct a study to determine the boundaries of the tumor lesion. At this stage there is a need for additional methods of determining the tumor border. There are several known methods of determining the border of a tumor lesion: roentgenography, thermography, ultrasound, radionuclide imaging, SCT and nuclear magnetic resonance imaging. But today there are methods of visualization of the border of the tumor lesion intraoperatively.

Today it is known that the main method of treatment of patients with skin cancer is surgical. But it depends on the morphology and then the treatment can be complex or combined. As a rule, the first stage is surgical. Cases of widespread cancer are treated with symptomatic therapy.



So, objectively, in patients with BCC, it looks like a red formation protruding above the surface of the skin, which is covered with scales and has become hard over time. In the center of the skin lesion a bleeding ulcer forms. In patients with SCC, it objectively looks like a yellow scaly part, with a tender surface, which also bleeds when touched. An ulcer also forms at the site of such a lesion.

Patients have complains about itching and changes in the size of the neoplasm. Patients say that from the beginning, irritation of pink color appeared in the form of a flat formation with increased tissue on the periphery. After some time, the irritation changes to a red spot with an open ulcer, which does not heal for more than a month. To confirm the nature of the tumor process, a biopsy, preferably a total one, should be performed, which would allow determining the treatment.

**Results and their discussion.**The main increase in the incidence of malignant skin formations in recent years has been observed at the expense of older age groups.Objective clinical signs and the result of a morphological examination are sufficient to determine a clinical diagnosis and offer a treatment plan to a patient with suspected skin cancer or diagnosed skin cancer.

### **Conclusion**

1. The effectiveness of treatment and 5-year survival of patients with malignant skin tumors depends on G, the stage of the disease and the spread of the process.

2. To reduce the number of skin cancer diseases, it is necessary to carry out prevention, that is, to exclude the effects of harmful factors, to conduct sanitary and preventive conversations.

3. Today it is known that the main method of treatment of patients with skin cancer is surgical with determination of the border of the tumor lesion.

**References:**

1. Евчев Ф.Д., Евчева А.Ф. Етіологія, патогенез, клінічна семиотика і діагностика новоутворень шкіри голови, шиїтулуба. Повідомлення 1// Журнал вушних, носових і горлових хвороб. – 2018 № 1.- С. 76 – 82.
2. Ф.Д. Євчев, Д.І. Заболотний, А.Ф. Євчева. Діагностика та лікування хворих зі злоякісними новоутвореннями зовнішнього носа і вуха та тулуба. Посібник, «Астропринт» 2021.С.184.
3. Cancer in Ukraine, 2015 – 2016. Захворюваність, смертність, показники діяльності онкологічної служби 2017. Бюлетень національного канцер-реєстру України №18 (новий!).
4. Практична онкологія. Practical oncology Т. 13, №2 – 2012. 81.
5. Снарская Е.С., Молочков В.А. Базалиома. - М.: Медицина, 2003. - 136 с.
- Лукач Е.В., Чепурна О.М., Пашковський В.М. Ринологія №1, 2017 (1); С. 65 - 67. Лікування базальноклітинного раку зовнішнього носа методом фотодинамічної терапії.
6. Лукач Э. В. Проблеми і перспективи сучасної ЛОР – онкології в Україні // Онкологія. – 2000. – Т.2. №1-2.- - С.181-193.
7. Посібник «Клінічні рекомендації NCCN в онкології: пухлини голови та шиї, щитоподібної залози і шкіри». Squamous Cell Skin Cancer.

**References:**

1. Evchev F.D., Evcheva A.F. Etiolohiia, patohenez, klinichna semyotyka i diahnostyka novoutvoren shkiry holovy, shyiituluba. Povidomlennia 1. // Zhurnal vushnykh, nosovykh i horlovykh khvorob. – 2018 № 1.- S. 76 – 82.

2. F.D. Yevchev, D.I. Zabolotnyi, A.F. Yevcheva. Diahnostyka ta likuvannia khvorykh zi zloiakisnymy novoutvorenniamy zovnishnoho nosa i vukha ta tuluba. Posibnyk, «Astroprynt» 2021.S.184.

3. Cancerin Ukraine, 2015 – 2016. Zakhvoriuvanist, smertnist, pokaznyky diialnosti onkologichnoi sluzhby 2017. Biuleten natsionalnoho kantser-reiestru Ukrainy №18 (novyi!).

4. Praktychna onkologhiia. Practical oncology T. 13, №2 – 2012. 81.

5. Snarskaia E.S., Molochkov V.A. Bazalyoma. - M.: Medytsyna, 2003. - 136 s.

Lukach E.V., Chepurna O.M., Pashkovskiy V.M. Rynolohiia №1, 2017 (1); S. 65 - 67. Likuvannia bazalnoklitynnoho raku zovnishnoho nosa metodom fotodynamichnoi terapii.

6. Lukach E. V. Problemy i perspektyvy suchasnoi LOR – onkologii v Ukraini // Onkologhiia. – 2000. – T.2. №1-2.- - S.181-193.

7. Posibnyk «Klinichni rekomendatsii NCCN v onkologii: pukhlyny holovy ta shyi, shchytopydibnoi zalozy i shkiry». Squamous Cell Skin Cancer.

Citation: Fedir Yevchev, Olga Titarenko, Anatolii Maletskyi, Anatolii Maletskyi, Vasily Bocharov, Lyudmila Zubkova (2023). DIAGNOSTIC SIGNS AND METHODS OF TREATMENT OF PATIENTS WITH MALIGNANT NEOPLASMS OF THE SKIN OF THE EXTERNAL NOSE AND EAR. New York. TK Meganom LLC. Innovative Solutions in Modern Science. 4(59). doi: 10.26886/2414-634X.4(59)2023.1

Copyright: Fedir Yevchev, Olga Titarenko, Anatolii Maletskyi, Anatolii Maletskyi, Vasily Bocharov, Lyudmila Zubkova ©. 2023. This is an openaccess article distributed under the terms of the Creative Commons Attribution License (CC BY). The use, distribution or reproduction in other forums is permitted, provided the original author(s) or licensor are credited and that the original publication in this journal is cited, in accordance with accepted academic practice. No use, distribution or reproduction is permitted which does not comply with these terms.