

**MINISTRY OF HEALTH PROTECTION OF UKRAINE
ODESA NATIONAL MEDICAL UNIVERSITY**

**International faculty
Department of Internal Medicine № 1**

APPROVED
Vice-rector for research and educational work
Eduard Buryachkovskiyi
«____», 2023



**Methodical development for practical classes
in the academic discipline**

faculty, course: 6th year, international
Academic discipline: "Internal Medicine"

Approved:

Meetings of the department of internal medicine No. 1 of the Odesa National Medical University

Protocol No.1 from September "05", 2023

Head of the department _____ (Yurii KARPENKO)



Developers:

Karpenko Yurii Ivanovich, professor
Zolotarova Natalia Artemivna, profesor
Poliakov Anatolii Yevheniiiovych, profesor
Izha Hanna Mykolaivna, assosiate professor
Kryzhanovskiy Yurii Mykolaiovych, assosiate professor
Pavlovska Kateryna Mykolaivna, assosiate professor
Potapchuk Oleksandr Vasylovych, associate professor
Savelieva Olha Valeriivna, assosiate professor
Shukhtina Iryna Mykolaivna, assosiate professor
Alavatska Tetiana Vasylivna, assistant
Blikhar Olena Volodymyrivna, assistant
Bondarenko Olha Vitaliivna, assistant
Hunenko Iryna Ihorivna, assiatant
Kravtsova Kateryna Volodymyrivna, assistant
Maistrenko Mariia Serhiivna, assistant
Mytrokhina Nadiya Anatoliivna, assistant
Pashaieva Viktoriia Faikivna, asssistant
Riabinina Anna Hennadiivna, assistant
Sukhina Yuliia Oleksandrivna, assistant
Ukhan Viktoriia Viktorivna, assistant
Yanvarova Olha Yuriivna, assistant
Yurdanova Ilona Heorhiivna, assistant
Zolotarova Kseniia Olehivna, assistant

Topic 1. Management of a patient with arterial hypertension

The main goals: to acquire communication skills and skills of clinical examination and treatment of a patient with arterial hypertension

Key words: definition of arterial hypertension; modern classification of hypertension by degree, stage, risk according to the SCORE scale; method of measuring blood pressure; evaluation of the results of the following research methods: DMAT, ECG, Holter monitoring, Echo-CS, ultrasound of brachiocephalic arteries, Ankle-brachial Index, lipidograms; mechanisms of action of the main five groups of drugs; main contraindications and side effects of hypotensive drugs; tactics of hypotensive therapy in a patient with concomitant pathology.

Equipment:multimedia materials - a set of thematic slides from the department's multimedia library; electronic versions of ECG with signs of LVH; screenshots of the results of daily blood pressure monitoring, a set of situational problems on the subject of the lesson.

Plan:

1. Organizational measures (greetings, verification of those present, announcement of the topic, purpose of the lesson, motivation of higher education seekers to study the topic).
2. Control of the reference level of knowledge (checking homework, written work, written testing, including writing KROK-2 tests, frontal survey)
3. Formation of professional abilities and skills (mastery of skills, curation, determination of treatment regimen, laboratory research, etc.): discussion of features of diagnosis and treatment of arterial hypertension, the most common clinical manifestations, criteria for establishing a diagnosis
4. Summing up (summarizing the topic, evaluating applicants, discussing the next lesson topic and homework)

Control questions:

1. Explain main causes of Arterial hypertension:
2. What laboratory tests are helpful in differentiating hypertension of endocrine and renal origin?
3. Which objective signs of organic damage to target organs account for the establishment of stage II hypertension?
4. What objective signs of organ damage for target organs accounts for stage III hypertension?
5. The main risk factors, which are used to assess the overall risk of complications in arterial hypertension:
6. List of target-organ damage, which are used to assess the overall risk of complications of arterial hypertension:
7. What co-morbidities, which are accounted in assessing the overall risk of complications in Arterial hypertension?
8. What laboratory and instrumental examinations are necessary to be assigned in patients with high blood pressure?
9. What are the values of diagnostic results in ambulatory blood pressure monitoring?
10. Tactics of a doctor in case of detection of hypertension.
11. Specify electrocardiographic signs of left ventricular hypertrophy which are characteristic for hypertension.

MCQ's:

1. What is the type of arterial hypertension, if the blood pressure is still not within the target levels on the intake of at least 4 antihypertensive drugs?
 - A. Malignant hypertension
 - B. Symptomatic hypertension
 - C. Reactive hypertension
 - D. Resistant hypertension
 - E. Asymptomatic hypertension
2. 60-year-old male, who suffers from hypertension since 20 years, suddenly develops an attack of

breathlessness after a stressful situation. On examination: orthopnoeic position, heart rate - 120/min., BP - 210/120 mm Hg, tones over the heart apex are weakened, additional tone in diastole is present, respiratory rate - 32/min. Respiration sounds are weakened over the lower parts of the lungs, crepitative rales are heard. What complication did patient develop?

- A. Aortic dissection
- B. Hysteria
- C. Pulmonary thromboembolism
- D. Pneumonia
- E. Acute left ventricular failure

3. A 30 years old female complains of increasing blood pressure, pronounced weakness, convulsions, rapidly disappearing paresis, palpitations, dizziness, headache. Sufferes from hypertension for 3 years. The ECG: HR=88/min., prolongation of QT interval, ST depression in V1-V6, negative T waves in V3- V6. Urine: the reaction is alkaline, relative density - 1010, transparent, no protein and sugar, urinary sediment within normal. The blood level of potassium-2,9mmol/L, sodium 160 mmol/L. What pathology led to hypertension?

- A. Pituitary - Cushing
- B. Hypertension Stage II.
- C. Hypertension Stage III.
- D. Cohn's syndrome
- E. Chronic pyelonephritis

4. The patient aged 35, complains of increasing blood pressure, headache, tinnitus, palpitations. On objective examination: Pulse - 100/min., rhythmic, intense. BP - 240/100 mmHg. On percussion the left border of the heart is shifted 1 cm to the left, heart sound over the apex are weak, accentuation of II tone over aorta. Systolic murmur is auscultated on both sides from umbilicus. What pathology most likely determines the clinical picture?

- A. Stenosis of the renal arteries
- B. Hypertension
- C. Chronic glomerulonephritis
- D. Nephroptosis
- E. Cohn Syndrome

5. A 32-year-old woman complains of dizziness, headache, palpitation, tremor. For the last several months she has been under outpatient observation for increased arterial pressure. Since recently such attacks have become more frequent and severe. Objectively: the skin is covered with clammy sweat, tremor of the extremities is present. HR110/min., BP- 220/140 mm Hg. Heart sounds are muffled. Blood test results: WBCs- $9,8 \cdot 10^9/l$, ESR- 22 mm/hour. Blood glucose - 9,8 millimole/l. What disease is the most likely cause of this crisis?

- A. Pheochromocytoma
- B. Essentialhypertension
- C. Preeclampsia
- D. Primaryhyperaldosteronism
- E. Diabeticglomerulosclerosis

6. 45 year-old patient suffers with severe weakness, polyuria, increased blood pressure - up to 210/120 mmHg. In the blood test: potassium - 3,12 mmol/L (low), sodium - 148 mmol/L (upper normal), aldosterone - 715 pmol/L (hight). The most likely diagnosis:

- A. Hypertension stage III, CHF stage II B
- B. Cushing Syndrome
- C. Chronic pyelonephritis, chronic renal failure
- D. Diabetic glomerulosclerosis, chronic renal failure
- E. Conn's Syndrome

7. Patient 32 years old, complains of intermittent dizziness, headache, nasal bleeding, pain in the heart, hand muscle weakness. Objective examination: physical development is asymmetric (the muscles of the upper half of the body are hypotrophic, while muscles of the pelvis and lower limbs are normal), hands are cold to the touch. Pulse - 86/min., rhythmic, BP on left hand - 200/100 mmHg, right hand - 180/90 mmHg. What diagnosis should be suspected in the first place?

- A. Hypertension
- B. Aortic dissection
- C. Cardiopsychoneurosis
- D. Takayasu disease
- E. Vascular occlusive disease of lower extremities

8. 17-year-old male passes medical examination before military service. Has no complaints, BP - 180/110 mm Hg. In childhood had measles, scarlet fever, some "kidney disease". Height - 165 cm, weight - 68 kg, RR - 15/min., pulse - 80/min., rhythmical. Rough systolic murmur with maximum in the III intercostal space left of the sternum. BP(feet) - 100/55 mmHg., body temperature - 36,6° C. What is the most likely diagnosis?

- A. Cardiopsychoneurosis
- B. Hypertension
- C. Aortic dissection
- D. Aortic stenosis
- E. Takayasu's disease

9. A 62-year-old man addressed a urologist with complaints of frequent urination at night (5-6 times per night), sensation of incomplete voiding of the urinary bladder, pain in the lower abdomen, slow urination. Anamnesis: the II degree essential hypertension (peak BP is 160/100 mm Hg). Current case: the II degree enlargement of the prostate gland, PSA is 2,2 ng/ml. Select the drug suitable for long- term therapy of the patient's combined pathology:

- A. Doxazosin
- B. Propranolol
- C. Indapamide
- D. Amlodipine
- E. Captopril

10. During the baseline medical examination a 43 years old factory worker revealed arterial blood pressure 174/104 mmHg, in 2 weeks – 166/98 mmHg. No complaints. Reports having no diseases previously. Last year BP was 146/95 mmHg. Heart rate – 90/min. Smokes 2 packs of cigarettes a day and is overweight. The most rational therapy tactics is:

- A. Prescribe ACE-inhibitors + thiazides, recommend changing lifestyle
- B. Prescribe amlodipine + herbal supplements
- C. Hospitalize patient immediately
- D. Treat with drug-free methods (diet, smoking cessation, physical activity)
- E. Issue disability certificate

Clinical Tasks:

Task № 1

The cardiologist asked the woman, aged 40, complaining of a persistent increase in arterial blood pressure to 200/110 mmHg within 6 months, headache, thirst, expressed general weakness. In general, the blood test: no changes. In general, the urine analysis: alkaline reaction, specific gravity 1005, 0 protein, 015 g/l sugar(-), Leukocytes 2-3in n/s. In the biochemical analysis of blood: total protein 75 g/l, glucose 4.4 mmol/L, total bilirubin 12 mmol/L, urea 5.1 mmol/L, creatinine 72 mmol/L, Na 155 mmol/L, K 2.9 mmol/L, total cholesterol 4.9 mmol/L. The ECG: sinus rhythm, right, HR= 75/min, T wave flattening, expressed U wave, signs of hyperthrophy of the left ventricle (LV). At CHD: small hypertrophy of the walls of LV EF= 67%, LV diastolic dysfunction type-I. The patient's ratio of aldosterone/renin activity of blood plasma is 54.

Questions:

1. What the cause of hypertension? Formulate a clinical diagnosis.
2. What instrumental methods in addition to apply for further diagnosis?

Task № 2

Patient 44 years old has headache, internal tremor, palpitations, fear. OBJECTIVE: Pulse- 100/min, BP- 200/100mmHg, the left border of cardiac dullness is shifted 1.5cm to the left sternocladimastoidous line, the sonorous tones of the heart, vesicular breathing. The ECG- sinus

tachycardia, signs of left ventricular hypertrophy.

Questions:

1. Formulate a clinical diagnosis.
2. Make a clinical examination of the patient.

Task № 3

Patient 35 years old, complains of headache, palpitation, discomfort behind sternum, chills which last 30-60 minutes. **OBJECTIVE:** pale skin, eyes enlarged. HR- 160/min. BP-240/130 mmHg. During the attack, a blood test: A- 11 h109/L, blood sugar- 9.6 mmol/L. The ultrasonography revealed the formation of a three-dimensional projection of the right adrenal gland.

Questions:

1. Formulate a preliminary clinical diagnosis.
2. Make a plan of clinical examination of the patient.

Summary:

Recommended reading list

Basic literature:

- Harrison's Principles of Internal Medicine Self-Assessment and Board Review, 20th Edition 20th Edition.- (August 13, 2021). - 736 pages
- Pocket Medicine: The Massachusetts General Hospital Handbook of Internal Medicine / 007 edition (12 Sept. 2019). - 272 pages
- Davidson's Principles and Practice of Medicine: Enhanced Digital Version Included / Elsevier; 23rd edition (25 April 2018). - 1440 pages

Additional literature:

- Macleod's Clinical Examination /Elsevier; 14th edition (11 Jun. 2018). - 400 pages
- Current Medical Diagnosis and Treatment /McGraw-Hill Education; Updated edition (14 Sept. 2021). - 1840 pages
- Lippincott Connect Standalone Courseware for Bates' Guide to Physical Examination and History Taking 1.0 /LWW; 13th ed. edition (23 Mar. 2023).
- Step-Up to Medicine / Wolters Kluwer Health; 5th edition (8 May 2019). - 582 pages
- Goldman-Cecil Medicine, 2-Volume Set (Cecil Textbook of Medicine) / Elsevier; 26th edition (20 Dec. 2019). - 2944 pages
- The Washington Manual of Medical Therapeutics / Wolters Kluwer Health; 36th edition (6 Jun. 2019). - 1074 pages
- Harrison's Manual of Medicine / McGraw-Hill Education; 20th edition (5 Nov. 2019). - 1245 pages

Electronic information resources

- World Health Organization. URL: www.who.int/ru/index.html.
- European Regional Office of the World Health Organization. URL: www.euro.who.int.
- <https://www.aasld.org/>
- https://academic.oup.com/ndt/pages/General_Instruction
- <https://cprguidelines.eu/>
- <https://www.escardio.org/Guidelines/Clinical-Practice-Guidelines>
- <http://www.oxfordmedicaleducation.com/>
- <http://ard.bmj.com>
- <https://www.escardio.org/Guidelines/Clinical-Practice-Guidelines>

Practical class

Topic 2. Management of a patient with heart rhythm disorders.

The main goals: to acquire communication skills and skills of clinical examination of a patient with arrhythmia, to be able to diagnose emergency conditions in patients with heart rhythm disorders, to master the tactics of providing emergency medical care to patients with heart rhythm disorders; to be able to perform therapeutic manipulations in patients with arrhythmias.

Key words: modern classification of heart rhythm disorders, its main classifications; pathophysiological mechanisms and the most frequent etiological factors of arrhythmias; ECG diagnosis of various variants of arrhythmias; instrumental methods of diagnosing arrhythmias, diagnostic possibilities and indications for carrying out ECG, HM ECG, Echocardiography, electrophysiological research; classification and clinical pharmacology of antiarrhythmic drugs; modern standards of treatment of arrhythmias; methods and indications for electroimpulse therapy; surgical methods of treatment of cardiac arrhythmias, indications for their use; primary and secondary prevention of arrhythmias.

Equipment: multimedia materials – a set of thematic slides from the department's multimedia library; electronic versions of ECG with various types of arrhythmias; screenshots of the results of daily monitoring of ECG, Echocardiography; a set of situational problems on the subject of the lesson.

Plan:

1. Organizational measures (greetings, verification of those present, announcement of the topic, purpose of the lesson, motivation of higher education seekers to study the topic)
2. Control of the reference level of knowledge (checking homework, written work, written testing, including writing KROK-2 tests, frontal survey)
3. Formation of professional abilities and skills (mastery of skills, conducting curation, determining the treatment scheme, conducting laboratory research, etc.): discussion of the features of diagnosis and treatment of patients with heart rhythm disorders, the most common clinical manifestations, criteria for establishing a diagnosis.
4. Summing up (summarizing the topic, evaluating applicants, discussing the next lesson topic and homework)

Control questions:

1. Compare the physical examination and electrocardiographic signs of atrial and ventricular arrhythmia and atrial fibrillation.
2. Describe the clinical and electrocardiographic signs of sinus syndrome and the Wolff-Parkinson-White's syndrome.
3. List the laboratory tests needed to establish the causes of arrhythmias.
4. Indicate the diagnostic value of daily Holter monitoring, echocardiography, electrophysiology study; list the indications for their purpose.
5. Complete the table, which describes the main classes of anti-arrhythmic drugs

Class, group	Electrophysiological mechanism	Drugs	Possible side effects
IA			
IB			
IC			
II			
III			
IV			

6. Standards of patients with extrasystole arrhythmia treatment.
7. Standards of patients with atrial fibrillation treatment.
8. Indications for electric pulse therapy.
9. Describe the possible surgical methods of arrhythmia treatment.
10. Primary and secondary cardiac arrhythmias prevention.
11. Prognosis and operability of patients with cardiac arrhythmias.

MCQ's

1. The patient, 72 years old, with a history of non-Q-wave myocardial infarction complains of palpitations, shortness of breath at moderate exertion. Objectively: the rhythm of cardiac activity is irregular, heart rate – 96/min., weakened heart sounds, systolic murmur over aorta, RR – 16/min. ECG: the absence of P waves in all leads, different RR intervals, T-waves are better expressed in chest leads. What kind of arrhythmia should we think about?
A. Atrial fibrillation

- B. Ventricular extrasystoles
- C. Atrial extrasystoles
- D. Atrio-ventricular block
- E. Paroxysmal tachycardia

2. A 35 years old patient suddenly develops episode of heartbeat, shortness of breath and a dull pain in the heart after physical exertion. History: for 12 yrs suffers from rheumatism, but without heart failure. Objectively: BP: 110-130/85 mmHg, pulse – 96 per min., heart rate – 130 per min. The ECG shows small waves of different shapes instead of P-waves, RR intervals have different durations. What is the most likely diagnosis?

- A. Atrial flutter.
- B. Supraventricular paroxysmal tachycardia.
- C. Atrial fibrillation.
- D. Ventricular paroxysmal tachycardia.
- E. Respiratory arrhythmia.

3. 46 year old patient, complains of sudden “heart attacks”, which are accompanied by pulsations in the area of neck, headache, nausea. The palpitation lasts for 15-20 minutes and stops after breath-hold with straining. What kind of rhythm disorder can be suspected?

- A. Paroxysm of atrial fibrillation
- B. Episode of ventricular paroxysmal tachycardia
- C. Atrial flutter
- D. Episode of supraventricular paroxysmal tachycardia
- E. Extrasystolic arrhythmia

4. 56 year-old patient, came to a local doctor with complaints of repeated intense nose bleeding. History: at the age of 18 he was treated from the acute rheumatic fever, for the last 6 years has constant form of A-fib, takes metoprolol 100 mg daily for rate control and warfarin for thrombosis prophylactics. ECG: atrial fibrillation with ventricular rate of 70/min. INR: 3,1. In order to decrease bleeding risk you decide to change anticoagulation therapy. Your choice is:

- A. Aspirin
- B. Clopidogrel
- C. Heparin
- D. Dabigatran
- E. Alteplase

5. 45 years-old male with myocardial infarction in the left ventricle anterior wall felt "pauses" in the heart rhythm, increased weakness. ECG: sinus rhythm, heart rate – 78/min. Periodically 2-3 extended ventricular complexes of more than 0,18 sec. appear, they are irregular, have polymorphic forms, after each one of them full compensatory pause is present. What is the complication of myocardial infarction?

- A. Intraventricular block
- B. Atrial extrasystoles
- C. Nodal extrasystoles
- D. Ventricular tachycardia
- E. Ventricular extrasystoles

6. 52 years old male, an engineer, complains of intermittent occurrence of palpitation attacks, which last 3-8 minutes and disappear on their own. Repeated examinations and ECG study did not show arrhythmias. What instrumental investigation should be performed to identify the arrhythmia in this patient?

- A. Ergometer testing
- B. Trans-esophageal electrostimulation of the heart
- C. Holter ECG monitoring
- D. Intra-cardiac electrophysiological study
- E. Percutaneous coronary angiography

7. 74 years old male, visited the physician with complaints of slow weak urination. Presents no complaints related to the heart. The examination reveals possible atrial fibrillation: heart rate 72/min., irregular, with alternating amplitude, without pulse deficit. Symptoms of heart failure are absent. ECG

confirms the presence of atrial fibrillation. From history it is known that arrhythmia was revealed three years ago. What should be the tactics of the therapist about the atrial fibrillation treatment?

- A. Prescribe digoxin
- B. Prescribe aspirin under the control of clotting time
- C. Prescribe verapamil under the control of heart rate
- D. Prescribe clopidogrel
- E. Prescribe warfarin under the control of the INR (2,0-3,0)

8. Patient, who is in the intensive care unit for the first day after acute myocardial infarction, develops ECG-changes: ventricular extrasystoles, 10-15/min., sometimes paired or in short-term episodes of ventricular tachycardia. In this situation, the best choice is to introduce:

- A. Amiodarone
- B. Novocainamide
- C. Lidocaine
- D. Verapamil
- E. Anaprilin

9. A 67 y.o. patient complains of palpitation, dizziness, noise in ears, feeling of shortage of air. Objectively: pale, damp skin. Vesicular respiration, respiratory rate- 22 per min, pulse- 200 bpm, AP – 100/70 mm Hg. On ECG: heart rate- 200 bpm, ventricular complexes are widened, deformed, location of segments ST and of wave T is discordant. The wave P is not changed, superimposes QRST, natural conformity between P and QRS is not present. What kind of arrhythmia is present?

- A. Paroxysmal ventricular tachycardia
- B. Sinus tachycardia
- C. Atrial flutter
- D. Ventricular extrasystole
- E. Atrial tachycardia

10. The patient, 55 years old, with a diagnosis of variant (vasospastic) angina has frequent paired ventricular extrasystoles. Takes amiodarone in the everyday dose of 200 mg per day. The function of which organ must be controlled?

- A. Stomach
- B. Kidney
- C. Pancreas
- D. Liver
- E. Thyroid gland

Clinical tasks:

Task № 1

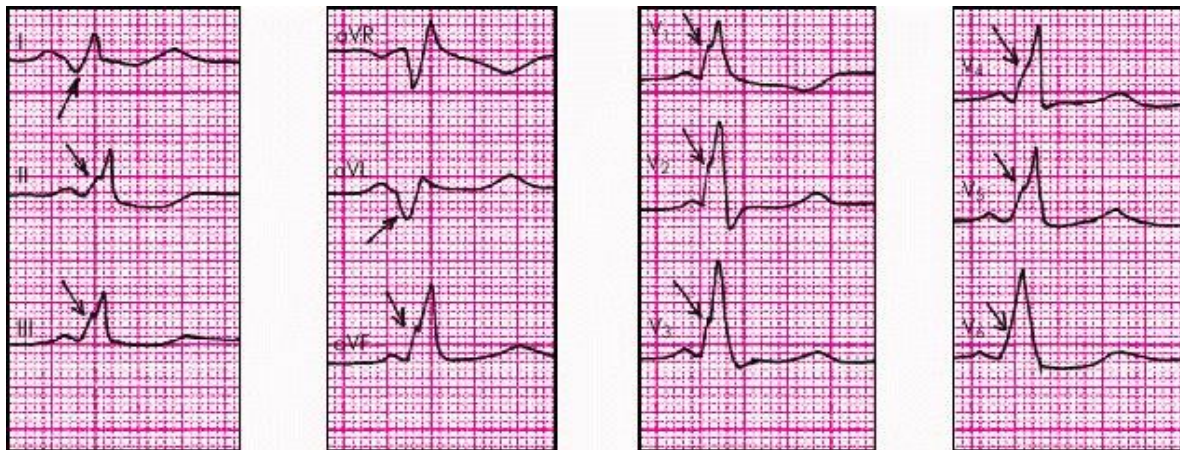The patient, 52 years old, was operated on for mitral heart defect with prosthetic valve. Suddenly, at night he had the feeling of palpitations. OBJECTIVE: ESR -26 mm / h. Leukocytes – 9,8 g / liter. CRP + +. BP – 135/80 mm Hg. HR – 108/min., pulse – 88/min. The ECG: P absent, QRS unchanged, Pr = 0,88-0,60 sec., Waves f.

Questions:

- 1) To formulate a preliminary diagnosis.
- 2) Designate an emergency treatment for the cardiac rhythm resumption.
- 3) Make a plan of patient examination.
- 4) Assign the treatment

Objective № 2

Female 20 years old, complains of palpitations attacks, which are accompanied by dizziness, shortness of breath and aching pain in the cardiac apex. Sick for about 10 months. In the early episodes were observed 1-2 times a month, were short-lived. Recently, attacks have become more frequent. OBJECTIVE: heart sounds sonorous, rhythmic. Heart rate – 80/min., BP – 120/90 mm Hg. Abdomen is soft, painless. ECG of the patient in interictal period is presented in the figure.



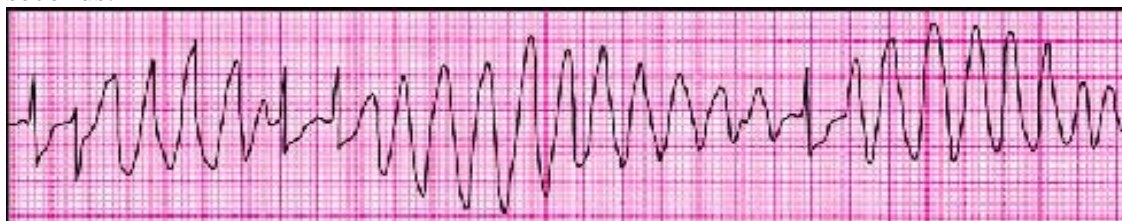The ECG during the attack: heart rate – 180/min., T waves merge with R.

Questions:

- 1) • What type of arrhythmia is diagnosed in a patient?
- 2) • How to conduct prevention and management of paroxysmal tachycardia in these patients?
- 3) • What are the indications for surgical treatment of such conditions?

Task № 3

The patient, 28 years old, a history of mitral valve prolapse, body mass index 34.5 kg/m². To reduce the weight took a combination of drugs with a diuretic effect for a long time. In the last week there were three episodes of sudden pain behind the sternum, accompanied by palpitations, dizziness, lasted several minutes. A ECG, which at the time of attack has registered the following changes within 75 seconds:



Questions:

- 1) Describe the discovered polymorphic ventricular arrhythmias.
- 2) What reasons · and medications can provoke this kind of arrhythmia?
- 3) Make a plan of examination and treatment of patients.

Summary:

Recommended reading list

Basic literature:

- Harrison's Principles of Internal Medicine Self-Assessment and Board Review, 20th Edition 20th Edition.- (August 13, 2021). - 736 pages
- Pocket Medicine: The Massachusetts General Hospital Handbook of Internal Medicine / 007 edition (12 Sept. 2019). - 272 pages
- Davidson's Principles and Practice of Medicine: Enhanced Digital Version Included / Elsevier; 23rd edition (25 April 2018). - 1440 pages

Additional literature:

- Macleod's Clinical Examination /Elsevier; 14th edition (11 Jun. 2018). - 400 pages
- Current Medical Diagnosis and Treatment /McGraw-Hill Education; Updated edition (14 Sept. 2021). - 1840 pages
- Lippincott Connect Standalone Courseware for Bates' Guide to Physical Examination and History Taking 1.0 /LWW; 13th ed. edition (23 Mar. 2023).
- Step-Up to Medicine / Wolters Kluwer Health; 5th edition (8 May 2019). - 582 pages
- Goldman-Cecil Medicine, 2-Volume Set (Cecil Textbook of Medicine) / Elsevier; 26th edition (20 Dec. 2019). - 2944 pages
- The Washington Manual of Medical Therapeutics / Wolters Kluwer Health; 36th edition (6 Jun.

2019). - 1074 pages

- Harrison's Manual of Medicine / McGraw-Hill Education; 20th edition (5 Nov. 2019). - 1245 pages

Electronic information resources

- World Health Organization. URL: www.who.int/ru/index.html.
- European Regional Office of the World Health Organization. URL: www.euro.who.int.
- <https://www.aasld.org/>
- https://academic.oup.com/ndt/pages/General_Instruction
- <https://cprguidelines.eu/>
- <https://www.escardio.org/Guidelines/Clinical-Practice-Guidelines>
- <http://www.oxfordmedicaleducation.com/>
- <http://ard.bmj.com>
- <https://www.escardio.org/Guidelines/Clinical-Practice-Guidelines>

Practical class

Topic 3. Management of a patient with impaired cardiac conduction.

The main goals: to acquire communication skills and skills of clinical examination of a patient with impaired conduction, to be able to diagnose emergency conditions in patients with impaired conduction, to master the tactics of providing emergency medical care to patients with impaired conduction, as well as to be able to perform medical manipulations in this category of patients.

Key words: diseases that can be complicated by conduction disorders; ECG criteria of the following disorders: SA-blockade, AV-blockade of the I, II, III degree, His bundle blockades and their clinical manifestations; instrumental studies of a patient with a conduction disorder: ECG, Holter monitoring, Echo-CS; the main drugs used to treat conduction disorders; indications for temporary and permanent cardiac stimulation; indications for PM implantation; prognosis and work capacity in patients with cardiac conduction disorders.

Equipment: multimedia materials - a set of thematic slides from the department's multimedia library; electronic versions of ECG with various types of conduction disturbances; screenshots of the results of daily monitoring of ECG, echocardiography; a set of situational problems on the subject of the lesson.

Plan:

1. Organizational measures (greetings, verification of those present, announcement of the topic, purpose of the lesson, motivation of higher education seekers to study the topic)
2. Control of the reference level of knowledge (checking homework, written work, written testing, including writing KROK-2 tests, frontal survey)
3. Formation of professional abilities and skills (mastery of skills, curation, determination of treatment regimen, laboratory research, etc.): discussion of features of diagnosis and treatment of arterial hypertension, the most common clinical manifestations, criteria for establishing a diagnosis
4. Summing up (summarizing the topic, evaluating applicants, discussing the next lesson topic and homework)

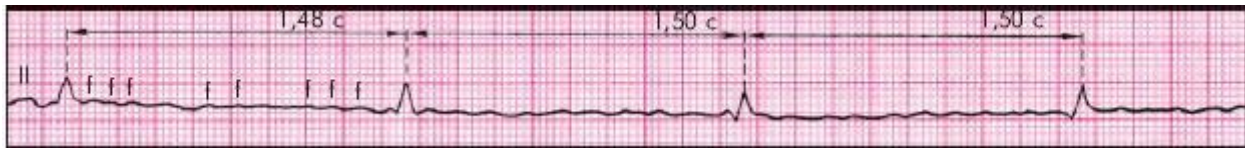
Quiz:

1. Classification of atrioventricular conduction disorders.
2. Compare the clinical and electrocardiographic signs of AV block of various degrees.

AV block I degree	Heart sounds, pulse	Duration, PQ (PR)	RR intervals and RR	QRS
II degree AV block, type Mobitz I				
II degree AV block, type Mobitz II				
II degree AV block, Type III				

III degree AV block				
----------------------------	--	--	--	--

3. Describe the ECG signs of Fredericks' syndrome. What myocardial diseases are characterized by such disorders?



4. Compare ECG signs of His bundle branch block.

	Regulation E. axis of the heart	QRS width	Deformation of QRS in precordial leads	Deformation of QRS in I, aVL, V6 leads	Violations of repolarization
Complete block of LHB					
Complete block of RHB					

5. What additional laboratory and instrumental analysis should be appointed to establish the genesis and severity of cardiac arrhythmias?

6. Drug treatment of patients with AV block.
7. Indications for temporary and permanent cardiostimulation.
8. Types of implantable pacemakers, defibrillators, cardioverters. Features of their differential use.
9. Primary and secondary prevention of cardiac conduction disorders.
10. Determination of prognosis and performance in patients with impaired cardiac conduction.

MCQ's:

1. Male patient aged 70, complains of recurrent episodes of weakness, which are accompanied by pain in the heart, weakness, dizziness. Objective: acrocyanosis, pulse - 38/min., rhythmical, BP - 150/90 mm Hg. Heart borders expanded to the left. Ist sound above the apex is changed: from time to time is heard as Strazhesko "gun-tone". The ECG: atrial and ventricular complexes occur in independent rhythmical pattern. What is the most likely diagnosis?
 - A. Sinus block
 - B. Complete atrioventricular block
 - C. Sick sinus syndrome
 - D. Sinus bradycardia
 - E. Epilepsy
2. 62 year-old female complains of "discomfort" sensation in the heart area, intermittent palpitation, general weakness. Notes progressing of described symptoms for several months. Visited a doctor because of a brief episode of vertigo with loss of consciousness several days ago. Objective examination: Pulse - 52/min., arrhythmic. No murmurs on auscultation. ECG: sinus rhythm, irregular, P- Q interval = 0,20 sec., QRS = 0,08 sec, a gradual decrease of RR interval with subsequent absence of PQRST. What is the most likely cause of this condition?
 - A. II degree atrioventricular block
 - B. I degree atrioventricular block
 - C. II degree sinus block
 - D. III degree atrioventricular block
 - E. Trifascicular blockage of His' bundle leg
3. The patient aged 70, complains of weakness, dizziness, short periods of unconsciousness, pain in the heart. Auscultation: heart rate - 40/min., heart sounds are rhythmic, decreased loudness of Ist sound, periodically greatly increased. BP - 180/90 mm Hg. What is the most likely cause of

hemodynamic disturbances in the patient?

- A. Bradisystolic atrial fibrillation
- B. I degree atrioventricular block
- C. III degree atrioventricular block
- D. Sinus bradycardia
- E. Complete Hiss' bundle left branch block

4. A 53-year-old female patient complains of cardiac pain and rhythm intermissions. She has experienced these presentations since childhood. The patient's father had a history of cardiac arrhythmias. Objectively: the patient is in grave condition, Ps- 220 bpm, AP- 80/60 mm Hg. ECG results: heart rate - 215/min, extension and deformation of QRS complex accompanied by atrioventricular dissociation; positive P wave. Sometime later heart rate reduced down to 45/min, there was a complete dissociation of P wave and QRST complex. Which of the following will be the most effective treatment?

- A. Calcium antagonists
- B. beta-adrenoreceptor blocking agents
- C. Cholinolytics
- D. Implantation of the artificial pacemaker
- E. Cardiac glycosides

5. A 38-year-old patient was diagnosed a complete left bundle branch block (LBBB), that newly appeared while him being treating acute infectious-allergic myocarditis. After 2 months of treatment and ambulatory observation the patient's general condition is satisfactory. No complaints, shows normal objective and laboratory findings, but ECG changes persist. What is indicated for this patient?

- A. Electrophysiological examination
- B. Referral to medical expertise
- C. Installing the pacemaker
- D. Rehospitalization
- E. Observation of a physician

6. Generalized low voltage on an ECG (QRS deflection < 5 mm in limb leads and < 10 mm in precordial leads) may be a marker for all of the following disorders EXCEPT:

- A. Amyloidosis
- B. Cardiac transplant rejection
- C. Coronary artery disease
- D. Pericardial effusion
- E. Hyperthyroidism

7. 68 years old patient, brought by an ambulance in grave condition with complaints of dizziness, periodic loss of consciousness, seizures. Pulse - 36/min., rhythmical. BP - 170/85 mm Hg. 1st tone on the apex is decreased, accent of IInd tone above aorta. Vesicular breathing, in the lower lung segments fine bubbling moist rales are heard. ECG: atrial and ventricular complexes occur independently, frequency of ventricular complexes - 33/min. Which tactics must be applied urgently in this case?

- A. Strophanthin intravenously
- B. Electrocardiostimulation
- C. Obsidan intravenously
- D. Electrical defibrillation
- E. Potassium chloride intravenously

8. A woman aged 53, complains of pain and discomfort in the heart area. History: considers herself ill since childhood, tells that her father suffered from some "heart arrhythmia". Objective: general condition is grave, heart rate - 215/min., BP - 80/60 mm Hg. ECG: heart rate - 220/min., expansion and deformation of the QRS complex with the presence of atrioventricular dissociation, P wave is positive. Subsequently, heart rate decreased to 45/min., a complete disconnection of P wave and the QRST. Which of the following will be most effective?

- A. Cholineblocker (atropine)
- B. Beta-blockers
- C. Implantation of pacemaker
- D. Calcium antagonists (verapamil)

The patient, 67 years old, suffer from coronary artery disease for a long time. Attacks of angina efforts over the past week, there was a feeling of "sinking heart". Take the recommended district physician bisoprolol, trimetazidine, aspirin, panangin. The ECG interval P-Q 0,16 sec, periodically absent QRST complex while preserving the P wave, repolarization disorder in right precordial leads.

Questions:

- 1) What are the complications occurred in a patient?
- 2) Formulate a preliminary clinical diagnosis.
- 3) Make a plan of the patient examination and treatment.

Summary:

Recommended reading list

Basic literature:

- Harrison's Principles of Internal Medicine Self-Assessment and Board Review, 20th Edition 20th Edition.- (August 13, 2021). - 736 pages
- Pocket Medicine: The Massachusetts General Hospital Handbook of Internal Medicine / 007 edition (12 Sept. 2019). - 272 pages
- Davidson's Principles and Practice of Medicine: Enhanced Digital Version Included / Elsevier; 23rd edition (25 April 2018). - 1440 pages

Additional literature:

- Macleod's Clinical Examination /Elsevier; 14th edition (11 Jun. 2018). - 400 pages
- Current Medical Diagnosis and Treatment /McGraw-Hill Education; Updated edition (14 Sept. 2021). - 1840 pages
- Lippincott Connect Standalone Courseware for Bates' Guide to Physical Examination and History Taking 1.0 /LWW; 13th ed. edition (23 Mar. 2023).
- Step-Up to Medicine / Wolters Kluwer Health; 5th edition (8 May 2019). - 582 pages
- Goldman-Cecil Medicine, 2-Volume Set (Cecil Textbook of Medicine) / Elsevier; 26th edition (20 Dec. 2019). - 2944 pages
- The Washington Manual of Medical Therapeutics / Wolters Kluwer Health; 36th edition (6 Jun. 2019). - 1074 pages
- Harrison's Manual of Medicine / McGraw-Hill Education; 20th edition (5 Nov. 2019). - 1245 pages

Electronic information resources

- World Health Organization. URL: www.who.int/ru/index.html.
- European Regional Office of the World Health Organization. URL: www.euro.who.int.
- <https://www.aasld.org/>
- https://academic.oup.com/ndt/pages/General_Instruction
- <https://cprguidelines.eu/>
- <https://www.escardio.org/Guidelines/Clinical-Practice-Guidelines>
- <http://www.oxfordmedicaleducation.com/>
- <http://ard.bmj.com>
- <https://www.escardio.org/Guidelines/Clinical-Practice-Guidelines>

Practical class

Topic 4. Management of a patient with cardiac pain.

The main goals: to acquire communication skills and skills of clinical examination of a patient with cardiac pain; to be able to establish a preliminary diagnosis, carry out a differential diagnosis and determine the clinical diagnosis of the disease in a patient with cardialgia; master the principles of treatment, recommendations for lifestyle changes in the management of patients with cardialgia; learn to diagnose emergency conditions in patients with cardialgia; master the tactics of providing emergency medical care to patients with cardiac pain; to be able to perform therapeutic manipulations in patients with cardiac pain.

to acquire communication skills and skills of clinical examination of a patient with stable angina pectoris; be able to establish a preliminary diagnosis, carry out a differential diagnosis and determine

the clinical diagnosis of the disease in a patient with stable angina pectoris; master the principles of treatment, recommendations for lifestyle changes in the management of patients with stable angina pectoris; learn how to diagnose emergency conditions in patients with stable angina pectoris and master the tactics of providing emergency medical care; to be able to perform therapeutic manipulations in patients with stable angina pectoris.

Key words: the technique of carrying out a differential diagnosis according to the leading syndrome of cardialgia; principles and methods of differential therapy of patients with cardialgia syndrome; differences between psychogenic and somatic pain; CNS-induced pain; main laboratory and instrumental research methods.

modern classification of CHD; functional classes of stable angina pectoris according to the Canadian classification and their compliance with stress tests (VEM, treadmill); differences between stable angina and other forms of CAD; examination plan for a patient with stable angina pectoris; ECG signs of myocardial ischemia during exercise; the possibilities of holter monitoring in the diagnosis of myocardial ischemia, indications for the appointment of holter monitoring; clinical and instrumental signs of coronary X syndrome; features of the phenomenon of painless myocardial ischemia (in whom it occurs, what are its manifestations, how to diagnose it); indications for coronary angiography; assessment of lipidogram, troponin test results; management tactics of a patient with stable angina depending on FC; additional research methods: PET, myocardial scintigraphy, dipyridamole test.

Equipment: multimedia materials - a set of thematic slides from the department's multimedia library; screenshots of laboratory test results: ACS, markers of myocardial necrosis, amylase, GHTP, LF, lipidogram, indicators of inflammation; a set of situational problems on the topic of the lesson; screenshots of the results of instrumental research: ECG, X-ray, fibroscopy, Echo-CS, abd-ultrasound, stress tests; mannequin for performing the following practical skills: palpation of the chest, palpation of trigger points (intercostal, paravertebral); percussion and auscultation of lungs and heart.

Plan:

1. Organizational measures (greetings, verification of those present, announcement of the topic, purpose of the lesson, motivation of higher education seekers to study the topic)
2. Control of the reference level of knowledge (checking homework, written work, written testing, including writing KROC-2 tests, frontal survey)
3. Formation of professional abilities, skills (mastery of skills, curation, determination of the treatment scheme, laboratory research, etc.):discussion of the features of diagnosis and treatment of patients with cardialgia, the most common clinical manifestations, criteria for establishing a diagnosis
4. Summing up (summarizing the topic, evaluating applicants, discussing the next lesson topic and homework)

Quiz:

1. List what heart, respiratory, digestive, nervous and musculoskeletal system diseases can cause false angina.
2. Fill the table with distinctive features of cardialgia in some diseases.

Disease	Features of cardialgia (conditions of appearance, the character of localization, irradiation, duration, factors of relief)	Other clinical syndromes
Angina		
Myocardial infarction		
Myocarditis		
Pericarditis		
Neuro-circulatory dystonia		
Mediastinal pleuritis		
Esophagitis		
Cardiac ulcer		
Cholecystitis		

Intercostal neuralgia		
Herpes Zoster		

3. What instrumental methods can confirm the diagnosis of angina, myocardial infarction, dissecting aortic aneurysm, pericarditis, pulmonary artery embolism, pneumothorax, esophagitis, cholecystitis, thoracic radiculitis?
4. What are the laboratory methods which confirm the diagnosis of myocardial infarction, myocarditis, pulmonary embolism, cholecystitis, herpes zoster?
5. Terms of relief of acute angina attacks and prophylactic anti-anginal therapy.
6. Terms of coping with pain syndrome in acute myocardial infarction.
7. The treatment of patients with neuro-circulatory dystonia.
8. Features of cardialgia treatment due to the digestive system diseases.
9. Features of cardialgia treatment due to the musculo-skeletal system diseases.
10. Cardialgia treatment due to inflammatory heart diseases.

MCQ's:

1. 24 years old female complains of acute pain in the heart area, dyspnoea on slight exertion, palpitations, increased body temperature up to 37,2° C. Symptoms appeared within 2 weeks after an attack of influenza. Objective: heart borders are moderately shifted to right and left, the 1st sound is weakened, short systolic murmur over the apex. Above the lungs - vesicular breathing. What is the preliminary diagnosis?
 - A. Rheumatism, mitral insufficiency
 - B. Acute myocarditis
 - C. Cardiopsychoneurosis
 - D. Acute pericarditis
 - E. Pneumonia
2. After the paroxysm of atrial fibrillation, a patient suddenly develops chest pain, dyspnoea. Objective data: skin is covered with sweat, neck veins are swollen, eyes wide open. Pulse is weak, 140/min, BP - 80/40 mm Hg. The ECG shows deviation of electrical cardiac axis to the right, positive SI-QIII-TIII sign. What complication did patient develop?
 - A. Rupture of interventricular septum
 - B. Myocardial infarction
 - C. Pulmonary embolism
 - D. Cardiac tamponade
 - E. Cardiac asthma
3. 53 years old female, body weight 100 kg, complains of a headache, pressing heart pain at rest. Reports no definite connection of pain frequency and physical exertion. Sick for about 7 years. Menstruation stopped 4 years ago. On objective examination: BP - 186/100 mm Hg., HR=84/min., signs of LV hypertrophy. What is the most probable cause of cardialgia?
 - A. Thoracic radiculopathy
 - B. Climacteric cardiomyopathy
 - C. Pituitary - Cushing
 - D. Hypothalamic syndrome
 - E. Coronary artery disease, stable angina
4. A woman 30 years old, with influenza, has dyspnea on moderate exertion, palpitations, acute pain in the heart. Pulse - 96/min., BP - 100/60 mm Hg. The 1st sound is weakened and soft systolic murmur are heard above the apex. Development of what complication can this clinical picture indicate?
 - A. Acute viral myocarditis
 - B. Acute viral pericarditis
 - C. Idiopathic myocarditis
 - D. Dilated cardiomyopathy
 - E. Neuro-circulatory dystonia
5. 54 years-old male, farm worker, notes the appearance of burning retrosternal pain, which radiates to the left hand and appears during physical work and fast walking. The pain disappears after physical activity stops. Patient regularly drinks alcohol. Objective data: face and neck slight hyperemic,

congestion of the small vessels of the nose and cheeks. Pain on palpation in the left paravertebral points at ThIV – ThVI. Heart borders expanded 2cm to the left, sounds are weakened, heart rate - 86/min., BP - 180/105 mm Hg. Liver + 3 cm. No edema. ECG - left ventricular hypertrophy. According to ultrasound, the gall bladder has concretion with a diameter up to 4 mm. The most reliable cause of heart pain is:

- A. Hypertension
- B. IHD: stable angina
- C. Hypertrophic cardiomyopathy
- D. Cholelithiasis
- E. Osteochondrosis of spine

6. 43-year-old male old, complains of compressing pain of the precardiac area that happens 2-3 times a week, lasts up to 20 minutes and is associated with physical activity. BP - 130/80 mm Hg. ECG: in leads V1-V3 shows decreased amplitude of "T" waves. What method of investigation should be conducted as the next step to clarify the diagnosis?

- A. Coronary angiography
- B. Stress-echocardiography
- C. Potassium-obsidane test
- D. Atropine test
- E. Ergometer testing

7. Patient of therapy department, 34 years old, complains of severe stabbing pain in the left half of the chest when coughing, at inspiration. Objective: body temperature - 37,5°C, left lung auscultation – “mechanical” noise both on inspiration and expiration, which does not disappear after cough. What kind of diagnosis we are to think about?

- A. Left-sided lobar pneumonia
- B. Acute fibrinous pleuritis
- C. Acute endopericarditis
- D. Intercostal myalgia
- E. Left-sided pneumothorax

8. 59 years old male, complains of “pain in the heart”, cough, increased body temperature to 38°C. Had acute non-ST elevation myocardial infarction 3 weeks ago. Pulse - 86/min., rhythmic, BP - 110/70 mm Hg. Heart - the noise of pericardium friction (friction rub). Lungs: left subscapular - moist rales. Chest X-ray – without pathological findings. Complete blood count: L – $10,4 \times 10^9 / L$, ESR - 35 mm/h. ECG: normal MI dynamics. Administration of what drug will be most correct?

- A. Nitroglycerin
- B. Antibiotics
- C. Fraxiparine
- D. Glucocorticoids
- E. Streptokinase

9. A woman aged 74, complains of sharp retrosternal pain radiating to the back, weakness, palpitation, which occurred suddenly after physical exertion. Has a history of arterial hypertension over 15 years. Objective: HR - 110/min., low-filling pulse, especially on the right side. BP: right - 80/60 mm Hg., left - 170/90 mm Hg. Quiet heart sounds, accent of the IInd sound above aorta. Echo: the diameter of the aorta - 5,2 cm, left ventricle - 5,6 cm. What if the preliminary diagnosis?

- A. Thoracic radiculitis
- B. Acute myocardial infarction
- C. Aortic dissection
- D. Supraventricular tachycardia
- E. Constrictive pericarditis

10. The patient aged 48, has a history of arterial hypertension for 5 years. Took prescribed medications irregularly. Yesterday while performing heavy physical work, suddenly felt an intensive pain in the heart area radiating to the left shoulder, sweating, feeling “fear of death”. The pain disappeared after 10 minutes of rest. Objective examination: Pulse - 72/min., rhythmic, BP - 165/100 mm Hg., organs of the chest and abdomen without pathological findings. ECG: sinus rhythm 68/min., normal electrical axis. What is the most probable diagnosis which predetermined the clinical picture?

- A. Peptic ulcer of the duodenum
- B. New-onset angina (Unstable angina)
- C. Variant angina
- D. Diaphragmatic hernia strangulation
- E. Pinched intercostal nerve

Clinical tasks:

Task № 1

The patient 25 years old, complains of fatigue, weakness, irritability, "sensitive" sleeping, a local (palm) sweating, sometimes unstable subfebrile temperature. All this is accompanied by aching pain in the heart, a feeling of emptiness in the chest, sometimes difficulty to breath, which compels the patient to deepen breathing. BP 125/70 mm HR -82/min. Vesicular breathing. On the ECG-sinus arrhythmia, decreased amplitude of the T wave.

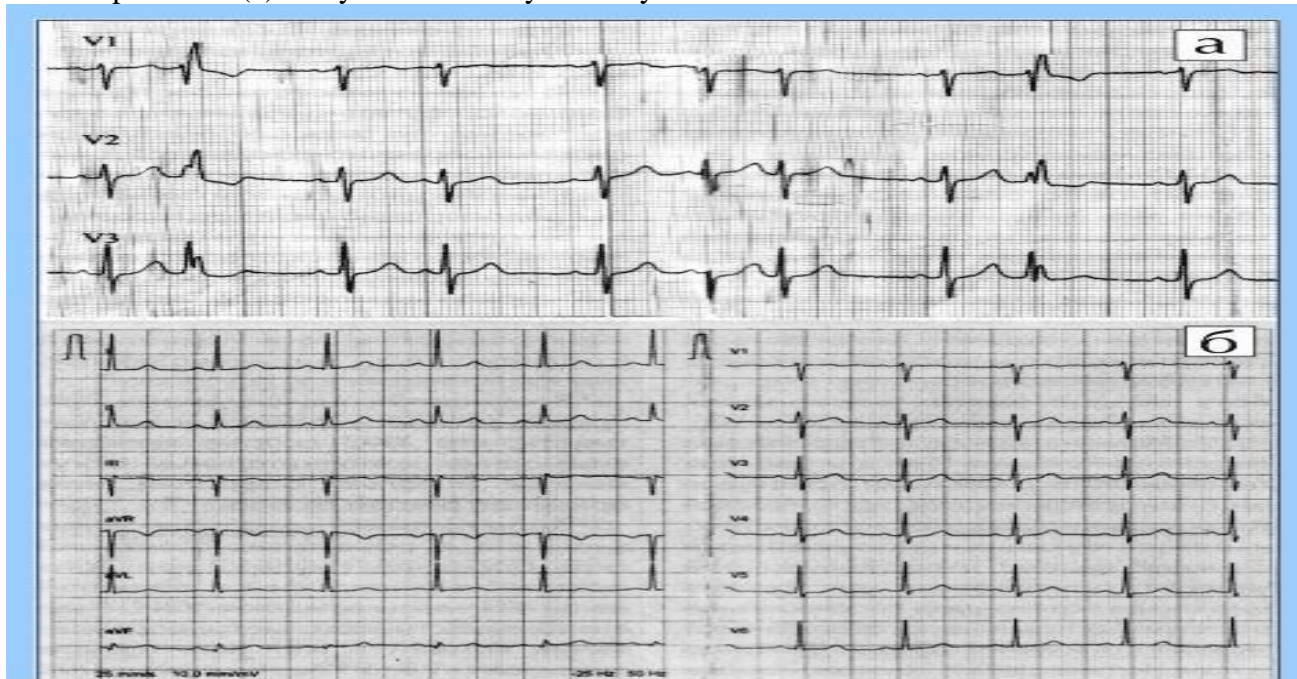
Questions:

- 1) To formulate a preliminary diagnosis.
- 2) Make a plan of the patient examination.
- 3) Prescribe treatment.

Objective № 2

The patient, 62 years old, complained of pain attacks in the heart, arrhythmia, dyspnea. The attack lasted for 8-10 hours. Pulse-72/min., arrhythmic, BP - 145/100 mm Hg. Vesicular breathing. Liver 2 cm below the costal arch, gall bladder is sensitive on palpation. Ultrasound revealed calculus in diameter of 1.8 cm in ductus cysticus. Laparoscopic cholecystectomy was performed.

ECG of patient in (a) 4 days after cholecystectomy



Questions:

- 1) Formulate a clinical diagnosis.
- 2) Explain the dynamics of ECG changes.
- 3) Explain the pathogenesis of cardiodynia patient.
- 4) Make a plan · subsequent patient management.

Task № 3

Patient 46 years old complains about stabbing pain in the left half of the chest within the last 3 days. Pain is exacerbated by deep breathing. He is a smoker. He has persistent cough which improved a little during the week. HR-9/min., BP - 115/9mm Hg. Vesicular breathing. The liver is +0.5 cm. In ECG is a

sinus tachycardia, P pulmonale, decreased amplitude of the T wave. The organs of the chest radiography S5 infiltrative opacity in the left lung.

Questions:

- 1) Formulate a clinical diagnosis.
- 2) Make a plan of patients' examination.
- 3) Assign the treatment.

Summary:

Recommended reading list

Basic literature:

- Harrison's Principles of Internal Medicine Self-Assessment and Board Review, 20th Edition 20th Edition.- (August 13, 2021). - 736 pages
- Pocket Medicine: The Massachusetts General Hospital Handbook of Internal Medicine / 007 edition (12 Sept. 2019). - 272 pages
- Davidson's Principles and Practice of Medicine: Enhanced Digital Version Included / Elsevier; 23rd edition (25 April 2018). - 1440 pages

Additional literature:

- Macleod's Clinical Examination /Elsevier; 14th edition (11 Jun. 2018). - 400 pages
- Current Medical Diagnosis and Treatment /McGraw-Hill Education; Updated edition (14 Sept. 2021). - 1840 pages
- Lippincott Connect Standalone Courseware for Bates' Guide to Physical Examination and History Taking 1.0 /LWW; 13th ed. edition (23 Mar. 2023).
- Step-Up to Medicine / Wolters Kluwer Health; 5th edition (8 May 2019). - 582 pages
- Goldman-Cecil Medicine, 2-Volume Set (Cecil Textbook of Medicine) / Elsevier; 26th edition (20 Dec. 2019). - 2944 pages
- The Washington Manual of Medical Therapeutics / Wolters Kluwer Health; 36th edition (6 Jun. 2019). - 1074 pages
- Harrison's Manual of Medicine / McGraw-Hill Education; 20th edition (5 Nov. 2019). - 1245 pages

Electronic information resources

- World Health Organization. URL: www.who.int/ru/index.html.
- European Regional Office of the World Health Organization. URL: www.euro.who.int.
- <https://www.aasld.org/>
- https://academic.oup.com/ndt/pages/General_Instruction
- <https://cprguidelines.eu/>
- <https://www.escardio.org/Guidelines/Clinical-Practice-Guidelines>
- <http://www.oxfordmedicaleducation.com/>
- <http://ard.bmj.com>
- <https://www.escardio.org/Guidelines/Clinical-Practice-Guidelines>

Practical class

Topic 5. Management of a patient with chronic coronary syndrome.

The main goals: to indicate the relevance of the topic, know the etiopathogenetic classification of CCS, know the risk factors for the development of CCS, know the etiopathogenesis, know the diagnostic criteria for CCS and treatment

Key words: chronic coronary syndrome, stable angina, unstable angina, variant angina, ECG, coronarography, stenting, CABG.

Equipment: multimedia materials - a set of thematic slides from the department's multimedia library; screenshots of laboratory test results: ACS, markers of myocardial necrosis, amylase, GHTP, LF, lipidogram, indicators of inflammation; a set of situational problems on the topic of the lesson; screenshots of the results of instrumental research: ECG, X-ray, fibroscopy, Echo-CS, abd-ultrasound, stress tests; mannequin for performing the following practical skills: palpation of the chest, palpation of trigger points (intercostal, paravertebral); percussion and auscultation of lungs and heart

Plan:

1. Organizational measures (greetings, verification of those present, announcement of the topic, purpose of the lesson, motivation of higher education seekers to study the topic)
2. Control of the reference level of knowledge (checking homework, written work, written testing, including writing KROK-2 tests, frontal survey)
3. Formation of professional abilities and skills (mastery of skills, curation, determination of treatment regimen, laboratory research, etc.): discussion of features of diagnosis and treatment of arterial hypertension, the most common clinical manifestations, criteria for establishing a diagnosis
4. Summing up (summarizing the topic, evaluating applicants, discussing the next lesson topic and homework)

Quiz:

1. List the diagnostic criteria for typical types of angina and atypical angina.
2. How is the functional class of stable angina?
3. What laboratory methods of examination are necessary in patients with stable angina?
4. What are the diagnostic possibilities have additional instrumental methods of examination (electrocardiogram during physical stress, circadian Holter monitoring of ECG, stress echocardiogram, coronary angiography). Indications for their purpose.
5. General recommendations in IHD (diet, physical activity, smoking, psychological state).
6. Help in acute attack of angina.
7. Standards for assessments, which improves the prognosis of patients with IHD (aspirin, ACE inhibitors, statins, β -blockers).
8. Standards of antianginal therapy.
9. Tactics of patients' treatment, depending on the functional class of angina.
10. Features of patients with vasospastic angina treatment.
11. What endovascular and surgical treatment methods are used in such patients, the tactics of patients' management in the postoperative period.

MCQ's:

1. 64 years-old male, with a diagnosis of IHD: stable angina FC II, Heart failure of IIA stage. Takes complex treatment (nitrates, ACE inhibitors, statins, aspirin), noted decrease in frequency and intensity of angina attacks, but headache and dizziness appeared. These phenomena can be triggered by following medication:
 - A. Ramipril
 - B. Isosorbide mononitrate
 - C. Atorvastatin
 - D. Metoprolol succinate
 - E. Aspirin
2. Patient, 60 years old, complains of pressingretrosternalpain while walking 200 m horizontally. BP - 140/70 mm Hg. Pulse - 80/min. Ergometry test: reduced tolerance to physical stress, 80 W. The most possible diagnosis is?
 - A. Progressive angina
 - B. Stable angina FC III
 - C. Vasospastic angina
 - D. Stable angina FC II
 - E. Stable angina IV FC
3. A 52 year old patient with history of functional Class II angina complains of having intense and prolonged retrosternal pains, decreased exercise tolerance for 5 days. Angina is less responsive to nitroglycerine. What is the most probable diagnosis?
 - A. Cardialgia due to spine problem
 - B. IHD: Functional Class II angina
 - C. IHD: Unstable angina
 - D. Myocardial dystrophy
 - E. Myocarditis
4. A 57-year-old scientist experiences constricting retrosternal pain several times a day while walking

for 100-150 m. The pain lasts for up to 10 minutes and can be relieved by nitroglycerine. Objectively: the patient is overweight, heart borders exhibit no abnormalities, heart sounds are rhythmic, Ps - 78 bpm, AP - 130/80 mm Hg. ECG contains low amplitude of T wave in V4-5. What disease might be suspected?

- A. Instable stenocardia
- B. Stable FC III stenocardia
- C. Stable FC I stenocardia
- D. Stable FC II stenocardia
- E. Stable FC IV stenocardia

5. A 44-year-old patient applied to hospital with complaints of pain behind the sternum with irradiation to the left scapula. The pain appears during significant physical work, lasts for 5-10 minutes and is disappears at rest. The patient is sick for 3 weeks. What is the preliminary diagnosis?

- A. IHD: Variant angina pectoris (Prinzmetal's)
- B. IHD: First established angina pectoris
- C. IHD: Stable angina pectoris I FC
- D. IHD: Stable angina pectoris IV FC
- E. IHD: Progressive angina pectoris

6. 45 year-old male, complains of intense pain behind the sternum, which irradiates to the mandible, appears at rest, at night, lasts for 10-15 minutes. Holter ECG-monitoring revealed ST segment elevation in leads V2-V4 at the time of such pain episode. What is the diagnosis?

- A. Vasospastic angina
- B. Myocardial infarction
- C. Stable angina FC II
- D. Progressive angina
- E. Stable angina IV FC

7. In order to exclude ischemic heart disease a 51 year-old male underwent veloergometry test. During a second load stage ECG showed horizontal ST segment depression in precordial leads. These changes should be evaluated as a sign of:

- A. Deconditioning of the patient
- B. Normal findings
- C. Coronary insufficiency
- D. Degenerative changes
- E. Electrolyte disturbances

8. A 44 year-old male patient has heart attacks regularly occurring in the early morning hours. According to Holter monitoring at this time arched ST segment elevation appears in the precordial leads, lasts for 15 minutes. Objective: heart sounds weakened, heart rate - 64/min., BP - 140/80 mm Hg. The most reasonable prescription:

- A. Ramipril
- B. Metoprolol
- C. Atorvastatin
- D. Amlodipine
- E. Isosorbide dinitrate

9. A 49 years-old male is diagnosed stable angina class II. Intake of nitroglycerin and long acting nitrates causes severe headache. Which of the above products can be a substitute for nitroglycerin in treatment of angina attack?

- A. Amiodarone
- B. Molsidomine
- C. Nifedipine
- D. Bisoprolol
- E. Verapamil

10. The patient, aged 52, has stable angina of II FC that was diagnosed 8 months ago. Pulse - 108/min., arrhythmic, moderately intense, BP - 170/100 mm Hg. The ECG - ventricular extrasystoles 1-2 per minute. Which drug is indicated for long-term therapy in this patient?

- A. Panangin

- B. Nitrosorbide
- C. Mildronate
- D. Thiotriazoline
- E. Metoprolol

Clinical tasks:

Task № 1

Patient D., aged 65, complains of a contractive pain in the chest that occurs when walking in the 200 meters, relieved by nitroglycerin. 3 years ago, suffered an acute myocardial infarction. Uses constant drugs: Atenolol - 100 mg 2 times a day, aspirin - 100 mg 1 time a day. Last days notes weakness, dyspnea. OBJECTIVE: Pulse - 52/min., BP - 120/80 mm Hg. The ECG - signs of post-infarction cardiosclerosis.

Questions:

- 1) To formulate a preliminary diagnosis of the patient.
2. Make a plan of examination.
- 3) Adjust the appointment of a patient.

Task № 2

Patient 40 years old, complained of intermittent intense pain in the heart, the pains occur at night during sleep. Nitroglycerine is ineffective. On examination there revealed signs of vagotonia - bradycardia, sweating. The ECG: short-term rise ST V1-V4. Lipid profile without pathology. Tolerance to physical activity 100 watts.

Questions:

- 1) Formulate a preliminary diagnosis.
- 2) Make a complete plan of the patients' examination.
- 3) Make a plan of treatment.

Task № 3

Patient 68 years old, over 6 years suffering from diabetes, IHD with angina over the past year. Integrated antianginal therapy was ineffective. Coronary angiography revealed occlusion of the anterior descending branch of the left coronary artery. Was performed percutaneous transluminal coronary angioplasty with stent. The patient's condition is satisfactory. Pain in my heart only when walking fast. Vesicular breath. Rhythmic activity of the heart, heart rate - 90/min., BP 145/95 mm Hg Total cholesterol - 6.4 mmol / liter. Fasting glucose - 6.2 mmol / liter.

Questions:

- 1) Formulate a clinical diagnosis of the patient.
- 2) Make a plan of the patient management after coronary revascularization.
- 3) Make a plan of treatment.

Summary:

Recommended reading list

Basic literature:

- Harrison's Principles of Internal Medicine Self-Assessment and Board Review, 20th Edition 20th Edition.- (August 13, 2021). - 736 pages
- Pocket Medicine: The Massachusetts General Hospital Handbook of Internal Medicine / 007 edition (12 Sept. 2019). - 272 pages
- Davidson's Principles and Practice of Medicine: Enhanced Digital Version Included / Elsevier; 23rd edition (25 April 2018). - 1440 pages

Additional literature:

- Macleod's Clinical Examination /Elsevier; 14th edition (11 Jun. 2018). - 400 pages
- Current Medical Diagnosis and Treatment /McGraw-Hill Education; Updated edition (14 Sept. 2021). - 1840 pages
- Lippincott Connect Standalone Courseware for Bates' Guide to Physical Examination and History Taking 1.0 /LWW; 13th ed. edition (23 Mar. 2023).
- Step-Up to Medicine / Wolters Kluwer Health; 5th edition (8 May 2019). - 582 pages
- Goldman-Cecil Medicine, 2-Volume Set (Cecil Textbook of Medicine) / Elsevier; 26th edition (20 Dec. 2019). - 2944 pages
- The Washington Manual of Medical Therapeutics / Wolters Kluwer Health; 36th edition (6 Jun. 2019). - 1074 pages
- Harrison's Manual of Medicine / McGraw-Hill Education; 20th edition (5 Nov. 2019). - 1245 pages

Electronic information resources

- World Health Organization. URL: www.who.int/ru/index.html.
- European Regional Office of the World Health Organization. URL: www.euro.who.int.
- <https://www.aasld.org/>
- https://academic.oup.com/ndt/pages/General_Instruction
- <https://cprguidelines.eu/>
- <https://www.escardio.org/Guidelines/Clinical-Practice-Guidelines>
- <http://www.oxfordmedicaleducation.com/>
- <http://ard.bmj.com>
- <https://www.escardio.org/Guidelines/Clinical-Practice-Guidelines>

Practical class

Topic 6. Management of a patient with cardiomegaly.

The main goals: to acquire communication skills and clinical examination skills of a patient with cardiomegaly; be able to establish a preliminary diagnosis, carry out a differential diagnosis and determine the clinical diagnosis of the disease in a patient with cardiomegaly; master the principles of treatment, recommendations for lifestyle changes in the management of patients with cardiomegaly; to be able to perform therapeutic manipulations in patients with stable angina pectoris.

Key words: the basis of complaints, anamnesis, percussive and auscultatory data in patients with cardiomegaly; a patient examination plan to establish the etiology of cardiomegaly; ECG analysis and changes characteristic of myocarditis, cardiomyopathy or pericarditis; differential diagnosis and establishing the causes of heart enlargement; specific changes during ultrasound examination; treatment plan for a patient with the appropriate nosology, drugs used in the treatment of cardiomegaly; basic measures of rehabilitation and prevention.

Equipment: multimedia materials - a set of thematic slides from the department's multimedia library; screenshots of laboratory test results: ACS, markers of myocardial necrosis, amylase, GHTP, LF, lipidogram, indicators of inflammation; a set of situational problems on the topic of the lesson; screenshots of instrumental research results: ECG, Echocardiography, Rg-grams; mannequin for performing the following practical skills: palpation of the chest, palpation of trigger points (intercostal, paravertebral); percussion and auscultation of the heart.

Plan:

- Organizational measures (greetings, verification of those present, announcement of the topic, purpose of the lesson, motivation of higher education seekers to study the topic)
- Control of the reference level of knowledge (checking homework, written work, written testing, including writing KROK-2 tests, frontal survey)
- Formation of professional abilities and skills (mastery of skills, curation, determination of treatment regimen, laboratory research, etc.): discussion of features of diagnosis and treatment of arterial hypertension, the most common clinical manifestations, criteria for establishing a diagnosis

- Summing up (summarizing the topic, evaluating applicants, discussing the next lesson topic and homework)

Control questions:

1. Give determination of cardiomegaly. What variants of total or local cardiomegaly are possible for patients?
2. What physical methods of inspection can we use to find cardiomegaly?
3. Fill a table «ECG signs of heart hypertrophy ».

	ECG signs
Right atrium hypertrophy	
Left atrium hypertrophy	
Right ventricle hypertrophy	
Left ventricle hypertrophy	

4. Fill a table « X-ray signs of cardiomegaly».

	X-ray changes of right and left arcus of heart contour
Mitral heart configuration	
Aortal heart configuration	
Triangular heart configuration	

5. Diagnostic possibilities of echocardiograph and coronaro-ventriculography for verification of cardiomegaly type?
6. Fill a table « features of cardiomegaly».

	Cardiomegaly features	Other clinical syndromes	Echo features
Mitral stenosis			
Mitral deficiency			
Aortic stenosis			
Aortic deficiency			
Diffuse myocarditis			
Exsudative pleurisy			
Dilatativecardiomyopathy			
Hypertrophiccardiomyopathy			
Restrictive cardiomyopathy			

7. Principles of patients with myocarditis treatment.
8. Principles of patients with exudative pericarditis treatment.
9. Treatment of patients with different variants cardiomyopathies.
10. Primary and second prophylaxis of cardiomegaly development.

MCQ's:

1. A 38 year-old patient, complaints about the expressed shortness of breath, pain in heart area. Connects a disease to being ill with flu 2 weeks ago. Objectively: sits, leaning forward. Swelling and cyanosis of the face, marked swelling of neck veins. The borders of heart are extended in both sides, sounds are weakened, HR - 112/min., BP -100/60 mm Hg, liver +4 cm. General blood: ESR - 42 mm/hour. ECG: low voltage of waves in all leads. X-ray: trapezoidal shade of heart. What is the most possible diagnosis?
 - A. Rheumatic heart disease
 - B. Virus myocarditis
 - C. Ischemic heart disease
 - D. Dilation cardiomyopathy
 - E. Exudative pericarditis
2. Man 37 years, previously being healthy, complains of palpitation, progressing shortness of breath,

"interruptions" in heart rhythm, dizziness, rapid fatigue. At an inspection he was found to have cardiomegaly, weakening of heart sounds, systolic murmur above the apex, signs of heart failure of IIA stage. ECG: atrial fibrillation, complete left bundle branch block, negative deflection of T in V1-V6. On Echo-CG: diffuse dilation of heart chambers, LV lateral wall thickness = 6mm, decreased contractility of myocardium. What is your preliminary diagnosis?

- A. Myocarditis
- B. Hypertensive cardiomyopathy
- C. Exudative pericarditis
- D. Dilative cardiomyopathy
- E. Constrictive cardiomyopathy

3. 45 y.o. woman complains of intensive heart pain, dyspnea, irregularities in the heart activity, progressive fatigue for the last 3 weeks. She had acute respiratory infection a month ago. On examination: BP - 120/80 mm Hg, heart rate 98 bpm, heart borders +1,5 cm left side, sounds are muffled, soft systolic murmur at apex and Botkin's areak; sporadic extrasystoles. Liver isn't palpable, no edema. Blood test: WBC - $6,7 \times 10^9/L$, ESR - 21 mm/hour. What is the most probable diagnosis?

- A. Hypertrophic cardiomyopathy
- B. Climacteric myocardiodystrophia
- C. Ischemic heart disease, angina pectoris
- D. Rheumatism, mitral insufficiency
- E. Acute myocarditis

4. After the prolonged period of subfebrile temperature the patient noticed strengthening of dyspnea, pain in right subcostal area, feet edema. Neck veins are swollen. Pulse - 120/min., sometimes disappears on inhalation. Heart sounds are prominently weakened. On ECG - decrease of voltage of QRS complex, elevation of ST segment in V1-V5. Shade of heart is extended, rounded. Specify the most possible diagnosis:

- A. Myocardial infarction with the Q wave
- B. Exudative pericarditis
- C. Post infarct cardio sclerosis
- D. Dismetabolic cardiomyopathy
- E. Severe rheumatic fever

5. Male, 65 years, complains of permanent retrosternal pain which is not relieved with nitroglycerine; cough with blood in sputum. Condition deteriorates for three days. History: 2 myocardial infarctions – 2 years and 3 weeks ago. Objectively: body temperature - $37,8^{\circ}C$. Pulse - 90/min., rhythmic. The right and left heart borders are shifted 1 cm outside, sounds are weakened. On the left at level of IV-V ribs - shortening of percussion sound, noise of pleura friction. On ECG: decrease in QRS complex voltage, concordant elevation of ST segment in chest leads. What is most possible reason for these symptoms?

- A. Cardiac asthma
- B. Severe pneumonia
- C. Recurrent myocardial infarction
- D. Dressler's syndrome
- E. Thromboembolism of the pulmonary artery

6. Woman 37 years old, complains of dyspnea, squeezing pain behind a breastbone. Had been ill with flu a week ago. Objectively: acrocyanosis, HR - 98/min., BP is 90/75 mm Hg, RR - 26/min. The heart borders are extended to the left and to the right for 3 cm. Heart sounds are weakened, above an apex there is protodiastolic gallop rhythm, systolic murmur. Hb - 100 g/L, ESR - 25 mm/min. What the preliminary diagnosis can be?

- A. IHD, angina
- B. Dilated cardiomyopathy
- C. Exudative pericarditis
- D. Restrictive cardiomyopathy
- E. Infectious-allergic myocarditis

7. An 18 years old applicant complains of dyspnea at moderate physical loading. His condition worsened half a year ago. Objectively: pulse - 88/min., high. BP is 180/20 mm of Hg. Skin is pale. The borders of heart are extended to the left, upwards. Systolic-diastolic murmur in II intercostal space to

the left of sternum, II sound above a pulmonary artery is increased. On ECG: signs of both ventricles hypertrophy. Chest X-ray: pulsation and bulging of pulmonary artery shadow and of left ventricle. What must be the tactic of the doctor?

- A. Restriction of the physical activity
- B. Dispensary supervision
- C. Therapeutic treatment appointment
- D. Continuation of investigation
- E. Consultation of a cardiac surgeon

8. A 36 years old patient, who abuses alcohol regularly, complains of dyspnea, feet edema. Connects the disease with overcooling. Objectively: the general condition is grave, acrocyanosis. Pulse - 112/min., rhythmic. BP is 90/65 mm Hg. An apex beat is not palpable. Heart sounds are weakened, above the apex short systolic murmur is heard. Breathing is vesicular. Stomach is uncomfortable on palpation, the lower liver edge comes forward for 6 cm from under a costal arch, is dense. General blood count: Hb - 125 g/L, Leu - $10,9 \times 10^9/L$, ESR - 16 mm/min. Urinalysis - without peculiarities. ECG: voltage is diminished, negative indents of T wave in V1-V6. What is the most possible reason of circulation insufficiency?

- A. IHD: myocardial infarction without the Q wave.
- B. Pericarditis
- C. Infection-allergic myocarditis
- D. Alcoholic cardiomyopathy
- E. Dilated cardiomyopathy

9. Patient of 25 years old, complains of pain in the heart of aching character, palpitation, feeling of interruptions in heart work, dyspnea. In childhood he suffered from rheumatism. Objectively: joints are not changed. Cyanosis of lips, pulse - 96/min., arrhythmic, frequent extrasystoles. BP is 105/70 mm Hg. The heart borders are extended. Above an apex the II sound is weakened, protracted systolic murmur. Above pulmonary artery - II sound is increased. Above lungs - breathing is weakened. What changes of Echo-cardiogram are most possible in this patient?

- A. Thickening of right ventricle walls
- B. Right ventricle cavity dilation
- C. Dilation and hyperkinesis of the left ventricle walls
- D. Expansion of the left ventricle cavity
- E. Dilatation of the left atria and left ventricle

10. 4 weeks after myocardial infarction a 56-year-old patient developed acute heart pain, pronounced dyspnea. Objectively: the patient's condition is extremely grave, there is marked cyanosis of the face, swelling and throbbing of the neck veins, peripheral pulse is absent, carotid artery pulse is rhythmic, 130/min., BP is 60/20 mm Hg. Auscultation of the heart reveals extremely muffled sounds, percussion reveals heart border extension in both directions. What is the optimal treatment tactic for this patient?

- A. Pericardiocentesis and immediate thoracotomy
- B. Oxygen inhalation
- C. Puncture of the pleural cavity on the left
- D. Conservative treatment, infusion of adrenomimetics
- E. Pleural cavity drainage

Clinical tasks:

Task 1.

A patient is 38 years old, grumbles about the dyspnea at the physical loading, interruptions in work of heart, transient dizziness. Till now the patient considered himself healthy. Objectively: pulse - 76/min., BP is 120/80 mm Hg. Left border of heart - on the left medioclavicular line. Systole murmur is in the Erb's point. On ECG: signs of the left ventricle hypertrophy, displacements of ST down and negative T wave in II, V5, V6. Echo-CG: back wall of the left ventricle of 1 cm, an interventricular septum 1,7 cm

Questions:

- 1) Formulate a preliminary diagnosis for a patient?
- 2) To work out a plan of patient's examination?

3) To work out a plan of assessments?

Task 2.

A patient is 38 years old, grumbles about the dyspnea, increase of temperature to 37,2°s. ARD carried out three weeks ago. Objectively: pallor, acrocyanosis. Pulse - 100/min., BP is 140/85 mm of Hg. The heart borders are extended to the left and to the right. Sounds of the heart are absent, above the apex, systolic murmur is determined. Above lungs, breathing is weakened in lower departments. On ECG: a rhythm is a sine, an II stage atrioventricular block.

- 1) Formulate the preliminary diagnosis of patient?
- 2) Work out a plan of patients' examination?
- 3) Work out a plan of settings?

Task 3.

Patient of 32 years, during 2 years grumbles about the dyspnea in a state of rest, nightly attacks of difficulty in breathing, feet edema, gradual increase of abdomen volume. Objectively: the state is heavy, acrocyanose, moist silent rales in the lower areas of lungs. Pulse - 90/min., arrhythmical. Heart sounds are weakened, systole murmur above an apex. BP is 90/60 mm Hg. Echo-CG: expansion of all of heart cavities, EF - 28 %. The valves of heart are not changed. The sheets of pericardium are not thickened.

Questions:

- 1) Formulate the preliminary diagnosis of patient?
- 2) To work out a plan of patients' examination?
- 3) To work out a plan of settings?

Summary:

Recommended reading list

Basic literature:

- Harrison's Principles of Internal Medicine Self-Assessment and Board Review, 20th Edition 20th Edition.- (August 13, 2021). - 736 pages
- Pocket Medicine: The Massachusetts General Hospital Handbook of Internal Medicine / 007 edition (12 Sept. 2019). - 272 pages
- Davidson's Principles and Practice of Medicine: Enhanced Digital Version Included / Elsevier; 23rd edition (25 April 2018). - 1440 pages

Additional literature:

- Macleod's Clinical Examination /Elsevier; 14th edition (11 Jun. 2018). - 400 pages
- Current Medical Diagnosis and Treatment /McGraw-Hill Education; Updated edition (14 Sept. 2021). - 1840 pages
- Lippincott Connect Standalone Courseware for Bates' Guide to Physical Examination and History Taking 1.0 /LWW; 13th ed. edition (23 Mar. 2023).
- Step-Up to Medicine / Wolters Kluwer Health; 5th edition (8 May 2019). - 582 pages
- Goldman-Cecil Medicine, 2-Volume Set (Cecil Textbook of Medicine) / Elsevier; 26th edition (20 Dec. 2019). - 2944 pages
- The Washington Manual of Medical Therapeutics / Wolters Kluwer Health; 36th edition (6 Jun. 2019). - 1074 pages
- Harrison's Manual of Medicine / McGraw-Hill Education; 20th edition (5 Nov. 2019). - 1245 pages

Electronic information resources

- World Health Organization. URL: www.who.int/ru/index.html.
- European Regional Office of the World Health Organization. URL: www.euro.who.int.
- <https://www.aasld.org/>
- https://academic.oup.com/ndt/pages/General_Instruction
- <https://cprguidelines.eu/>
- <https://www.escardio.org/Guidelines/Clinical-Practice-Guidelines>
- <http://www.oxfordmedicaleducation.com/>
- <http://ard.bmj.com>

- <https://www.escardio.org/Guidelines/Clinical-Practice-Guidelines>

Practical class

Topic 7. Management of a patient with heart murmurs.

The main goals: to acquire communication skills and clinical examination skills of a patient with heart murmurs; to be able to establish a preliminary diagnosis, carry out a differential diagnosis and determine the clinical diagnosis of the disease in a patient with heart murmurs; master the principles of treatment, recommendations for lifestyle changes when managing patients with heart murmurs; to be able to perform therapeutic manipulations in patients with heart murmurs.

Key words: etiology, pathogenesis and pathomorphology of diseases accompanied by heart murmurs; clinical classification of heart murmurs: nature of course, degree of activity of the process, clinical and morphological characteristics of the lesion; clinical manifestations of diseases accompanied by heart murmurs; diagnostic significance of additional research methods (general clinical, biochemical, immunological, instrumental); diagnostic criteria for diseases accompanied by heart murmurs; principles of treatment of diseases accompanied by heart murmurs, groups of drugs used and tactics of their use.

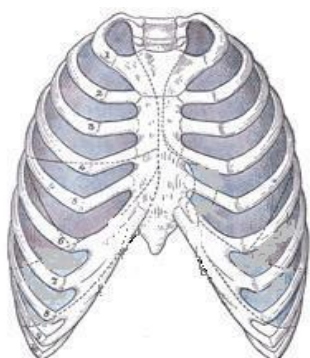
Equipment: multimedia materials - a set of thematic slides from the department's multimedia library; screenshots of laboratory test results: ACS, markers of myocardial necrosis, amylase, GHTP, LF, lipidogram, indicators of inflammation; a set of situational problems on the topic of the lesson; screenshots of instrumental research results: ECG, Echocardiography, Rg-grams; mannequin for performing the following practical skills: palpation of the chest, palpation of trigger points (intercostal, paravertebral); percussion and auscultation of the heart.

Plan:

- Organizational measures (greetings, verification of those present, announcement of the topic, purpose of the lesson, motivation of higher education seekers to study the topic)
- Control of the reference level of knowledge (checking homework, written work, written testing, including writing KROK-2 tests, frontal survey)
- Formation of professional abilities and skills (mastery of skills, curation, determination of treatment regimen, laboratory research, etc.): discussion of features of diagnosis and treatment of arterial hypertension, the most common clinical manifestations, criteria for establishing a diagnosis
- Summing up (summarizing the topic, evaluating applicants, discussing the next lesson topic and homework)

Control questions:

1. List the features of functional cardiac murmur.
2. Designate the points of auscultation of heart sounds and cardiac murmur.



3. Complete the table « Differential diagnosis of systolic cardiac murmur»

	Murmur characteristic (localization, irradiation, conditions of intensification, length, shape)	Heart sounds characteristic	Cardiomegaly features	BP and pulse features
Aortic stenosis				
Mitral deficiency				
Mitral valve prolapse				
Atrial septum defect				
Ventricular septum defect				

Complete a table « Differential diagnosis of diastolic cardiac murmur»

	Murmur characteristic (localization, irradiation, conditions of intensification, length, shape)	Heart sounds characteristic	Cardiomegaly features	BP and pulse features
Aortic deficiency				
Mitral stenosis				

4. Fill a table «Features of Echo-CG diagnostics of heart defects».

	M-regimen	B-regimen	Dopplerography
Aortic stenosis			
Mitral deficiency			
Mitral valve prolapse			
Aortic deficiency			
Mitral stenosis			

5. What patients is it possible to hear the Flints' murmur, Kumbs' murmur, Grekhema-Still's murmur? Describe these murmurs.

6. What laboratory methods of diagnostics help to reveal the reason of heart defect?

7. Classify the stages of heart defect.

8. What clinical syndromes (4) are patients with mitral valve prolapse characterized by?

MCQ's:

1. A 67-year-old man complains of dyspnea on exertion, attacks of retrosternal pain, dizziness. He has no history of rheumatism. Objectively: pale skin, acrocyanosis. There are crackles in the lower lungs. There is systolic thrill in the II intercostal space on the right, coarse systolic murmur conducted to the vessels of neck. BP- 130/90 mm Hg, heart rate - 90/min., regular rhythm. The liver extends 5 cm from under the edge of costal arch, shin edemas are present. Specify the suspected valvular defect:

- A. Aortic stenosis
- B. Pulmonary artery stenosis
- C. Mitral insufficiency
- D. Ventricular septal defect
- E. Tricuspid regurgitation

2. A 33-year-old patient has developed dyspnea during physical exertion, palpitations, disruptions of heart rate, swollen legs. In the childhood the patient had a case of acute rheumatic fever that required in-patient treatment. There were no further requests for medical care. Objectively: heart rate is 92/min., rhythmic; BP is 110/70 mm Hg. At the apex the I heart sound is increased, triple rhythm, diastolic murmur. What heart disease is most likely?

- A. Mitral valve stenosis
- B. Mitral valve failure

C. Aortic outflow stenosis

D. Aortic valve failure

E. Tricuspid valve stenosis

3. A patient, 28 years old, complains of pain and slight swelling of knee-joints, shortness of breath, 'interruptions' in heart work. An apex beat is not displaced, diastolic murmur is heard above apex and local vibration of thorax in a diastole can be palpated. What disease is it possible to think about?

A. Mitral valve insufficiency

B. Rheumatoid arthritis with heart involvement

C. Mitral stenosis

D. Aortic valve insufficiency

E. Fibrinous pericarditis

4. Echo-CG revealed a cavity of the left atrium of 5,0 cm, mitral valve is fibrously changed, posterior leaflet is shifted forward, motion of leaflets is P-like, unidirectional. What do these changes indicate?

A. Mitral valve stenosis

B. Mitral valve insufficiency

S. Prolapse of mitral valve

D. Defect of ventricular septum

E. Defect of atrial septum

5. An 19-year-old patient presents no problems. Percussion reveals that heart borders are displaced to the right and left by 1 cm, there is a coarse systolic murmur with its epicenter within the 4th intercostal space on the left. What is the most informative examination to confirm the clinical diagnosis?

A. ECG

B. Ventriculography

C. PCG

D. Holter monitoring

E. Polycardiography

6. An 18 years old patient complains about feeling of cold in feet, headache, dizziness. Objectively: hyperemia of face, pulse is rhythmic, 88/min., BP- 180/120 mm Hg. Auscultation: systolic murmur in second intercostal space to the left of sternum, which is conducted on the vessels of neck, and more expressively heard in interscapular area. X-ray: usuration of ribs surfaces. Specify the most possible disease:

A. Atherosclerosis of aorta

B. Defect of ventricular septum

C. Coarctation of the aorta

D. Arterial hypertension

E. Aortic aneurysm

7. A female rheumatic patient experiences diastolic thoracic wall tremor (diastolic thrill), accentuated S1 at apex, there is diastolic murmur with presystolic intensification, opening snap, S2 accent at pulmonary artery. What kind of heart disorder is observed?

A. Opened arterial duct

B. Aortic valve insufficiency

C. Pulmonary artery stenosis

D. Mitral valve insufficiency

E. Mitral stenosis

8. A patient, 40 years old, delivered to the hospital with complaints of shortness of breath, headache, dizziness, pain in heart area due to the physical exertion. In anamnesis frequent quinsies in childhood, episodes of consciousness loss. Objectively: general condition is satisfactory. Skin is pale. An apex beat is increased; the left border of heart is displaced to lin. medioclavicularis sin. II sound above an apex and above aorta is weakened, rough systolic murmur above aorta, which is conducted on carotids. Pulse 76/min., BP -100/60 mm Hg. What defect does the patient have?

A. Aortic valve insufficiency

B. Hypertrophic cardiomyopathy

C. Mitral valve insufficiency

D. Stenosis of aortal ostium

E. Coarctation of aorta

9. A 44 year old woman complains of dyspnea, edema of the legs and tachycardia during minor physical exertion. Heart borders are displaced to the left and S1 is accentuated, there is diastolic murmur on apex. The liver is enlarged by 5 cm. What is the cause of heart failure?

- A. Aortic stenosis
- B. Mitral stenosis
- C. Tricuspid regurgitation
- D. Tricuspid stenosis
- E. Mitral regurgitation

10. Examination of 21 years old patient revealed systolic murmur and accent of II sound in IInd intercostal space on the left, BP is 135/80 mm Hg. Specify the most possible diagnosis:

- A. Ventricular septum defect
- B. Aortosclerosis
- C. Coarctation of the aorta
- D. Insufficiency of mitral valve
- E. Stenosis of pulmonary artery ostium

Clinical tasks:

Task №1.

A woman, 32 years old, has defined rheumatism from youth, aortic defect. Felt satisfactorily. After abortion 4 months ago began to mark the gallops of temperature 37-37,6 °C, chill, indisposition, shortness of breath, pains in heart area. Got antirheumatic treatment. Objectively: a skin is pale, on thighs shallow hemorrhage pouring out. There are single unsteady moist rales in the lower departments of lungs. The heart borders are extended to the left on 3 cm. There is diastole murmur in II intercostal area, IInd sound is not determined. BP is 160/40 mm Hg, pulse, - 90/min., rapid, rhythmic. On ECG is a hypertrophy of the left ventricle. A liver and spleen come forward under costal arch on 2 cm, no pain.

Hb - 100g/l, L - 3,0x10⁹/l, ESR - 40 mm/h.

Questions:

1. To formulate the praliminary diagnosis of patient
2. To work out a plan of full clinical examination.
3. To prescribe treatment.

Task №2.

Man 67 years old, grumbles about the shortness of breath at the physical loading, sharp pains after a breastbone, dizziness. No rheumatism. Skin covers are pale, acrocyanosis. In the lower departments of lungs are moist rales. The systole trembling is in II intercostal area, rough systolic sound, which is conducted on the vessels of neck. BP -130/90 mm Hg., HR- 90/min., a rhythm is correct. A liver comes forward under the edge of costal arch on 5 cm, shins are edematous.

Questions:

1. To formulate the preliminary diagnosis of patient.
2. To work out a plan of full clinical examination.
3. To prescribe treatment.

Task №3.

A woman, 40 years old, grumbles about the shortness of breath and palpitation due to the insignificant physical loading, heaviness in right undercostal area and edema of shins. Objectively: acrocyanosis, II tone above an apex is weakened, blowing systolic murmur, which is conducted in the left armpit area. The increase of the left departments of heart is X-ray marked, thallium, smoothed out, the contrasted gullet deviates on the arc of large radius. At Doppler-echocardiography found out the regurgitation through the mitral opening.

Questions:

1. To formulate the preliminary diagnosis of patient
2. To work out a plan of full clinical examination.

3. To appoint treatment.

Summary:

Recommended reading list

Basic literature:

- Harrison's Principles of Internal Medicine Self-Assessment and Board Review, 20th Edition 20th Edition.- (August 13, 2021). - 736 pages
- Pocket Medicine: The Massachusetts General Hospital Handbook of Internal Medicine / 007 edition (12 Sept. 2019). - 272 pages
- Davidson's Principles and Practice of Medicine: Enhanced Digital Version Included / Elsevier; 23rd edition (25 April 2018). - 1440 pages

Additional literature:

- Macleod's Clinical Examination /Elsevier; 14th edition (11 Jun. 2018). - 400 pages
- Current Medical Diagnosis and Treatment /McGraw-Hill Education; Updated edition (14 Sept. 2021). - 1840 pages
- Lippincott Connect Standalone Courseware for Bates' Guide to Physical Examination and History Taking 1.0 /LWW; 13th ed. edition (23 Mar. 2023).
- Step-Up to Medicine / Wolters Kluwer Health; 5th edition (8 May 2019). - 582 pages
- Goldman-Cecil Medicine, 2-Volume Set (Cecil Textbook of Medicine) / Elsevier; 26th edition (20 Dec. 2019). - 2944 pages
- The Washington Manual of Medical Therapeutics / Wolters Kluwer Health; 36th edition (6 Jun. 2019). - 1074 pages
- Harrison's Manual of Medicine / McGraw-Hill Education; 20th edition (5 Nov. 2019). - 1245 pages

Electronic information resources

- World Health Organization. URL: www.who.int/ru/index.html.
- European Regional Office of the World Health Organization. URL: www.euro.who.int.
- <https://www.aasld.org/>
- https://academic.oup.com/ndt/pages/General_Instruction
- <https://cprguidelines.eu/>
- <https://www.escardio.org/Guidelines/Clinical-Practice-Guidelines>
- <http://www.oxfordmedicaleducation.com/>
- <http://ard.bmj.com>
- <https://www.escardio.org/Guidelines/Clinical-Practice-Guidelines>

Practical class

Topic 8. Management of a patient with heart failure.

The main goals: to acquire communication skills and clinical examination skills of a patient with heart failure; to be able to establish a preliminary diagnosis, carry out a differential diagnosis and determine the clinical diagnosis of the disease in a patient with heart failure; master the principles of treatment, recommendations for lifestyle changes in the management of patients with heart failure; to be able to perform therapeutic manipulations in patients with heart failure.

Key words: definition of the term chronic heart failure; types of HF: right and left ventricular; diastolic and systolic (with reduced left ventricular ejection fraction (LVEF), with preserved left ventricular ejection fraction (LVEF), with an average level of left ventricular ejection fraction (LVEF)); classification of CH according to Vasylenko-Strazhesko and according to NYHA; collection of anamnesis from a patient with HF; mastering practical skills (listening for the presence of III tone (gallop rhythm), recognition of congestive rales in the lungs, presence of transudate, determination of expansion and pulsation of the jugular veins, signs of congestive hepatomegaly, hepatojugular reflux, assessment of edema of the lower extremities); characteristics of laboratory methods (BNP, NT-proBNP, general blood test, general urinalysis; biochemical tests: K⁺, Na⁺, creatinine and GFR, plasma cholesterol, bilirubin, "liver" enzymes, glucose, uric acid); interpretation of the results of instrumental research methods (ECG (aneurysm, scars), echocardiography, ultrasound of the pleural

cavity, X-ray 6- minute walk test).

Equipment: multimedia materials - a set of thematic slides from the department's multimedia library; screenshots of laboratory test results: ACS, markers of myocardial necrosis, amylase, GHTP, LF, lipidogram, indicators of inflammation; a set of situational problems on the topic of the lesson; screenshots of instrumental research results: ECG, Echocardiography, Rg-grams; mannequin for performing the following practical skills: palpation of the chest, palpation of trigger points (intercostal, paravertebral); percussion and auscultation of the heart.

Plan:

- Organizational measures (greetings, verification of those present, announcement of the topic, purpose of the lesson, motivation of higher education seekers to study the topic)
- Control of the reference level of knowledge (checking homework, written work, written testing, including writing KROK-2 tests, frontal survey)
- Formation of professional abilities and skills (mastery of skills, curation, determination of treatment regimen, laboratory research, etc.): discussion of features of diagnosis and treatment of arterial hypertension, the most common clinical manifestations, criteria for establishing a diagnosis
- Summing up (summarizing the topic, evaluating applicants, discussing the next lesson topic and homework)

Control questions:

1. List the reasons for development of cardiac insufficiency depending on etio-pathogenetic mechanisms.
2. Describe the basic clinical forms of cardiac insufficiency (systole and diastole HF, sharp and chronic HF, left ventricular, right ventricular, biventricular HF, HF with low and high cardiac heart ejections).
3. Clinical value of the left ventricle non-symptom dysfunction.
4. List the most typical echocardiography changes due to CHF and give their clinical estimation.
5. List the most typical information of X-ray thorax examination due to HF, tactic of doctor.
6. List the most typical pathological ECG changes due to HF, tactic of doctor.
7. Method and clinical value of 6-minute walking test for patients with CHF.
8. Describe the most typical laboratory rejections at HF, specify the algorithm of reacting.
9. List the testimonies for conducting of coronary angiography in patients with CHF.
10. To conduct the CHF classification with an account of:
 - a) The clinical stage,
 - b) Variant of HF,
 - c) Functional class on the criteria of NYHA.

MCQ's:

1. A patient is 60 years old, 2 years ago suffered myocardial infarction, complains of the attacks of dyspnea at night. Objectively at a time of such attack: general condition is grave, orthopnea. acrocyanosis. Pulse - 120/min. BP is 100/60 mm Hg. RR - 36/min., rhythmic. 2nd sound above apex is weakened, rhythm of gallop, accent of II sound above pulmonary artery. Breathing is weakened in the lower parts of lungs. What complication appeared in a patient?
 - A. Bronchial asthma attack
 - B. Severe pulmonary heart
 - C. Cardiac asthma attack
 - D. Cardiogenic shock
 - E. Thromboembolism of the pulmonary artery
2. Male 70 years old, for more than 12 years suffers from arterial hypertension. Last year had myocardial infarction. Has IInd group of disability. Takes 40 mg of nitrosorbid daily. On examination: cyanosis, swelling of neck vessels, dyspnea at minimal physical exertion, feet edema. The borders of heart are shifted to the left, sounds are weakened, systolic murmur above the apex, accent of II tone above aorta. Pulse - 96/min., BP - 130/90 mm Hg. Specify the reason for BP normalization in a

patient.

- A. Reduction of myocardium contractility
- B. Constant use of nitrates
- C. Regress of atherosclerosis
- D. Increase of natriuretic hormone level
- E. Increasing volume of circulating blood

3. During dynamic investigation of a patient the increase of central venous pressure is combined with the decrease of arterial pressure. What process is proved by such combination?

- A. Increase of bleeding speed
- B. Developing of cardiac insufficiency
- C. Shunting
- D. Depositing of blood in venous channel
- E. Presence of hypervolemia

4. A 42 y.o. patient with rheumatic heart disease complains of anorexia, weakness and loss of weight, breathlessness and swelling of feet. The patient had tooth extraction one month ago. On examination: t° - 39°C , Ps - 104/min. Auscultation: diastolic murmur in the mitral area. Petechial lesion around the clavicle; spleen is palpable. What is the preliminary diagnosis?

- A. Aortic stenosis
- B. Thrombocytopenia purpura
- C. Subacute bacteria endocarditis
- D. Mitral stenosis
- E. Recurrence of rheumatic fever

5. Patient 60 years old, 2 years ago suffered Q-wave myocardial infarction. In the last 2 months dyspnea appeared and began to progress, decreases in sitting position. Objectively: cyanosis of face and neck, jugular veins swelling, enlarged and painful liver, expressed feet edema. X-ray and echocardiographic examination revealed moderate amount of liquid in the pericardium cavity. What is the most possible cause of pericardium changes?

- A. Tuberculosis pericarditis
- B. Acute infectious-allergic pericarditis
- C. Dressler's syndrome
- D. Hydropericardium
- E. Rheumatic pancarditis

6. A 66 years-old patient complains of dyspnea at rest and feet edema. For the last 20 years suffers from arterial hypertension. Smokes 30 cigarettes a day. Objectively: dull percussion sound and weakening of vesicular breathing in the lower segments of right lung, dry rales above left lung. BP is 170/110 mm Hg, pulse, - 105/min., arrhythmical. X-ray: homogeneous decline of transparency with a slanting level. Specify the most possible reason of pulmonary pathology for this patient.

- A. Pneumonia, exudative pleurisy
- B. Heart failure with hydrothorax
- C. Lung cancer with atelectasis
- D. Lung tuberculosis
- E. Renal insufficiency with anasarca

7. Patient, 54 years old, with the expressed dyspnea, 3 years ago suffered Q-wave myocardial infarction, complicated with the left ventricle front wall aneurysm. On examination: cyanosis of skin and mucous membranes, acrocyanosis, orthopnea. HR - 110/min. BP is 110/70 mm Hg. On auscultation plenty of fine bubbling rales are heard above lungs. ECG: no dynamics if compared to archive ECG. What is the most possible diagnosis?

- A. Cardiac asthma
- B. Lung edema
- C. Cardiogenic shock
- D. Repeated myocardial infarction
- E. Post hospital pneumonia

8. A 60-year old patient, after the examination IHD: post-infarction cardiosclerosis, stable angina of III FC, heart failure of IIA stage were diagnosed. Which one among the listed criteria is the most

reliable for systolic heart failure variant diagnostics?

- A. Dyspnea at loadings
- B. Edema of lower extremities in the evening
- C. Ejection fraction < 40 %
- D. Moist rales are in the lower areas of lungs
- E. Hepatomegaly

9. Patient of 46 years old, delivered by an ambulance with complaints of the dyspnea at rest, palpitation, interruptions in heart work, weakness. Objectively: condition is grave, orthopnea, expressed acrocyanosis. RR - 28/min. Auscultation: moist fine bubbling rales in the lower segments of lungs. An apex beat is shifted to the left and down; the borders of heart are extended to the left for 3,5 cm. Sounds of heart are muffled, protodiastolic gallop rhythm. BP is 150/70 mm of Hg. Pulse - 94/min., weak filling. Liver is 4 cm lower the edge of costal arch. Edema of lower extremities. Which of listed symptoms is a reliable sign of left-ventricular heart failure on physical examination?

- A. Rales above lungs
- B. Tachycardia
- C. Heart extension
- D. Rhythm of gallop
- E. Orthopnea

10. An attack of dyspnea began suddenly at night in a 63 years old woman. History: suffers from arterial hypertension for 15 years, 2 years ago had myocardial infarction. Objectively: position in bed - orthopnea, skin is pale, covered with cold sweat, acrocyanosis. Pulse -104/min. BP - 210/ 130 mm Hg, RR - 38/min. On percussion - resonant lung sound, dullness in lower segments, above all areas of lungs single dry rales are heard, in lower segments - multiple fine bubbles rales. What complication have certainly developed in a patient?

- A. Acute left ventricular failure
- B. Paroxysmal tachycardia
- C. Bronchial asthma attack
- D. Thromboembolism of pulmonary artery
- E. Acute left atrial failure

Summary:

Recommended reading list

Basic literature:

- Harrison's Principles of Internal Medicine Self-Assessment and Board Review, 20th Edition 20th Edition.- (August 13, 2021). - 736 pages
- Pocket Medicine: The Massachusetts General Hospital Handbook of Internal Medicine / 007 edition (12 Sept. 2019). - 272 pages
- Davidson's Principles and Practice of Medicine: Enhanced Digital Version Included / Elsevier; 23rd edition (25 April 2018). - 1440 pages

Additional literature:

- Macleod's Clinical Examination /Elsevier; 14th edition (11 Jun. 2018). - 400 pages
- Current Medical Diagnosis and Treatment /McGraw-Hill Education; Updated edition (14 Sept. 2021). - 1840 pages
- Lippincott Connect Standalone Courseware for Bates' Guide to Physical Examination and History Taking 1.0 /LWW; 13th ed. edition (23 Mar. 2023).
- Step-Up to Medicine / Wolters Kluwer Health; 5th edition (8 May 2019). - 582 pages
- Goldman-Cecil Medicine, 2-Volume Set (Cecil Textbook of Medicine) / Elsevier; 26th edition (20 Dec. 2019). - 2944 pages
- The Washington Manual of Medical Therapeutics / Wolters Kluwer Health; 36th edition (6 Jun. 2019). - 1074 pages
- Harrison's Manual of Medicine / McGraw-Hill Education; 20th edition (5 Nov. 2019). - 1245 pages

Electronic information resources

- World Health Organization. URL: www.who.int/ru/index.html.
- European Regional Office of the World Health Organization. URL: www.euro.who.int.

- <https://www.aasld.org/>
- [https://academic.oup.com/ndt/pages/General Instruction](https://academic.oup.com/ndt/pages/General_Instruction)
- <https://cprguidelines.eu/>
- <https://www.escardio.org/Guidelines/Clinical-Practice-Guidelines>
- <http://www.oxfordmedicaleducation.com/>
- <http://ard.bmj.com>
- <https://www.escardio.org/Guidelines/Clinical-Practice-Guidelines>

Practical class

Topic 9. Management of a patient with shortness of breath

The main goals: to acquire communication skills and clinical examination skills of a patient with shortness of breath; be able to establish a preliminary diagnosis, carry out a differential diagnosis and determine the clinical diagnosis of the disease in a patient with shortness of breath; master the principles of treatment, recommendations for lifestyle changes when managing patients with shortness of breath; diagnose emergency conditions in patients with shortness of breath; master the tactics of providing emergency medical aid to patients with shortness of breath; to be able to perform therapeutic manipulations in patients with heart failure.

Key words: definition of shortness of breath ("expiratory shortness of breath", "inspiratory shortness of breath", "mixed shortness of breath"); etiology and pathogenesis of diseases that cause shortness of breath (exudative pericarditis, bronchial asthma (BA), chronic obstructive pulmonary disease (COPD), pneumonia, exudative pleurisy, pulmonary emphysema, pneumosclerosis, lung and heart failure); diagnostic value of clinical, instrumental and laboratory examination data to determine the disease that caused shortness of breath; principles of non-drug and drug treatment of patients with diseases that progress with shortness of breath syndrome; complications, prognosis and working capacity of patients with diseases accompanied by shortness of breath; primary and secondary prevention of diseases accompanied by shortness of breath.

Equipment: multimedia materials - a set of thematic slides from the department's multimedia library; screenshots of the results of general clinical, biochemical, immunological, instrumental research methods; a set of situational problems on the topic of the lesson; mannequin for performing the following practical skills: palpation of the chest, palpation of trigger points (intercostal, paravertebral); percussion and auscultation of the lungs.

Plan:

1. Organizational measures (greetings, verification of those present, announcement of the topic, purpose of the lesson, motivation of higher education seekers to study the topic)
2. Control of the reference level of knowledge (checking homework, written work, written testing, including writing KROK-2 tests, frontal survey).
3. Formation of professional abilities and skills (mastery of skills, curation, determination of treatment regimen, laboratory research, etc.): discussion of features of diagnosis and treatment of arterial hypertension, the most common clinical manifestations, criteria for establishing a diagnosis
4. Summing up (summarizing the topic, evaluating applicants, discussing the next lesson topic and homework)

Quiz:

1. Define dyspnea and suffocation? What kind of heart and vascular, respiratory, nervous and other systems disease can cause shortness of breath and suffocation?
2. Describe the features of dyspnea and suffocation in patients with diseases of the respiratory system?
3. Describe the features of dyspnea and suffocation in patients with diseases of the cardiovascular system?
4. Describe the features of dyspnea and suffocation in patients with diseases of the nervous system?

5. Describe the diagnostic possibilities of instrumental diagnostic methods (ECG, ECG with physical activity, echocardiogram, Holter monitor daily, X-ray of the heart and lungs) in determining the causes and severity of wheezing and dyspnea in patients with cardiovascular diseases?
6. Describe the diagnostic possibilities of instrumental diagnostic methods (ECG, X-ray of the heart and lungs, respiratory function tests) to determine the causes and severity of wheezing and dyspnea in patients with pulmonary pathology?
7. Tactics of treatment of patients, depending on the genesis of dyspnea?
8. Feature of non-drug, medical and surgical treatment?
9. Complete the table "Differential diagnostic signs of pulmonary embolism, cardiac and bronchial asthma.

Sign	PATE	Cardiac asthma	Bronchial asthma

10. Prognosis and capability of patients with shortness of breath and suffocation?

MCQ's:

1. 63-year-old patient, 20 days from the beginning of myocardial infarction suddenly developed sharp pain in the left half of thorax, followed by an attack of dyspnea. Objectively: the patient is excited, skin and mucous membranes are pale, cyanotic. Varicose veins of lower extremities. Pulse - 120/min., BP - 100/70 mm Hg. Heart sounds are weakened, accent of II tone on the pulmonary artery. Above the lungsweakened breathing sounds on the left side. ECG-dynamics - turning the electrical axis of the heart to the right. Indicate the most likely cause of the patient's deterioration:
 - A. Recurrent MI
 - B. Dressler's syndrome
 - C. Pneumonia
 - D. Pleural effusion
 - E. Pulmonary embolism
2. The patient was treated from myocardial infarction. On the 13-th day his condition got worse: chest pain, shortness of breath appeared. Objective: temperature-38, 2 ° C, heart rate - 112/min., RR - 26/min. Under the right scapula a small-bubbling rales could be heard, and 2 days later right-sided pleural effusion was diagnosed. Complete blood count: L - $8,9 \times 10^9/L$, eosinophils - 8%, ESR - 24 mm / min. What is the complication of myocardial infarction in this patient?
 - A. Re-infarction
 - B. Pulmonary embolism
 - C. Acute left ventricular failure
 - D. Dressler's syndrome
 - E. Pneumonia
3. A 49-year-old male patient complains of dyspnea of combined nature, cough, edema, abdomen enlargement due to ascites. He has a 20-year history of chronic bronchitis. For the last 3 years he has been disabled (group II) because of cardiac changes. Objectively: mixed cyanosis, edema. Ps - 92/min, rhythmic, BP - 120/70 mm Hg, respiration rate - 24/min. Accentuation of the second sound above the pulmonary artery. Auscultation reveals the box resonance sound above the lungs, dry rales over the entire surface of lungs. What is the mechanism of heart changes development in this patient?
 - A. Respiratory reflex
 - B. Kitaev's reflex
 - C. Bainbridge reflex
 - D. Cardiovascular reflex

E. Euler-Liljestrand reflex

4. A 62-year-old patient has been admitted to a hospital with complaints of dyspnea, tightness in the right subcostal area, abdomen enlargement. These presentations have been progressing for a year. Objectively: swelling of the neck veins, heart auscultation reveals presystolic gallop rhythm, ascites, palpable liver and spleen. Chest X-ray reveals pericardium fibrosis. What disease most probably caused dyspnea in this patient?

- A. Chronic pulmonary heart
- B. Hepatocirrhosis
- C. Lung cancer with invasion to the pleura
- D. Constrictive pericarditis
- E. Pulmonary embolism

5. A 66-year-old patient complains of severe pain in the right side of chest, dyspnea, dry cough which appeared suddenly on exertion. Objectively: the right side of the chest lags behind in the act of breathing. Percussion reveals tympanic sound. Auscultation reveals pronouncedly diminished breath sounds on the right. Ps- 100/min, weak, arrhythmic. AP- 100/50 mm Hg. Cardiac sounds are weakened. What disease can be suspected in this patient?

- A. Right-sided pneumothorax
- B. Right-sided hydrothorax
- C. Right-sided dry pleurisy
- D. Right-sided pleuropneumonia
- E. Pulmonary embolism

6. In a patient, 54 years old, with Q wave myocardial infarction of left ventricular posterior wall on the 5th day suddenly episode of suffocation appeared. Position - orthopnea. In lungs - scattered dry rales, in the lower parts - small bubbling rales. Pansystolic murmur appeared in the field of cardiac apex, which is transmitted to the left armpit. Deterioration is likely due to:

- A. Dressler's Syndrome
- B. Interventricular septum rupture
- C. Relapse of myocardial infarction
- D. Papillary muscle rupture
- E. The development of endocarditis

7. A 45-year-old man was brought to clinic with complaints of the pain that started suddenly in the left chest part and epigastric area, shortness of breath, nausea, one-time vomiting. The acute pain started after weight-lifting. On physical exam: shallow breathing, RR - 38/min, left chest part is behind during respiration, by percussion - tympanic sound, respiration is not auscultated. Ps - 110 bpm, of weak filling. BP - 100/60 mm Hg, insignificant displacement of heart to the right, sounds are dull. What examination is the most expedient to do first?

- A. Chest X-Ray
- B. Electrocardiography
- C. Bronchoscopy
- D. Esophagogastroscopy
- E. Ultrasound of the abdominal cavity

8. A 59-year-old male patient complains of dyspnea on exertion, heaviness in the right hypochondrium and shin edemata towards evening. Objectively: temperature - 38,1°C, HR - 20/min, HR=Ps=92/min, AP- 140/90 mm Hg. There is apparent kyphoscoliosis. In the lungs dry and wheezing rales can be auscultated. Heart sounds are muffled, rhythmic. ECG: Rv1+Sv5=15 mm. X-ray picture shows the bulging of pulmonary artery cone, right ventricle enlargement. What is the most likely cause of this condition?

- A. Atherosclerotic cardiosclerosis
- B. Cor pulmonale
- C. Dilatation cardiomyopathy
- D. Mitral stenosis
- E. Primary pulmonary hypertension

9. A patient 60 years of age, who has been suffering from hypertension for 20 years, after a stressful situation suddenly developed an attack of dyspnea. Objective: orthopnea, heart rate - 120/min., BP -

210/120 mm Hg. 1st sound over the apex of the heart is weakened, an additional sound heard in diastole, respiratory rate - 32/min. Respiration over the lower parts of the lungs is weakened, single small bubbling moist rales. What complication did the patient develop?

- A. Aortic dissection
- B. Hysteria attack
- C. Thromboembolism of pulmonary artery branches
- D. Pneumonia
- E. Acute left ventricular failure

10. A 60 y.o. patient complains of acute sensation of air insufficiency, following the venoectomy due to subcutaneous vein thrombophlebitis 3 days ago. Patient's skin became cyanotic, with grey shade. Marked psychomotor excitement, tachypnea, substernal pain. What postoperative complication has occurred?

- A. Hypostatic pneumonia
- B. Hemorrhagia
- C. Pulmonary embolism
- D. Myocardial infarction
- E. Valvular pneumothorax

Clinical task:

Task № 1

Patient 66 years old, 5 years ago suffered from myocardial infarction. At night, acutely developed dyspnea of mixed type, there was a dry cough, palpitations. OBJECTIVE: excited, respiratory rate - 34/min. Above the lungs: isolated dry rales in the lower divisions - small amount of moist rales. The left border of the heart is shifted to the left by 3 cm, tachycardia - to 120/min. Rhythmic sounds, accent of the IInd sound on the pulmonary artery. BP - 245/105 mm Hg.

Questions:

- 1) Formulate a preliminary diagnosis of the patient.
- 2) Make a plan of complete clinical examination of the patient.
- 3) Make a plan of treatment.

Task № 2

The patient, aged 47, complained of fever up to 39 ° C, fever, sweating, dry cough, shortness of breath, chest pain on the right with a deep breath and cough. Acute disease started six days ago. OBJECTIVE: in a serious condition, the skin is pale, RR - 28/min, in the lower right half of the chest the voice trembling is absent, percussion - a dull sound, auscultation - breath sharply weakened.

Questions:

- 1) Formulate a preliminary diagnosis of the patient.
- 2) Make a plan of complete clinical examination of the patient.
- 3) Make a plan of treatment.

Task № 3

The doctor was turned the 19 years-old patient, who had been ill with dry pleurisy, bronchitis. During the high jump at the playground he felt a sharp pain in the left side, severe shortness of breath. OBJECTIVE: pale, blue lips, the left half of the chest behind the act of breathing. Percussion: left - tambourines auscultation - lack of breathing. Pulse - 98/min., BP - 90/50 mm Hg.

Questions:

- 1) Formulate a preliminary diagnosis of the patient.
- 2) Make a plan of complete clinical examination of the patient. 3) Make a plan of treatment

Summary:

Recommended reading list

Basic literature:

- Harrison's Principles of Internal Medicine Self-Assessment and Board Review, 20th Edition 20th Edition.- (August 13, 2021). - 736 pages

- Pocket Medicine: The Massachusetts General Hospital Handbook of Internal Medicine / 007 edition (12 Sept. 2019). - 272 pages
- Davidson's Principles and Practice of Medicine: Enhanced Digital Version Included / Elsevier; 23rd edition (25 April 2018). - 1440 pages

Additional literature:

- Macleod's Clinical Examination /Elsevier; 14th edition (11 Jun. 2018). - 400 pages
- Current Medical Diagnosis and Treatment /McGraw-Hill Education; Updated edition (14 Sept. 2021). - 1840 pages
- Lippincott Connect Standalone Courseware for Bates' Guide to Physical Examination and History Taking 1.0 /LWW; 13th ed. edition (23 Mar. 2023).
- Step-Up to Medicine / Wolters Kluwer Health; 5th edition (8 May 2019). - 582 pages
- Goldman-Cecil Medicine, 2-Volume Set (Cecil Textbook of Medicine) / Elsevier; 26th edition (20 Dec. 2019). - 2944 pages
- The Washington Manual of Medical Therapeutics / Wolters Kluwer Health; 36th edition (6 Jun. 2019). - 1074 pages
- Harrison's Manual of Medicine / McGraw-Hill Education; 20th edition (5 Nov. 2019). - 1245 pages

Electronic information resources

- World Health Organization. URL: www.who.int/ru/index.html.
- European Regional Office of the World Health Organization. URL: www.euro.who.int.
- <https://www.aasld.org/>
- https://academic.oup.com/ndt/pages/General_Instruction
- <https://cprguidelines.eu/>
- <https://www.escardio.org/Guidelines/Clinical-Practice-Guidelines>
- <http://www.oxfordmedicaleducation.com/>
- <http://ard.bmj.com>
- <https://www.escardio.org/Guidelines/Clinical-Practice-Guidelines>

Practical class

Topic 10. Management of a patient with edematous syndrome.

The main goals: to acquire communication skills and skills of clinical examination of a patient with edema syndrome; be able to establish a preliminary diagnosis, carry out a differential diagnosis and determine the clinical diagnosis of the disease in a patient with edematous syndrome; master the principles of treatment, recommendations for lifestyle changes in the management of patients with edematous syndrome; diagnose emergency conditions in patients with edematous syndrome; master the tactics of providing emergency medical care to patients with edematous syndrome; to be able to perform therapeutic manipulations in patients with edematous syndrome.

Key words: etiology, pathogenesis, pathomorphology, clinical features of the course of diseases accompanied by the development of edematous syndrome (acute and chronic glomerulonephritis, heart failure with "congestive kidney", diabetic nephropathy, liver cirrhosis); laboratory-instrumental signs of the diseases listed above; the technique of interviewing the patient to identify signs of organ damage and diseases that caused swelling; formulation of the preliminary diagnosis of the disease; differential diagnosis of edematous syndrome; tactics of treatment of a patient with edematous syndrome; prognosis of the course of the disease, recommendations for treatment and prevention of the detected disease.

Equipment: multimedia materials - a set of thematic slides from the department's multimedia library; screenshots of the results of general clinical, biochemical, immunological, instrumental research methods; a set of situational problems on the topic of the lesson; mannequin for performing the following practical skills: palpation of the chest, palpation of trigger points (intercostal, paravertebral); percussion and auscultation of the lungs.

Plan:

- Organizational measures (greetings, verification of those present, announcement of the topic, purpose of the lesson, motivation of higher education seekers to study the topic)
- Control of the reference level of knowledge (checking homework, written work, written testing, including writing KROK-2 tests, frontal survey).
- Formation of professional abilities and skills (mastery of skills, curation, determination of treatment regimen, laboratory research, etc.): discussion of features of diagnosis and treatment of arterial hypertension, the most common clinical manifestations, criteria for establishing a diagnosis
- Summing up (summarizing the topic, evaluating applicants, discussing the next lesson topic and homework)

Control questions:

1. Define a term “edema”, “edema syndrome”
2. Systematize edemas on prevalence, pathogenetic mechanisms of development
3. Expound the mechanisms of edema syndrome's formation at chronic cardiac insufficiency
4. Define a concept “nephrotic syndrome”. Specify main principles of its development
5. Expound the mechanisms of edema syndrome's formation at myxedema (hyperthyreosis)
6. What are the mechanisms of edema syndrome's formation at hypoproteinemic state?
7. Classification of diuretics. Mechanisms of their action, indications, contra-indications. Side effects
8. Basic principles of chronic cardiac insufficiency therapy
9. Basic principles of nephrotic syndrome therapy
10. Basic principles of myxedema (hypothyroidism) therapy

MCQ's:

1. The basic manifestations of nephrotic syndrome are all listed, EXCEPT:
 - A) High proteinuria
 - B) Increased level of creatinine
 - C) Hypo- and disproteinemia
 - D) Edema
 - E) Hypolipidemia
2. All these symptoms can be present in myxedema (hypothyroidism), EXCEPT:
 - A) Pretibial localization of edema
 - B) Edematic skin does not detain the fingerprints
 - C) Increase of diuresis
 - D) Increase of blood pressure
 - E) Edema disappears after L-thyroxin therapy
3. Following are the reasons of edema syndrome at chronic heart failure, EXCEPT:
 - A) Increase of RAAS's activity
 - B) Increase of SAS' activity
 - C) Reduction of cardiac output
 - D) Reduction of vasopressin's activity
 - E) Increase of potassium urinary excretion
4. A 25-year-old man has facial edema, moderate back pains. His temperature is 37,5°C, BP 180/100 mm Hg, hematuria [up to 100 in v/f], proteinuria [2,0 g/L], hyaline casts - 10 in v/f., specific gravity - 1020. The onset of the disease is probably connected with acute tonsillitis that started 2 weeks ago. What is the most probable diagnosis?
 - A. Acute pyelonephritis
 - B. Acute glomerulonephritis
 - C. Cancer of the kidney
 - D. Urolithiasis
 - E. Chronic glomerulonephritis
5. The edema syndrome is typical for all these stages of chronic heart failure, EXCEPT:
 - A) II A, systolic type
 - B) II B, , systolic type

- C) III stage
 - D) Leftventricular isolated
 - E) Rightventricular isolated
6. All these researches have to be carried out for stage specification of chronic heart failure, EXCEPT:
- A) Cardiac ultrasound
 - B) Ergometry testing
 - C) Ultrasound of liver, kidneys
 - D) ECG, bilirubin
 - E) Urea and creatinin
7. The basic manifestations of chronic heart failure caused by pulmonary hypertension are all of listed, EXCEPT:
- A) Jugular venous distention
 - B) Tricuspidinsufficiency
 - C) Tricuspid valve stenosis
 - D) Hypertrophy of right ventricle on ECG
 - E) Peripheral edema and liver congestion
8. Digoxin is used as a treatment of chronic cardiac insufficiency in:
- A) Atrial fibrillation
 - B) Hypertention
 - C) Total atrio-ventricular blockade
 - D) Aortic valvular disease
 - E) All answers are wrong
9. The most frequent symptom of left ventricular insufficiency is:
- A) Heart pain
 - B) Cyanosis
 - C) Orthopnea
 - D) Stridorotic breathing
 - E) Ascites
10. What mentioned criteria is the most reliable sign in diagnostics of systolic cardiac insufficiency?
- A) Dyspnea on exertion
 - B) Edema of the lower extremities
 - C) Ejection fraction is less than 40%
 - D) Moist rales in the low parts of lungs
 - E) Enlargement of the liver

Clinical tasks:

Task 1.

The man, 63 years old, had myocardial infarction for 2 times, and has been suffered from essential hypertension III stage for about 15 years. Permanent form of fibrillation was exposed during the last 2 years. He entered cardiological department with complaints of night attacks of breathlessness, heartbeat at the least physical loading, breathlessness at rest, weakness and sleeplessness. It was found objectively cyanosis; his pulse was 52/min, arrhythmic. Pulse rate was 60/min, ABP was 160/95 mm.m.c. Respiration rate was 24/min. There was the accent of 2nd tone upon the pulmonary artery and jugular venous distention. It was found clear pulmonary sound upon whole of lung surface. Dry rales were auscultated upon all pulmonary area; there were smallvesicle, noteless rales in lower pulmonary area. Edema of shin and scrotum was observed. It was revealed the enlargement of the liver on 3 sm with the rounded side. EcoCS: EV was 35%. Creatinin of plasma was 0,109 mmol/l.

Questions:

1. Specify the stage and the functional class of chronic cardiac insufficiency:
2. The patient must be prescribed everything, EXCEPT:
3. Make up the plan of the treatment.

Task 2.

Woman, 52 years old, observes the increase of her weight and edemas after menopause's beginning.

She has addressed to a doctor with complaints of weakness, fatigability, chill, constipation, drowsiness and hair loss. During the inspection the woman is deferred; with dry and xanthic skin. It is observed the overweight; edematous face, expressed periorbital edema. It is revealed bradycardia during the physical examination. Pulse is 64/min, soft, AP is 160/100 mm.m.c. She has enlargement of the heart (heart sounds are dull) and edema of extremities. Hypochromic anemia, relative lymphocytosis, eosinophilia, deceleration of ESR are observed in blood analysis. Cholesterol is 25 mmol/l. Basal metabolic rate is 25%.

Questions:

1. Name the most probable diagnosis:
2. Everything must be executed for the diagnosis specification, EXCEPT:
3. Carry out the differential diagnosis.

Task 3.

Woman, 40 years old, has been hospitalized with expressed edemas. Edemas appeared some months ago. At the inspection nephrotic syndrome was found. 11 grams of protein is excreted with urine for the day. Creatinin of plasma is 0,9 mmol/l. Morphological changes of renal structure isn't observed at the optical researches of kidneys' biopat. Immunofluorescent research also hasn't exposed any pathology. The epicytes' changes, whose small processes flow together along glomerular capillaries, were observed during electronic microscopy. Prednisolone was prescribed to the patient in daily dose 60 mg. After the 8 weeks of the therapeutic course edemas have considerably diminished, but Cushingoid's changes have appeared. Daily protein excretion is 5 grams in 24 hours. Prednisolone was delayed and Diuretics were prescribed by the doctor. Edemas have disappeared, general condition has improved. The patient appealed for medical aid because of edemas in 2 years. Creatinin of plasma during the second hospitalization is 3,7 mmol/l, daily protein excretion is 14 gr.

Questions:

1. What has been diagnosed during the first hospitalization?
2. What would have been the most probable diagnosis, if the renal biopsy had been made during the second hospitalization?
3. What medicines must be prescribed during the second hospitalization?

Summary:

Recommended reading list

Basic literature:

- Harrison's Principles of Internal Medicine Self-Assessment and Board Review, 20th Edition 20th Edition.- (August 13, 2021). - 736 pages
- Pocket Medicine: The Massachusetts General Hospital Handbook of Internal Medicine / 007 edition (12 Sept. 2019). - 272 pages
- Davidson's Principles and Practice of Medicine: Enhanced Digital Version Included / Elsevier; 23rd edition (25 April 2018). - 1440 pages

Additional literature:

- Macleod's Clinical Examination /Elsevier; 14th edition (11 Jun. 2018). - 400 pages
- Current Medical Diagnosis and Treatment /McGraw-Hill Education; Updated edition (14 Sept. 2021). - 1840 pages
- Lippincott Connect Standalone Courseware for Bates' Guide to Physical Examination and History Taking 1.0 /LWW; 13th ed. edition (23 Mar. 2023).
- Step-Up to Medicine / Wolters Kluwer Health; 5th edition (8 May 2019). - 582 pages
- Goldman-Cecil Medicine, 2-Volume Set (Cecil Textbook of Medicine) / Elsevier; 26th edition (20 Dec. 2019). - 2944 pages
- The Washington Manual of Medical Therapeutics / Wolters Kluwer Health; 36th edition (6 Jun. 2019). - 1074 pages
- Harrison's Manual of Medicine / McGraw-Hill Education; 20th edition (5 Nov. 2019). - 1245 pages

Electronic information resources

- World Health Organization. URL: www.who.int/ru/index.html.
- European Regional Office of the World Health Organization. URL: www.euro.who.int.

- <https://www.aasld.org/>
- [https://academic.oup.com/ndt/pages/General Instruction](https://academic.oup.com/ndt/pages/General_Instruction)
- <https://cprguidelines.eu/>
- <https://www.escardio.org/Guidelines/Clinical-Practice-Guidelines>
- <http://www.oxfordmedicaleducation.com/>
- <http://ard.bmj.com>
- <https://www.escardio.org/Guidelines/Clinical-Practice-Guidelines>

Practical class

Topic 11. Management of a patient with pain in the back and limbs.

The main goals: to acquire communication skills and skills of clinical examination of a patient with back pain; be able to establish a preliminary diagnosis, carry out a differential diagnosis and determine the clinical diagnosis of the disease in a patient with back pain; master the principles of treatment, recommendations for lifestyle changes when managing patients with back pain; diagnose emergency conditions in patients with back pain; master the tactics of providing emergency medical care to patients with edematous syndrome; to be able to perform therapeutic manipulations in patients with back pain.

Key words: etiological factors of back pain; classification and clinical types of back pain; basic principles of diagnosis of patients with pain in the back and limbs, according to existing standards; possible risk factors for pain syndrome in the back and limbs; etiology and pathogenesis of ankylosing spondylitis (AS) / synonym - Bekhterev's disease (CB), myeloma disease; the results of laboratory and instrumental examination methods that are important for diagnosis; tactics of differential therapy; secondary prevention measures; prognosis and degree of working capacity.

Equipment: multimedia materials - a set of thematic slides from the department's multimedia library; screenshots of the results of general clinical, biochemical, immunological, instrumental research methods; a set of situational problems on the topic of the class; a set of radiographs, a negatoscope; electronic versions of radiographs.

Plan:

- Organizational measures (greetings, verification of those present, announcement of the topic, purpose of the lesson, motivation of higher education seekers to study the topic)
- Control of the reference level of knowledge (checking homework, written work, written testing, including writing KROK-2 tests, frontal survey)
- Formation of professional abilities and skills (mastery of skills, curation, determination of treatment regimen, laboratory research, etc.): discussion of features of diagnosis and treatment of arterial hypertension, the most common clinical manifestations, criteria for establishing a diagnosis
- Summing up (summarizing the topic, evaluating applicants, discussing the next lesson topic and homework)

Control questions:

1. Explain the pathogenesis and clinical features of the reflected back pain due to internal diseases (myocardial infarction, pericarditis, pleurisy, stratified aneurysm of the aorta, spontaneous pneumothorax, penetrating gastric ulcer, acute cholecystitis, renal colic).
2. What clinical features are characteristic for pain in the back and extremities, associated with intervertebral discs hernia?
3. What clinical features are characteristic for pain in the back and extremities, associated with metastatic lesions and multiple myeloma?
4. List the diagnostic criteria for ankylosing spondyloarthritis and reactive arthritis. Why was the name of Reiter's disease changed?
5. Describe the methods of objective examination of patients with ankylosing spondyloarthritis.

6. What extraarticular lesions are possible in patients with ankylosing spondylitis and reactive arthritis?
7. What laboratory methods are needed to verify the back pain causes?
8. What X-ray changes are typical for patients with ankylosing spondylitis and reactive arthritis?
9. What are the basic principles of pharmacological treatment of patients with ankylosing spondylitis and reactive arthritis.
10. What antimicrobial preparations and for what purpose are prescribed to patients with reactive arthritis and postenterocolitic arthritis?

MCQ's:

1. A 40 years old patient is ill for about 8 years. Complains about pain in the lumbar spine, more in the morning, in neck and thoracic spine, especially during cough, pain in hip and knee joints on the right. Objectively: body is fixed in position of inclination forward with the head dropped downward, atrophy of buttock muscles. X-ray of spine: vertebral osteoporosis, ossification of longitudinal ligaments. What diagnose is most probable?
 - A. Ankylosing spondylitis
 - B. Tuberculous spondylitis
 - C. Psoriatic spondylarthropathy
 - D. Spondylarthropathy due to reactive arthritis
 - E. Complicated osteochondrosis of spine
2. A patient is 40 years old, suffers from Bekhterev's disease, complains of increase of body temperature to 37,8°C, pain in the back, especially in the second half of night. He is ill for 2 years. Objectively: limitation of movement in a spine, pain in the sacroiliac joint, ESR - 45 mm/h. X-ray reveals narrowing of sacroiliac joints space. What ophtalmic pathology often does appear in case of such flow of disease?
 - A. Visual nerve atrophy
 - B. Retinal detachment
 - C. Cataract
 - D. Iris and ciliary body inflammation
 - E. Blepharitis
3. A 48-year-old woman complains of pain in the thoracic spine, sensitivity disorder in the lower body, disrupted motor function of the lower limbs, body temperature rise up to 37,5°C. She has been suffering from this condition for 3 years. Treatment by various specialists was ineffective. X-ray reveals destruction of adjacent surfaces of the VIII and IX vertebral bodies. In the right paravertebral area at the level of lesion there is an additional soft tissue shadow. What diagnosis is most likely?
 - A. Tuberculous spondylitis of the thoracic spine
 - B. Spinal tumor
 - C. Multiple sclerosis
 - D. Metastases into the spine
 - E. Osteochondrosis
4. As a result of load lifting a 68-year-old woman developed acute pain in the lumbar region, in a buttock, posterolateral surface of her right thigh, external surface of the right shin and dorsal surface of foot. Objectively: weakness of the anterior tibial muscle, long extensor muscle of the right toes, short extensor muscle of the right toes. Low Achilles reflex on the right. Positive Lasegue's sign. What examination method would be most effective for specification of the diagnosis of L5 root discogenic compression?
 - A. Magnetic resonance scan
 - B. Spinal column X-ray
 - C. Electromyography
 - D. Angiography
 - E. Lumbar puncture
5. 22 y.o. man complains of having morning pains in his back for the last three months. The pain can be relieved during the day and after physical exercises. Physical examination revealed reduced mobility in the lumbar part of his spine, increase of muscle tonus in the lumbar area and sluch during moving. X-ray pattern of spine revealed bilateral sclerotic changes in the sacrolumbar part. What test

will be the most necessary for confirming a diagnosis?

- A. Uric acid in blood plasma
- B. Antinuclear antibodies
- C. ESR
- D. Rheumatoid factor
- E. HLA-B27

6. Patient 70 years old, complains on pain in area of humeral joints, buttocks, thighs, morning stiffness more than 1 hour, weight loss. Got sick sharply, symptoms grew for 2 weeks. On examination: contraction and pain in muscles on palpation in the noted areas, ESR - 60 mm/h. Treatment must begin with:

- A. Non-steroid anti-inflammatory drugs
- B. Glucocorticosteroids
- C. Drugs of 4-aminoquinoline group
- D. Myospasmodics
- E. None of listed

7. Woman, 32 years old, complains of intensive pains in knee joints, neck. In the morning feels pains in interscapular area, feet joints; pain weakens after stretching up joints. Patient has high body weight, a crunch is heard in knees on bending them, the shape of joints is changed, joints are sensible on palpation. In a blood test: ESR - 18 mm/h., L. - $8,0 \times 10^9/L$. X-ray: sclerosis of right subcartilaginous plate is in the left knee-joint. What is the basis of this pathology?

- A. Urates deposit (tophi) in joint tissues
- B. Auto-immune process in a synovial layer
- C. Degenerative processes in a cartilage
- D. Infection with beta-hemolytic streptococcus
- E. Hemorrhage in a joint

8. 37-year-old patient complains of pain in the lumbar spine that is getting stronger during walking; restricted mobility, edema of the right side of abdomen. He has a history of focal tuberculosis. X-ray picture shows the destruction of the adjacent surfaces of the 1-2 vertebral bodies of the lumbar spine, vertebral body height is decreased, intervertebral foramen is undetectable. Abdominal ultrasound reveals a 15*20 cm formation in the retroperitoneal space, there are echo signals of fluid presence. What is the most likely diagnosis?

- A. Tuberculous spondylitis of the lumbar spine
- B. Fracture of the 1-2 vertebral bodies of the lumbar spine
- C. Spinal metastases
- D. Spondylolisthesis of the lumbar spine
- E. Osteochondrosis

9. Man of 31 years old, a few years periodically treated from radiculitis of lumbosacral spine. In the last 2 months pain appeared in the joints of upper and lower extremities, which increased in the second half of night. Objectively: slight swelling of knee-joints, pain on palpation of lumbosacral spine, limitations of thorax mobility at deep breathing. Because of suspicion on Bekhterev's disease patient was prescribed the spine and hip-bone X-ray examination. What X-ray changes are the most possible?

- A. Multiple cystic changes
- B. Osteoporosis, usuration of joint surfaces
- C. The joint space decrease, osteophytosis
- D. Bilateral sacroileitis
- E. Increased joint space, subchondral sclerosis

10. A 35-year-old patient has been admitted to a hospital for pain in the left sternoclavicular and knee joints, lumbar area. The disease has an acute character and is accompanied by fever up to 38°C. Objectively: the left sternoclavicular and knee joints are swollen and painful. In blood: WBCs - $9,5 \times 10^9/l$, ESR - 40 mm/h, CRP - 1,5 millimole/l, fibrinogen - 4,8 g/l, uric acid - 0,28 millimole/l. Examination of the urethra scrapings reveals chlamydia. What is the most likely diagnosis?

- A. Gout
- B. Rheumatic arthritis
- C. Reiter's syndrome

- D. Bechterew's disease
- E. Rheumatoid arthritis

Clinical tasks:

Task №1.

Man 38 years old, during 3 years marks a general fatigue, pains and constraint in the lower and middle departments of the back, sterno-clavicular joint and neck. Pain especially increases between 3 and by a 6 o'clock of morning sleep. Pain and constraint can diminish at physical exercises. The patient also marks redness, pain in eyes and sensitiveness to light. ESR- 27 mm/h. X-ray exposed syndesmophits in the pectoral and lumbar departments of spine.

Question:

- 1) Formulate the preliminary diagnosis of patient
- 2) What diagnostic tests is it necessary to execute for spine defeat clinical features establishment?
- 3) Work out a plan of complete patient's examination.
- 4) Appoint the plan of treatment.

Task №2.

The patient, 72 years old, complaints on pain in the back, in right arm, feeling the numbness in both hands, dizziness. Pain increased after heavy suitcase raising. Patient has high body mass. BP 135/80 mm Hg. ESR- 12 mm/h. On the X-ray examination of spine 6 months ago there revealed marginal bone excrescences and subchondral sclerosis of vertebrae bodies.

Question:

- 1) Formulate the preliminary diagnosis of patient.
- 2) Work out a plan of complete patient's examination.
- 3) Write the plan of treatment.

Task №3.

A patient, 28 years old, grumbles about pain in joints on mastication, expressed pains in small of the back, disuria. Once or twice treated aphthose stomatitis. On examination: keratoderma of soles psoriatic skins changes on elbows. Hb- of a 105 gr/l, ESR- 22 mm/h., pus cells in urine 10 -14 in sight area.

Question:

- 1) Formulate the preliminary diagnosis of patient
- 2) Work out a plan of complete patient's examination
- 3) Appoint treatment of this patient.

Summary:

Recommended reading list

Basic literature:

- Harrison's Principles of Internal Medicine Self-Assessment and Board Review, 20th Edition 20th Edition.- (August 13, 2021). - 736 pages
- Pocket Medicine: The Massachusetts General Hospital Handbook of Internal Medicine / 007 edition (12 Sept. 2019). - 272 pages
- Davidson's Principles and Practice of Medicine: Enhanced Digital Version Included / Elsevier; 23rd edition (25 April 2018). - 1440 pages

Additional literature:

- Macleod's Clinical Examination /Elsevier; 14th edition (11 Jun. 2018). - 400 pages
- Current Medical Diagnosis and Treatment /McGraw-Hill Education; Updated edition (14 Sept. 2021). - 1840 pages
- Lippincott Connect Standalone Courseware for Bates' Guide to Physical Examination and History Taking 1.0 /LWW; 13th ed. edition (23 Mar. 2023).
- Step-Up to Medicine / Wolters Kluwer Health; 5th edition (8 May 2019). - 582 pages
- Goldman-Cecil Medicine, 2-Volume Set (Cecil Textbook of Medicine) / Elsevier; 26th edition (20 Dec. 2019). - 2944 pages
- The Washington Manual of Medical Therapeutics / Wolters Kluwer Health; 36th edition (6 Jun. 2019). - 1074 pages
- Harrison's Manual of Medicine / McGraw-Hill Education; 20th edition (5 Nov. 2019). - 1245 pages

Electronic information resources

- World Health Organization. URL: www.who.int/ru/index.html.
- European Regional Office of the World Health Organization. URL: www.euro.who.int.
- <https://www.aasld.org/>
- https://academic.oup.com/ndt/pages/General_Instruction
- <https://cprguidelines.eu/>
- <https://www.escardio.org/Guidelines/Clinical-Practice-Guidelines>
- <http://www.oxfordmedicaleducation.com/>
- <http://ard.bmj.com>
- <https://www.escardio.org/Guidelines/Clinical-Practice-Guidelines>

Practical class

Topic 12. Management of a patient with joint syndrome.

The main goals: to acquire communication skills and clinical examination skills of a patient with joint syndrome; be able to establish a preliminary diagnosis, carry out a differential diagnosis and determine the clinical diagnosis of the disease in a patient with joint syndrome; master the principles of treatment, recommendations for lifestyle changes in the management of patients with joint syndrome; diagnose emergency conditions in patients with joint syndrome; master the tactics of providing emergency medical care to patients with edematous syndrome; to be able to perform therapeutic manipulations in patients with joint syndrome.

Key words: main clinical manifestations of rheumatic diseases; joint syndrome - nosological features; basic and additional research methods in rheumatology; laboratory research methods and their clinical significance; instrumental methods of research of patients with rheumatic diseases and their clinical significance;

Equipment: multimedia materials - a set of thematic slides from the department's multimedia library; screenshots of the results of general clinical, biochemical, immunological, instrumental research methods; a set of situational problems on the topic of the class; a set of radiographs, a negatoscope; electronic versions of radiographs.

Plan:

- Organizational measures (greetings, verification of those present, announcement of the topic, purpose of the lesson, motivation of higher education seekers to study the topic)
- Control of the reference level of knowledge (checking homework, written work, written testing, including writing KROK-2 tests, frontal survey)
- Formation of professional abilities and skills (mastery of skills, curation, determination of treatment regimen, laboratory research, etc.): discussion of features of diagnosis and treatment of arterial hypertension, the most common clinical manifestations, criteria for establishing a diagnosis
- Summing up (summarizing the topic, evaluating applicants, discussing the next lesson topic and homework)

Quiz:

1. Describe the clinical, laboratory and X-ray manifestations of articular syndrome in patients with acute rheumatic fever.
2. Describe the clinical, laboratory and X-ray manifestations of articular syndrome in patients with rheumatoid arthritis.
3. Describe the clinical, laboratory and X-ray manifestations of articular syndrome in patients with reactive arthritis.
4. Describe the clinical, laboratory and X-ray manifestations of articular syndrome in patients with lupus.
5. Describe the clinical, laboratory and X-ray manifestations of articular syndrome in patients with osteoarthritis.
6. Describe the clinical, laboratory and X-ray manifestations of articular syndrome in patients with gouty arthritis.
7. Provide modern diagnostic criteria for rheumatism, rheumatoid arthritis, lupus, gout.
8. List the modern principles of lupus treatment, which drugs are effective for the most manifest joint syndrome?
9. List the modern principles of rheumatoid arthritis treatment. What complications are possible with the use of NSAIDs, the corticosteroids.
10. List the modern principles of gouty arthritis treatment

MCQ's:

1. Patient 27 years old, who has rheumatoid arthritis for 7 months, objectively has edema of elbow, radio-carpal, knee and ankle joints, rheumatoid nodules in elbow area. In blood: ESR- 56 mm/h., CRP(+++). On the X-ray of specified joints osteoporosis is revealed. What should be the basic therapy in such situation?
 - A. Diclofenac sodium
 - B. Indometacin
 - C. Methotrexate
 - D. Prednisone
 - E. Meloxicam
2. A patient is 18 years old, grumbles about a general weakness, increase of temperature to 37,8°C, palpitation, shortness of breath during walking, pain in knee joints. Got sick a month ago, in 2 weeks after having quinsy. Objectively: pinky colored skin, pulse - 98/min., BP is 100/60 mm Hg. Left heart border 0,5 cm out from lin. medioclavicularis sin. Ist sound above apex is weakened. Tender systolic murmur is heard. A doctor suspected rheumatism. What is the further tactic?
 - A. Send to otorhinolaryngologist for consultation
 - B. To conduct examination and ambulatory treatment
 - C. Prescribe the sick-leave and to treat to temperature normalization
 - D. To send to policlinic rheumatologist for consultation
 - E. To send on the in-patient department examination and treatment
3. The patient, 17 years old, has complains of intense pain in large joints of hands, in heart area, palpitations, feet edema, that appeared after travel to Egypt. Temperature is 38,8°C. Pallor of skin, erythematic rash above affected joints. Erosions on red lips border, areas of hairs falling out. Noise of pleura friction under the left scapula. Heart sounds are deaf. Pulse - 124/min., BP is 160/100 mm Hg. Hb -92 g/l, ESR- 66 mm/h. CRP-(+++). Positive Wasserman's reaction. Which additional diagnostic researches will be the most informative for this disease' diagnosis?
 - A. Anti-nuclear antibodies
 - B. Immune-blotting and immune-enzyme reaction
 - C. Rheumatic factor determination
 - D. Titer of ASL-0
 - E. Biopsy of skin and muscles
4. In a 16 years old patient on the 3rd week after ARD notices an increase of body temperature, phenomena of migrant polyarthritis, on the skin of trunk and proximal extremities parts there is pinky

barely noticeable rash as a thin rim. Weak systolic murmur on the apex of heart. On ECG: small lengthening of interval of PQ, ESR is increased, positive CRP. What is the most credible diagnosis?

- A. Infectious endocarditis
- B. Rheumatoid arthritis
- C. Infectiously-allergic myocarditis
- D. Acute rheumatic fever
- E. Arthritis due to German measles

5. A 55 years old male, was admitted to clinic because of renal colic, which periodically repeated during last year. Objectively: under the skin of ears and right elbow joint nodular formations are seen, covered a thin glossy skin. Pulse - 88/min. BP is 170/100 mm Hg. Pasternackiy's symptom is positive on both sides What test is the most necessary to clarify the diagnosis?

- A. ESR
- B. Rheumatoid factor
- C. Uric acid
- D. Urinary sediment
- E. Lactic acid

6. 30 y.o. female with rheumatoid arthritis of five years duration complains of pain in the first three fingers of her right hand over past 6 weeks. The pain seems especially severe at night often awakening her from sleep. The most likely cause is?

- A. Rheumatoid vasculitis
- B. Atlanto-axial subluxation of cervical spine
- C. Sensory peripheral neuropathy
- D. Carpal tunnel syndrome
- E. Rheumatoid arthritis without complication

7. A 18 y.o. male patient complains of pain in knee and ankle joints, temperature elevation to 39,5°C. He had a respiratory disease 1,5 week ago. On examination: temperature - 38,5°C, swollen knee and ankle joints, pulse - 106 bpm, rhythmic, AP - 90/60 mm Hg, heart borders without changes, sounds are weakened, soft systolic apical murmur. What indicator is connected with possible etiology of the process?

- A. alpha1-antitrypsine
- B. Antistreptolysine-O
- C. Creatinkinase
- D. Rheumatic factor
- E. Seromuroid

8. A 30 year old patient complains about pain in small joints of her hands, paresthesia at the tips of fingers, weakness, difficult deglutition. She has been suffering from this for 13 years. Objectively: face anemia, shortening of nail bones, skin indurations in the area of shoulder girdle are present. Roentgenological examination of lungs revealed basal pneumosclerosis. Fibrogastroscopy revealed esophagus constriction in its cardiac part. Blood count: leukocytes - $9,8 \cdot 10^9/L$, ESR - 22 mm/h, gamma-globulin - 22%. What is the most probable diagnosis?

- A. Myxedema
- B. Systemic lupus erythematosus
- C. Systemic scleroderma
- D. Dermatomyositis
- E. Rheumatoid arthritis

9. Female patient, 24 years old, had acute enterocolitis of infectious genesis. She was treated in an infectious hospital. After the discharge an acute pain appeared in a right knee followed by joint edema. Objectively: joint is slightly painful on palpation, mobility is limited. In blood: leucocytosis, ESR - 30 mm/h, CRP (++) , fibrinogen - 5,2 g/L, alpha-2-globulins - 12%, the titre of antibodies to iersinias is increased, RF(-). What is the diagnosis?

- A. Reactive arthritis.
- B. Reuter's disease.
- C. Osteoarthritis
- D. Gout.

E. Chondromatosis of joint.

10. A 56 years old female patient with excessive body mass complains of pain in knee joints, which increases after walking, especially on a stairs and due to prolonged standing on feet. Considers herself ill for 5 years. Objectively: knee joints are deformed, edematous, sensitive on movement, crackle on movement. X-ray of joints - a joint space is narrowed, prominent subchondral sclerosis, regional osteophits are present. What diagnosis is most possible?

- A. Rheumatoid arthritis
- B. Rheumatic arthritis
- C. Reactive arthritis
- D. Gout
- E. Osteoarthritis

Clinical tasks:

Task №1.

A patient 43 years old, worker of meat-packing plant, grumbles about pain and slight swelling, redness in left metatarso-phalanx joint of 1st finger and right ankle joint. Pain interferes with the least movement, increases at stress. He is ill for 3 years, last acute attack of the disease after the beerdrinking, dry sausage eating. Objectively: joints are crimson, edematous, sensitive by touch. On the X- ray of joint there is narrowing of joint crack, expressly limited defects of bone tissue in epiphyses ("symptom of punch").

Question:

- 1) Make a preliminary diagnosis.
- 2) Make the chart of examination.
- 3) Conduct differential diagnostics.
- 4) Make the chart of treatment.
- 5) Give clinic and pharmacologic description and ground of the appointed preparations necessity.

Task №2.

Patient N., 60 years, grumbles about a morning constraint in the joints of both wrists, narrow-mindedness of motions. Objectively: elbow deviation of both wrists, deformation of II, III fingers on the type of "neck of swan" on both sides, sunken interosseous intervals. An increase of RF titre is in blood serum. X-ray: epiphysis osteoporosis, narrowing of joint cracks, incomplete dislocations.

Question:

- 1) Make a preliminary diagnosis
- 2) Make the chart of examination
- 3) Conduct differential diagnostics
- 4) Make the chart of treatment
- 5) Give clinical and pharmacological description and ground of appointed preparations necessity.

Task №3.

Patient 25 years old, had acute enterocolitis of infectious genesis. After the discharge from an infectious hospital acute pain appeared in a right knee-joint with an edema, the joint is sensitive, mobility is limited. In blood: leukocytosis, ESR- 30mm/ch., CRP(++), fibrinogen- 5,2 gr/l, alpha-2-globulin -12%, titre of antibodies to infectious agents is increased, RF is not exposed.

Question:

- 1) Make a preliminary diagnosis
- 2) Make the chart of examination
- 3) Make the chart of treatment
- 4) Give clinical and pharmacological description and ground of the appointed preparations necessity

Summary:

Recommended reading list

Basic literature:

- Harrison's Principles of Internal Medicine Self-Assessment and Board Review, 20th Edition 20th

Edition.- (August 13, 2021). - 736 pages

- Pocket Medicine: The Massachusetts General Hospital Handbook of Internal Medicine / 007 edition (12 Sept. 2019). - 272 pages
- Davidson's Principles and Practice of Medicine: Enhanced Digital Version Included / Elsevier; 23rd edition (25 April 2018). - 1440 pages

Additional literature:

- Macleod's Clinical Examination /Elsevier; 14th edition (11 Jun. 2018). - 400 pages
- Current Medical Diagnosis and Treatment /McGraw-Hill Education; Updated edition (14 Sept. 2021). - 1840 pages
- Lippincott Connect Standalone Courseware for Bates' Guide to Physical Examination and History Taking 1.0 /LWW; 13th ed. edition (23 Mar. 2023).
- Step-Up to Medicine / Wolters Kluwer Health; 5th edition (8 May 2019). - 582 pages
- Goldman-Cecil Medicine, 2-Volume Set (Cecil Textbook of Medicine) / Elsevier; 26th edition (20 Dec. 2019). - 2944 pages
- The Washington Manual of Medical Therapeutics / Wolters Kluwer Health; 36th edition (6 Jun. 2019). - 1074 pages
- Harrison's Manual of Medicine / McGraw-Hill Education; 20th edition (5 Nov. 2019). - 1245 pages

Electronic information resources

- World Health Organization. URL: www.who.int/ru/index.html.
- European Regional Office of the World Health Organization. URL: www.euro.who.int.
- <https://www.aasld.org/>
- https://academic.oup.com/ndt/pages/General_Instruction
- <https://cprguidelines.eu/>
- <https://www.escardio.org/Guidelines/Clinical-Practice-Guidelines>
- <http://www.oxfordmedicaleducation.com/>
- <http://ard.bmj.com>
- <https://www.escardio.org/Guidelines/Clinical-Practice-Guidelines>

Practical class

Topic 13. Management of a patient with broncho-obstructive syndrome.

The main goals: to acquire communication skills and clinical examination skills of a patient with broncho- obstructive syndrome; be able to establish a preliminary diagnosis, carry out a differential diagnosis and determine the clinical diagnosis of the disease in a patient with broncho-obstructive syndrome; master the principles of treatment, recommendations for lifestyle changes in the management of patients with broncho-obstructive syndrome; to diagnose emergency conditions in patients with broncho-obstructive syndrome; master the tactics of providing emergency medical care to patients with broncho-obstructive syndrome; to be able to perform therapeutic manipulations in patients with broncho-obstructive syndrome.

Key words: the structure of the bronchial tree and lungs, the function of external breathing, blood circulation and biomechanics of breathing; etiology, pathogenesis of BA; modern classification, clinical features of BA; differential diagnosis of BA with COPD, pneumonia, pulmonary tuberculosis, lung tumors accompanied by broncho-obstructive syndrome; basic instrumental and laboratory research methods that prove the presence of BA; tactics of management of asthma patients depending on the causes, principles of differential treatment, indications for transfer of patients to the intensive care unit; primary and secondary prevention of BA, prognosis.

Equipment: multimedia materials - a set of thematic slides from the department's multimedia library; screenshots of the results of instrumental and laboratory tests (peak flowmetry, spirometry, radiography, bronchography, CT, bronchoscopy, ECG, EGDS); a set of situational problems on the topic of the class; a set of radiographs, a negatoscope; electronic versions of radiographs.

Plan:

1. Organizational measures (greetings, verification of those present, announcement of the topic, purpose of the lesson, motivation of higher education seekers to study the topic)
2. Control of the reference level of knowledge (checking homework, written work, written testing, including writing KROK-2 tests, frontal survey)
3. Formation of professional abilities and skills (mastery of skills, curation, determination of treatment regimen, laboratory research, etc.): discussion of features of diagnosis and treatment of arterial hypertension, the most common clinical manifestations, criteria for establishing a diagnosis
4. Summing up (summarizing the topic, evaluating applicants, discussing the next lesson topic and homework)

The control question:

1. Definition of bronchial obstruction, the clinical criteria.
2. What are the main causes and differs bronchial obstruction in asthma and COPD.
3. Definition of COPD according to the WHO. Classification.
4. Definition of BA according to the WHO. Classification.
5. What is the research method used to monitor respiratory functions of BA, its diagnostic value.
6. The most frequent complications of asthma.
7. The most frequent complications of COPD.
8. Tactics destination bronchodilators in asthma and COPD in accordance with standard treatment.
9. Tactics purpose of steroids in asthma and COPD in accordance with standard treatment.
10. Prevention and non-pharmacological treatment of asthma and COPD.

MCQ's:

1. A 45 year-old male suffering from bronchial asthma for 12 years, developed an attack of asthma, which he failed to stop with salbutamol (used for 12 times during the day). What is the reason for the ineffectiveness of salbutamol in relieving of attack?
 - A. Alpha-1 adrenoceptor blockade
 - B. Lowering of blood pH level due to carbon dioxide
 - C. Deactivation and down-regulation of beta-adrenoreceptors
 - D. Decreased density of alpha 2-adrenoreceptors
 - E. Increased edema of the bronchial mucosa
2. Male of 62 years old, noted increased shortness of breath during the last month, productive cough, fever. Objective examination: body temperature 37,1 C, respiratory rate 24 per min., Pulse / heart rate 88 per min., BP=120/70 mm Hg. Skin cyanosis, swollen neck veins, lower legs and feet edema. Therapist assigned spirometry study. Which indicators best reflects the chronic airway obstruction?
 - A. Vital lung capacity
 - B. Forced expiratory volume.
 - C. Residual lung capacity
 - D. Expiratory reserve volume
 - E. Forced vital capacity
3. Topographic percussion of lungs in a patient who got a serious job-related barotrauma revealed that the lower lungs borders were located one rib below normal, there was a significant increase in both lungs height and Kronig's isthmus. What disease should be suspected in the first place?
 - A. Pulmonary emphysema
 - B. Exudative pleuritis
 - C. Chronic bronchitis
 - D. Bronchial asthma
 - E. Pneumothorax
4. Which of the following factors best reflects airway obstruction?
 - A. Maximum lung ventilation (MVL)
 - B. Residual lung volume (RV)
 - C. Forced expiratory volume in 1 sec. (FEV-1)
 - D. Forced vital capacity (FVC)

- E. The ratio of FEV-1/FVC
5. Doctor enters the ward where five patients with respiratory system diseases are located. Which patient must be examined by a doctor in the first place?
- Lying on his right side
 - Lying on his left side
 - Sitting at a table and reading the newspaper.
 - Sitting on the bed, leaning on the edge.
 - Lying on his back on the bed with a raised head end.
6. A 22 y.o. patient with bronchial asthma experiences dyspnea attacks 3-4 times a week. Nocturnal attacks are 1 time a week. FEV1- 50% of necessary figures, during the day it's variations is 25%. What is the severity of persistent bronchial asthma condition?
- Asthmatic status
 - Mild condition
 - Serious condition
 - Moderate severity condition
 - Intermittent flow
7. Male, 36 years old, suffered pneumonia and began to note that the inhalation of smoke, exhaust fumes, deodorants, as well as the transition from a warm room out into the street is causing cough, chest tightness, feeling of lack of air. This condition can be regarded as:
- Protracted bronchitis from pneumonia
 - Syndrome of bronchial hyperreactivity
 - Asthma
 - Hyperventilation syndrome
 - All of the above
8. A 23-year-old patient had taken 1 g of aspirin to treat acute respiratory infection. After that he developed an asthmatic fit with labored expiration that was arrested by introduction of aminophylline. The patient's medical history is not burdened with allergies. The patient has undergone two surgeries for nasal polyposis in the past. What diagnosis is most likely?
- Aspirin-induced asthma
 - Atopic bronchial asthma
 - Infectious allergic bronchial asthma
 - Exercise-induced asthma
 - Symptomatic bronchospasm
9. The patient is 46 years old suffering from bronchial asthma in combination with hypertension II stage, 2 degree. What is the most appropriate drug to control blood pressure?
- ACE inhibitors
 - Calcium channel blockers, short-acting
 - Calcium channel blockers, prolonged
 - Beta-blockers
 - Diuretics
- 10 A worker, aged 39, working in the slate production during 15 years, complains of expiratory exertional dyspnea, dry cough. On examination: deafening of the percutory sounds in interscapular region, rough breath sounds, dry disseminated rales. On fingers' skin - greyish warts. Factory's sectorial doctor suspects asbestosis. Which method is the most informative for diagnosis verification?
- Blood gases examination
 - Bronchoscopy
 - Spirography
 - Bronchoalveolar lavage
 - Thorax roentgenography

Clinical tasks:

Task N 1.

Patient 38 years old, was taken to hospital SMP. Complaints about Acute shortness of breath and pain in the right half of the thorax, increasing with breathing and coughing, expressed general weakness. He

suffers from childhood asthma. By the time of acute deterioration being bronchial asthma is not disturbed. The patient was preparing to leave the sanatorium, sharply raised the suitcase. It felt a sudden pain in the right half of the chest, and appeared the above complaints. On examination - patient initiated, covered with cold, sticky sweat, mild cyanosis of the skin. Respiratory rate - 32 in 1 min., Superficial. Rib cage shape is similar to barrel, right at percussion - tympanic sound, same voice trembling weakened over the other departments - the sound boxed. On auscultation - breath sharply weakened the right, left on the back of the breathing hard, isolated dry rales. Rhythmic activity of the heart, teaching, 96 in 1 min., Heart sounds are muffled, the accent colors on the P pulmonary artery. Radiography of the chest cavity: sharply defined edge of the right lung, separated from the skeleton of the thorax distinct zone, devoid of lung pattern. Mediastinum shifted to the left side. ECG: sinus rhythm, right, HR 96 in 1 min., EOS is shifted to the right, signs of hypertrophy of the right ventricle and right atrium. General blood and urine tests were normal.

The control question:

1. Formulate a diagnosis.
2. Explain the pathogenesis of clinical symptoms.
3. What are diseases that can complicate the specified condition.
4. The program of treatment.
5. Emergency.
6. The program of differential diagnosis

Task № 2.

Patient 40 years, 16 years working in the foundry. For many years, complained of cough with mucous-purulent sputum, especially in autumn and winter. The deterioration occurred after SARS, no longer separated sputum, cough, painful, causing pain in the muscles of the chest and abdomen.

OBJECTIVE: Cyanosis person, heart sounds muffled. Above the light percussion boxed sound, breathing weakened vesicular with extended expiration, scattered dry rales.

VLC - 2,4 l with proper 4,2 l

The control question:

1. Formulate a preliminary diagnosis
- 2.. What are the symptoms indicate the development of pulmonary emphysema.
3. Describe the possible radiological changes
4. Describe the possible changes in ECG
5. Treatment programs
6. Criteria for referral MSEC

Task № 3.

Patient aged 42, miner. Complaints suddenly uncurled weakness, shortness of breath, "the fear of death", chills, nausea, vomiting, a one-time, the urge to urinate. In the history of frequent colds, manifested by increased temperature to 38 ° C, cough with mucous and purulent sputum. In the past few months, persistent cough, in the morning, abundant expectoration of purulent sputum mostly nature. On examination the patient: skin of normal color. BP 126/72 mmHg Pulse / heart rate 80 1 min. Rhythmically. The fingers in the form of "drumsticks", nails in the form of "time windows". The boundaries of the relative cardiac dullness in the normal range. Heart sounds are clear, the focus is not. Thorax barrel shape, uniformly involved in the act of breathing, lung excursion is somewhat limited. Percussion - pulmonary bandbox sound, to the left down corner of the blade - its shortening in this region when auscultation is determined by the weakening of breathing, moist medium bubbling rale, the rest of the lung during breathing listens hard, dry rales. The abdomen was normal. Diagnostic purposes has been appointed bronchography. After 2 minutes after irrigation larynx dicaine appeared the above complaints. And 10 minutes later, pale skin, high humidity. BP 60/20 mm. RT. Art., pulse 120 in 1 min., rhythmic. Expiratory dyspnea, respiratory rate 40 per 1 min. Activity of the heart is excited, muted tones. During the examination the patient lost consciousness, appeared convulsions, foam from his mouth, dilated pupils.

The control question:

1. For what purpose was appointed bronchography

2. What changes in the lung could be identified with radiography, bronchography.
3. Formulate a diagnosis of the developed after irrigation larynx dicaine.
4. What are the pathogenetic mechanisms of this condition.
5. Bring the volume of emergency assistance.

Summary:

Recommended reading list

Basic literature:

- Harrison's Principles of Internal Medicine Self-Assessment and Board Review, 20th Edition 20th Edition.- (August 13, 2021). - 736 pages
- Pocket Medicine: The Massachusetts General Hospital Handbook of Internal Medicine / 007 edition (12 Sept. 2019). - 272 pages
- Davidson's Principles and Practice of Medicine: Enhanced Digital Version Included / Elsevier; 23rd edition (25 April 2018). - 1440 pages

Additional literature:

- Macleod's Clinical Examination /Elsevier; 14th edition (11 Jun. 2018). - 400 pages
- Current Medical Diagnosis and Treatment /McGraw-Hill Education; Updated edition (14 Sept. 2021). - 1840 pages
- Lippincott Connect Standalone Courseware for Bates' Guide to Physical Examination and History Taking 1.0 /LWW; 13th ed. edition (23 Mar. 2023).
- Step-Up to Medicine / Wolters Kluwer Health; 5th edition (8 May 2019). - 582 pages
- Goldman-Cecil Medicine, 2-Volume Set (Cecil Textbook of Medicine) / Elsevier; 26th edition (20 Dec. 2019). - 2944 pages
- The Washington Manual of Medical Therapeutics / Wolters Kluwer Health; 36th edition (6 Jun. 2019). - 1074 pages
- Harrison's Manual of Medicine / McGraw-Hill Education; 20th edition (5 Nov. 2019). - 1245 pages

Electronic information resources

- World Health Organization. URL: www.who.int/ru/index.html.
- European Regional Office of the World Health Organization. URL: www.euro.who.int.
- <https://www.aasld.org/>
- https://academic.oup.com/ndt/pages/General_Instruction
- <https://cprguidelines.eu/>
- <https://www.escardio.org/Guidelines/Clinical-Practice-Guidelines>
- <http://www.oxfordmedicaleducation.com/>
- <http://ard.bmj.com>
- <https://www.escardio.org/Guidelines/Clinical-Practice-Guidelines>

Practical class

Topic 14. Management of a patient with infiltrative darkening in the lungs.

The main goals: to acquire communication skills and skills of clinical examination of a patient with infiltrative darkening in the lungs; to be able to establish a preliminary diagnosis, carry out a differential diagnosis and determine the clinical diagnosis of the disease in a patient with infiltrative darkening in the lungs; master the principles of treatment, recommendations for lifestyle changes in the management of patients with infiltrative darkening of the lungs; to diagnose emergency conditions in patients with infiltrative darkening in the lungs; to master the tactics of providing emergency medical care to patients with infiltrative darkening of the lungs; to be able to perform therapeutic manipulations in patients with infiltrative darkening in the lungs.

Key words: definition of pulmonary infiltrate; leading criteria for assessing the nature of the pathological process (position of mediastinal organs, shadow structure); the method of survey and examination of patients with pulmonary infiltrate; leading syndromes of the disease based on the data obtained during the survey and examination of patients, formulation of the preliminary diagnosis

taking into account the classification of the given disease; examination plan; the method of carrying out a differential diagnosis according to the leading syndrome of the disease; formulation of the final clinical diagnosis; principles of treatment of patients with diseases that lead to the formation of pulmonary infiltrate; peculiarities of diagnosis of limited pulmonary infiltrate; round shadow syndrome; ring-shaped shadow in the lung field; outbreaks and limited dissemination; diffuse dissemination.

Equipment: multimedia materials - a set of thematic slides from the department's multimedia library; screenshots of the results of instrumental and laboratory tests (ECG, CT scan, ultrasonograms); a set of situational problems on the topic of the lesson; a set of radiographs, a negatoscope; electronic versions of radiographs.

Plan:

- Organizational measures (greetings, verification of those present, announcement of the topic, purpose of the lesson, motivation of higher education seekers to study the topic)
- Control of the reference level of knowledge (checking homework, written work, written testing, including writing KROK-2 tests, frontal survey)
- Formation of professional abilities and skills (mastery of skills, curation, determination of treatment regimen, laboratory research, etc.): discussion of features of diagnosis and treatment of arterial hypertension, the most common clinical manifestations, criteria for establishing a diagnosis
- Summing up (summarizing the topic, evaluating applicants, discussing the next lesson topic and homework).

The control question:

1. Definition - pulmonary infiltration.
2. Infiltrate types (size, number, shape, density, location, communication with the root of the lung).
3. Clinical semiology of inflammatory pneumonic infiltration.
4. Clinical semiology of tuberculous pulmonary infiltration.
5. Clinical semiology of disseminated pulmonary infiltration.
6. Clinical semiology of neoplastic pulmonary infiltration.
7. What are the diagnostic methods to verify the etiology, the nature of pulmonary infiltration.
8. The tactics of management of patients with pneumonic infiltrate.
9. The tactics of management of patients with tumor infiltration.
10. The tactics of management of patients with disseminated pulmonary infiltrate.

MCQ's:

1. The patient aged 58, was admitted to the pulmonary department because of pathological changes revealed at routine chest X-ray. In the past had focal pulmonary tuberculosis, received treatment, 5 years ago had confirmed recovery. No complaints at admission. Chest X-ray: subpleural focus rounded up to 3 cm, with unclear contours in the lower lobe of right lung. Peripheral lung cancer suspected. What instrumental method will verify the diagnosis?
 - A. Bronchoscopy.
 - B. Bronchography.
 - C. Transthoracic needle biopsy.
 - D. X-ray.
 - E. Computed tomography.
2. A 56-year-old patient complains of having persistent chest pain on the right for the last 2 months. The pain is not associated with respiration. He also complains of cough with blood-streaked sputum, weakness, decreased performance, fatigue. Chest radiograph shows a globular shade of 4x6 cm connected to the root of the lung in the lower part of the right lung. What is the most likely diagnosis?
 - A. Lung abscess
 - B. Metastasis
 - C. Peripheral lung cancer
 - D. Pneumonia

E. Tuberculoma

3. Patient complains of progressing weakness, loss of appetite, loss of weight, more than 3 months cough, night sweats, subfebrile temperature. Chest X-ray shows bilateral lesions of the apical and posterior segments of the lungs of various sizes and densities. Above affected segments pleura is visualized. What is the most probable diagnosis?

- A. Cardiac lung.
- B. Pulmonary edema.
- C. Focal tuberculosis.
- D. Peripheral lung cancer.
- E. None of the above.

4. A 54 year old patient complains about pain in the right part of her chest, dyspnea, cough with a lot of foul-smelling albuminoid sputum in form of "meat slops". Objectively: the patient's condition is grave, cyanosis is present, breathing rate is 31/min, percussion sound above the right lung is shortened, auscultation revealed different rales. What is the most probable diagnosis?

- A. Chronic pneumonia
- B. Pleura empyema
- C. Lung abscess
- D. Lung gangrene
- E. Multiple bronchiectasis

5. 48 years old female patient complains of fever up to 39,8 °C, cough with purulent bloody sputum. His condition is grave, cyanosis, apnea, respiratory rate 32 in 1 min .. Heart rate / pulse of 116 in 1 min. In the right lung areas weakened vesicular breathing alternate with those of small bubbling moist rales. Radiological findings: in the right lung background infiltration with multiple thin-walled cavities with a horizontal level is seen. General blood test: leukocytosis, 18 G/L, 19% stab neutrophils, ESR 43 mm / hour. Which of the following diagnoses is most likely?

- A. Pneumococcal pneumonia.
- B. Viral pneumonia.
- C. Staphylococcal pneumonia.
- D. Caseous pneumonia.
- E. Micoplasmic pneumonia.

6. A 41 y.o. female patient is suffering from chemicals-associated COPD. Recently there has been production about 0,5 L of purulent sputum with maximum discharge in the morning. Fingers are like "drum sticks", nails look like "watch glass". What is the most probable diagnosis?

- A. Pneumonia
- B. Bronchiectasia
- C. Chronic bronchitis
- D. Gangrene of lungs
- E. Tuberculosis

7. Patient 30 years old, complains of cough with viscous sputum, shortness of breath, right chest pain when breathing, increased body temperature to 39 - 40 oC. Acutely ill after overcooling. Objective: pale; RR is 28 in 1 min., increased voice trembling and bronchial breathing on auscultation above lower right segments. In general blood: - leukocytosis, stab shift, acceleration of ESR. Radiological findings: infiltrative changes in the lower lobe of right lung. From what drug should etiotropic therapy begin?

- A. Doxycyclin,
- B. Metronidasole.
- C. Amoxicillin.
- D. Gentamicin.
- E. Ciprofloxacin.

8. Patient aged 35, complains of severe pain in his right chest, increasing at the slightest movement. Sick for about a day, after working outside in the cold weather. On examination: decreased right hemithorax movement in the act of breathing, its palpation is painful, especially intercostal spaces on the right; clear percussion sounds, vesicular breath. Body temperature is normal, blood tests, urine tests, X-ray of the chest cavity - without pathology. The most likely diagnosis?

- A. Right-sided dry pleurisy.
 - B. Right-lower lobe pneumonia.
 - C. Right-sided intercostal neuralgia.
 - D. Fracture of 7-th right rib.
 - E. None of the above.
9. A hospital has admitted a 52-year-old patient with disseminated pulmonary tuberculosis, complaints of acute pain in the right half of chest, that developed after going upstairs to the 3rd floor; cough, dyspnea at rest, marked cyanosis. What kind of complication should be suspected first of all?
- A. Spontaneous pneumothorax
 - B. Cardiac failure
 - C. Pulmonary failure
 - D. Pleuritis
 - E. Acute myocardial infarction
10. A patient complains of a tormental (agonizing) cough with expectoration of up to 600 ml/daily purulent chocolatecolor sputum with a decay smell. Onset of illness was abrupt, t - 39°C, fever of irregular type. There is the area of darkening with rough contours and a cavity in a center on X-ray film, with irregular contours and level of liquid. What disease is the question?
- A. Gangrene of lung
 - B. Tuberculosis
 - C. Bronchiectatic illness
 - D. Pneumonia complicated by an abscess
 - E. Lobar pneumonia

Clinical tasks:

Task N 1.

The patient aged 53 years enrolled in the pulmonary section, complaining of marked weakness, constant shortness of breath, cough with a small amount of mucous sputum, increased body temperature.

The above complaints within 1,5 months. Anamnesis: 3 months before right-sided nephrectomy performed in connection with right renal cell carcinoma. No postoperative complications.

OBJECTIVE: state of medium gravity. Malnutrition. Skin pale. Peripheral lymph nodes were not enlarged. NPV 24 in 1 min. Above the Light: percussion - the sound is shortened, auscultation - vesicular breath with hard shade, no wheezing. Heart rate / pulse 90 in 1 min .. BP 110/80 mmHg Heart sounds are muffled. The abdomen is painless, soft, right - the post-operative scar.

The control question:

1. A manifestation of a disease can be reduced klinicheskay situation?
2. What changes could be in the study of a general analysis of blood?
3. Possible changes in the X-ray examination of the chest cavity?
4. The program of examination of the patient?
5. The treatment?
6. Consultations what specialists are needed?

Task № 2.

Patient 35 years, injecting drug users, admitted to hospital with complaints of cough with greenish sputum, shortness of breath during physical activity, expressed sweating, increased body temperature to 38.4 oC. Bolen 6 days, not treated. OBJECTIVE: condition serious. Skin was pale. NPV 26 in 1 min. For percussion on the right lower corner of blades is determined by the shortening of the percussion sounds on auscultation over this area - hard breathing, small bubbling moist rales. Heart rate / pulse 92 in 1 min., BP 90/60 mm.rt.st. Tones of heart muted. Abdomen palpation mild, moderate disease in the right hypochondrium. Liver from the costal arch.

The control question:

1. Formulate a preliminary diagnosis. "
2. What changes can be detected with X-ray examination of the chest cavity?
3. The development of any possible complications in this case?

4. Survey Programme, taking into account the basic pathology and the possible complications?
5. Antibacterial therapy?

Task № 3.

Patient 54 years, 25 years addicted to alcohol. Acutely ill: body temperature rose to 39 ° C, there was a cough with viscous sputum with an unpleasant smell. OBJECTIVE: in a serious condition. Patient retarded. Skin wet with cyanotic hue. RR 28 in 1 min. The right half of the chest behind when breathing. Below the clavicle on the right there is a growing voice tremor, dullness of percussion sound, breath and bronchial tint slim crackling. Left on the background of pulmonary percussion sound attenuation vesicular breathing, single scattered dry rales. Heart rate / pulse 96 in 1 min., BP 95/55 mmHg Heart sounds are muffled. The abdomen is increased in volume, jutting belly. Palpation of liver failed.

The control question:

1. Formulate a preliminary diagnosis.
2. What causes gravity condition bolnogo?
3. What is the most likely etiology of pulmonary pathology?
4. Describe the X-ray picture of pulmonary pathology.
5. Possible complications of pulmonary pathology.
6. With what may be involved in causing stomach?
7. The program of examination of the patient.
8. The program of treatment.

Summary:

Recommended reading list

Basic literature:

- Harrison's Principles of Internal Medicine Self-Assessment and Board Review, 20th Edition 20th Edition.- (August 13, 2021). - 736 pages
- Pocket Medicine: The Massachusetts General Hospital Handbook of Internal Medicine / 007 edition (12 Sept. 2019). - 272 pages
- Davidson's Principles and Practice of Medicine: Enhanced Digital Version Included / Elsevier; 23rd edition (25 April 2018). - 1440 pages

Additional literature:

- Macleod's Clinical Examination /Elsevier; 14th edition (11 Jun. 2018). - 400 pages
- Current Medical Diagnosis and Treatment /McGraw-Hill Education; Updated edition (14 Sept. 2021). - 1840 pages
- Lippincott Connect Standalone Courseware for Bates' Guide to Physical Examination and History Taking 1.0 /LWW; 13th ed. edition (23 Mar. 2023).
- Step-Up to Medicine / Wolters Kluwer Health; 5th edition (8 May 2019). - 582 pages
- Goldman-Cecil Medicine, 2-Volume Set (Cecil Textbook of Medicine) / Elsevier; 26th edition (20 Dec. 2019). - 2944 pages
- The Washington Manual of Medical Therapeutics / Wolters Kluwer Health; 36th edition (6 Jun. 2019). - 1074 pages
- Harrison's Manual of Medicine / McGraw-Hill Education; 20th edition (5 Nov. 2019). - 1245 pages

Electronic information resources

- World Health Organization. URL: www.who.int/ru/index.html.
- European Regional Office of the World Health Organization. URL: www.euro.who.int.
- <https://www.aasld.org/>
- https://academic.oup.com/ndt/pages/General_Instruction
- <https://cprguidelines.eu/>
- <https://www.escardio.org/Guidelines/Clinical-Practice-Guidelines>
- <http://www.oxfordmedicaleducation.com/>
- <http://ard.bmj.com>
- <https://www.escardio.org/Guidelines/Clinical-Practice-Guidelines>

Practical class

Topic 15. Management of a patient with community-acquired pneumonia. Management of a patient with hospital-acquired pneumonia.

The main goals: to acquire communication skills and skills of clinical examination of a patient with hospital and non-hospital pneumonia; be able to establish a preliminary diagnosis, carry out a differential diagnosis and determine the clinical diagnosis of the disease in a patient with hospital and non-hospital pneumonia; master the principles of treatment, recommendations for lifestyle changes in the management of patients with hospital and non-hospital pneumonia; diagnose emergency conditions in patients with hospital-acquired and community-acquired pneumonia; master the tactics of providing emergency medical care to patients with hospital and non-hospital pneumonia; to be able to perform therapeutic manipulations in patients with hospital and non-hospital pneumonia.

Key words: etiological agents of non-hospital and hospital-acquired pneumonia, lung abscess; modern classification of pneumonia and lung abscess; clinical manifestations and features of the course of hospital and non-hospital pneumonia, lung abscess; differential diagnosis of hospital-acquired and non-hospital-acquired pneumonia, as well as other conditions accompanied by the syndrome of compaction of lung tissue; the main research methods that confirm the diagnosis of pneumonia, lung abscess: Rg-graphy OGK, CT, spiral CT, macro- and microscopic examination of sputum, culture of sputum, etc.; tactics of managing patients with community-acquired pneumonia depending on the category. The main groups of antibiotics that are used in different degrees of severity. Principles of differential treatment. Indications for transferring patients to the intensive care unit; treatment of hospital-acquired pneumonia depending on the possible causative agent or its association. Antibiotic therapy of hospital pneumonia. Indications for transferring patients to the intensive care unit; treatment of acute and chronic lung abscess. Indications for operative treatment; primary and secondary prevention of pneumonia and lung abscess.

Equipment: multimedia materials - a set of thematic slides from the department's multimedia library; screenshots of the results of instrumental and laboratory tests (ECG, CT scan, ultrasonograms); a set of situational problems on the topic of the lesson; a set of radiographs, a negatoscope; electronic versions of radiographs.

Plan:

- Organizational measures (greetings, verification of those present, announcement of the topic, purpose of the lesson, motivation of higher education seekers to study the topic)
- Control of the reference level of knowledge (checking homework, written work, written testing, including writing KROK-2 tests, frontal survey)
- Formation of professional abilities and skills (mastery of skills, curation, determination of treatment regimen, laboratory research, etc.): discussion of features of diagnosis and treatment of arterial hypertension, the most common clinical manifestations, criteria for establishing a diagnosis
- Summing up (summarizing the topic, evaluating applicants, discussing the next lesson topic and homework) .

The control question:

1. Definition, classification (category, severity) of community-acquired pneumonia.
2. Causative agents of community-acquired pneumonia.
3. Clinical semiology of pneumonia.
4. Laboratory criteria for pneumonia
5. Radiographic criteria for pneumonia.
6. Criteria for severe community-acquired pneumonia.
7. Empirical therapy of community acquired pneumonia. The concept of stepwise therapy with antibiotics.
8. Pathogenetic therapy of pneumonia.

9. Complications of pneumonia.

10. The criteria for the effectiveness of treatment of community acquired pneumonia. Duration of antibiotic therapy.

11. Clinical examination.

MCQ's:

1. A 26-year-old patient with left lower lobe pneumonia experiences an acute chest pain on the left during coughing. Objectively: diffuse cyanosis, extension of the left side of chest. Percussion reveals high tympanitis. Auscultation reveals no respiratory murmurs above the left side of chest. There is a deviation of the right cardiac border towards the midclavicular line. What complication did the patient develop?

- A. Dry pleurisy
- B. Pneumothorax
- C. Hydrothorax
- D. Asphyxia
- E. Acute right-ventricular failure

2. A 43 years-old male called a doctor because of body temperature of 40 ° C with chills, cough, accompanied by pain in the right chest side. Sick 2 days after hypothermia at work. Objective: skin is pale, herpetic eruptions on his upper lip. The right half of the chest moves less when breathing. Auscultation: left - vesicular breathing, right - a crackling background vesicle-bronchial breath. Which of the additional methods of examination is the most informative for diagnosis?

- A. Spirography.
- B. Peak flowmetry.
- C. Complete blood count.
- D. X-ray of the chest cavity.
- E. The general analysis of sputum.

3. A 29 y.o. man was discharged from the hospital after having an out-of -hospital pneumonia. He has no complaints. On physical exam: his temperature is 36,6°C, RR-18/min, Ps - 78 bpm, BP - 120/80 mm Hg. During auscultation there is harsh respiration to the right of the lower part of the lung. Chest X-ray: infiltrative changes are absent, intensification of the pulmonary picture to the right in the lower lobe. How long should the doctor keep the patient under ambulatory observation?

- A. 12 months
- B. 1 month
- C. 3 months
- D. 6 months
- E. Permanently

4. The patient has a diagnosis of community acquired pneumonia on the basis of clinical, radiological findings. Patient lives in a dormitory. The disease debuted with pharyngitis, enlarged lymph nodes, hepatosplenomegaly. Which of the following infectious agent is most likely causing pulmonary disease?

- A. Streptococcus pneumonia.
- B. Gram (-) bacilli.
- C. Mycoplasma pneumonia.
- D. None of the above.
- E. Any of the above.

5. A 30 years old male was hospitalized because of pneumonia. Acutely ill after cold exposure. The clinical picture includes high fever, pain syndrome, intoxication, cough. Radiological examination revealed infiltration of the entire lower lobe of right lung involving the pleura. Indicate the most likely causative agent.

- A. Staphylococcus.
- B. Klebsiela.
- C. Streptococcus.
- D. Pseudomonas aeruginosa.
- E. Streptococcus pneumoniae.

6. 4 days ago a 32-year-old patient caught a cold: he presented with sore throat, fatigue. The next morning he felt worse, developed dry cough, body temperature rose up to 38,2°C, muco-purulent expectoration appeared. Percussion revealed vesicular resonance over lungs, vesicular breathing weakened below the angle of the right scapula, fine sonorous and sibilant wheezes. What is the most likely diagnosis?

- A. Focal right-sided pneumonia
- B. Bronchial asthma
- C. Acute bronchitis
- D. Pulmonary carcinoma
- E. Pulmonary gangrene

7. The patient 30 years was diagnosed of community-acquired pneumonia with typical course of the disease. After 5 days of treatment with amoxycillin 1,0 g daily symptoms persist: high fever, leukocytosis in blood, according to chest X-ray - increased focus of infiltration. In this situation we should:

- A. Continue treatment with amoxycillin in the previous dose.
- B. Increase the dose of amoxycillin.
- C. Replace amoxycillin with fluoroquinolone of III- IV generation
- D. Add sulfanilamide preparations to amoxycillin.
- E. Choose different macrolide antibiotic

8. A 54 y.o. male patient suffers from dyspnea during mild physical exertion, cough with sputum which is excreted with difficulty. On examination: diffuse cyanosis. Chest is barrel-shaped. Weakened vesicular breathing with prolonged expiration and dry whistling rales. AP is 140/80 mm Hg, pulse is 92 bpm, rhythmic. Spirography: vital capacity (VC)/predicted vital capacity- 65%, FEV1/FVC – 50%. Determine the type of respiratory insufficiency (RI).

- A. RI of mixed type with prevailing obstruction
- B. RI of restrictive type
- C. RI of obstructive type
- D. RI of mixed type with prevailing restriction
- E. There is no RI

9. A 40-year-old patient has acute onset of disease caused by overexposure to cold. Temperature has increased up to 39°C. Foul-smelling sputum is expectorated during coughing. Various moist crackles can be auscultated above the 3rd segment on the right. Blood test: leukocytes - $15,0 \cdot 10^9/l$, stab neutrophils - 12%, ESR- 52 mm/hour. On Xray: in the 3rd segment on the right there is a focus of shadow 3 cm in diameter, low density, with fuzzy smooth margins and a clearing in its center. What disease is most likely in the given case?

- A. Pneumonia complicated by an abscess
- B. Infiltrative tuberculosis
- C. Peripheral pulmonary cancer
- D. Cystic echinococcosis
- E. Pulmonary cyst

10. A 24-year-old patient is a clerk. His working day runs in a conditioned room. In summer he was taken by an acute disease with the following symptoms: fever, dyspnea, dry cough, pleural pain, myalgia, arthralgia. Objectively: moist rales on the right, pleural friction rub. X-ray picture showed infiltration of the inferior lobe. In blood: WBC - $11 \times 10^9/l$, stab neutrophils - 6%, segmented neutrophils

– 70%, lymphocytes - 8%, ESR - 42 mm/h. What is the ethiological factor of pneumonia?

- A. Legionella
- B. Mycoplasma
- C. Streptococcus
- D. Staphylococcus
- E. Pneumococcus

Clinical Tasks

Task № 1.

The patient was 69 years old male, taken to hospital in serious condition with complaints of severe

weakness, shortness of breath, heaviness in chest, cough. The case history: 10 years worried about heart pain when walking, 3 years ago suffered a myocardial infarction. The deterioration occurred 5 days ago, when after hypothermia appeared chills, fever up to 39 °C, pains in the chest, a little dry cough. He took bisepitol. After 2 days the temperature returned to normal. However, left chest pain when breathing and pain behind the sternum, accruing dyspnea and cough with scanty sputum. In the day of admission developed choking, a feeling of compression of the sternum, bubbling breath. With suspected myocardial infarction hospitalized. **OBJECTIVE:** condition is unsatisfactory, pronounced lips cyanosis. RR 40 in 1 min. physical examination reveals bronchial breath sound, dull percussion sound with crackles above upper area right lung field. Above lower part of left lung present decreased breath sound and moist rales. Heart rate / pulse of 112 in 1 min. BP 75/50 mmHg. Liver 3 cm below the costal arch. Blood analysis: hemoglobin 140g / l, leukocytes 3.0 G / l, eosinophils, 0%, band - 2%, stab - 12%, segmentolnuclear - 67%, lymphocytes - 15%, monocytes - 4%. In neutrophils of toxic grain.

The control question:

1. Describe syndromes in the clinical picture.
2. Justify the preliminary diagnosis.
3. What do you expect to get X-ray examination?
4. The reason for the development and nature of asthma, developed a patient?
5. Full screening program.
6. To which category can be classified as pneumonia in the case of detection?
7. The treatment program.

Task№ 2.

The patient was 20 years. If you receive complaints about painful, "sore" cough accompanied by chest pain, weakness, lioitu throughout the body, raising the temperature. Sick for 6 days. The onset of illness accompanied by fever up to 37.8 - 38 °C, pain in muscles, headache, runny nose, burning sensation in the eyes. On the second day of cough. GP diagnosed SARS, has appointed paracetamol drops of cold, cough medicine. However, the condition did not improve, continued fever, accruing weakness, cough intensified. On examination: skin pale, warm and moist. Sclera injected. Thorax uniformly involved in breathing. Percussion: right down the angle of blade sounds with tympanic shade. Auscultation here weakened vesicular breathing, dry rales. From other bodies in the physical examination revealed no significant deviations.

The control question:

1. How do you evaluate the available changes in the lungs
2. Estimates the diagnosis.
3. Most probable etiological factor in pulmonary pathology.
4. Examination plan.
5. Treatment program.

Task№3.

A 62 years old man was admitted to the surgical department with the diagnosis: acute cholecystitis with complaints of pain in the right half of the abdomen, especially during deep breathing, shortness of breath, coughing, chilling. Ill on the eve of yesterday evening, after the feast. He felt pain in the right hypochondrium, nausea, vomiting once was. The morning temperature 38.1

In the past, considered himself healthy. **OBJECTIVE:** patient euphoric, feverish eyes. The body temperature of 39 °C. RR 36 in 1 min., With the wings of the nose. Percussion of the left lung reveals pulmonary bandbox sound, right below the angle of scapula - blunting. Auscultation on the left - no features on the right - relaxed vesicular breathing, moist small bubbling rales. Pulse arrhythmic, 90 in 1 min. BP 110/60 mmHg. The heart is increased in diameter. Arrhythmic heart activity, faint tones, above the aorta auscultated systolic murmur. Positive symptom Sirotinin-Kukoverova. The abdomen is moderately distended, defined muscle tension in the right hypochondrium. In the analysis of blood: hemoglobin 132 g / l, erythrocyte - 4,3 T / l, WBC - 17.6 G / l, a shift in leucocyte count to the left, ESR - 8 mm / hour. X-ray of the chest cavity: right lower lobe of right lung - reducing the transparency of lung tissue. The heart is increased at the expense of the left ventricle. The aorta is sealed, is deployed.

The control question:

1. Select syndromes in the clinical picture.
2. What are the symptoms of Sirotinin-Kukoverov?
4. What are the physical examination will reject the diagnosis of acute cholecystitis.
5. Where the patient should be treated?
6. The program of treatment of pulmonary pathology.
7. The treatment program of cardiovascular pathology.

Summary:**Recommended reading list****Basic literature:**

- Harrison's Principles of Internal Medicine Self-Assessment and Board Review, 20th Edition 20th Edition.- (August 13, 2021). - 736 pages
- Pocket Medicine: The Massachusetts General Hospital Handbook of Internal Medicine / 007 edition (12 Sept. 2019). - 272 pages
- Davidson's Principles and Practice of Medicine: Enhanced Digital Version Included / Elsevier; 23rd edition (25 April 2018). - 1440 pages

Additional literature:

- Macleod's Clinical Examination /Elsevier; 14th edition (11 Jun. 2018). - 400 pages
- Current Medical Diagnosis and Treatment /McGraw-Hill Education; Updated edition (14 Sept. 2021). - 1840 pages
- Lippincott Connect Standalone Courseware for Bates' Guide to Physical Examination and History Taking 1.0 /LWW; 13th ed. edition (23 Mar. 2023).
- Step-Up to Medicine / Wolters Kluwer Health; 5th edition (8 May 2019). - 582 pages
- Goldman-Cecil Medicine, 2-Volume Set (Cecil Textbook of Medicine) / Elsevier; 26th edition (20 Dec. 2019). - 2944 pages
- The Washington Manual of Medical Therapeutics / Wolters Kluwer Health; 36th edition (6 Jun. 2019). - 1074 pages
- Harrison's Manual of Medicine / McGraw-Hill Education; 20th edition (5 Nov. 2019). - 1245 pages

Electronic information resources

- World Health Organization. URL: www.who.int/ru/index.html.
- European Regional Office of the World Health Organization. URL: www.euro.who.int.
- <https://www.aasld.org/>
- https://academic.oup.com/ndt/pages/General_Instruction
- <https://cprguidelines.eu/>
- <https://www.escardio.org/Guidelines/Clinical-Practice-Guidelines>
- <http://www.oxfordmedicaleducation.com/>
- <http://ard.bmj.com>
- <https://www.escardio.org/Guidelines/Clinical-Practice-Guidelines>

Practical class**Topic 16. Management of a patient with hemoptysis. Management of a patient with respiratory failure.**

The main goals: to acquire communication skills and clinical examination skills of a patient with hemoptysis and chronic cough; be able to establish a preliminary diagnosis, carry out a differential diagnosis and determine the clinical diagnosis of the disease in a patient with hemoptysis and chronic cough; master the principles of treatment, recommendations for lifestyle changes in the management of patients with hemoptysis and chronic cough; diagnose emergency conditions in patients with hemoptysis and chronic cough; master the tactics of providing emergency medical care to patients with hemoptysis and chronic cough; to be able to perform therapeutic manipulations in patients with hemoptysis and chronic cough.

Key words: definition of the concept; differences in hemoptysis, pulmonary bleeding, bleeding from the upper respiratory tract; etiology of bleeding from the respiratory tract; clinic of bleeding from the respiratory tract; differential signs of pulmonary bleeding and bloody vomiting; features of hemoptysis with various causes of its occurrence; diagnosis of pulmonary bleeding; tactics of managing a patient with pulmonary bleeding; hemostatic therapy (medicated and non-medicated) for pulmonary bleeding.

Equipment: multimedia materials - a set of thematic slides from the department's multimedia library; screenshots of the results of instrumental and laboratory tests (ECG, CT scan, ultrasonograms); a set of situational problems on the topic of the lesson; a set of radiographs, a negatoscope; electronic versions of radiographs.

Plan:

- Organizational measures (greetings, verification of those present, announcement of the topic, purpose of the lesson, motivation of higher education seekers to study the topic)
- Control of the reference level of knowledge (checking homework, written work, written testing, including writing KROK-2 tests, frontal survey)
- Formation of professional abilities and skills (mastery of skills, curation, determination of treatment regimen, laboratory research, etc.): discussion of features of diagnosis and treatment of arterial hypertension, the most common clinical manifestations, criteria for establishing a diagnosis
- Summing up (summarizing the topic, evaluating applicants, discussing the next lesson topic and homework) .

The control question:

1. Definition of acute, subacute, chronic cough.
2. Etiology of chronic cough (common and uncommon).
3. History and exam, diagnostic investigation for patients with chronic cough.
4. Differential diagnosis of chronic cough.
5. Assessment of chronic cough, urgent considerations.
6. Definition of hemoptysis, massive hemoptysis.
7. Etiology and pathogenetic mechanisms of bleeding from the respiratory tract.
8. Clinical features of hemoptysis.
9. Differential diagnosis of hemoptysis.
10. The program of examination for patients with hemoptysis.
11. Tactics of treatment of patient with hemoptysis. Urgent considerations.

MCQ's

1. A male patient, long-time smoker, admitted to hospital with persistent cough and hemoptysis. The X- ray of lungs: the upper lobe of right lung not clearly visualized. Right lung root enlarged. Lung CT: Solid mass in upper right segments, enlargement of paraaortic and paratracheal lymph nodes. Most possible diagnosis:

- A. Right upper lobe pneumonia.
- B. Tuberculosis of the lungs.
- C. Right upper lobe peripheral cancer.
- D. Bronchiectasis.
- E. Right pulmonary artery embolism.

2. A 48 years old patient complains of acute chest pain with hemoptysis, shortness of breath during slight physical exertion, general weakness. In history: deep lower extremities vein thrombophlebitis. Objective: diffusely cyanotic skin, swelling of the jugular veins. RR 34 in 1 min. Percussion: dull sound above right lung. HR 120 in 1 min., BP - 100/60 mmHg Auscultation: gallop rhythm, tones are muted, S2 accentuation above pulmonary artery. Liver +3 cm from under the costal arch, painful at palpation. What is a preliminary diagnosis.

- A. Lobar pneumonia.
- B. Exudative pleurisy.
- C. Infective myocarditis.

D. Pulmonary embolism.

E. Myocardial infarction.

3. A 62 years old patient was admitted to the hospital because of acute myocardial infarction. On the third day of MI suddenly developed dyspnea, diffuse cyanosis, cold sticky sweat, collapse. Pulse rapid, thread-like. In the next hours developed hemoptysis with foamy blood. What diagnosis should you think about?

A. Recurrent myocardial infarction.

B. Aneurysm of the heart.

C. Intercostal neuralgia.

D. Cardiac asthma.

E. Nosocomial pneumonia.

4. A 35 y.o. woman was admitted to thoracic surgery department with fever up to 40°C, onset of pain in the side caused by deep breathing, cough with considerable quantity of purulent sputum and blood with bad smell. What is the most likely diagnosis?

A. Pulmonary tuberculosis

B. Abscess of the lung

C. Bronchiectatic disease

D. Complication of liver echinococcosis

E. Actinomycosis of lungs

5. A 60 years old man with 3 months history of dry cough in the morning, noticed increasing shortness of breath, and sometimes hemoptysis, loss of weight, voice hoarseness. Chest X-ray: heterogenous darkening with indistinct contours in basal segments of the right lung with a deep strands penetrating into the surrounding tissue. What should you think about?

A. Focal pneumonia.

B. Tuberculosis of the lungs.

C. Lobar pneumonia.

D. Lung cancer.

E. Aspergilloma.

6. A patient was admitted to hospital with a productive cough, hemoptysis, general weakness, poor appetite, night sweats. The preliminary diagnosis of infiltrative pulmonary tuberculosis was put. Which test should be ordered to confirm the diagnosis?

A. Analysis of sputum for the mycobacteria, chest X-ray.

B. Transbronchial lung biopsy.

C. Blood biochemistry (acute phase indicators).

D. Bronchography.

E. Mantoux test with 2 TU.

7. A 55 years old man admitted to the hospital with pain in the right half of the chest, shortness of breath, coughing up blood. He suffers from coronary heart disease, three weeks ago had an operation because of left shin deep vein thrombosis. According the complaints mentioned above, what is the most likely diagnosis?

A. Community-acquired right-sided pleuropneumonia.

B. Thromboembolism of the pulmonary artery branches.

C. Strangulated diaphragmatic hernia.

D. Perforation of the lung abscess in the pleural cavity.

E. None of the above.

8. A 63 years old man was admitted to hospital with symptoms of hemoptysis. Which test should be ordered first?

A. Radiography of the chest.

B. Pleural puncture.

C. Bronchoscopy,

D. ECG.

E. CT of the chest.

9. A female of 37 years old with 8 years history of bronchial asthma that was treated irregularly. During a strong unproductive cough, felt a sharp pain in the chest on the right, dizziness. Taken to

hospital. Objective: condition is grave, slight cyanosis. RR 32 per 1 min., Heart rate / pulse of 110 in 1 min., BP 80/40 mmHg. Percussion over the right lung - tympanic sound. In ECG the inversion of the T wave in V1 - V3, ST-segment depression in II, III, aVF. Which of the following is the most likely diagnosis:

- A. Acute myocardial infarction.
- B. Spontaneous pneumothorax.
- C. Embolism of pulmonary artery branches.
- D. Asthmatic status.
- E. Acute adrenal insufficiency.

10. A man was admitted to hospital with complaints of severe retrosternal pain, hemoptysis, hectic fever. The examination revealed manifestations of acute thrombophlebitis of subcutaneous veins of the left tibia. Which of the following is the primary method in verifying a diagnosis?

- A. Ultrasound of the lower extremities vessels.
- B. Bronchoscopy.
- C. Radiography of the chest cavity.
- D. Phlebography.
- E. Chest CT with contrast

Clinical Tasks:

Task № 1.

A 65 years old man was admitted to reception office with complaints of bloody sputum expectorations during cough. Other complaints. Bleeding started 40 min. Back after the physical work associated with lifting heavy objects. The patients themselves did not consider. The patient - pneumonia 15 years ago. 40 years ago took part in the fighting, was wounded in the thigh, forearm, chest (the blind wound).

OBJECTIVE: pale skin, sweating. RR 22 in 1 min .. Above the Light: percussion - a clear lung sounds on auscultation - vesicular breath, right in the lower part of moist rales. Heart rate / pulse of 98 to 1 min., BP 130/80 mm. Hg. Heart sounds are muffled, rhythmic. The abdomen was soft painless. Liver and spleen were not palpable. Radiography of the chest cavity revealed an intense shade dimensions 0,5 x 1,5 cm in the middle lobe of right lung. I'll remember that back in the hospital, where he was treated at the wound, he talked about the fragment. For 40 years he had not bothered.

The control question:

1. What is the possible cause of pulmonary haemorrhage?
2. Why is the blood comes out when you cough?
3. Formulate a preliminary diagnosis
4. What kind of investigation you must do?
5. Criteria for severity of bleeding?
6. In which department should be patient?
7. The program of emergency pulmonary hemorrhage.

Task № 2. Male 46 years old, was admitted a hospital with complaints of shortness of breath, pain in his right side during the past two days. This morning when he has cough with foamy blood sputum. 10 years ago, was treated at the fibro-cavernous pulmonary tuberculosis.

OBJECTIVE: asthenic body and cyanosis of the face and upper third of the chest, swelling of the jugular veins, sweating. RR 24 in 1 min. Over light percussion - lung sound auscultation - breathing hard, diffuse dry rales, right over the top wet rales. Heart rate / pulse 88 in 1 min., BP 150/85 mm. RT. Art .. Heart sounds are rhythmic, muffled, accentuation 2nd sound above pulmonary artery. Stomach, painless at palpation, the liver 1 cm appears from under the rib region.

The control question:

1. Formulate a preliminary diagnosis.
2. What is the cause of bleeding in this case?
3. What are the signs of bleeding in this case indicates pulmonary origin?
4. What does cyanotic skin mean, swelling of the neck veins, the accentuation 2nd sound above pulmonary point?
5. What do you expect to find in the ECG study?

6. What research is needed to determine the degree of blood lost ?
7. Programme hemostatic therapy.

Task № 3. The patient aged 42, was admitted to the clinic with complaints of cough with expectoration of sputum with blood. In the last 2 - 3 months worried about weakness, fatigue by the end of the day. Temperature was not increased. Lost 4 kg .. Became concerned about a dry cough. On the day of receipt of pains in the chest on the left and blood clots in the sputum when coughing. Complaints from the gastrointestinal tract was not. Thrombophlebitis did not suffer. On examination: pale skin. On the left supraclavicular of neck presents the detectable dense painless mass. RR 28 in 1 min .. In light percussion on the left behind at the lower third of the blade at the spine - dullness of percussion sounds on auscultation are the same area present bronchial breathing. Pulse 100 in 1 min., Rhythmical. BP 145/78 mm. Heart sounds are clear. The abdomen was soft, painless, liver and spleen were not enlarged.

The control question:

1. Formulate a clinical diagnosis.
2. What is the diagnostic value of the node in the supraclavicular region to the left?
3. What does the bronchial tone of breath and what changes in vocal resonance should be suited for him?
4. The program of examination of the patient.
5. Consultations what specialists are needed?
6. The treatment program. Hemostatic therapy.

Summary:

Recommended reading list

Basic literature:

- Harrison's Principles of Internal Medicine Self-Assessment and Board Review, 20th Edition 20th Edition.- (August 13, 2021). - 736 pages
- Pocket Medicine: The Massachusetts General Hospital Handbook of Internal Medicine / 007 edition (12 Sept. 2019). - 272 pages
- Davidson's Principles and Practice of Medicine: Enhanced Digital Version Included / Elsevier; 23rd edition (25 April 2018). - 1440 pages

Additional literature:

- Macleod's Clinical Examination /Elsevier; 14th edition (11 Jun. 2018). - 400 pages
- Current Medical Diagnosis and Treatment /McGraw-Hill Education; Updated edition (14 Sept. 2021). - 1840 pages
- Lippincott Connect Standalone Courseware for Bates' Guide to Physical Examination and History Taking 1.0 /LWW; 13th ed. edition (23 Mar. 2023).
- Step-Up to Medicine / Wolters Kluwer Health; 5th edition (8 May 2019). - 582 pages
- Goldman-Cecil Medicine, 2-Volume Set (Cecil Textbook of Medicine) / Elsevier; 26th edition (20 Dec. 2019). - 2944 pages
- The Washington Manual of Medical Therapeutics / Wolters Kluwer Health; 36th edition (6 Jun. 2019). - 1074 pages
- Harrison's Manual of Medicine / McGraw-Hill Education; 20th edition (5 Nov. 2019). - 1245 pages

Electronic information resources

- World Health Organization. URL: www.who.int/ru/index.html.
- European Regional Office of the World Health Organization. URL: www.euro.who.int.
- <https://www.aasld.org/>
- https://academic.oup.com/ndt/pages/General_Instruction
- <https://cprguidelines.eu/>
- <https://www.escardio.org/Guidelines/Clinical-Practice-Guidelines>
- <http://www.oxfordmedicaleducation.com/>
- <http://ard.bmj.com>
- <https://www.escardio.org/Guidelines/Clinical-Practice-Guidelines>

Practical class

Topic 17. Management of a patient with fever of unknown origin. Damage to organs and systems during HIV infection.

The main goals: to acquire communication skills and skills of clinical examination of a patient with fever of unknown origin, damage to organs and systems due to HIV infection; be able to establish a preliminary diagnosis, carry out a differential diagnosis and determine the clinical diagnosis of the disease in a patient with fever of unknown origin, damage to organs and systems in HIV infection; master the principles of treatment, recommendations for lifestyle changes in the management of patients with fever of unknown origin, damage to organs and systems in HIV infection; to diagnose emergency conditions in patients with fever of unknown origin, damage to organs and systems due to HIV infection; master the tactics of providing emergency medical care to patients with fever of unknown origin, damage to organs and systems in HIV infection; to be able to perform therapeutic manipulations in patients with fever of unknown origin, damage to organs and systems due to HIV infection.

Key words: etiology, pathogenesis and pathomorphology of HIV infection; clinical classification of HIV infection and AIDS: nature of the course, stages, clinical and morphological characteristics of the lesion; clinical manifestations of HIV infection and AIDS depending on the course and stage of the disease; diagnostic significance of additional research methods (general clinical, biochemical, instrumental); diagnostic criteria for HIV infection and AIDS; principles of treatment of HIV infection and AIDS, groups of drugs used and tactics of their use.

Equipment: multimedia materials - a set of thematic slides from the department's multimedia library; screenshots of the results of instrumental and laboratory studies (Rg-graphy of OGK, CT, spiral CT, macro- and microscopic examination of sputum, culture of sputum, spirograms, ultrasonograms); a set of situational problems on the topic of the lesson; a set of radiographs, a negatoscope; electronic versions of radiographs.

Plan:

1. Organizational measures (greetings, verification of those present, announcement of the topic, purpose of the lesson, motivation of higher education seekers to study the topic)
2. Control of the reference level of knowledge (checking homework, written work, written testing, including writing KROK-2 tests, frontal survey)
3. Formation of professional abilities and skills (mastery of skills, curation, determination of treatment regimen, laboratory research, etc.): discussion of features of diagnosis and treatment of arterial hypertension, the most common clinical manifestations, criteria for establishing a diagnosis
4. Summing up (summarizing the topic, evaluating applicants, discussing the next lesson topic and homework).

Questions:

1. Definitions of FUO.
2. Degrees, types of fever.
3. Terms of measuring body temperature.
4. Infectious diseases as a cause of FUO.
5. Malignant neoplasms as a cause of FUO.
6. Autoimmune diseases as a cause of FUO.
7. Iatrogenous FUO.
8. Other causes of FUO.
9. General examination in FUO
10. Further examination (if indicated) for FUO.
11. Indications for symptomatic drug therapy.

1. A 17 y.o. patient complains of headache, mainly in the frontal and temporal areas, superciliary arch, appearing of vomiting at the peak of headache, pain during the eyeballs movement, joint's pain. On examination: excited, $t^{\circ} - 39.5^{\circ}\text{C}$, Ps - 110/min. Tonic and clonus cramps. Uncertain meningeal signs. What is the most likely diagnosis?

- A. Parainfluenza
- B. Influenza, typical disease duration
- C. Respiratory syncytial virus
- D. Influenza with cerebral edema manifestations
- E. Adenovirus infection

2. A 48 years old driver was admitted to the hospital with complaints of periodic headache, chilling, raising the temperature to 37.5°C within two years after acute respiratory infection. Objective: temperature body 37°C , heart rate / pulse 78 in 1 min., BP 140/90 mmHg. The internal organs reveal no changes. In general blood: hemoglobin 140 g/L, erythrocytes 4.6 T/L, leukocytes 8.4 G/L, ESR 18 mm/h. Urinalysis: density 1,010, protein: 0,033 g/L, leukocytes 10 - 12 in the vis.field., erythrocytes 1 - 2 in the vis.field., a lot of bacteria. Chronic pyelonephritis was suspected. What's most early and permanent feature of chronic pyelonephritis?

- A. Reduction of urine density.
- B. Proteinuria.
- C. Pyuria.
- D. Bacteriuria.
- E. Prolonged fever.

3. What's the most informative study to confirm the diagnosis of chronic pyelonephritis?

- A. Analysis of urine by Zimnitskiy.
- B. Determination of glomerular filtration rate.
- C. Determination of creatinine in serum.
- D. Determination of bacteriuria.
- E. Overview ultrasound of the kidneys.

4. A 20-years-old college student presents with resistant fever, polyarthritis, weight loss, brittle nails and hair loss. He has nephritis. He was treated with NSAIDs but still doesn't feel well. According to the findings above, what is your preliminary diagnosis?

- A. Rheumatism.
- B. SLE.
- C. Dermatomyositis
- D. Sepsis.
- E. Lymphogranulomatosis.

5. Patient, 32 years, presents to the Emergency Department with one month history of weakness, fatigue, pain, swelling of joints, bitterness in the mouth, feeling of heaviness in the epigastric region, increased body temperature to 38°C . He reports that all these symptoms appeared one and a half months after injectable drugs abuse. On examination: liver and spleen protrude from the hypochondrium for 3 cm. Increased peripheral lymph nodes. What preliminary diagnosis is most likely?

- A. Acute viral hepatitis A.
- B. HIV - infection.
- C. Acute viral hepatitis B.
- D. Reactive polyarthritis.
- E. Acute viral hepatitis C + HIV infection.

6. What disease you suspect in a patient 60 years with symptoms of dysuria, periodic prolonged fever, pain in the lumbar region and the absence of nephrotic syndrome?

- A. Prostatic hypertrophy.
- B. Chronic glomerulonephritis.
- C. Urolithiasis.
- D. Cystitis.
- E. Pyelonephritis.

7. Patient 27 years old, complains of fatigue, heaviness in the left hypochondrium, increased body

temperature. About a year ago neutrophilic leukocytosis without clinical manifestation was found in routine general blood test. Complete blood count: hemoglobin 116 g/L, erythrocytes 3,8 T/L, CI 0,9, WBC 12,5 G/L, basophils 7%, eosinophils 10%, promyelocytes 1%, myelocytes 24%, Metamyelocytes 22%, 14% stab, segmentolnuclear 14%, lymphocytes 8%, ESR 10 mm/hour. What preliminary diagnosis is most likely?

- A. Chronic myeloid leukemia
- B. Lymphogranulomatosis.
- C. Acute leukemia.
- D. Multiple myeloma.
- E. Erythremia.

8. HIV displays the highest tropism towards the following blood cells:

- A. T-killers
- B. T-suppressors
- C. T-helpers
- D. Thrombocytes
- E. Erythrocytes

9. A 20 years old female arrived to Emergency Department because of rash on the face, pain in the joints of hands and feet, febrile temperature during the last month. She reports that these symptoms appeared after holiday tanning on the beach. Objectively: Erythema in the cheek and back of the nose, deformation of knee, ankle and radio carpal joints due to their edema. Heart sounds are muffled. The abdomen is painless. Which of the following criteria is most characteristic of this disease?

- A. Alopecia.
- B. Raynaud's phenomenon.
- C. Anemia.
- D. A high titer of antibodies to native DNA.
- E. None of the above.

10. A 20-year-old worker's medical examination revealed generalized lymphadenopathy mainly affecting the posterior cervical, axillary and ulnar lymph nodes. There are multiple injection marks on the elbow bend skin. The man denies taking drugs, the presence of injection marks ascribes to influenza treatment. Blood count: RBCs - $3,3 \cdot 10^{12}/l$, Hb - 104 g/l, WBCs - $3,1 \cdot 10^9/l$, moderate lymphopenia. What study is required in the first place?

- A. Immunogram
- B. ELISA for HIV
- C. Sternal puncture
- D. X-ray of lungs
- E. Lymph node biopsy

Clinical Tasks

Tasks № 1.

The patient was 50 years old, the seller with past history of hypertension during 7 years. Repeatedly was on sick leave about hypertension II stage, 3 grade. Sciatica. Currently takes enalapril, diuretics, Nifedipine. However, the blood pressure of 200/120 mmHg not fall below 170/110 mmHg. Last degradation in addition to raising the pressure up to 210 \ 120 mm Hg accompanied by pain in the lumbar region. From the patient medical history revealed that during the past 1.5 years, ESR was 28 - 35 mm / h, the urine is often revealed microhematuria, diagnosed with SARS because of the fourfold increase in body temperature to 37,8 - 38,3 C. Seen: face was pale and puffy. Heart rate / pulse 86 in 1 min. Rhythmically. BP 205/125 mmHg Heart borders shifted to the left. Heart sounds are muffled, the focus of P tone over the aorta. Abdomen was soft and painless. On the left hypochondrium is determined painless, nodular formations, 3 cm protruding from under the costal arch. Leg and foot edematous. Blood analysis: hemoglobin 100 g / l, erythrocytes 3.1 T / l, leucocytes 12 g / l, ESR 45 mm / hour. An Alise incontinence: bloody, completely red blood cells.

The questions:

1. Whether the diagnosis is correct precinct therapist - hypertensive disease P st, 3 rd degree
2. What are the syndromes can be distinguished?

3. Formulate a preliminary diagnosis, justify it.
4. The program further examination the patient.
5. The treatment program.

Tasks № 2.

Patients, aged 52, a locksmith, for 10 years suffered suffers from diabetes mellitus type 2, a mild form. 9 months ago ill paraproctitis, operated, healed normally. 2 months after the operation periodically rise in body temperature to 38 - 39 ° C, accompanied by chills, increased sweating. Thrice was on sick leave with a diagnosis of SARS, the flu. After taking paracetamol, aspirin, the temperature was lowered, the patient goes to work. However, the continued weakness, fatigue, occasionally chilling. In the latest deterioration of the examined patients, the doctor revealed leukopenia (3.8 g / l), ESR 32 mm / hour. Urine analysis: protein 0,99 g / l, erythrocytes change 10 - 12 in p.zr.. With the diagnosis of acute glomerulonephritis the patient hospitalized. Objectively: the patient was pale, the skin of forearms petechial rash in the groin palpable solitary, pea-sized lymph nodes. Pulse 86 in 1 min. Leaping type. BP 145/55mm.Hg. Left border of the heart is shifted to the left. Over the aorta and at Botkin auscultated diastolic noise. An increase of liver and spleen.

The questions:

1. What are the syndromes can be distinguished?
2. Formulate a preliminary diagnosis.
3. What prompted the development of disease in a patient?
4. The main criterion for clinical pathology?
5. Survey Programme, the main laboratory test.
6. The treatment program.

Tasks № 3.

Patients 60 years old, complained of dizziness, tinnitus, sweating, shortness of breath when walking, increased body temperature to 37.5 -38 oC. Bolen 4 months, when povilis and began accruing the above complaints. When the first call to the doctor the state seen as SARS, suggested aspirin and vitamins. It is marked a short-term improvement. But after 2 weeks of low-grade fever, shortness of breath, weakness. GP antibiotics. However, significant improvement was also diagnosed with community-acquired pneumonia, 2 categories of patients sent to hospital. OBJECTIVE: body temperature 38oS, the state of moderate severity. Skin and mucous membranes are pale. On the skin of the forearms, chest, abdomen isolated petechiae. Tonsils loose when pressing with a spatula - purulent contents appear. RR 24 in 1 min. Percussion of the lungs pulmonary bandbox sound. Auscultation - breathing weakened, vesicular. Heart rate / pulse 82 in 1 min. BP 130/75 mmHg Heart enlarged left. Activities of heart rhythmic, muffled tones. Over the apex - soft systolic murmur. The abdomen was soft and painless. Liver and spleen were not enlarged. Blood analysis: hemoglobin 74 g / l, erythrocytes 2.8 T / l, leucocytes 26 g / l, ESR 38 mm / hour, blast cells - 40%, stab - 2%, segmentolnuclear - 38%, lymphocytes - 18%, monocytes - 2%, platelets - 76 g / liter.

The questions:

1. Scroll to the clinical and laboratory syndrome.
2. Formulate a preliminary diagnosis
3. Survey Program
4. What changes in the myelogram you expect?
5. Treatment program
6. Forecast in this case.

Summary:

Recommended reading list

Basic literature:

- Harrison's Principles of Internal Medicine Self-Assessment and Board Review, 20th Edition 20th Edition.- (August 13, 2021). - 736 pages
- Pocket Medicine: The Massachusetts General Hospital Handbook of Internal Medicine / 007

edition (12 Sept. 2019). - 272 pages

- Davidson's Principles and Practice of Medicine: Enhanced Digital Version Included / Elsevier; 23rd edition (25 April 2018). - 1440 pages

Additional literature:

- Macleod's Clinical Examination /Elsevier; 14th edition (11 Jun. 2018). - 400 pages
- Current Medical Diagnosis and Treatment /McGraw-Hill Education; Updated edition (14 Sept. 2021). - 1840 pages
- Lippincott Connect Standalone Courseware for Bates' Guide to Physical Examination and History Taking 1.0 /LWW; 13th ed. edition (23 Mar. 2023).
- Step-Up to Medicine / Wolters Kluwer Health; 5th edition (8 May 2019). - 582 pages
- Goldman-Cecil Medicine, 2-Volume Set (Cecil Textbook of Medicine) / Elsevier; 26th edition (20 Dec. 2019). - 2944 pages
- The Washington Manual of Medical Therapeutics / Wolters Kluwer Health; 36th edition (6 Jun. 2019). - 1074 pages
- Harrison's Manual of Medicine / McGraw-Hill Education; 20th edition (5 Nov. 2019). - 1245 pages

Electronic information resources

- World Health Organization. URL: www.who.int/ru/index.html.
- European Regional Office of the World Health Organization. URL: www.euro.who.int.
- <https://www.aasld.org/>
- https://academic.oup.com/ndt/pages/General_Instruction
- <https://cprguidelines.eu/>
- <https://www.escardio.org/Guidelines/Clinical-Practice-Guidelines>
- <http://www.oxfordmedicaleducation.com/>
- <http://ard.bmj.com>
- <https://www.escardio.org/Guidelines/Clinical-Practice-Guidelines>

Practical class

Topic 18. Management of a patient with gastric dyspepsia.

The main goals: to acquire communication skills and skills of clinical examination of a patient with diarrhea syndrome; to be able to establish a preliminary diagnosis, carry out a differential diagnosis and determine the clinical diagnosis of the disease in a patient with diarrheal syndrome; to master the principles of treatment, recommendations for lifestyle changes in the management of patients with diarrheal syndrome; diagnose emergency conditions in patients with diarrheal syndrome; master the tactics of providing emergency medical care to patients with diarrheal syndrome; to be able to perform therapeutic manipulations in patients with diarrheal syndrome.

Key words: concept of chronic diarrheal syndrome; basics of pathogenesis; classification of clinical forms of these diseases; peculiarities of the course of intestinal infections depending on the clinical form and type of pathogen; main clinical manifestations of these diseases; possible complications and the timing of their appearance; modern methods of diagnosis of chronic diarrheal syndrome; tactics of managing patients in case of emergencies.

Equipment: multimedia materials - a set of thematic slides from the department's multimedia library; screenshots of the results of instrumental and laboratory tests (CBC, urine test; ultrasound of digestive organs, FGDS with targeted biopsy, study of gastric secretion and intragastric pH-metry; X- ray, X-ray of the stomach and DPC; scintigraphy of the stomach; irrigoscopy, colonoscopy); a set of situational problems on the topic of the lesson; a set of radiographs, a negatoscope; electronic versions of radiographs.

Plan:

1. Organizational measures (greetings, verification of those present, announcement of the topic, purpose of the lesson, motivation of higher education seekers to study the topic)

2. Control of the reference level of knowledge (checking homework, written work, written testing, including writing KROK-2 tests, frontal survey)
3. Formation of professional abilities and skills (mastery of skills, curation, determination of treatment regimen, laboratory research, etc.): discussion of features of diagnosis and treatment of arterial hypertension, the most common clinical manifestations, criteria for establishing a diagnosis
4. Summing up (summarizing the topic, evaluating applicants, discussing the next lesson topic and homework)

Control questions:

1. List the basic symptoms of syndrome of gastric dyspepsia.
2. Describe the features of gastric dyspepsia syndrome due to chronic gastritis, ulcerous disease, stomach cancer and functional stomach diseases.
3. List the basic kinds and variants of gastric dyspepsia syndrome.
4. List the factors, cooperating with distribution of helicobacter infection, mechanism of persistence of *H. pylori* in a mucous membrane.
5. Describe the features of clinical and morphological forms of *H. pylori*.
6. Name the forms of chronic gastritis.
7. List the pathogenic mechanisms of ulceration.
8. Bring management protocol of patient with peptic ulcer.
9. What double and triple therapy of *N. pylori* eradication.
10. List the types of supporting anti-reflux therapy.

MCQ's

1. In autumn a 26 y.o. patient developed stomach ache arising 1,5-2 hours after having meals and at night. He complains of pyrosis and constipation. The pain is getting worse after consuming spicy, salty and sour food, it can be relieved by means of soda and hot-water bag. The patient has been suffering from this disease for a year. Objectively: furred moist tongue. Abdomen palpation reveals epigastric pain on the right, resistance of abdominal muscles in the same region. What is the most likely diagnosis?
 - A. Stomach ulcer
 - B. Chronic cholecystitis
 - C. Diaphragmatic hernia
 - D. Duodenal ulcer
 - E. Chronic pancreatitis
2. A 51 y.o. woman complains of dull pain in the right subcostal area and epigastric area, nausea, appetite decline during 6 months. There is a history of gastric peptic ulcer. On examination: weight loss, pulse is 70 bpm, AP is 120/70 mm Hg. Diffuse tenderness and resistance of muscles on palpation. There is a hard lymphatic node 1x1cm in size over the left clavicle. What method of investigation will be the most useful?
 - A. Esophagogastroduodenoscopy with biopsy
 - B. Ultrasound examination of abdomen
 - C. pH-metry
 - D. Ureatic test
 - E. Stomach X-ray
3. Gastric juice analysis of a 44-year-old male patient revealed absence of free hydrochloric acid at all stages. Endoscopy revealed pallor, thinning of gastric mucosa, smoothed folds. Microscopically the atrophy of glands with intestinal metaplasia was found. What disease is this situation typical for?
 - A. Menetrier disease
 - B. Chronic type B gastritis
 - C. Chronic type C gastritis
 - D. Chronic type A gastritis
 - E. Stomach cancer
4. A 75 y.o. man has acute pain in the paraumbilical region accompanied by vomiting and feeling of abdominal swelling in approximately 30 minutes after meals. He lost 10 kg during the last months

because he doesn't eat in order to avoid pain. Abdomen examination reveals no changes in the periods between pain attacks. Above the right femoral artery a murmur can be auscultated, peripheral pulsation in the lower extremities is weak. X-ray examination of stomach and colonoscopy revealed no changes. What is the leading factor of this pathogenesis?

- A. Psychogenic changes
- B. Inflammation
- C. Transient obstruction
- D. Neoplastic process
- E. Ischemia

5. A 62-year-old patient complains of nearly permanent sensation of heaviness and fullness in the epigastrium, that increases after eating, foul-smelling eructation, occasional vomiting with food consumed 1-2 days ago, weight loss. 12 years ago he was found to have an ulcer of pyloric channel. The patient has taken ranitidine for periodic hunger pain. The patient's condition has been deteriorating over the last 3 months. Objectively: splashing sound in the epigastrium is present. What kind of complication is it?

- A. Pyloric stenosis
- B. Penetration of gastric ulcer
- C. Functional pyloric spasm
- D. Foreign body in the stomach (bezoar)
- E. Malignization of gastric ulcer

6. A 37-year-old patient complains of heartburn, sour eructation, burning, compressing retrosternal pain and pain along the esophagus rising during forward bending of body. The patient hasn't been examined, takes Almagel on his own initiative, claims to feel better after its taking. Make a provisional diagnosis:

- A. Duodenal ulcer
- B. Functional dyspepsia
- C. Cardiospasm
- D. Gastric ulcer
- E. Gastroesophageal reflux disease

7. A 49-year-old patient complains of swallowing disorder that intensifies during eating solid food, hiccups, hoarse voice, nausea, regurgitation, significant weight loss (15 kg within 2,5 months). Objectively: body weight is reduced; the skin is pale and dry; vesicular respiration; heart sounds are sufficiently sonorous; heart rate is rhythmic. The abdomen is soft, no pain on palpation. The liver is not enlarged. What investigation is most necessary for making the diagnosis in this case?

- A. Esophagoduodenoscopywithbiopsy
- B. Clinicalbloodanalysis
- C. X-ray of the gastrointestinal tract
- D. X-ray in the Trendelenburg position
- E. Investigationofgastricsecretion

8. A 49-year-old patient complains of swallowing problems, especially with solid food, hiccups, voice hoarseness, nausea, regurgitation, significant weight loss (15 kg within 2,5 months). Objectively: body weight is reduced. Skin is pale and dry. In lungs: vesicular breathing, heart sounds are loud enough, heart activity is rhythmic. The abdomen is soft, painless on palpation. Liver is not enlarged. What study is required to make a diagnosis?

- A. Esophageal duodenoscopy along with biopsy
- B. Clinical blood test
- C. X-ray of digestive tract organs
- D. X-ray in Trendelenburg's position
- E. Study of gastric secretion

9. A male patient complains of heartburn which gets stronger while bending the body, substernal pain during swallowing. There is a hiatus hernia on X-ray. What disorders should be expected at gastroscopy?

- A. Gastric peptic ulcer
- B. Chronic gastritis
- C. Gastroesophageal reflux

D. Acute erosive gastritis

E. Duodenal peptic ulcer

10. A 60-year-old patient complains of nearly permanent sensation of heaviness and fullness in the epigastrium, which increases after eating, foul-smelling eructation, occasional vomiting with food consumed 1-2 days ago, weight loss. 12 years ago he was first found to have an ulcer of pyloric channel. The patient has taken ranitidine for periodic hunger pains. The patient's condition has been deteriorating over the last 3 months. Objectively: splashing sound in the epigastrium is present. What kind of complication is it?

A. Pyloric stenosis

B. Penetration of gastric ulcer

C. Functional pyloric spasm

D. Foreign body in the stomach (bezoar)

E. Malignization of gastric ulcer

Clinical tasks

Task №1

A patient is 35 years old, grumbles about heartburn, belch air and sour, burning, squeezing pains after a breastbone, along the esophagus, arising up in 30-40 minutes after a meal, at inclinations of trunk forward. He was not examined, takes almagel independently, after which marks the state improvement.

Questions.

1. Your diagnosis is?
2. Possible complications?
3. What additional tests should be done?
4. Tactic of doctor in relation to treatment of this patient?

Task №2

A man, 46 years old, suffering from a chronic bronchitis with the frequent intensifying, grumbles about burning pains after the breastbone of different intensity and durations, increasing at peace and at inclinations. About what disease is it necessary to think about?

Questions.

1. What is cause of acute worsening of patients' state?
2. What researches must be quickly conducted to a patient?
3. Is it necessary to hospitalize a patient?
4. Further tactic of patient's management?

Task №3

Man 35 years old, during 7 years suffering from ulcerous illness of duodenum with the frequent intensifying appealed to the polyclinic with complaints on hungry nightly pains in epigastria, nausea, constipations. Passed the courses of ambulatory and in-patient department treatment, including ranitidin, almagel, no-shpa, metronidasol, seed of flax and physiotherapy. Objectively: a stomach is sensitive in epigastria and right undercostal area. An examination is appointed a patient, including FGDS, ultrasound of abdominal cavity organs.

Questions.

1. What additional research will help to specify a diagnosis?
2. What will be the treatment tactics?
3. What researches should be conducted additionally?
4. Health centre system of patient.

Summary:

Recommended reading list

Basic literature:

- Harrison's Principles of Internal Medicine Self-Assessment and Board Review, 20th Edition 20th Edition.- (August 13, 2021). - 736 pages

- Pocket Medicine: The Massachusetts General Hospital Handbook of Internal Medicine / 007 edition (12 Sept. 2019). - 272 pages
- Davidson's Principles and Practice of Medicine: Enhanced Digital Version Included / Elsevier; 23rd edition (25 April 2018). - 1440 pages

Additional literature:

- Macleod's Clinical Examination /Elsevier; 14th edition (11 Jun. 2018). - 400 pages
- Current Medical Diagnosis and Treatment /McGraw-Hill Education; Updated edition (14 Sept. 2021). - 1840 pages
- Lippincott Connect Standalone Courseware for Bates' Guide to Physical Examination and History Taking 1.0 /LWW; 13th ed. edition (23 Mar. 2023).
- Step-Up to Medicine / Wolters Kluwer Health; 5th edition (8 May 2019). - 582 pages
- Goldman-Cecil Medicine, 2-Volume Set (Cecil Textbook of Medicine) / Elsevier; 26th edition (20 Dec. 2019). - 2944 pages
- The Washington Manual of Medical Therapeutics / Wolters Kluwer Health; 36th edition (6 Jun. 2019). - 1074 pages
- Harrison's Manual of Medicine / McGraw-Hill Education; 20th edition (5 Nov. 2019). - 1245 pages

Electronic information resources

- World Health Organization. URL: www.who.int/ru/index.html.
- European Regional Office of the World Health Organization. URL: www.euro.who.int.
- <https://www.aasld.org/>
- https://academic.oup.com/ndt/pages/General_Instruction
- <https://cprguidelines.eu/>
- <https://www.escardio.org/Guidelines/Clinical-Practice-Guidelines>
- <http://www.oxfordmedicaleducation.com/>
- <http://ard.bmj.com>
- <https://www.escardio.org/Guidelines/Clinical-Practice-Guidelines>

Practical class

Topic 19. Management of a patient with chronic diarrheal syndrome.

The main goals: to acquire communication skills and skills of clinical examination of a patient with diarrhea syndrome; to be able to establish a preliminary diagnosis, carry out a differential diagnosis and determine the clinical diagnosis of the disease in a patient with diarrheal syndrome; to master the principles of treatment, recommendations for lifestyle changes in the management of patients with diarrheal syndrome; diagnose emergency conditions in patients with diarrheal syndrome; master the tactics of providing emergency medical care to patients with diarrheal syndrome; to be able to perform therapeutic manipulations in patients with diarrheal syndrome.

Key words: concept of chronic diarrheal syndrome; basics of pathogenesis; classification of clinical forms of these diseases; peculiarities of the course of intestinal infections depending on the clinical form and type of pathogen; main clinical manifestations of these diseases; possible complications and the timing of their appearance; modern methods of diagnosis of chronic diarrheal syndrome; tactics of managing patients in case of emergencies.

Equipment: multimedia materials - a set of thematic slides from the department's multimedia library; screenshots of the results of instrumental and laboratory tests (ultrasound of digestive organs, FGDS with targeted biopsy, study of gastric secretion and intragastric pH-metry; X- ray, X-ray of the stomach and DPC; scintigraphy of the stomach; irrigoscopy, colonoscopy); a set of situational problems on the topic of the lesson; a set of radiographs, a negatoscope; electronic versions of radiographs.

Plan:

1. Organizational measures (greetings, verification of those present, announcement of the topic,

- purpose of the lesson, motivation of higher education seekers to study the topic)
2. Control of the reference level of knowledge (checking homework, written work, written testing, including writing KROK-2 tests, frontal survey)
 3. Formation of professional abilities and skills (mastery of skills, curation, determination of treatment regimen, laboratory research, etc.): discussion of features of diagnosis and treatment of arterial hypertension, the most common clinical manifestations, criteria for establishing a diagnosis
 4. Summing up (summarizing the topic, evaluating applicants, discussing the next lesson topic and homework)

Control questions:

1. Give the determination of diarrhea.
2. What types of diarrhea on the mechanism of origin do you know?
3. Describe the basic mechanism of osmotic diarrhea.
4. What diseases result in development of osmotic diarrhea.
5. Name the basic mechanisms of secretory diarrhea.
6. List the diseases at which diarrhea carries secretory character.
7. Name the basic mechanisms of diarrhea development due to malabsorption.
8. Give the determination to concepts: steatorrhea, kreatorrhea and amylopoorrhea. What tests reveal them?
9. That do coprology include in itself?
10. Methods of primary and secondary prophylaxis of diseases, accompanied by diarrheal syndrome.

MCQ's:

1. A 43 year old woman has suffered from nonspecific ulcerative colitis for 5 years. On rectoromanoscopy: evident inflammatory process of lower intestinal parts, pseudopolyposive changes of mucous membrane. In blood: WBC- $9,8 \times 10^9/L$, RBC- $3,0 \times 10^{12}/L$, ESR - 52 mm/hour. What medication provides pathogenetic treatment of this patient?
 - A. Vikasolum
 - B. Sulfosalasine
 - C. Kreon
 - D. Linex
 - E. Motilium
2. 4 hours after having meals a patient with signs of malnutrition and steatorrhea experiences stomach pain, especially above navel and to the left of it. Diarrheas take turns with constipation lasting up to 3-5 days. Palpation reveals moderate painfulness in the choledochopancreatic region. The amylase rate in blood is stable. X-ray reveals some calcifications located above navel. What is the most likely diagnosis?
 - A. Chronic calculous cholecystitis
 - B. Chronic gastroduodenitis
 - C. Duodenal ulcer
 - D. Zollinger-Ellison syndrome
 - E. Chronic pancreatitis
3. A 46-year-old male patient complains of frequent liquid stools with a lot of mucus, pus and blood; pain across the abdomen, loss of 7 kg within 6 months. He has a 1-year history of non-specific ulcerative colitis. What group of drugs should be preferred for this patient?
 - A. Corticosteroids
 - B. Antibacterial
 - C. Sulfonamides
 - D. Nitrofurans
 - E. Polyzymes
4. A 43-year-old female patient complains of unstable defecation with frequent constipations, abdominal swelling, headache, sleep disturbance. Body weight is unchanged. What disease are these clinical presentations typical for?
 - A. Irritable bowel syndrome
 - B. Chronic enteritis

C. Chronic pancreatitis

D. Chronic atrophic gastritis

E. Colorectal cancer

5. A 55 y.o. patient complains of distended abdomen and rumbling, increased winds evacuation, liquid foamy feces with sour smell following the dairy products consumption. What is the correct name of this syndrome?

A. Syndrome of fermentative dyspepsia

B. Syndrome of decayed dyspepsia

C. Syndrome of fatty dyspepsia

D. Dyskinesia syndrome

E. Malabsorption syndrome

6. A 48-year-old male patient complains of constant pain in the upper abdomen, mostly on the left, that is getting worse after taking meals; diarrhea, weight loss. The patient is an alcohol abuser. 2 years ago he had acute pancreatitis. Blood amylase is 4 g/h*L. Coprogram shows steatorrhea, creatorrhea. Blood glucose is 6,0 mmol/L. What treatment is indicated for this patient?

A. Gastrozepin

B. Insulin

C. Panzinorm forte

D. Contrycal

E. No-spa

7. A 58 y.o. man, who has taken alcoholic drinks regularly for 20 years, complains of intensive girdle pain in the abdomen. Profuse nonformed stool 2-3- times a day has appeared for the last 2 years, loss of weight for 8 kg for 2 years. On examination: abdomen is soft, painless. Blood amylase - 12g/L. Feces examination-neutral fat 15 g per day, starch grains. What is the most reasonable treatment at this stage?

A. Pancreatine

B. Contrykal

C. Aminocapron acid

D. Levomicytine

E. Imodium

8. 43 y.o. male complains of stomach pain, which relieves with defecation, and is accompanied by abdominal winds, rumbling, the feeling of incomplete evacuation or urgent need for bowel movement, constipation or diarrhea in alternation. These symptoms have lasted for over 3 months. No changes in laboratory tests. What is the most likely diagnosis?

A. Chronic enterocolitis, exacerbation phase

B. Spastic colitis

C. Colitis with hypertonic type dyskinesia

D. Irritable bowel syndrome

E. Atonic colitis

9. A 35 y.o. woman consulted a doctor about occasional pains in paraumbilical and iliac region that reduce after defecation or passage of gases. Defecation takes place up to 6 times a day, stool is not solid, with some mucus in it. Appetite is normal, she has not put off weight. First such symptoms appeared 1,5 year ago, but colonoscopy data reveals no organic changes. Objectively: abdomen is soft, a little bit painful in the left iliac region. Blood and urine are normal. What is the preliminary diagnosis?

A. Celiac disease

B. Irritable bowels syndrome

C. Crohn's disease

D. Pseudomembranous colitis

E. Dispancreatism

10. 60-years-old woman was admitted to gastroenterology department with complaints of attacks of stomach pain, water diarrhea, face redness with the episodes of the stridor breathing. What diagnosis is most probable?

A. Gastroenteritis.

- B. Carcinoid syndrome.
- C. Non-specific ulcerous colitis.
- D. Syndrome of irritated intestine.
- E. Rectum cancer.

Clinical tasks:

Task №1.

A patient 25 years old, grumbles about attacks of stomach pain, frequent liquid stool with the mucus and blood, increased body temperature. He is ill during 2 years, had lost 14 kg. Objectively: pulse – 96/min, BP-110/70 mm Hg, temperature of body -37,6 C. Skin covers and visible mucous membranes are pale. A stomach is soft, sensitive on palpation along the colon, especially on the left. On colonoscopy: a wall of intestine is edematous, easily injured, erosions and ulcers. There is a significant amount of mucus and blood. Monotony and continuity of inflammation of intestine wall is marked. Anemia and leucocytosis is revealed in the general blood analysis.

Questions:

- 1) What non-specified disease is the most probable for this patient?
 - A. Non-specific ulcerous colitis.
 - B. Crown's disease.
 - C. Syndrome of irritated colon.
 - D. Carcinoid syndrome.
 - E. Ameba dysentery.
- 2) Methods of primary and secondary prophylaxis.
- 3) Work out a plan of treatment.

Task №2.

A patient 30 years old, grumbles about attacks of stomach pain, liquid stool 6-8 times per day, weakness, increased body temperature, nausea and vomiting. He is ill during 2 years, had lost 12 kg. On examination: a skin is dry, tongue is red. A stomach is soft, on palpation thick intestine is sensitive. In a right lower quadrant there palpated the formation of paste consistency. There are switches in a perianal area. Pulse - 92 /min, BP-100/70 mm Hg, temperature -37,4^C. In blood: red blood cells - $3,2 \cdot 10^{12}/l$, Hb92 gr/l, L. - $10,6 \cdot 10^9/l$, ESR-32 mm/h. Irrigoscopy: ulceration of granulematous areas of the intestine mucous membrane, «cobble road». FCS: in area of iliac intestine - polyploid formations, strictures, microabscesses, cracks.

Questions:

- 1) What diagnosis is the most credible?
 - A. Non-specific ulcerous colitis.
 - B. Crown's disease.
 - C. Syndrome of irritated intestine.
 - D. Carcinoid syndrome.
 - E. Chronic ischemic colitis.
- 2) What sign distinguish Crown's disease from non-specific ulcerous colitis?
 - A. Diarrhea.
 - B. Fever.
 - S. Stomach ache.
 - D. Ulceration of the mucous membrane.
 - E. Switches, granulomas, cracks.
- 3) Work out a plan of treatment.

Task № 3.

Patient T., 60 years old, during 3 last months grumbles about stomach-aches, which diminish after defecation and accompanied by flatulence, rumbling, feeling of the incomplete emptying or imperative urges on defecation, by locks and diarrhea. Marks worsening after stresses. Objectively: general state is satisfactory. Stomach is a little swollen, on palpation is sensible along the intestine. Pulse - 80 /min, BP-130/70 mm Hg. General analysis of blood and urine without changes. Coprologic research of

excrement is normal, research on the presence of the Protozoa, parasites gave a negative result. Colonoscopy is normal.

Questions:

- 1) What is the most possible diagnosis?
 - A. Atonic colitis.
 - B. Non-specific ulcerous colitis.
 - C. Crohn's disease.
 - D. Syndrome of irritated intestine.
 - E. Chronic ischemic colitis.
- 2) Make plan of inspection.
- 3) What diseases is it necessary to conduct a differential diagnosis with?

Summary:

Recommended reading list

Basic literature:

- Harrison's Principles of Internal Medicine Self-Assessment and Board Review, 20th Edition 20th Edition.- (August 13, 2021). - 736 pages
- Pocket Medicine: The Massachusetts General Hospital Handbook of Internal Medicine / 007 edition (12 Sept. 2019). - 272 pages
- Davidson's Principles and Practice of Medicine: Enhanced Digital Version Included / Elsevier; 23rd edition (25 April 2018). - 1440 pages

Additional literature:

- Macleod's Clinical Examination /Elsevier; 14th edition (11 Jun. 2018). - 400 pages
- Current Medical Diagnosis and Treatment /McGraw-Hill Education; Updated edition (14 Sept. 2021). - 1840 pages
- Lippincott Connect Standalone Courseware for Bates' Guide to Physical Examination and History Taking 1.0 /LWW; 13th ed. edition (23 Mar. 2023).
- Step-Up to Medicine / Wolters Kluwer Health; 5th edition (8 May 2019). - 582 pages
- Goldman-Cecil Medicine, 2-Volume Set (Cecil Textbook of Medicine) / Elsevier; 26th edition (20 Dec. 2019). - 2944 pages
- The Washington Manual of Medical Therapeutics / Wolters Kluwer Health; 36th edition (6 Jun. 2019). - 1074 pages
- Harrison's Manual of Medicine / McGraw-Hill Education; 20th edition (5 Nov. 2019). - 1245 pages

Electronic information resources

- World Health Organization. URL: www.who.int/ru/index.html.
- European Regional Office of the World Health Organization. URL: www.euro.who.int.
- <https://www.aasld.org/>
- https://academic.oup.com/ndt/pages/General_Instruction
- <https://cprguidelines.eu/>
- <https://www.escardio.org/Guidelines/Clinical-Practice-Guidelines>
- <http://www.oxfordmedicaleducation.com/>
- <http://ard.bmj.com>
- <https://www.escardio.org/Guidelines/Clinical-Practice-Guidelines>

Practical class

Topic 20. Management of a patient with jaundice.

The main goals: to acquire communication skills and skills of clinical examination of a patient with jaundice; be able to establish a preliminary diagnosis, carry out a differential diagnosis and determine the clinical diagnosis of the disease in a patient with jaundice; master the principles of treatment, recommendations for lifestyle changes in the management of patients with jaundice; diagnose emergency conditions in patients with jaundice; master the tactics of providing emergency medical

care to patients with jaundice; to be able to perform therapeutic manipulations in patients with jaundice.

Key words: normal level and exchange of bile pigments; ways of its violation in various types of jaundice; the volume of laboratory and instrumental research methods necessary for the differential diagnosis of diseases accompanied by subhepatic, hepatic and suprahepatic jaundice; patient management tactics depending on the cause; modern standards of treatment; basics of primary and secondary prevention.

Equipment: multimedia materials - a set of thematic slides from the department's multimedia library; screenshots of the results of instrumental and laboratory tests (biochemical liver tests, coprogram, ultrasound of the abdominal cavity, ultrasound with choleretic breakfast, duodenal sounding, EGDS); a set of situational problems on the subject of the lesson.

Plan:

1. Organizational measures (greetings, verification of those present, announcement of the topic, purpose of the lesson, motivation of higher education seekers to study the topic)
2. Control of the reference level of knowledge (checking homework, written work, written testing, including writing KROK-2 tests, frontal survey)
3. Formation of professional abilities and skills (mastery of skills, curation, determination of treatment regimen, laboratory research, etc.): discussion of features of diagnosis and treatment of arterial hypertension, the most common clinical manifestations, criteria for establishing a diagnosis
4. Summing up (summarizing the topic, evaluating applicants, discussing the next lesson topic and homework).

Control questions:

1. Name the basic types of jaundice.
2. Name the criteria of mechanical jaundice.
3. Name the syndromes, related to functional hyperbilirubinemias.
4. Define the criteria of hemolytic jaundice.
5. Conduct a differential diagnosis between parenchymatous and mechanical jaundices.
6. Name the basic stages of bilirubin metabolism in an organism.
7. Define the differences between false and veritable jaundice.
8. Name basic diseases, related to the category: inherited deficit of glucoroniltransferase enzyme.
9. Name the basic instrumental methods of liver examination for differential diagnostics of jaundices.
10. Name the basic laboratory indexes of biochemical blood research, related to cytolytic and cholestatic tests.

MCQ's:

1. Which disease among listed below does not lead to jaundice development?
 - A. Talasemia.
 - B. Aplastic anemia.
 - C. Acquired hemolytic anemia.
 - D. Microspherocytosis.
 - E. Auto-immune hemolytic anemias.
2. What from the listed does not lead to development of indirect hyperbilirubinemia?
 - A. Zhilber's syndrome.
 - B. Hemolytic anemia.
 - C. Non-effective erythropoiesis
 - D. Dublin-Johnson's syndrome.
 - E. Auto-immune hemolytic anemia.
3. A 56-year-old woman complains of itching skin of her torso, constant nausea, constipation, sensation of heaviness and pain in the right subcostal area, extreme general fatigue. The patient suffers from biliary cirrhosis. The skin is pale icteric. The abdomen is soft, the liver protrudes 2,0 cm from

under the margin of the right costal arch, sensitive on palpation. Biochemical investigation: total bilirubin - 142,0 μmol/l, conjugated bilirubin - 139,0 μmol/l, alanine aminotransferase 0,98 mmol/hour·l, aspartate aminotransferase - 0,82 mmol/hour·l, alkaline phosphatase - 8,7 mmol/hour·l. What drug should be prescribed in the first place?

- A. Ursodeoxycholic acid
- B. Sirepar
- C. Allochol
- D. Essentialeforte (Phospholipides)
- E. Livolinforte

4. A 42 y.o. patient was admitted to the gastroenterology with skin itching, jaundice, discomfort in the right subcostal area, generalized weakness. On examination: skin is jaundice, traces of scratches, liver is

+5 cm, spleen is 6x8 cm. In blood: alkaline phosphatase - 550 U/L, general bilirubin - 62 μmol/L, cholesterol - 8,1 mmol/L. What is the leading syndrome in the patient?

- A. Mesenchymal inflammatory
- B. Cytolytic
- C. Cholestatic
- D. Asthenic
- E. Liver-cells insufficiency

5. In the case of revealing the splenomegaly, reticulocytosis and indirect bilirubinemia, what is the most possible diagnosis?

- A. Hemolytic anemia.
- B. Chronic leucosis.
- C. Thrombosis of spleen veins.
- D. Portal cirrhosis of liver.
- E. Cirrhosis of liver.

6. A 52-year-old patient complains about having pain attacks in the right subcostal area for about a year. The pain arises mainly after taking fatty food. Over the last week the attacks occurred daily and became more painful. On the 3rd day of hospitalization the patient presented with icteric skin and scleras, light- colored feces and dark urine. In blood: neutrophilic leukocytosis - $13,1 \times 10^9/L$, ESR- 28 mm/h. What is the most likely diagnosis?

- A. Hypertensive dyskinesia of gallbladder
- B. Chronic recurrent pancreatitis
- C. Fatty degeneration of liver
- D. Chronic cholangitis, exacerbation stage
- E. Chronic calculous cholecystitis

7. What state is accompanied by the discolored stool?

- A. Hemolytic jaundice.
- B. Parenchymatous jaundice.
- C. Mechanical jaundice.
- D. All the listed diseases.
- E. Auto-immune hemolytic anemia.

8. The increase of alfa-fetoprotein in adults signs about:

- A. Hepatocellular carcinoma.
- B. Chronic hepatitis.
- C. Viral hepatitis.
- D. Cirrhosis of liver.
- E. Auto-immune hepatitis.

9. 52 year old woman complained of attacks of right subcostal pain after fatty meal she has been suffering from for a year. Last week the attacks repeated every day and became more painful. What diagnostic study would you recommend?

- A. X-ray examination of the gastrointestinal tract
- B. Ultrasound study of the pancreas
- C. Ultrasound examination of the gallbladder

D. Liver function tests

E. Blood cell count

10. 77 year old man who has been suffering from diabetes for the last six months was found to be jaundiced. He was asymptomatic except for weight loss at the rate of 10 kg in 6 months. Physical examination revealed a hard, globular, right upper quadrant mass that moves during respiration. A CT scan shows enlargement of the head of the pancreas, with no filling defects in the liver. The most likely diagnosis is:

A. Infectious hepatitis

B. Carcinoma of the head of the pancreas

C. Metastatic disease of liver

D. Hemolytic jaundice

E. Malignant biliary stricture

Clinical tasks:

Task №1.

A 60-years-old woman, mother of six children, felt sudden sharp pain in right undercostal area with irradiation to a scapula. Twice there was vomiting with bile. A temperature rose up to 38,8C, a chill appeared. On examination: icteric sclera, a liver comes forward on 1 cm from under a costal arch. A stomach is soft, sensitive in the projections of gall-bladder, local intestinal tension in right undercostal area. Merfy's symptom is positive. Pulse - 100/min. General analysis of blood: L - $10,6 \cdot 10^9/l$, ESR- 24 mm/hour.

Questions:

1) What is the most possible preliminary diagnosis?

A. Infectious hepatitis.

B. Hemolytic jaundice.

C. Carcinoma of pancreas head.

D. Cholelithiasis.

E. Zhilber's syndrome.

2) Methods of primary and secondary prophylaxis.

3) Make plan of treatment.

Task №2.

Man, 75 years old, grumbles about a weakness, intensive itching of skin covers, bad sleep, loss of appetite, flatulence. Last 6 months marks worsening: itching increased, especially in a night-time, appeared icteric skin and sklera, pains in epigastria, periodic increase of body temperature to 37,7C. Patient lost 10 kg for the last 6 months. Objectively: Skin of icteric color with a greenish tint and plural scratches. Hepatosplenomegaly is exposed. On palpation painless spherical soft formation, moving on breathing, is determined in right undercostal area. Computer tomography exposes the increase of pancreas head, without defects in a liver.

Questions:

1) What is the most possible preliminary diagnosis?

A. Infectious hepatitis.

B. Hemolytic jaundice.

C. Carcinoma of pancreas head.

D. Cholelithiasis.

E. Metastasis in liver.

2) Methods of primary and secondary prophylaxis.

3) Make plan of treatment.

Task №3.

A patient 20 years old, grumbles about pains in right undercostal area, which increases after a meal, nausea, increase of body temperature to 37oC, icteric skin, atralgia. He is ill for 8 months. On the examination: skin and sclera are icteric. A stomach is swollen, excessive sensitiveness in right undercostal area. A liver is enlarged to 5 cm comes forward for the edges of costal arch, an edge is

morecompact, surface is smooth. In blood: ESR-47 mm/h, bilirubin general - 86,1 mkmol/l, direct - 42,3 mkmol/l. In blood antibodies are exposed to the smooth muscles cells. General protein - 62 gr/l, albumen - 40%, globulin - 60%, gamma globulin-38 %. The markers of viral hepatitis are not exposed. On ultrasound: diameter of portal vein is 1 cm

Questions:

- 1) What is the most possible preliminary diagnosis?
 - A. Hemochromatosis.
 - B. Primary biliar cirrhosis.
 - C. Zhilber's syndrome.
 - D. Auto-immune hepatitis.
 - E. Hemolytic jaundice.
- 2) Methods of primary and secondary prophylaxis.
- 3) Make a plan of treatment.

Summary:

Recommended reading list

Basic literature:

- Harrison's Principles of Internal Medicine Self-Assessment and Board Review, 20th Edition 20th Edition.- (August 13, 2021). - 736 pages
- Pocket Medicine: The Massachusetts General Hospital Handbook of Internal Medicine / 007 edition (12 Sept. 2019). - 272 pages
- Davidson's Principles and Practice of Medicine: Enhanced Digital Version Included / Elsevier; 23rd edition (25 April 2018). - 1440 pages

Additional literature:

- Macleod's Clinical Examination /Elsevier; 14th edition (11 Jun. 2018). - 400 pages
- Current Medical Diagnosis and Treatment /McGraw-Hill Education; Updated edition (14 Sept. 2021). - 1840 pages
- Lippincott Connect Standalone Courseware for Bates' Guide to Physical Examination and History Taking 1.0 /LWW; 13th ed. edition (23 Mar. 2023).
- Step-Up to Medicine / Wolters Kluwer Health; 5th edition (8 May 2019). - 582 pages
- Goldman-Cecil Medicine, 2-Volume Set (Cecil Textbook of Medicine) / Elsevier; 26th edition (20 Dec. 2019). - 2944 pages
- The Washington Manual of Medical Therapeutics / Wolters Kluwer Health; 36th edition (6 Jun. 2019). - 1074 pages
- Harrison's Manual of Medicine / McGraw-Hill Education; 20th edition (5 Nov. 2019). - 1245 pages

Electronic information resources

- World Health Organization. URL: www.who.int/ru/index.html.
- European Regional Office of the World Health Organization. URL: www.euro.who.int.
- <https://www.aasld.org/>
- https://academic.oup.com/ndt/pages/General_Instruction
- <https://cprguidelines.eu/>
- <https://www.escardio.org/Guidelines/Clinical-Practice-Guidelines>
- <http://www.oxfordmedicaleducation.com/>
- <http://ard.bmj.com>
- <https://www.escardio.org/Guidelines/Clinical-Practice-Guidelines>

Practical class

Topic 21. Management of a patient with ascites. Management of a patient with portal hypertension.

The main goals:to acquire communication skills and clinical examination skills of a patient with ascites and portal hypertension; be able to establish a preliminary diagnosis, carry out a differential diagnosis and determine the clinical diagnosis of the disease in a patient with ascites and portal

hypertension; master the principles of treatment, recommendations for lifestyle changes in the management of patients with ascites and portal hypertension; diagnose emergency conditions in patients with ascites and portal hypertension; master the tactics of providing emergency medical care to patients with ascites and portal hypertension; to be able to perform therapeutic manipulations in patients with ascites and portal hypertension.

Key words: causes and clinical manifestations of portal hypertension and ascites; the volume of laboratory and instrumental research methods necessary for the differential diagnosis of diseases accompanied by hepatomegaly, portal hypertension and ascites; patient management tactics depending on the cause; modern standards of treatment; basics of prevention of these complications.

Equipment: multimedia materials - a set of thematic slides from the department's multimedia library; screenshots of the results of instrumental and laboratory tests (biochemical liver tests, coprogram, ultrasound of the abdominal cavity, ultrasound with choleretic breakfast, duodenal sounding, EGDS); a set of situational problems on the subject of the lesson.

Plan:

1. Organizational measures (greetings, verification of those present, announcement of the topic, purpose of the lesson, motivation of higher education seekers to study the topic)
2. Control of the reference level of knowledge (checking homework, written work, written testing, including writing KROK-2 tests, frontal survey)
3. Formation of professional abilities and skills (mastery of skills, curation, determination of treatment regimen, laboratory research, etc.): discussion of features of diagnosis and treatment of arterial hypertension, the most common clinical manifestations, criteria for establishing a diagnosis
4. Summing up (summarizing the topic, evaluating applicants, discussing the next lesson topic and homework).

Quiz

1. Pathogenetic classification of diseases accompanied by ascites.
2. Differential diagnosis of ascites with abdominal diseases, malignant neoplasms, cardiac and renal failure
3. Plan of patients' examination with ascites.
4. Instrumental and laboratory research methods in ascites. Investigation of ascitic fluid
5. Tactics of patients' management, depending on the causes of ascites, differentiated therapy
6. Standards of patients' treatment with ascites.
7. Principles of diuretic therapy for ascites
8. Indications for celiocentesis and surgical treatment
9. Primary and secondary prevention of ascites.
10. Prognosis and ability to work with ascites.

MCQ's

1. 49 - year-old man, disability group I, treated from the liver cirrhosis for several years. In recent months the abdomen significantly enlarged, general weakness appeared. Admitted to the hospital after two weeks of daily taking furosemide. What changes you most probably will identify in the study of blood electrolytes?
 - A. Decreased Potassium
 - B. Decreased Calcium
 - C. Decreased Sodium
 - D. Increased Calcium
 - E. Increased Potassium
2. The patient complains of nausea, feeling of "fullness" after eating any food, abdominal distension, progressive weight loss. Sick with hepatitis for 20 years. On examination: skin is pale. Expansion of subcutaneous veins of anterior abdominal wall, the presence of free fluid in the abdomen, hepatomegaly, splenomegaly, edema of the lower extremities. What are the main pathogenetic

mechanisms of development of the state of the patient?

- A. Violation of the blood coagulation
- B. Activation of lipid peroxidation and a violation of mineral metabolism
- C. Postsinusoid blood flow blocking to the liver and the formation of porto-caval anastomosis
- D. Reduced pumping function of the heart
- E. Dysfunction of the parasympathetic and sympathetic divisions of the autonomic nervous system

3. A 42-year-old female patient suffers from micronodular cryptogenic cirrhosis. Over the last week her condition has deteriorated: she developed convulsions, mental confusion, progressing jaundice.

What study may give reasons for such aggravation?

- A. Determination of cholesterol ethers
- B. Determination of serum ammonia
- C. Determination of alpha-fetoprotein
- D. Determination of ALAT and ASAT
- E. Determination of alkaline phosphatase

4. In patient M., who is sick with liver cirrhosis for a long time, lately there have been complaints of moderate pain in the epigastric area, constant bloating, which intensifies after meals. Objective: enhanced subcutaneous veins of abdomen, signs of free fluid in the abdomen, enlarged liver and spleen. On ultrasonography: increased portal vein, enlargement of the liver and spleen. What kind of dominant complication of liver cirrhosis can you think about?

- A. Thrombosis of the portal vein
- B. Hepatocellular insufficiency
- C. Portal hypertension
- D. Peritonitis
- E. Dysbacteriosis of intestine

5. The patient aged 48, complains of heaviness in the right hypochondrium, bitter taste in the mouth, itching. He is ill with viral hepatitis. Objective: enlarged abdomen due to ascites, dilated veins on the anterior abdominal wall, umbilicus is evaginated, spleen is enlarged. Your diagnosis?

- A. Cancer of the head of the pancreas
- B. Cirrhosis
- C. Liver cancer
- D. Cholelithiasis
- E. Viral hepatitis

6. The patient aged 36, is has ascites, splenomegaly, liver sizes by Kurlov – 11x9x8 cm, varicose veins of the esophagus. Anamnesis: had abdominal trauma, intestinal bleeding. AST - 46 U/L, ALT - 68 U/L, bilirubin, total - 21 mkmol/L, free -17,1mkmol/L. The diagnosis is:

- A. Thrombosis of hepatic veins (Budd-Chiari syndrome)
- B. Thrombosis of the portal vein
- C. Constrictive pericarditis
- D. Thrombosis of the inferior vena cava
- E. Tumor of the peritoneum (mesothelioma)

7. The patient B. 32 years old, suffering from hematogenous disseminated tuberculosis developed dyspnea, abdominal enlargement, edema. In pleural cavities, pericardium and abdominal cavity exudate is detected. Paracentesis was performed, 12 liters of light-yellow liquid were extracted from the abdominal cavity. Examination of the liquid: relative density - 1010, protein 6.6 g/L, cells: 120 cells per cubic mm., Atypical cells have not been detected, microbiological examination showed no bacterial growth. Choose the most likely diagnosis.

- A. Ascites with heart failure
- B. Ascites with peritoneal mesothelioma
- C. Ascites in liver cirrhosis
- D. Ascites, peritonitis
- E. Ascites with tuberculous polyserositis

8. 48-year-old patient complains of heaviness in the right hypochondrium, itching of the skin. He had been treated in infectious diseases hospital repeatedly due to icterus and itch. On physical exam: meteorism, ascitis, dilation of abdominal wall veins, protruded umbilicus, spleen enlargement. What

can be diagnosed in this case?

- A. Liver cirrhosis
- B. Cancer of the liver
- C. Cancer of the head of pancreas
- D. Gallstones
- E. Viral hepatitis B

9. In the history of the patient of 30 years old there is closed chest trauma. Recently notes increased shortness of breath, heaviness in the right hypochondrium, the feeling of palpitations. Objective examination: acrocyanosis, swollen neck veins, ascites, edema of the lower extremities. On auscultation the heart sounds are quiet, extra III tone can be auscultated. On x-ray: chest organs without pathological changes. What disease occurred in the patient?

- A. Constrictive pericarditis
- B. Exudative pericarditis
- C. Chronic bronchitis
- D. Aortic stenosis
- E. Cirrhosis

10. A patient, aged 48, complains of heaviness in the right hypochondrium, itching of the skin. Repeatedly he had been treated in infectious diseases hospital because of icterus and itch. Objectively: meteorism, ascitis, dilation of abdominal wall veins, protruding navel, spleen enlargement. Diagnosis is:

- A. Cancer of the liver
- B. Gallstones
- C. Liver cirrhosis
- D. Viral hepatitis B
- E. Cancer of the head of pancreas

Situational tasks

Task №1

Patient S., 56 years complains on constant gravity in the right hypochondrium, the increase in the volume of the abdomen, swelling legs and feet, general weakness, shortness of breath. He is ill for about 5 years when he began to observe the gravity in the right hypochondrium, abdominal distension. Last year started to appear periodic swelling on his feet, a significant increase in the volume of the abdomen. In the past, abused alcohol. Objectively: the skin and sclera - subicteric. The skin of the trunk has isolated vascular asterixes. Tongue is glossy, bright crimson color. Abdomen is greatly extended due to the presence of free fluid. Liver 5 cm in favor from the edge of the right costal arch, palpation of the liver is difficult because of the tension of the anterior abdominal wall. The spleen is 3 cm below the left costal arch. Edema of legs and feet. Survey: Blood: Er-3, 5 T / L; Hb-129 g / l, L - 6,4 g / l, ESR -28 mm / hour. Bilirubin total, 27.6 mmol / l; direct-14, 6mmol / liter, indirect-13, 0 mmol / liter. AST-0, 7 mmol / h l, ALT-1, 2 mmol / h l. Alkaline phosphatase-2.5 mmol / h × liter. Total protein, 50 g / liter. Albumin 49% globulins: α 1 -3%, α 2 -8%, β -10%, γ -20%. Urea - 4,5mmol / liter. EGDS: varicose veins of the esophagus.

1) Select the leading syndrome.

- A. Ascites.
- B. Hepatic encephalopathy.
- C. Hepatocellular failure.
- D. Hepatorenal.
- E. Cholestasis.

2) Make a plan of treatment

Task №2

Patient H., 58 years old, complains on constant gravity in the right hypochondrium, the increase in the volume of the abdomen, swelling legs and feet, general weakness, shortness of breath. He is ill for about 5 years when he began to observe the gravity in the right hypochondrium, abdominal distension. Last year started to appear periodic swelling on his feet, a significant increase in the volume of the

abdomen. In the past, abused alcohol. Objectively: the skin and sclera - subicteric. The skin of the trunk has isolated vascular asterixes. Tongue is glossy, bright crimson color. Abdomen is greatly extended due to the presence of free fluid. Liver 5 cm in favor from the edge of the right costal arch, palpation of the liver is difficult because of the tension of the anterior abdominal wall. The spleen is 3 cm below the left costal arch. Edema of legs and feet. Survey: Blood: Er-3, 5 T / L; Hb-129 g / l, L - 6,4 g / l, ESR -28 mm / hour. Bilirubin total, 27.6 mmol / l; direct-14, 6mmol / liter, indirect-13, 0 mmol / liter. AST-0, 7 mmol / h l, ALT-1, 2 mmol / h l. Alkaline phosphatase-2.5 mmol / h × liter. Total protein, 50 g / liter. Albumin 49% globulins: α 1 -3%, α 2 -8%, β -10%, γ -20%. Urea - 4,5mmol / liter. EGDS: varicose veins of the esophagus. Scintigraphy of the liver: liver diffusely enlarged. Accumulation of radiopharmaceutical is uniformly reduced. The spleen is enlarged, actively accumulates pharmaceuticals.

1) What is the cause of these changes?

- A. Cirrhosis.
 - B. Cholelithiasis.
 - C. Heart failure.
 - D. Chronic hepatitis.
 - E. Steatosis.
- 2) Assign treatment.

Summary:

Recommended reading list

Basic literature:

- Harrison's Principles of Internal Medicine Self-Assessment and Board Review, 20th Edition 20th Edition.- (August 13, 2021). - 736 pages
- Pocket Medicine: The Massachusetts General Hospital Handbook of Internal Medicine / 007 edition (12 Sept. 2019). - 272 pages
- Davidson's Principles and Practice of Medicine: Enhanced Digital Version Included / Elsevier; 23rd edition (25 April 2018). - 1440 pages

Additional literature:

- Macleod's Clinical Examination /Elsevier; 14th edition (11 Jun. 2018). - 400 pages
- Current Medical Diagnosis and Treatment /McGraw-Hill Education; Updated edition (14 Sept. 2021). - 1840 pages
- Lippincott Connect Standalone Courseware for Bates' Guide to Physical Examination and History Taking 1.0 /LWW; 13th ed. edition (23 Mar. 2023).
- Step-Up to Medicine / Wolters Kluwer Health; 5th edition (8 May 2019). - 582 pages
- Goldman-Cecil Medicine, 2-Volume Set (Cecil Textbook of Medicine) / Elsevier; 26th edition (20 Dec. 2019). - 2944 pages
- The Washington Manual of Medical Therapeutics / Wolters Kluwer Health; 36th edition (6 Jun. 2019). - 1074 pages
- Harrison's Manual of Medicine / McGraw-Hill Education; 20th edition (5 Nov. 2019). - 1245 pages

Electronic information resources

- World Health Organization. URL: www.who.int/ru/index.html.
- European Regional Office of the World Health Organization. URL: www.euro.who.int.
- <https://www.aasld.org/>
- https://academic.oup.com/ndt/pages/General_Instruction
- <https://cprguidelines.eu/>
- <https://www.escardio.org/Guidelines/Clinical-Practice-Guidelines>
- <http://www.oxfordmedicaleducation.com/>
- <http://ard.bmj.com>
- <https://www.escardio.org/Guidelines/Clinical-Practice-Guidelines>

Topic 22. Management of a patient with hepatomegaly and hepatolienal syndrome.

The main goals: to acquire communication skills and skills of clinical examination of a patient with hepatomegaly, hepatolienal syndrome; to be able to establish a preliminary diagnosis, carry out a differential diagnosis and determine the clinical diagnosis of the disease in a patient with hepatomegaly, hepatolienal syndrome; master the principles of treatment, recommendations for lifestyle changes in the management of patients with hepatomegaly, hepatolienal syndrome; to diagnose emergency conditions in patients with hepatomegaly, hepatolienal syndrome; master the tactics of providing emergency medical care to patients with hepatomegaly, hepatolienal syndrome; to be able to perform therapeutic manipulations in patients with hepatomegaly, hepatolienal syndrome.

Key words: definition of hepatolienal syndrome; etiology, pathogenesis of HLS; liver diseases (acute hepatitis, chronic hepatitis, liver cirrhosis, liver cancer, benign tumors, liver cysts, echinococcus, tuberculosis, abscess); diseases of the hematopoietic system (acute leukemia, chronic myeloid leukemia, chronic lymphocytic leukemia, lymphogranulomatosis, lymphomas); storage diseases (hemochromatosis, hepatolenticular degeneration, amyloidosis); diseases of the cardiovascular system (insufficiency of blood circulation, constrictive pericarditis); clinical manifestations; mandatory laboratory and instrumental methods of diagnosis of diseases with HLS; additional research methods according to indications: computer tomography, liver biopsy; principles of treatment of diseases with HLS.

Equipment: multimedia materials - a set of thematic slides from the department's multimedia library; screenshots of the results of instrumental and laboratory tests (biochemical liver tests, coprogram, ultrasound of the abdominal cavity, ultrasound with choleretic breakfast, duodenal sounding, EGDS); a set of situational problems on the subject of the lesson.

Plan:

1. Organizational measures (greetings, verification of those present, announcement of the topic, purpose of the lesson, motivation of higher education seekers to study the topic)
2. Control of the reference level of knowledge (checking homework, written work, written testing, including writing KROK-2 tests, frontal survey)
3. Formation of professional abilities and skills (mastery of skills, curation, determination of treatment regimen, laboratory research, etc.): discussion of features of diagnosis and treatment of arterial hypertension, the most common clinical manifestations, criteria for establishing a diagnosis
4. Summing up (summarizing the topic, evaluating applicants, discussing the next lesson topic and homework).

The control question:

1. Determination of hepatomegaly and splenomegaly
2. Classification of diseases involving hepato- and hepatosplenomegaly. Differential diagnosis.
3. Analysis of patients with hepato- and splenomegaly
4. Basic biochemical syndromes in hepatitis and cirrhosis
5. Basic principles of treatment depending on the reasons hepatolienal syndrome or hepatomegaly
6. Hepatoprotectors and antiviral therapy
7. Standard therapy for patients with hepatolienal syndrome
8. Indications for surgical treatment
9. Primary and secondary prevention of diseases with an increase in the liver and spleen
10. Prognosis and ability to work with hepatolienal syndrome and hepatomegaly

MCQ's

1. Female 24 years old, complains of intense itching of the skin, especially in the evening, dull pain in the right hypochondrium. Ill for 2 years after delivery. Objective: jaundice, xanthelasma on the eyelids. Liver is palpated 6 cm below the right costal arch, its edge is thick, smooth and painless. The spleen is enlarged for 3 cm. Blood test for hepatitis B surface antigen is negative. Indicators of iron metabolism within the normal range. Which form of liver injury is most likely in the patient?

- A. Primary biliary cirrhosis
- B. Chronic hepatitis B.
- C. Chronic cholecystitis
- D. Hemochromatosis
- E. Fatty hepatosis

2. Female 46 years old, complains of dull pain in right hypochondrium, weakness, fatigue, itchy skin, periodic chills for 3 years. The pain is sometimes paroxysmal, accompanied by fever, increased itching. Objective: icterus of sclerae, body temperature is 37,5°C, the abdomen is moderately enlarged, painful in the right hypochondrium. Liver +3 cm, dense, painful. The spleen is not palpable. In blood test: Hb-121 g/L, Leu - $11,0 \times 10^9/L$, band neutrophils - 14%, ESR - 30 mm / h. What is the most likely diagnosis?

- A. Chronic cholangitis
- B. Chronic cholecystitis
- C. Hemolytic anemia
- D. Chronic hepatitis
- E. Cirrhosis

3. Patient 56 years presents moderate skin and sclerae icterus, the increase in the size of the liver and spleen. Three years ago was treated for hepatitis B. The examination revealed: HBsAg (+), HBeAg (+). High concentration of HBV DNA. Which of these drugs is a first-line drugs in the treatment of the disease?

- A. Prednisone
- B. Karsil
- C. PEG-interferon
- D. Vitogepat
- E. Essenciale-forte

4. Female 37 years old, contacted a doctor in because of exacerbation of chronic hepatitis. Blood test revealed increased indirect bilirubin, AST, ALT, and reduction of albumin and prothrombin. Which of the pathologic processes most likely caused these changes?

- A. Violation of hemostasis
- B. Cholestasis
- C. Portal hypertension
- D. Hypersplenism
- E. Cytolysis

5. Patient V., 51years old, many years abuses alcohol. Complaints of nausea, diarrhea, skin yellowness. Objectively: icterus of skin and sclerae, muscle atrophy, subfebrile fever. Liver +3 cm below the costal arch, painful on palpation. What method of diagnostics is considered a "gold standard" of diagnostics in this case?

- A. Immune activity test
- B. Markers of viral hepatitis.
- C. Puncture biopsy of the liver.
- D. Cytolysis activity (AST, ALT)
- E. Proteinogram

6. Patient T, 48 years old, complains of loss of appetite, heaviness in the epigastrium after eating, dull pain in right hypochondrium, which intensifies after a fatty meal; nausea, flatulence, weight loss. Objectively - yellow skin, spider veins, gynecomastia, ascites. Liver palpation is not painful, liver is firm, its edge is sharp; spleen is enlarged. Your preliminary diagnosis:

- A. Liver cirrhosis
- B. Chronic active hepatitis
- S. Acute hepatitis A
- D. Acute cholecystitis
- E. Acute pancreatitis

7. A 23 year old patient complains of pain in the right hypochondrium, periodically - belching, nausea, decrease of appetite. Three years ago had appendectomy. 2 months later developed jaundice, for which was treated in the infectious diseases department. Objectively: liver enlarged for 2 cm. In blood test:

total bilirubin - 36 micromol/liter, direct bilirubin - 14.9 micromol / liter, AsAT - 65 U/L, ALT - 135 U/L. What disease does the patient have?

- A. Benign jaundice Gilbert
- B. Chronic cholangitis
- C. Chronic cholecystitis
- D. Chronic hepatitis
- E. Cirrhosis

8. Patient 28 years, constantly works in contact with a complex of chemicals for 6 years. Complains of headache, increased fatigue, feeling of heaviness in the right hypochondrium, appetite loss, jaundice. Objectively: the skin and sclera are subicteric. Abdomen is enlarged, liver +5 cm, its surface is smooth. In the blood test: Hb - 110 g /L, Leu - $8,1 \times 10^9$ /L, ESR -30 mm / hour, total bilirubin - 65 micromol /L, glucose - 6.3 mmol / liter. What is the most likely diagnosis?

- A. Chronic pancreatitis
- B. Haemochromatosis
- C. Chronic toxic hepatitis
- D. Viral hepatitis
- E. Benign hyperbilirubinemia

9. A 42 y.o. man is ill with autoimmune hepatitis. Blood test: A/G ratio 0,8, bilirubin – 42 mmol/L, transaminase : ALT- 210 U/L, AST - 175 U/L. What is the most effective means in treatment from the given below?

- A. Glucocorticoids, cytostatics
- B. Antibacterial medication
- C. Hepatoprotectors
- D. Antiviral medications
- E. Hemosorption, vitamin therapy

10. A woman may be diagnosed with hepatitis if it is confirmed by the presence of elevated:

- A. WBCs
- B. ALT
- C. Alkaline phosphatase
- D. BUN
- E. Sedimentation rate

Clinical tasks:

Tasks N1.

Patient H., 58 years complained of constant weight in the right hypochondrium, the increase in the volume of the abdomen, swelling legs and feet, general weakness, shortness of breath. Sick of about 5 years old when he began to observe the gravity in the right hypochondrium, abdominal distension. In the last year have started to appear periodically swelling on my feet. Within 3 months began to increase in the volume of the stomach. In the past, abused alcohol. Objectively: the skin and sclera subicteric. The skin of the trunk isolated vascular asterisks. Language "varnished", a bright crimson color. The abdomen is increased in volume due to the presence of free fluid and bloating. The horizontal flattened. Liver 5 cm in favor from the edge of the right costal arch, the edge sharp, the surface of a thick, rough, painless. The spleen of 3 cm below the left costal arch. Edema legs and feet. Survey: obsch.an.krovi: Riyadh - 3,3 T / l, Hb, 126g / l, L-5, 6 g / l, ESR-18 mm / hour. Bilirubin total-27, 6 mmol / l, associated-14.6 mmol / l, free-13, 0 mmol / liter. AST-0, 7 mmol / h \times l, ALT-1, 2 mmol / h \times liter. Alkaline phosphatase-2.5 mmol / h \times liter. Total protein, 50 g / liter. Albumin 49% globulins: α 1 -3%, α 2 -8%, β - 10%, γ -20%. Urea-4, 5 mmol / liter. EGDS: varicose veins of the esophagus. Scintigraphy of the liver: liver diffusely enlarged. Accumulation of radiopharmaceutical is uniformly reduced. The spleen is enlarged, actively accumulates pharmaceuticals.

The control question:

- 1) What caused these changes?
- 2) Assign treatment.

Tasks N 2

Patient E., 32 years complained of heaviness in the right hypochondrium, itchy skin, yellow sclera and mucous membranes, weakness, weight loss of 10 kg during the year, periodically raising the temperature to subfebrile digits, dark urine, light-colored stool. Sick about 4 years old, when after childbirth has begun to increase the temperature periodically to subfebrile figures appeared and began to grow overall weakness and itching of the skin. Objectively: the skin and sclera subikterichny. On the traces of scratching the skin, eyelids xanthoma. Abdomen soft. The liver appears to 4cm from the edge of the right costal arch, dense, painful, edge sharpened. Spleen was not palpable. Survey: total bilirubin 95, 3mkmol / l; straight-43, 3mkmol / liter, indirect-52, 0 mmol / liter. AST-2, 76 mmol / h l, ALT-3.24 mmol / h l. Alkaline phosphatase-4.9 mmol / h liter. Total protein, 78 g / liter. Albumin 52% globulins: α 1-3%, α 2-6%, β -11%, γ -22%. Urea-5, 9 mmol / liter. Cholesterol 8.8 mmol / liter.

The control question:

- 1) What additional research will determine the cause of cholestasis?
- 2) Assign additional examination
- 3) Assign treatment.

Summary:

Recommended reading list

Basic literature:

- Harrison's Principles of Internal Medicine Self-Assessment and Board Review, 20th Edition 20th Edition.- (August 13, 2021). - 736 pages
- Pocket Medicine: The Massachusetts General Hospital Handbook of Internal Medicine / 007 edition (12 Sept. 2019). - 272 pages
- Davidson's Principles and Practice of Medicine: Enhanced Digital Version Included / Elsevier; 23rd edition (25 April 2018). - 1440 pages

Additional literature:

- Macleod's Clinical Examination /Elsevier; 14th edition (11 Jun. 2018). - 400 pages
- Current Medical Diagnosis and Treatment /McGraw-Hill Education; Updated edition (14 Sept. 2021). - 1840 pages
- Lippincott Connect Standalone Courseware for Bates' Guide to Physical Examination and History Taking 1.0 /LWW; 13th ed. edition (23 Mar. 2023).
- Step-Up to Medicine / Wolters Kluwer Health; 5th edition (8 May 2019). - 582 pages
- Goldman-Cecil Medicine, 2-Volume Set (Cecil Textbook of Medicine) / Elsevier; 26th edition (20 Dec. 2019). - 2944 pages
- The Washington Manual of Medical Therapeutics / Wolters Kluwer Health; 36th edition (6 Jun. 2019). - 1074 pages
- Harrison's Manual of Medicine / McGraw-Hill Education; 20th edition (5 Nov. 2019). - 1245 pages

Electronic information resources

- World Health Organization. URL: www.who.int/ru/index.html.
- European Regional Office of the World Health Organization. URL: www.euro.who.int.
- <https://www.aasld.org/>
- https://academic.oup.com/ndt/pages/General_Instruction
- <https://cprguidelines.eu/>
- <https://www.escardio.org/Guidelines/Clinical-Practice-Guidelines>
- <http://www.oxfordmedicaleducation.com/>
- <http://ard.bmj.com>
- <https://www.escardio.org/Guidelines/Clinical-Practice-Guidelines>

Practical class

Topic 23. Management of a patient with urinary syndrome.

The main goals: to acquire communication skills and skills of clinical examination of a patient with urinary syndrome ; be able to establish a preliminary diagnosis, carry out a differential diagnosis and determine the clinical diagnosis of the disease in a patient with urinary syndrome ; master the

principles of treatment, recommendations for lifestyle changes in the management of patients with urinary syndrome; to diagnose emergency conditions in patients with urinary syndrome; master the tactics of providing emergency medical care to patients with urinary syndrome; to be able to perform therapeutic manipulations in patients with urinary syndrome.

Key words:etiology, pathogenesis, pathomorphology, clinical features of the course of diseases accompanied by the development of urinary syndrome (acute and chronic glomerulonephritis, urolithiasis, pyelonephritis, heart failure with "congestive kidney", diabetic nephropathy, hypernephroma, cystitis, bladder cancer, hemorrhagic vasculitis); laboratory-instrumental signs of the diseases listed above; formulation of the preliminary diagnosis of the disease in the monitored patient; an examination plan for the monitored patient, aimed at clarifying the diagnosis and carrying out a differential diagnosis for the leading urinary syndrome; interpretation of the results of laboratory and instrumental studies in a supervised patient; peculiarities of urinary syndrome in patients; tactics of treatment of a patient with urinary syndrome and evaluation of the prognosis of the disease.

Equipment:multimedia materials - a set of thematic slides from the department's multimedia library; screenshots of the results of laboratory (ZAS, three-cup Thompson test, urine analysis according to Nechiporenko, Amburger and Addis-Kakovsky, test according to Zemnytskyi) and instrumental (ultrasound and CT of kidneys, bladder) studies; a set of situational problems on the subject of the lesson.

Plan:

- Organizational measures (greetings, verification of those present, announcement of the topic, purpose of the lesson, motivation of higher education seekers to study the topic).
- Control of the reference level of knowledge (checking homework, written work, written testing, including writing KROC-2 tests, frontal survey)
- Formation of professional abilities and skills (mastery of skills, curation, determination of the treatment scheme, laboratory research, etc.): discussing the specifics of diagnosis and treatment of patients with urinary syndrome, the most common clinical manifestations, criteria for establishing a diagnosis
- Summing up (summarizing the topic, evaluating applicants, discussing the next lesson topic and homework)

The control question:

1. Please define urinary syndrome
2. Characteristics of urinary syndrome.
3. Conduct a differential diagnosis for hematuria, proteinuria and leukocyturia.
4. Tactic in patients with bladder syndrome, depending on the reason.
5. Causes of urinary syndrome in urinary tract diseases.
6. The role of laboratory test methods to clarify the diagnosis in the urinary syndrome (general and biochemical tests, urine tests by Nechiporenko, Zymnytsky, etc.).
7. The role of instrumental diagnostic methods to clarify the diagnosis in the urinary syndrome (ultrasound, X-ray, EKG, etc.).
8. The basic principles of pharmacological and non-pharmacological treatment of patients with bladder syndrome, depending on the reason.
9. Primary and secondary prevention.
10. Weather and performance in patients with bladder syndrome.

Tests:

1. Patient 18 years old, complains of general weakness, pain in the lumbar area. Two weeks ago I suffered from tonsillitis. BP -135/85 mm Hg. Urinalysis: protein - 1.65 g/L, Er - 10-15 in the field of view; hyaline cylinders - 8-10 in the field of view. Blood test: creatinine - 0.09 mmol / L, urea - 5.3 mmol / L. Which syndrome points out to the main illness?
A. Hypertensive Syndrome

B. Nephrotic syndrome

C. Uremic syndrome

D. Urinary syndrome

E. Astheno-vegetative syndrome

2. A 56 yo female patient complains of aching pain in the lumbar region, which is getting worse after standing in an upright position, physical exercise, supercooling. The patient also reports experiencing weakness in the afternoon. Episodes of pain in the lumbar area appeared for the last 10 years. Objectively: pale skin, t° - 37.4°C, BP - 180/100 mm Hg, minor costovertebral angle tenderness (Pasternatsky symptom). In blood: RBCs - $3.5 \times 10^{12}/L$, WBCs - $6.5 \times 10^9/L$, ESR - 23 mm/h. In urine: the relative density - 1010, leukocytes - 12-15 in the field of vision, erythrocytes - 2-3 in the field of vision. Urine bacterial count - 100,000 in 1 mL. What is the most likely diagnosis?

A. Chronic glomerulonephritis

B. Nephrolithiasis

C. Polycystic renal disease

D. Chronic pyelonephritis

E. Amyloidosis

3. A 35-year-old patient was on regular hemodialysis because of chronic glomerulonephritis in the last 3 years. Recently hospitalized because of progressive heart failure, hypotension, weakness, shortness of breath. On the ECG: bradycardia, 1st degree AV-block, high sharp "T" waves. In anamnesis - violation of a dietary regime. What biochemical changes may be the reason for the patient's current deterioration?

A. Hypernatremia

B. Hypocalcemia

C. Hyperkalemia

D. Hypokalemia

E. Hyperhydration

4. A patient with acute respiratory viral infection (3rd day of illness) complains of pain in the lumbar region, nausea, dysuria, oliguria. Urinalysis - hematuria (100-200 RBC in the field of view), specific gravity - 1002. The blood creatinine level is 0.18 millimole/l, potassium level - 6.4 millimole/l. Make the diagnosis:

A. Acute renal colic

B. Acute renal failure

C. Acute interstitial nephritis

D. Acute cystitis

E. Acute glomerulonephritis

5. A 36 yo patient got sick a week ago after hypothermia, symptoms included high fever, chills, profuse hyperhidrosis. Later dull back pain, unpleasant sensation when urinating appeared. Objective: prominent lumbar muscle tension, positive Pasternatsky symptom on both sides. In general blood count: leukocytosis up to $12 \times 10^9/L$, neutrophilosis. In urinalysis - protein 0.6 g/L, leukocytes in the entire field of view, bacteria - $1 \times 10^9/mL$. Your preliminary diagnosis?

A. Acute pyelonephritis

B. Kidney tuberculosis

C. Acute glomerulonephritis

D. Acute cystitis

E. Kidney stone disease

6. Patient 18 years old, complains of BP = 200/120 mm Hg., increase of night urine amount. A history of frequent tonsillitis. Objective: BP on hands - 160/100 mm Hg., on feet - 180/120 mm Hg. Urinalysis: specific gravity - 1008, protein - 0.99 g/L, Er - 10-20 in the field of view; different cylinders - 8-10 in the field of view. Changes in urine were first detected 10 years ago, hypertension was observed for 2 years. What is the most likely cause of arterial hypertension?

A. Chronic pyelonephritis

B. Chronic glomerulonephritis

C. Essential hypertension

D. Coarctation of aorta

E. Fibromuscular dysplasia of renal arteries

7. A young 16 yo male is administered 2 weeks after vaccination against diphtheria with complaints of facial swelling. No objective changes of the cardiovascular system, lungs, digestive system were detected. In blood test: Hb -148 g/L, Leuk - $10 \times 10^9/L$, ESR - 32 mm/hr., creatinine - 0.095 mmol/L. In urine: protein - 4.5 g/L, Leuk. - 2-3 in field of view, Er. - 25-30 in the field of view. Indicate the most likely mechanism that caused kidney damage:

- A. Toxic effects of the vaccine in renal glomeruli
- B. Damage of glomeruli by immune complexes
- C. Effect of specific antibodies in the kidney tubules
- D. Immediate type allergic reaction
- E. Delayed type of allergic reaction

8. Patients 18 years old, admitted to the hospital with significant edema, which appeared two weeks after the patient had a sore throat. Increased BP of 160/110 mm Hg. was detected. Previously had no diseases. What changes can be detected in urinary sediment?

- A. Moderate proteinuria, hyaline casts
- V. Proteinuria, leukocyturia
- S. Microhematuria, crystalluria
- D. Significant proteinuria, hematuria
- E. Macrohematuria, leukocyturia

9. A 40 yo man complains of headache in the occipital area. On physical examination: the skin is pale; face and hand edema, BP - 170/130 mm Hg. On EchoCG: concentric hypertrophy of the left ventricle. Ultrasound examination of the kidneys reveals a thinned cortical layer. Urine analysis shows proteinuria of 3.5 g/day. What is the probable diagnosis?

- A. Essential arterial hypertension
- B. Chronic pyelonephritis
- C. Chronic glomerulonephritis
- D. Polycystic disease of the kidneys
- E. Cushing's disease

10. 52-year-old female suffers from bronchiectasis for more than 10 years. Complaints of cough with purulent sputum, increased body temperature of $37.8^\circ C$. Pale, marked edema of face and shins. Urinalysis - protein - 1.02 grams/day, Leuk - 6-8 in the field of view, Er. - 3-5 in the field of view. What complication of bronchoectatic disease should you suspect?

- A. Chronic pyelonephritis
- B. Lung abscess
- C. Infectious glomerulonephritis
- D. Nephrotic syndrome
- E. Renal amyloidosis

Clinical tasks:

Tasks N 1.

Patient 35 years, turned over the almost constant subfebrile temperature within 4 months, stubborn pain in the lumbar area. Suffering from chronic pharyngitis. At objective: pale, height 168cm, weight 59kg. Edema of face and shins. BP - 160/100 mm Hg. century. Heart rate 78 per min. Daily diuresis - 1300 ml. Diuresis at night 650 ml. Urinalysis: specific weight - 1012, white - 0.065 g / l, L. - 20-35 in the p / s, Er. - 1-3 in the p / of.

The control question:

1. What is your preliminary diagnosis?
2. What test methods to assign to establish the final diagnosis?
3. Write a letter for the treatment of this patient.

Tasks N 2.

Patient 23 years old, approached the clinic with complaints of headache, poor vision, shortness of breath, general weakness, decreasing the number of selected per day to 1 liter of urine, change in urine (urine in the form of "meat slop). Three weeks ago, moved angina. OBJECTIVE: moderate pallor,

puffyface, swollen eyelids, heart rhythmic activity, and tone at the top depressed, beat. Pulse - 66/hv. SC - 175/105 mm Hg. century. Pasternatsky symptom weak positive on both sides. In the analysis of urine: protein - 1.48 grams per liter, Er. - 35-40 in the p / s, altered, LA - 8-10 in the p / of.

The control question:

1. What is the most likely diagnosis?
2. Specify main syndromes observed in patients.
3. Your recommendations for secondary prevention of disease.

Tasks N3.

Patient T., 23 years old, appealed to the district internist with complaints of general weakness, headache, swelling of the legs. Ill 5 years after hypothermia with appeared swelling of the legs, face, weakness, changes in the urine. Twice was treated in hospital. Objectively: swelling of the face and legs. In the lung - respiration vesicular, landmark heart unchanged. Heart tones loud, pulse 80 per min., rhythmic. SC 160/100 mm Hg. century. Dysuria. Pasternatsky sm negative on both sides. ZAK: HB - 100 g / l, L. -7.5 x10⁹ / l, ESR - 26 mm / hr. Urinalysis: densities - 1007, protein - 0.99 g / l, Er. - 1-3 in sight, L - 5- 10 in sight, hyaline and granular cylinders 6.8 in sight.

The control question:

1. What is the most likely diagnosis?
2. What is the cause of edema in the patient?
3. Make an examination and treatment plan.

Summary:

Recommended reading list

Basic literature:

- Harrison's Principles of Internal Medicine Self-Assessment and Board Review, 20th Edition 20th Edition.- (August 13, 2021). - 736 pages
- Pocket Medicine: The Massachusetts General Hospital Handbook of Internal Medicine / 007 edition (12 Sept. 2019). - 272 pages
- Davidson's Principles and Practice of Medicine: Enhanced Digital Version Included / Elsevier; 23rd edition (25 April 2018). - 1440 pages

Additional literature:

- Macleod's Clinical Examination /Elsevier; 14th edition (11 Jun. 2018). - 400 pages
- Current Medical Diagnosis and Treatment /McGraw-Hill Education; Updated edition (14 Sept. 2021). - 1840 pages
- Lippincott Connect Standalone Courseware for Bates' Guide to Physical Examination and History Taking 1.0 /LWW; 13th ed. edition (23 Mar. 2023).
- Step-Up to Medicine / Wolters Kluwer Health; 5th edition (8 May 2019). - 582 pages
- Goldman-Cecil Medicine, 2-Volume Set (Cecil Textbook of Medicine) / Elsevier; 26th edition (20 Dec. 2019). - 2944 pages
- The Washington Manual of Medical Therapeutics / Wolters Kluwer Health; 36th edition (6 Jun. 2019). - 1074 pages
- Harrison's Manual of Medicine / McGraw-Hill Education; 20th edition (5 Nov. 2019). - 1245 pages

Electronic information resources

- World Health Organization. URL: www.who.int/ru/index.html.
- European Regional Office of the World Health Organization. URL: www.euro.who.int.
- <https://www.aasld.org/>
- https://academic.oup.com/ndt/pages/General_Instruction
- <https://cprguidelines.eu/>
- <https://www.escardio.org/Guidelines/Clinical-Practice-Guidelines>
- <http://www.oxfordmedicaleducation.com/>
- <http://ard.bmj.com>
- <https://www.escardio.org/Guidelines/Clinical-Practice-Guidelines>

Practical class

Topic 24. Management of a patient with nephrotic syndrome

The main goals: to acquire communication skills and skills of clinical examination of a patient with nephrotic syndrome ; to be able to establish a preliminary diagnosis, carry out a differential diagnosis and determine the clinical diagnosis of the disease in a patient with nephrotic syndrome ; master the principles of treatment, recommendations for lifestyle changes in the management of patients with nephrotic syndrome ; to diagnose emergency conditions in patients with nephrotic syndrome; master the tactics of providing emergency medical care to patients with nephrotic syndrome; to be able to perform therapeutic manipulations in patients with nephrotic syndrome.

Key words: main risk factors, etiology and pathogenesis of nephrotic syndrome; clinical symptomatology of nephrotic syndrome with different nosologies; methods of diagnosing nephrotic syndrome; the main syndromes of diseases, with which it is necessary to differentiate nephrotic syndrome; basic principles of differentiated treatment, prevention and rehabilitation of patients with nephrotic syndrome; principles of providing emergency care for nephrotic crises.

Equipment: multimedia materials - a set of thematic slides from the department's multimedia library; screenshots of the results of laboratory (CBC, three-cup Thompson test, urine analysis according to Nechiporenko, Amburger and Addis-Kakovsky, test according to Zemnytskyi) and instrumental (ultrasound and CT of kidneys, bladder) studies ; a set of situational problems on the subject of the lesson.

Plan:

- Organizational measures (greetings, verification of those present, announcement of the topic, purpose of the lesson, motivation of higher education seekers to study the topic).
- Control of the reference level of knowledge (checking homework, written work, written testing, including writing KROC-2 tests, frontal survey)
- Formation of professional abilities and skills (mastery of skills, curation, determination of the treatment scheme, laboratory research, etc.): discussing the specifics of diagnosis and treatment of patients with urinary syndrome , the most common clinical manifestations, criteria for establishing a diagnosis
- Summing up (summarizing the topic, evaluating applicants, discussing the next lesson topic and homework)

The control questions:

1. What can aggravate the patient's condition? Hypertensive crises.
2. List syndromes that can be found in the patient.
3. Write the plan for treatment, emergency assistance in complications.
4. Give the definition of nephrotic syndrome.
5. Etiology, pathogenesis of nephrotic syndrome.
6. What diseases are accompanied by nephrotic syndrome, diagnostic criteria, differential diagnosis.
7. Clinical manifestations in diseases accompanied by nephrotic syndrome.
8. Tactics of managing the patient with nephrotic syndrome, depending on the reason.
9. The role of laboratory methods of investigation to clarify the diagnosis with nephrotic syndrome.
10. The role of instrumental diagnostic methods to clarify the diagnosis in the nephrotic syndrome.
11. The basic principles of pharmacological and non-pharmacological treatment of patients with nephrotic syndrome. The standards of treatment.
12. Primary and secondary prevention.
13. Weather and performance in patients with nephrotic syndrome.

Tests

1. A 54-year-old patient has an over 20-year history of femoral osteomyelitis. Over the last month she has developed progressive edema of the lower extremities. Urine test reveals: proteinuria at the rate of 6.6 g/l; in blood: dysproteinemia in the form of hypoalbuminemia, increase in alpha-2- and gamma-

globulin rate, ESR - 50 mm/h. What is the most likely diagnosis?

- A. Secondary renal amyloidosis
- B. Acute glomerulonephritis
- C. Myelomatosis
- D. Chronic glomerulonephritis
- E. Systemic lupus erythematosus

2. A 25-year-old man complains about face edematous, headache, dizziness, reduced urination, change of urine color (dark-red). These presentations appeared after pharyngitis. Objectively: face edematous, pale skin, temperature - 37.4°C; heart rate - 86/min, AP - 170/110 mm Hg. Heart sounds are muffled, the II sound is accentuated above the aorta. What etiological factor is probable in this case?

- A. Saprophytic staphylococcus
- B. Pyogenic streptococcus
- C. Beta-hemolytic streptococcus
- D. Staphylococcus aureus
- E. Alpha-hemolytic streptococcus

3. A 30-year-old patient 2 weeks after recovering from angina noticed edematous face, weakness, decreased work performance. There was gradual progress of dyspnea, edematous of the lower extremities, lumbar spine. Objectively: pale skin, weakening of the heart sounds, anasarca. AP - 160/100 mm Hg. In urine: the relative density - 1021, protein - 5 g/l, erythrocytes - 20-30 in the field of vision, hyaline cylinders - 4-6 in the field of vision. What is the most likely diagnosis?

- A. Acute glomerulonephritis
- B. Essential hypertension
- C. Acute pyelonephritis
- D. Infectious allergic myocarditis
- E. Myxedema

4. A 47-year-old male developed widespread edema during the last two months. In history - 10 years of treatment for pulmonary tuberculosis. Objectively: puffy face, swelling of legs and waist. BP - 130/80 mm Hg. Blood: Er. - 3.0×10^{12} /L, Leu. - 4.5×10^9 /L, ESR - 50 mm / hr. Total protein - 60 g/L, albumin - 42%, globulins - 58%, total cholesterol - 7.2 mmol /L. Urinalysis: specific weight - 1020, Er. - 1-2 in the field of view, Leu - 4-5 in the field of view, hyaline casts - 2-4 in the field of view; protein loss - 3.5 g / day. What is the most likely diagnosis?

- A. Renal vein thrombosis
- B. Chronic glomerulonephritis
- C. Acute glomerulonephritis
- D. Renal amyloidosis
- E. Chronic pyelonephritis

5. A patient 17 years, complained of pronounced swelling of the face and extremities that had appeared 3 weeks ago. Six months ago was treated in the infectious disease department because of jaundice. Objectively: skin is pale, face and legs are swollen. Liver edge is 2 cm below costal arch. Urinalysis: specific weight - 1020, protein - 4.4 g /L, Er. - 8-10 in the field of view. Daily diuresis - 0.6 liters. Blood protein - 52 grams per liter. Blood Na + - 138 mmol/L. What is the most likely mechanism of edema?

- A. Cirrhosis
- B. Retention of sodium
- C. Reduction of kidney concentrating function
- D. Significant release of antidiuretic hormone
- E. Hypoproteinemia

6. A male patient presents with swollen ankles, face, eyelids, elevated BP - 160/100 mm Hg, pulse - 54 bpm, daily loss of albumin with urine - 4g. What therapy is pathogenetic in this case?

- A. Corticosteroids
- B. Diuretics
- C. NSAIDs
- D. Calcium antagonists
- E. Antibiotics

7. A 26 yo patient complains of nausea, vomiting, headache, shortness of breath. He had an acute nephritis being 10 yo Proteinuria was found out in urine. Objectively: a skin is gray-pale, the edema is not present. Accent of II tone above aorta. BP 140/100-180/100 mm Hg. Blood level of residual N2 - 6.6 mmol/L, creatinine - 406 mmol/L. Day's diuresis - 2300 ml, nocturia. Specific density of urine is 1009, albumin - 0.9 g/L, WBC - 0-2 in f/vis. RBC - single in f/vis., hyaline casts single in specimen. Your diagnosis?

- A. Chronic nephritis with violation of kidney function
- B. Pheochromocytoma
- C. Hypertensive illness of the II degree
- D. Nephrotic syndrome
- E. Stenosis of kidney artery

8. Patient 41 years old suffers from severe type 1 diabetes for 28 years. Admitted to the Endocrinology Department with feet edema, BP of 210/140 mm.Hg. General condition is serious. Skin is pale. Acrocyanosis. Daily diuresis 4 liters. Urinalysis: specific gravity - 1024; protein - 12.6 g / L, Leu. - 1-4 in the field of view; Er. - 3-4 in the field of view. In the blood - cholesterol 6.8 mmol/L, urea - 7.9 mmol/L. What syndrome is present in this case?

- A. Nephrotic
- B. Urinary
- C. Nephritic
- D. Acute renal failure
- E. Chronic renal failure

9. Male 25 years old complains of weakness, breathlessness and swelling of both feet. Previously was healthy, last medication taken - ibuprofen due to knee injury. Objectively: Ps-90/min., Bp-180/100 mm Hg. Heart tones are loud. Dull percussion sound above the lower segments of the right lung. Liver +3 cm. General blood: Er. - $4.0 \cdot 10^{12}$ /L, Hb-103 g/L, Leuk.- $6.7 \cdot 10^9$ /L, Plt.- $236 \cdot 10^9$ /L, urea - 24.6 mmol/L, Creatinine - 0.254 micromole/L, Na+ - 135 mmol /L, K + - 5.6 mmol /L, albumin - 27 grams per liter. Chest X-Ray: right-sided pleurisy, heart shadow is normal. Your preliminary diagnosis?

- A. Acute pyelonephritis
- B. Nephritic syndrome
- C. Tuberculosis of kidneys
- D. Acute renal failure
- E. Nephrotic syndrome

10. A 28-year-old patient undergoes a course of treatment due to chronic glomerulonephritis. The treatment was successful, normalization of all the characteristics was recorded. What sanatorium and health resort treatment could be recommended?

- A. Not recommended
- B. The south coast of the Crimea
- C. Morshyn
- D. Myrhorod
- E. Truskavets

Clinical tasks

Task #1 .

Patient M. 23 R., complains of severe headache, pain in the lumbar area, swelling under the eyes and feet, general weakness. A month ago, moved paratonsillar abscess. OBJECTIVE: Pale skin, swelling face and legs. SC - 180/110 mm Hg. century. The limits of normal heart, normal cardiac impulse characteristics. Heart tones loud, clear, focus on aorta. In general, urine analysis: specific weight - 1025, protein - 3.2 grams. / L, Er. changed - 10-15 in the field of view, L - 3-5 in the field of view, hyaline cylinders - 1-3 in the field of view, daily diuresis - 400 ml.

The control questions:

1. Your preliminary diagnosis? Acute glomerulonephritis
2. Which test should be done for the final diagnosis?
3. Principles of pharmacological and non-pharmacological treatment of the patient.

Task No. 2.

Patient P., 42 years old. Complaints of cough with purulent sputum allocation abundant nature, sometimes with an admixture of blood, weakness, headaches. Over 5 years constant cough concerned with periodic exacerbation. Smoking. OBJECTIVE: low power, paleness, skin and mucous membranes, face puffiness, swelling shins. Fingers in clubbed. In the lungs: The box percussion sound of touch, hard breathing, different calibers moist crepitation over the lower right. Respiration rate 22 per minute. Pulse 80 per minute, rhythmical. SC 95/70 mm Hg. century.

General blood: HB - 98 December. / L, L. - $9.6 \times 10^9 / l$, ESR - 45 mm / hr. Protein - 58 grams. / L. Urinalysis: Densities - 1016, protein - 3.4 grams. / L, L. - 10-13 in P. height.,Er. 1.2 in S / height., Hyaline cylinders - 1-2 in S / height.

The control questions:

1. Your preliminary diagnosis?
2. Which method is the most informative study to clarify the diagnosis?
3. What to include secondary prevention in this patient?

Task No. 3.

Patient M, 26 years old, is in the therapeutic department with acute glomerulonephritis. Regular doctor complains of strong headaches in the back of the head, nausea, vomiting single. OBJECTIVE: the skin and visible mucous membranes pale face edematous. Pulse 56 per min., Stress, rhythm. SC 190/120 mmHg Left heart border shifted left by 2 cm Tones heart rhythm, accent 2 tone over aorta. Vesicular breath. Pasternatsky positive symptom on both sides.

The control questions:

Your preliminary diagnosis?

2. Which method is the most informative study to clarify the diagnosis?
3. What to include secondary prevention in this patient?

Summary:**Recommended reading list****Basic literature:**

- Harrison's Principles of Internal Medicine Self-Assessment and Board Review, 20th Edition 20th Edition.- (August 13, 2021). - 736 pages
- Pocket Medicine: The Massachusetts General Hospital Handbook of Internal Medicine / 007 edition (12 Sept. 2019). - 272 pages
- Davidson's Principles and Practice of Medicine: Enhanced Digital Version Included / Elsevier; 23rd edition (25 April 2018). - 1440 pages

Additional literature:

- Macleod's Clinical Examination /Elsevier; 14th edition (11 Jun. 2018). - 400 pages
- Current Medical Diagnosis and Treatment /McGraw-Hill Education; Updated edition (14 Sept. 2021). - 1840 pages
- Lippincott Connect Standalone Courseware for Bates' Guide to Physical Examination and History Taking 1.0 /LWW; 13th ed. edition (23 Mar. 2023).
- Step-Up to Medicine / Wolters Kluwer Health; 5th edition (8 May 2019). - 582 pages
- Goldman-Cecil Medicine, 2-Volume Set (Cecil Textbook of Medicine) / Elsevier; 26th edition (20 Dec. 2019). - 2944 pages
- The Washington Manual of Medical Therapeutics / Wolters Kluwer Health; 36th edition (6 Jun. 2019). - 1074 pages
- Harrison's Manual of Medicine / McGraw-Hill Education; 20th edition (5 Nov. 2019). - 1245 pages

Electronic information resources

- World Health Organization. URL: www.who.int/ru/index.html.
- European Regional Office of the World Health Organization. URL: www.euro.who.int.
- <https://www.aasld.org/>
- [https://academic.oup.com/ndt/pages/General Instruction](https://academic.oup.com/ndt/pages/General_Instruction)
- <https://cprguidelines.eu/>
- <https://www.escardio.org/Guidelines/Clinical-Practice-Guidelines>

- <http://www.oxfordmedicaleducation.com/>
- <http://ard.bmj.com>
- <https://www.escardio.org/Guidelines/Clinical-Practice-Guidelines>

Practical class

Topic 25. Management of a patient with chronic kidney disease.

The main goals: to acquire communication skills and skills of clinical examination of a patient with chronic kidney disease ; to be able to establish a preliminary diagnosis, carry out a differential diagnosis and determine the clinical diagnosis of the disease in a patient with chronic kidney disease ; master the principles of treatment, recommendations for lifestyle changes in the management of patients with chronic kidney disease ; diagnose emergency conditions in patients with chronic kidney disease; master the tactics of providing emergency medical care to patients with chronic kidney disease; to be able to perform therapeutic manipulations in patients with chronic kidney disease.

Key words: definition of the term chronic kidney disease (CKD); modern classification of CKD; clinical and diagnostic criteria of the main nosologies included in CKD; basic instrumental and laboratory research methods that prove the presence of CKD; principles of differential treatment of CKD, depending on the causes and stage; methods of primary and secondary prevention of CKD, prognosis.

Equipment: multimedia materials - a set of thematic slides from the department's multimedia library; screenshots of the results of laboratory (CBC, three-cup Thompson test, urine analysis according to Nechiporenko, Amburger and Addis-Kakovsky, test according to Zemnytskyi) and instrumental (ultrasound and CT of kidneys, bladder) studies ; a set of situational problems on the subject of the lesson.

Plan:

- Organizational measures (greetings, verification of those present, announcement of the topic, purpose of the lesson, motivation of higher education seekers to study the topic).
- Control of the reference level of knowledge (checking homework, written work, written testing, including writing KROC-2 tests, frontal survey)
- Formation of professional abilities and skills (mastery of skills, curation, determination of the treatment scheme, laboratory research, etc.): discussing the specifics □ of diagnosis and treatment of patients with urinary syndrome , the most common clinical manifestations, criteria for establishing a diagnosis
- Summing up (summarizing the topic, evaluating applicants, discussing the next lesson topic and homework)

The control question:

1. Definition and classification of chronic renal failure
2. Etiological factors
3. Characterize the term "chronic kidney disease".
4. Pathogenesis of lesions of organs and systems in CKD, their clinical manifestations.
5. Clinical and laboratory parameters change depending on the stage of CKD.
6. Differential treatment at different stages of CKD.
7. Substitution therapy: hemodialysis, kidney transplantation.
8. Indications and contraindications for dialysis, complications.
9. Primary and secondary prevention.
10. Prognosis in patients with CKD.

Tests

1. A 24 yo patient complains of nausea, vomiting, headache, shortness of breath. He had an acute

nephritis being 10 yo Proteinuria was found out in urine. Objectively: a skin is gray-pale, the edema is not present. Accent of II tone above aorta. BP 140/100-180/100 mm Hg. Blood level of residual N2 - 6.6 mmol/L, creatinine – 406mmol/L. Days diuresis - 2300 ml, nocturia. Specific density of urine is 1009, albumin - 0.9 g/L, WBC - 0-2 in f/vis. RBC.- single in f/vis., hyaline casts single in specimen. Your diagnosis?

- A. Pheochromocytoma
- B. Chronic nephritis with violation of kidney function
- C. Stenosis of kidney artery
- D. Nephrotic syndrome
- E. Hypertensive illness of the II degree

2. A 69-year-old female patient complains of temperature rise up to 38.3°C, haematuria. ESR - 55 mm/h. Antibacterial therapy turned out to be ineffective. What diagnosis might be suspected?

- A. Renal cancer
- B. Polycystic renal disease
- C. Renal amyloidosis
- D. Chronic glomerulonephritis
- E. Urolithiasis

3. Female 48 years old, complains of weakness, weight loss, reduced appetite, headache. In childhood suffered acute glomerulonephritis. Since 25 years has hypertension, medical treatment is not systematic, rarely visits her physician for checkups. Examination revealed signs of chronic kidney failure (plasma creatinine - 0.23 mmol / L). What are the most appropriate diet recommendations for this patient? A. Reducing the amount of fluid B. Limitations of fat C. Limitations of carbohydrates D. Protein Bread E. Limits of proteins

4. A 74-year-old patient after operation due to holecystectomy was prescribed gentamicin (80 mg every 8 hours) and cephalothin (2 g every 6 hours) due to fever. In 10 days there was an increase of creatinine up to 310 μmol/L. BP - 130/80 mm Hg, daily amount of urine is 1200 mL. Urine tests are without pathology. Ultrasound: the size of the kidneys is normal. What is the most likely reason for renal failure?

- A. Unequal infusion of the liquid
- B. Acute glomerulonephritis
- C. Cortical necrosis of kidneys
- D. Nephrotoxicity of gentamicin
- E. Hepatorenal syndrome

5. A 37-year-old patient was brought to the resuscitation unit. General condition of the patient is very serious. Sopor. The skin is gray, moist. Turgor is decreased. Pulse is rapid, intense. BP - 160/110 mm Hg, muscle tone is increased. Hyperreflexia. There is an ammonia odor in the air. What is the presumptive diagnosis?

- A. Uraemic coma
- B. Alcoholic coma
- C. Hyperglycemic coma
- D. Hypoglycemic coma
- E. Cerebral coma

6. A 35-year-old patient has been in the intensive care unit for acute renal failure due to a car accident for 4 days. Objectively: the patient is inadequate. Breathing rate - 32/min. Over the last 3 hours, individual moist rales can be auscultated in the lungs. ECG shows high "T" waves, right ventricular extrasystoles. CVP - 159 mm Hg. In blood: the residual nitrogen - 62 millimole/l, K⁺ - 7.1 millimole/l, Cl⁻ - 78 millimole/l, Na⁺ - 120 millimole/l, Ht - 0.32, Hb - 100 g/l, blood creatinine - 0.9 millimole/l. The most appropriate method of treatment would be:

- A. Plasma filtration
- B. Plasma sorption
- C. Hemosorption
- D. Hemodialysis
- E. Ultrafiltration

7. A 30-year-old woman suffers from polycystic kidney disease. She has been admitted with signs of

fatigue, thirst and nocturia. Diuresis is up to 1800 ml per day. BP is 200/100 mm Hg. Blood test: erythrocytes $1,8 \cdot 10^9 / l$, Hb - 68 g/l. Urine analysis: specific gravity - 1005, leukocytes - 50-60, erythrocytes - 3-5 in the vision field, creatinine - 0.82 mmol/l, potassium - 6.5 mmol/l, glomerular filtration rate - 10 ml/min. What tactics would be leading in the patient's treatment?

- A. Hemodialysis
- B. Antibacterial therapy
- C. Sorbent agents
- D. Blood transfusion
- E. Hypotensive therapy

8. A 30-year-old woman with a long history of chronic pyelonephritis complains about considerable weakness, sleepiness, decrease in diuresis down to 100 ml per day. AP- 200/120 mm Hg. In blood: creatinine - 0.62 millimole/l, hypoproteinemia, albumins - 32 g/l, potassium - 6.8 millimole/l, hypochromic anemia, increased ESR. What is the first step in patient treatment tactics?

- A. Hemodialysis
- B. Antibacterial therapy
- C. Enterosorption
- D. Haemosorption
- E. Blood transfusion

9. Male, 42 years old, complains of dry mouth, weakness, reduction of daily urine. Sick with chronic glomerulonephritis for 11 years. In the blood test: Hb - 90 g/L, calcium - 1.9 mmol / l, creatinine - 400 micromoles/L, urine protein - 1.2 g / day. What complications did the patient develop?

- A. nephrotic syndrome
- B. iron deficiency anemia
- C. Chronic renal failure III st.
- D. Chronic renal failure I st.
- E. Chronic renal failure II st.

10. 60 years old male complains of headache, dry mouth, thirst. Objective: Pulse - 86/min. BP -140/80 mm Hg. Pasternatsky symptom weakly positive on the right. Blood creatinine – 0.368 mmol/L. GFR = 38 ml/min. Urinalysis: specific gravity - 1008, protein - 0.198 g/L, Leuk - 30 in the vision field, Er.alkiline - 6-8 in the vision field. The most probable preliminary diagnosis?

- A. Chronic pyelonephritis, CRF II st.
- B. Chronic pyelonephritis, CRF III st.
- C. Chronic glomerulonephritis, CRF II st.
- D. Chronic glomerulonephritis, CRF I st.
- E. renal amyloidosis, CRF III st.

Clinical tasks:

Task #1.

Male 55 years old complains of general weakness, decreasing exudation, pain in the heart aching character. For 15 years, chronic pyelonephritis, treated in hospitals. OBJECTIVE: the skin dry with icteric tinge. Pulse - 80/min., Rhythmic, BP - 100/70 mm Hg. century. At the heart auscultation - tone weakness, the sound of friction of pericardium. After more research - creatinine - 1.1 mmol / l, GFR = 5 ml / min.

The control question:

1. Your preliminary diagnosis?
2. What are the tests required for setting the final diagnosis?
3. List the basic principles of treatment. What treatment is indicated for the patient? Hemodialysis

Task No. 2.

Patient P., 58. Complaints of headaches, tinnitus, weakness in his left hand and leg. 14 years ago revealed blood pressure. Last year, suffered strokes. Manifest changes in the urine. OBJECTIVE: high power, no edema. Nearside hemiparesis. Vesicular breath, enlarged heart left by 3 cm, muted tones, accent 2 tones in aorta, pulse 80 per min., Rhythmic, intense. BP = 210/120 mm Hg. General blood: HB130 g/L, Leuk - $6.6 \cdot 10^9 / l$, ESR -12 mm per hour. Urinalysis: Density - 1018, protein - 0.93

grams/ L, L. - P. 2-3 in the vision field, Er. 10.12 in the vision field, Hyalinecasts - 1-2 in the vision field. Eye fundus: retinopathy, hemorrhage foci. ECG: left axis deviation, left ventricular hypertrophy.

The control question:

1. Your preliminary diagnosis?
2. Conduct a differential diagnosis.
3. What is the most likely cause of hypertension in the patient?

Task No. 3.

Patient F. 18 years with myeloblastic acute leukemia after remission induction rate scheme 7 +3 (tsytozar, idarubitsyn) received ceftriaxone, Metrogil, amphotericin B (in units 40000 to / in the cap. 7 days.). After 2 weeks there were complaints about acute weakness, nausea, headache, cramps in the gastrocnemius. In KLA: Er.-2, 9h1012 / l, NV - December 97. / L in May. - 40h109 / l, Lake. - 1.6 h109 / l, approx.- 0 E- 0 P - 3%, C - 17%, L - 79%, M - 2%, ESR - 28 mm / hr. Wi: Color s / f, proportion - 1007, protein - 0.983 / L, Er. - 20 -25 in the vision field, L. - 4-7 in the vision field, hyaline casts - rare in the vision field. Blood creatinine - 0.286 mmol / L, potassium - 1.8 mmol / l, sodium - 135 mmol / liter.

The control question:

1. Your preliminary diagnosis?
2. Why the condition of the patient deteriorated?
3. Write treatment plan .

Summary:

Recommended reading list

Basic literature:

- Harrison's Principles of Internal Medicine Self-Assessment and Board Review, 20th Edition 20th Edition.- (August 13, 2021). - 736 pages
- Pocket Medicine: The Massachusetts General Hospital Handbook of Internal Medicine / 007 edition (12 Sept. 2019). - 272 pages
- Davidson's Principles and Practice of Medicine: Enhanced Digital Version Included / Elsevier; 23rd edition (25 April 2018). - 1440 pages

Additional literature:

- Macleod's Clinical Examination /Elsevier; 14th edition (11 Jun. 2018). - 400 pages
- Current Medical Diagnosis and Treatment /McGraw-Hill Education; Updated edition (14 Sept. 2021). - 1840 pages
- Lippincott Connect Standalone Courseware for Bates' Guide to Physical Examination and History Taking 1.0 /LWW; 13th ed. edition (23 Mar. 2023).
- Step-Up to Medicine / Wolters Kluwer Health; 5th edition (8 May 2019). - 582 pages
- Goldman-Cecil Medicine, 2-Volume Set (Cecil Textbook of Medicine) / Elsevier; 26th edition (20 Dec. 2019). - 2944 pages
- The Washington Manual of Medical Therapeutics / Wolters Kluwer Health; 36th edition (6 Jun. 2019). - 1074 pages
- Harrison's Manual of Medicine / McGraw-Hill Education; 20th edition (5 Nov. 2019). - 1245 pages

Electronic information resources

- World Health Organization. URL: www.who.int/ru/index.html.
- European Regional Office of the World Health Organization. URL: www.euro.who.int.
- <https://www.aasld.org/>
- https://academic.oup.com/ndt/pages/General_Instruction
- <https://cprguidelines.eu/>
- <https://www.escardio.org/Guidelines/Clinical-Practice-Guidelines>
- <http://www.oxfordmedicaleducation.com/>
- <http://ard.bmj.com>
- <https://www.escardio.org/Guidelines/Clinical-Practice-Guidelines>

Practical lesson

Topic 26. Management of a patient with anemia.

The main goals: to acquire communication skills and skills of clinical examination of a patient with anemia ; be able to establish a preliminary diagnosis, carry out a differential diagnosis and determine the clinical diagnosis of the disease in a patient with anemia ; master the principles of treatment, recommendations for lifestyle changes in the management of patients with anemia ; to diagnose emergency conditions in patients with anemia; master the tactics of providing emergency medical care to patients with anemia; to be able to perform therapeutic manipulations in patients with anemia.

Key words: definition of the term anemia; etiology and pathogenesis of anemia; modern classification of anemias; clinical manifestations, possible complications; basic methods of diagnosing anemias; general and dietary recommendations for patients with anemia, basic pharmaceuticals for treatment, options for supportive therapy; options for the course of the disease; terms and methods of monitoring the effectiveness of treatment.

Equipment: multimedia materials - a set of thematic slides from the department's multimedia library; screenshots of the results of laboratory (complete blood analysis, blood smear and erythrocyte indices, serum ferritin, serum iron and total iron-binding capacity) and instrumental (bone marrow punctate) studies ; a set of situational problems on the subject of the lesson.

Plan:

- Organizational measures (greetings, verification of those present, announcement of the topic, purpose of the lesson, motivation of higher education seekers to study the topic)
- Control of the reference level of knowledge (checking homework, written work, written testing, including writing KROK-2 tests, frontal survey)
- Formation of professional abilities and skills (mastery of skills, curation, determination of the treatment scheme, laboratory research, etc.): discussing the features of diagnosis and treatment of patients with anemia , the most common clinical manifestations, criteria for establishing a diagnosis
- Summing up (summarizing the topic, evaluating applicants, discussing the next lesson topic and homework).

The control questions:

1. Differential diagnosis of iron-deficient and B12-deficient anemia.
2. Underlying causes of iron deficiency.
3. Indications for hemotransfusion.
4. Management of patients with anemia of different genesis.
5. Mechanisms of intracellular and intravascular hemolysis.
6. Hemotransfusion components and blood components.
7. Differential diagnostics of hemolytic, hypoplastic and post-hemorrhagic anemia.
8. Clinical and laboratory diagnostics in hemolytic, hypoplastic and post-hemorrhagic anemia.
9. Basic principles of pharmacological and non-medicinal treatment for patients with anemias of different genesis. Standards of treatment.
10. Primary and secondary prevention.

Tests:

1. The physician must undertake measures for primary prophylaxis of iron deficiency anemia. Which of the following categories of patients are subject to such primary prophylactic measures?
A Patients after 60
B Patients after surgery
C Workers of industrial enterprises
D All children
E Pregnant women
2. Male, 43 years, complained of periodic impurity of blood in the stool, general weakness, fatigue, shortness of breath when walking, dizziness when rising from bed, heart racing. In review: paleness, the skin and mucous membranes, CHD - 20 min., Heart rate - 92 per min., BP=105/70 mmHg. In

blood: Er.- $2.2 \times 10^{12}/L$, Hb - 74, ret.-0.2%, plt: $160 \times 10^9 / l$, Leucocytes. $7.8 \times 10^9 / l$, e - 2%, bands - 6%, segs - 64%, Lymphocytes- 20%, mon - 8%, ESR 17 mm / hr. What is anemia occurs?

- A Chronic post-hemorrhagic anemia
- B Acute post-hemorrhagic anemia
- C B12-deficiency anemia
- D Folic-deficiency anemia
- E hypoplastic anemia

3. Patient 30 years, a history of oral-facial injury two days ago, complaints of nasal and gingival unstoppable bleeding. In review: skin pallor, Hyperventilation, moderate tachycardia, hypotension. In blood: Er. - $2.0 \times 10^{12} / l$, Hb - 60 g/L, ret.- 4% platelets - $150 \times 10^9 / L$, leucocytes. - $9.0 \times 10^9/L$, e3%, bands - 8%, segs - 72%. lymph - 15%, mon - 2%, ESR 18 mm/hr. Which kind of anemia is it?

- A. Acute post-hemorrhagic anemia
- B. Chronic iron deficiency post-hemorrhagic anemia
- C. Hemolytic anemia
- D. B12 - folic deficiency anemia
- E. Anemia in Randu-Osler disease

4. Male 46 years old, homeless, with signs of exhaustion. In the blood: Er. $1.5 \times 10^{12}/L$, Hb - 70, ret. - 0.1%. Erythrocyte severely hypochromic, microcytosis, anisocytosis, poikilocytosis; Plt - $170 \times 10^9/L$, Leukocytes - $4.5 \times 10^9 /L$, leukoformula normal. ESR - 16 mm / hr. What kind of anemia occurs?

- A. Aplastic anemia
- B. Post-hemorrhagic anemia
- C. Hemolytic anemia
- D. B12 - folic deficiency anemia
- E. Alimentary iron-deficiency anemia

5. A woman complains of muscle weakness and general fatigue, dyspnea, vertigo, brittleness of her hair and nails, an urge to eat chalk. Anamnesis states uterine fibroid. Common blood analysis: erythrocytes - $2.8 T /l$, Hb - 80 g/l, color index - 0.78, anisocytosis, poikilocythemia, serum iron - 10 $\mu\text{mol/l}$. What diagnosis is most likely?

- A. Iron-deficiency anemia
- B. B 12 -deficient anemia
- C. Autoimmune hemolytic anemia
- D. Aplastic anemia
- E. Hypoplastic anemia

6. A 49-year-old man complains of fatigue and shortness of breath. His Ht is 32%, and Hb - 103 g/l. Peripheral blood smear reveals macrocytosis. Serum vitamin B12 level is 92 pg/ml (normal is 170 to 940); serum folate level is 6 ng/ml (normal is 2 to 14). Possible causes to consider include all of the following EXCEPT:

- A Vegetarianism
- B Hepatitis
- C Colonic diverticulitis
- D Fish tapeworm infection
- E Regional enteritis

7. A 42-year-old patient complains of back pain, darkened urine, general weakness, dizziness that occurred after treating a cold with aspirin and ampicillin. Objectively: the patient is pale, with subicteric sclerae. HR - 98 bpm. Liver - +2 cm, spleen - +3 cm. In blood: RBCs - $2.6 \times 10^{12}/L$, Hb - 60 g/L, CI - 0.9, WBCs - $9.4 \times 10^9/L$, basophils - 0.5%, eosinophils - 3 %, stab neutrophils - 6%, segmented neutrophils - 58%, lymphocytes - 25%, monocytes - 7%, ESR - 38 mm/hour, reticulocytes - 24%. Total bilirubin - 38 millimole/l. What complication occurred in the patient?

- A. Acquired hemolytic anemia
- B. Toxic hepatitis
- C. Cholelithiasis
- D. Agranulocytosis
- E. Paroxysmal nocturnal hemoglobinuria

8 . A 45-year-old man has been suffering from duodenal ulcer disease for 5 years. He complains of

weakness, dizziness, dryness of the skin. Objectively: the skin and visible mucosa are pale, chapped lips; heart rate is 100/min., BP- 100/70 mm Hg, systolic murmur at all points on heart auscultation. All other internal organs are unchanged. Fecal occult blood test is positive. Blood test: erythrocytes - $3,1 \cdot 10^{12} / l$, Hb - 88 g/l, color index - 0.7, leukocytes - $4,6 \cdot 10^9 / l$, platelets - $350 \cdot 10^9 / l$, ESR - 21 mm/hour, anisocytosis, poikilocythemia, serum iron - 9.5 $\mu\text{mol/l}$. What treatment tactics would you choose?

A. Iron preparations, balanced diet

B. Concentrated red cells transfusion C. Intramuscular introduction of 500 mkg of cyanocobalamin

D. Corticosteroids, cytostatics

E. Ascorbic acid, calcium chloride

9. A 56-year-old patient entered the clinic with complaints of general weakness, dizziness, breathlessness when walking, heartburn in the tongue, numbness of the extremities. Sick for about 5 months. Objective: skin and visible mucous membranes pale, legs edematous, lymph nodes not enlarged. Heart tones muted over the tip of the beat. Tongue raspberry-red, papillary layer subdued. Abdomen soft, liver performs at 2 cm, spleen - 1 cm, painless. In blood: Hb - 60 g / L, Leuk. - $2.5 \cdot 10^9 / L$, e. - 1%, bands. - 5%, secs. - 57%, Lymph. - 36%, mon. - 1%, ESR - 62 mm/hr., Megalocytes: 6 in sight. What are the main diagnostic methods for this disease:

A. Analysis of bone marrow punctate

B. Determination of serum iron

C. Determination of bilirubin in the blood

D. Determination of osmotic resistance of erythrocytes

E. The Kumb's reaction

10. A 58-year-old woman complains of spontaneous bruises, weakness, bleeding gums, dizziness. Objectively: the mucous membranes and skin are pale with numerous hemorrhages of various times of origin. Lymph nodes are not enlarged. Heart rate - 100/min., BP - 110/70 mm Hg. There are no changes of internal organs. Blood test results: RBC $3,0 \cdot 10^{12} / l$, Hb - 92 g/l, color index - 0.9, anisocytosis, poikilocytosis, WBC - $10 \cdot 10^9 / l$, eosinophiles - 2%, stab neutrophiles - 12%, segmented neutrophiles - 68%, lymphocytes - 11%, monocytes - 7%, ESR - 12 mm/hour. What index should be determined additionally by a laboratory to make a diagnosis?

A. Platelets

B. Reticulocytes

C. Clotting time

D. Osmotic resistance of erythrocytes

E. Fibrinogen

Control tasks:

Task No. 1.

Patient 39 years, appealed to the precinct physician with complaints within 6 months of general weakness, dizziness, breathlessness, decreased appetite. She has 4 children. Vegetarian. Objectively: height 172 cm, weight 52 kg, mucous membranes pale, dry, spoon nail. Cardiac tones rhythmic, sonorous, BP 90/65 mmHg heart rate 120 per min. In the lungs - Vesicular breath. Liver and spleen not enlarged. Pasternatsky symptom negative on both sides. No edema. In blood: Er. - $2.7 \cdot 10^{12} / l$, CT - 0.6, NV - 90 g / l, ESR - 10 mm / hr. Serum iron - 8.7 $\mu\text{mol} / \text{liter}$.

The control questions:

1. Your preliminary diagnosis?

2. Which test should be set to determine the final diagnosis?

3. Your recommendations for pharmacological and non-medicinal treatment.

Task No. 2.

Patient 56 years, working radiographer 30 years. Appealed to the complaints of general weakness, dizziness, breathlessness, palpitations, bleeding gums. Objectively: pale mucous membranes yellow, in the abdomen - hemorrhages. At Peripheral lymph nodes are not enlarged. Rhythmic activity of the heart, left heart border + 2cm, BP 160/95 mm.Hg, heart rate 100 per min. In the lungs - Vesicular breath. Liver and spleen not enlarged. Pasternatsky symptom negative on both sides. No edema. In

blood: Er. - $2.7 \times 10^{12} / l$, Hb - $90 \text{ g} / l$, CT - 0.7; Leukocytes. - $3.3 \times 10^9 / l$, PLT - $80 \times 10^9 / l$, ESR20 mm / hr.

The control questions:

1. Your preliminary diagnosis?
2. Make a plan examination of the patient.
3. What patients need to carry differential diagnosis?

Task No. 3.

Patient 23 years old, sent to hospital therapeutic department complaining of headaches, general weakness, dizziness, breathlessness, jaundice. Objectively: skin lemon-yellow. Peripheral lymph nodes are not enlarged. Rhythmic activity of the heart, left heart border + 2cm, tone deaf heart, SC 160/95 mmHg., heart rate 100 per min. In the lungs - Vesicular breath. Liver 1.5 cm, with palpation painful enlarged spleen. Blood - Er. - $3.7 \times 10^{12} / l$, Hb - $95 \text{ g} / l$; Leukocytes. - $5.3 \times 10^9 / l$, PLT - $210 \times 10^9 / l$, ESR - 20 mm / hr., Reducing osmotic resistance of erythrocytes, total bilirubin $68 \text{ mmol} / l$. When ultrasound of the abdomen - the gall bladder stones, plunk-and splenomegaly.

The control questions:

1. Your preliminary diagnosis?
2. Make a plan examination of the patient.
3. What tactics of the patient?

Summary:

Recommended reading list

Basic literature:

- Harrison's Principles of Internal Medicine Self-Assessment and Board Review, 20th Edition 20th Edition.- (August 13, 2021). - 736 pages
- Pocket Medicine: The Massachusetts General Hospital Handbook of Internal Medicine / 007 edition (12 Sept. 2019). - 272 pages
- Davidson's Principles and Practice of Medicine: Enhanced Digital Version Included / Elsevier; 23rd edition (25 April 2018). - 1440 pages

Additional literature:

- Macleod's Clinical Examination /Elsevier; 14th edition (11 Jun. 2018). - 400 pages
- Current Medical Diagnosis and Treatment /McGraw-Hill Education; Updated edition (14 Sept. 2021). - 1840 pages
- Lippincott Connect Standalone Courseware for Bates' Guide to Physical Examination and History Taking 1.0 /LWW; 13th ed. edition (23 Mar. 2023).
- Step-Up to Medicine / Wolters Kluwer Health; 5th edition (8 May 2019). - 582 pages
- Goldman-Cecil Medicine, 2-Volume Set (Cecil Textbook of Medicine) / Elsevier; 26th edition (20 Dec. 2019). - 2944 pages
- The Washington Manual of Medical Therapeutics / Wolters Kluwer Health; 36th edition (6 Jun. 2019). - 1074 pages
- Harrison's Manual of Medicine / McGraw-Hill Education; 20th edition (5 Nov. 2019). - 1245 pages

Electronic information resources

- World Health Organization. URL: www.who.int/ru/index.html.
- European Regional Office of the World Health Organization. URL: www.euro.who.int.
- <https://www.aasld.org/>
- https://academic.oup.com/ndt/pages/General_Instruction
- <https://cprguidelines.eu/>
- <https://www.escardio.org/Guidelines/Clinical-Practice-Guidelines>
- <http://www.oxfordmedicaleducation.com/>
- <http://ard.bmj.com>
- <https://www.escardio.org/Guidelines/Clinical-Practice-Guidelines>

Practical class

Topic 27. Management of a patient with a leukemic reaction and leukemia

The main goals: to acquire communication skills and clinical examination skills of a patient with leukemia and a leukemic reaction ; to be able to establish a preliminary diagnosis, carry out a differential diagnosis and determine the clinical diagnosis of the disease in a patient with leukemia and a leukemoid reaction ; master the principles of treatment, recommendations for lifestyle changes in the management of patients with leukemia and leukemic reactions ; to diagnose emergency conditions in patients with leukemia and leukemic reaction; to master the tactics of providing emergency medical care to patients with leukemia and a leukemic reaction; to be able to perform therapeutic manipulations in patients with leukemia and leukemic reaction.

Key words: hematopoietic mechanism; main elements of myelogram; definition of acute leukemia (AL) and chronic leukemia (CL); determination of the leukogenic factor; pathogenesis of AL and CL; classification of AL and CL; typical clinical syndromes of AL and CL; typical laboratory signs; principle of treatment; definition of "lymphogranulomatosis", "lymphocytic lymphoma", "lymphadenopathy"; diseases related to tumors of the immune system; classification of lymphogranulomatosis and lymphocytic lymphomas; peculiarities of the impression of lymph nodes in lymphogranulomatosis and lymphocytic lymphomas; main clinical syndromes in lymphogranulomatosis and lymphocytic lymphomas; diagnosis of the main manifestations and complications of lymphogranulomatosis and lymphocytic lymphomas; principles of treatment of lymphogranulomatosis and lymphocytic lymphomas; patterns of development of manifestations and complications of lymphogranulomatosis and lymphocytic (non-Hodgkin) lymphomas; the main diseases that occur with lymphadenopathy syndrome; peculiarities of the impression of lymph nodes in infectious diseases, oncopathology, systemic diseases of connective tissue, etc.

Equipment: multimedia materials - a set of thematic slides from the department's multimedia library; screenshots of the results of laboratory (complete blood analysis, blood smear and erythrocyte indices, serum ferritin, serum iron and total iron-binding capacity) and instrumental (bone marrow punctate) studies ; a set of situational problems on the subject of the lesson.

Plan:

- Organizational measures (greetings, verification of those present, announcement of the topic, purpose of the lesson, motivation of higher education seekers to study the topic)
- Control of the reference level of knowledge (checking homework, written work, written testing, including writing KROK-2 tests, frontal survey)
- Formation of professional abilities and skills (mastery of skills, curation, determination of the treatment scheme, laboratory research, etc.): discussing the features of diagnosis and treatment of patients with anemia , the most common clinical manifestations, criteria for establishing a diagnosis
- Summing up (summarizing the topic, evaluating applicants, discussing the next lesson topic and homework).

The control questions:

1. Which group of diseases includes all leukemias?
2. What is progenitor hematopoiesis?
3. How to differentiate acute leukemia from chronic?
4. What is the difference between leukemia cells and normal cells?
5. Which cells are the substrate of chronic myeloid leukemia?
6. Which drugs are included in the acute leukemia eradication program?
7. Which are the main syndromes in acute leukemia?
8. Name the types of leukemoid reaction

Tests:

1 . A 32-year-old welder complains of weakness and fever. His illness initially presented as tonsillitis one month earlier. On examination: BT- 38,9 °C, RR- 24/min., HR100/min., BP- 100/70 mm Hg, hemorrhages on the legs, enlargement of the lymph nodes. CBC shows Hb- 70 g/l, RBC- $2,2 \cdot 10^{12} /l$,

WBC- $3,0 \cdot 10^9$ /l with 32% of blasts, 1% of eosinophiles, 3% of bands, 36% of segments , 20% of lymphocytes, and 8% of monocytes, ESR - 47 mm/hour. What is the cause of anemia?

A. Acute leukemia

B. Chronic lympholeukemia

C. Aplastic anemia

D. B₁₂-deficient anemia

E. Chronic hemolytic anemia

2. Which is the leading pathogenetic mechanism of leukemia?

A. Bone marrow metaplasia

B. Cellular blood elements anaplasia

C. Cells proliferation - tumor substrates

D. Expressed intoxication

E. Hemorrhagic manifestations

3. In which form of leukemia does the Philadelphia chromosome appear?

A. Acute myeloblastic leukemia

B. Polycythemia (erythremia)

C. Chronic lymphocytic leukemia

D. Chronic myeloid leukemia

E. Myeloma disease

4. Which changes in the peripheral blood are the most common for chronic lymphocytic leukemia?

A. Normochromic anemia

B. The absolute and relative lymphocytosis

C. Neutrophilic leukocytosis

D. Thrombopenia

E. Significant ESR increase

5. What is the substrate of tumor cells in multiple myeloma?

A. myeloblasts

B. A mature lymphocyte

C. Neutrophilic leukocyte

D. Erythroblasts

E. Plasmocytes

6. What is the most common clinical sign for chronic myeloid leukemia?

A. Splenomegaly

B. Hepatomegaly

C. Lymphadenopathy

D. Bleeding

E. Infectious manifestations

7. What is the leukemoid reaction?

A. Self-disease

B. Accompanying disease

C. Complications of underlying diseases

D. Reversible reaction of the hematopoietic system for a tumor, infection or intoxication

E. Irreversible reaction of the hematopoietic system for the above factors resulting in leukemia

8. Patient 23 years old suffering from the acute systemic lupus erythematosus with a high activity stage assigned to prednisolone 5 \ 0 mg per day. A few days later the patient was taken by complete blood count: er .- $4 \cdot 10^{12}$ / l, Hb - 102 g / l, ESR -32 mm / hour. WBC - 10.2×10^9 / l, e-2%, b -0., medullozell - 1%, metamyelocyte - 2%, n - 8%, Seg .. - 59%, lymph. 26%, mon -2%. Platelets - 120×10^9 / l. Give your opinion about the patient's state.

A. Acute myeloblastic leukemia

B. Myeloid leukemoid reaction type

C. Chronic myeloid leukemia

D. Systemic lupus erythematosus progression

E. Myeloma

9. In which form of leukemia bone-destructive changes of the skull, pelvis, ribs bones develop?

- A. Myelofibrosis
- B. Erythremia
- C. Myeloma
- D. Chronic myelocytic leukemia
- E. Chronic lymphocytic leukemia

10. Which group of medical preparations is the primary, pathogenetically substantiated, for the leukemia treatment?

- A. Cytostatics
- B. Corticosteroids
- C. Antibacterial Drugs
- D. hemostatic tools
- E. Antianaemic drugs

Control tasks:

Task No. 1.

Patient, 24 years, was admitted to hospital with complaints of progressive general weakness, malaise, fever up to 37.8 ° C. General weakness appeared 2 months ago, but the patient started feeling sick about two weeks ago, when he'd got some catarrhal phenomena (sore throat, runny nose, sneezing, headache, fever). Treated in the infirmary for acute respiratory disease with some improvement. But the increasing weakness of the left and subfebrile appeared cutaneous hemorrhages, and therefore investigated the overall analysis of the blood. In connection with the identified changes in the blood sent for medical examination and treatment in a clinical hospital.

The general condition of the patient is moderate. Marked pallor of the skin of the trunk isolated petechiae and ecchymosis. Peripheral lymph nodes were not enlarged. In the lungs - vesicular breathing, no wheezing. Cardiac loud, the rhythm is correct. Pulse 92 beats per minute. Above all points auscultated blowing systolic sound higher near jugular vessels. BP-140/60 mmHg, tongue is yellowish. Abdomen soft, regular shape, symmetrically involved in breathing, palpation painless. Liver at the edge of the costal arch, palpated pole of the spleen, it is mobile, painless.

Laboratory data. The general analysis of blood: red blood cells - $2.7 \cdot 10^{12} / l$, hemoglobin - 70 g / l, color index -0.96, the number of white blood cells - $18 \cdot 10^9$ per liter. Leukoformula: blast cells, 1%, eosinophils 5%, basophils - 0, metamyelocytes 2%, stab - 7%, segmented - 59%, lymphocytes - 22%, monocytes - 4%. ESR - 35 mm per hour. The number of platelets is 140,109 / liter.

Myelogram: bone marrow is rich in cellular elements, the number of myelokaryocytes - 194 thousand per microliter, blasts - 8.1% (rate - up to 2.8%), promyelocytes - 1%, myelocytes - 6.2, metamyelocytes 6.8 %, stab - 18.2%, segmented-34, 8%, lymphocytes - 10.6%, monocytes - 1.8%, plasma cells - 1%, all the elements erythroid - 11.5% (normal range, 14.5 to 26, 5). Leuco-erythroblastic ratio is 7.69 (normally 2.1 - 4.5). The number of megakaryocytes was slightly reduced.

Cytochemical study of blast cells showed a sharp positive reaction to their myeloperoxidase, negative reaction to glycogen.

The control questions:

1. What preliminary diagnosis?
2. What is the leading syndrome in a patient?
3. Which diseases should be a differential diagnosis of selected leading syndrome in a patient?
4. What test is this patient?
5. What treatment is necessary to appoint a patient?

Task No. 2.

Pt. 57 years complained of constant dull ache in the epigastrium, poor appetite, general weakness, weight loss of 10-12 kg for the last 1.5 - 2 months. He considers himself sick about 2 months ago due to pains in the stomach. CT scan for chest pathology is normal, CT abdomen revealed numerous lymph nodes up to 1 - 1.2 cm in diameter. At fibrogastroduodenoscopy on the greater curvature of the stomach revealed a tumor the size of 3 - 2.8 cm taken biopsy, when watching a poorly differentiated cancer cells are found. In general, the analysis of blood found eras. - $3.6 \times 10^{12} / l$, Hb - 92 g / l, Hematocrit - 28%, ESR - 38 mm per hour. WBC - 10.8×10^9 g / liter. In leukoformula medullocell -

1%, metamyelocyte - 2%, stabnuclear 8%, Seg. - 61%, lymph. 18%, Mon - 10%. Platelets $290 \times 10^9 / l$. In urine small proteinuria, sp. Weight - 1018, white blood cells - up to 5 in the field of view.

The questions:

1. What preliminary diagnosis?
2. What is the leading syndrome in a patient?
3. Which diseases should be a differential diagnosis in relation to changes in the blood of a patient?
4. What test is this patient?
5. What treatment is necessary to appoint a patient?

Task No. 3.

Patient 68 years old with complaints of fatigue, general weakness, the appearance of some formations on the neck to the left and the left armpit. all started 5-6 months ago with weakness. During examination the general condition is satisfactory, yellow hue of skin. vesicular breathing. Cardiac muffled rhythmic. Been increased on the left anterior lymph nodes (3 nodes on 2.5 - 3 cm), axillary left up to 2 cm in diameter. All nodes soft elastic consistency, movable, and are not soldered together, painless. The liver performs at 1 cm from the costal arch, the spleen is not palpable. Blood tests: er. - $3.9 \times 10^{12} / l$, Hb -106 g / liter. ESR - 5 mm / hour. WBC - 12.5×10^9 per liter. In leukoformule: eos - 1%, n / o 2%, with / I - 53%, lymph. - 42%, Mon. - 2%. Platelets - 185×10^9 per liter. All fields encountered cells Botkin-Gumprehta.

The questions:

1. What preliminary diagnosis?
2. What is the leading syndrome in a patient?
3. Which diseases should be differential diagnosis for the selected lead syndrome?
4. What test is this patient?
5. What treatment is necessary to appoint a patient?

Summary:

Recommended reading list

Basic literature:

- Harrison's Principles of Internal Medicine Self-Assessment and Board Review, 20th Edition 20th Edition.- (August 13, 2021). - 736 pages
- Pocket Medicine: The Massachusetts General Hospital Handbook of Internal Medicine / 007 edition (12 Sept. 2019). - 272 pages
- Davidson's Principles and Practice of Medicine: Enhanced Digital Version Included / Elsevier; 23rd edition (25 April 2018). - 1440 pages

Additional literature:

- Macleod's Clinical Examination /Elsevier; 14th edition (11 Jun. 2018). - 400 pages
- Current Medical Diagnosis and Treatment /McGraw-Hill Education; Updated edition (14 Sept. 2021). - 1840 pages
- Lippincott Connect Standalone Courseware for Bates' Guide to Physical Examination and History Taking 1.0 /LWW; 13th ed. edition (23 Mar. 2023).
- Step-Up to Medicine / Wolters Kluwer Health; 5th edition (8 May 2019). - 582 pages
- Goldman-Cecil Medicine, 2-Volume Set (Cecil Textbook of Medicine) / Elsevier; 26th edition (20 Dec. 2019). - 2944 pages
- The Washington Manual of Medical Therapeutics / Wolters Kluwer Health; 36th edition (6 Jun. 2019). - 1074 pages
- Harrison's Manual of Medicine / McGraw-Hill Education; 20th edition (5 Nov. 2019). - 1245 pages

Electronic information resources

- World Health Organization. URL: www.who.int/ru/index.html.
- European Regional Office of the World Health Organization. URL: www.euro.who.int.
- <https://www.aasld.org/>
- https://academic.oup.com/ndt/pages/General_Instruction
- <https://cprguidelines.eu/>
- <https://www.escardio.org/Guidelines/Clinical-Practice-Guidelines>

- <http://www.oxfordmedicaleducation.com/>
- <http://ard.bmj.com>
- <https://www.escardio.org/Guidelines/Clinical-Practice-Guidelines>

Practical class

Topic 28. Management of a patient with lymphadenopathy

The main goals: to acquire communication skills and clinical examination skills of a patient with lymphadenopathy; be able to establish a preliminary diagnosis, carry out a differential diagnosis and determine the clinical diagnosis of the disease in a patient with lymphadenopathy ; master the principles of treatment, recommendations for lifestyle changes in the management of patients with lymphadenopathy ; to diagnose emergency conditions in patients with lymphadenopathy; master the tactics of providing emergency medical care to patients with lymphadenopathy; to be able to perform therapeutic manipulations in patients with lymphadenopathy.

Key words: definition of the concept of lymphadenopathy (LDP); on diseases and pathological processes accompanied by LDP; diagnostic search in LDP patients; localization and prevalence of LDP; detection of additional symptoms in LDP patients; about the effectiveness of LDP in various diseases; features of peripheral blood analysis for various causes of LDP; features of LDP in leukemias; features of LDP in oncological diseases.

Equipment: multimedia materials - a set of thematic slides from the department's multimedia library; screenshots of the results of laboratory (expanded blood analysis) and instrumental (x-ray examination of the chest, ultrasound of the abdominal organs, immuno-serological studies (syphilis, HIV infection, hepatitis B and C) studies ; a set of situational problems on the subject of the lesson.

Plan:

1. Organizational measures (greetings, verification of those present, announcement of the topic, purpose of the lesson, motivation of higher education seekers to study the topic)
2. Control of the reference level of knowledge (checking homework, written work, written testing, including writing KROK-2 tests, frontal survey)
3. Formation of professional skills and abilities (mastery of skills, curation, determination of the treatment scheme, laboratory research, etc.): discussing the features of diagnosis and treatment of patients with lymphadenopathy , the most common clinical manifestations, criteria for establishing a diagnosis
4. Summing up (summarizing the topic, evaluating applicants, discussing the next lesson topic and homework)

The control questions:

- 1 What are the characteristics of lymph nodes, in which there are metastases? 2 What are lymph nodes usually increases when infected with Mononucleosis?
3. Which cells are pathognomonic for Hodgkin's disease You can find in lymph nodes?
4. What are the predominant cells in the lymph nodes in chronic lymphoid leukemia?
5. What are the differences between non-specific (trivial) lymphadenitis of lymph nodes in chronic lymphocytic leukemia?
6. Please list what diseases are accompanied by an increase in lymph nodes?
7. Can lymphadenopathy occur in AIDS?
8. Which most important in the diagnosis nosology lymphadenopathy?
9. Which lymphadenopathic inflammation in the presence of cat scratch?
10. When it is possible to the patient with increased lymph nodes immediately recommended for physiotherapy procedures on the affected area?

Tests

1 . A 25-year-old patient has been admitted to the hospital with the following problems: weakness, sweating, itching, weight loss, enlarged submandibular, cervical, axillary, inguinal lymph nodes. Objectively: hepatomegaly. Lymph node biopsy revealed giant Berezovsky-Reed-Sternberg cells, polymorphocellular granuloma composed of lymphocytes, reticular cells, neutrophils, eosinophils, fibrous tissue, plasma cells. What is the most likely diagnosis?

- A. Lymphogranulomatosis
- B. Lymph node tuberculosis
- C. Lymphoreticulosarcoma
- D. Cancer metastases to lymph nodes
- E. Macofollicular reticulosis

2. What is the most common diagnostic feature for Hodgkin's disease?

- A. Enlarged lymphatic nodes
- B. The bone marrow changes
- C. Painting peripheral blood
- D. Cytochemical blood cells study
- E. Histological lymph node biopsies, the presence of Berezovsky-Sternberg cells

3. Which organ is the most frequently affected by Hodgkin's disease?

- A. Kidney
- B. Spleen
- C. Lymphatic system
- D. Liver
- E. Stomach

4. Which tumor location is the most common in lymphosarcoma?

- A. Axillary
- B. Inguinal
- C. Mediastinal
- D. Supraclavicular
- E. Post cervical

5. In which organs except lymph nodes, can lymphosarcoma most often be localized?

- A. Intestine
- B. Brain
- C. Kidney
- D. Skin
- E. Liver

6. In which disease are the Berezovsky-Sternberg cells usually found?

- A. Chronic lymphocytic leukemia
- B. Lymphosarcoma
- C. Lymphogranulomatosis
- D. Tuberculous lymphadenitis
- E. Metastasis of cancer in the lymph node

7. What is the character of palpable lymph nodes in the early stage of chronic lymphocytic leukemia?

- A. Soft consistency, not soldered to the skin and underlying tissues
- B. Elastic consistency, motionless, painless
- C. Elastic consistency, not soldered to the skin and underlying tissues
- D. Soft elastic, immobile, painful
- E. Lymph nodes woody density, fused with the skin and underlying tissues, painful

8. The patient, aged 46, complained of itchy skin, expressed sweating, especially at night, fever up to 38.6 ° C. Objectively: the skin of the chest shows traces of scratching, supraclavicular lymph nodes have the size of pigeon eggs, with the skin not soldered. What diagnostic test should be done for raising diagnosis?

- A. The general analysis of blood.
- B. Review chest x-ray
- C. Biopsy enlarged lymph node.
- D. Immunogram.

E. Proteins blood protein fractions.

9. The patient, 64 years old, was examined in the clinic for referral spa - spa treatment. No complaints. OBJECTIVE: enlarged cervical, axillary and inguinal lymph nodes, liver at 3 cm appears from under the edge of the costal arch, an enlarged spleen (in diameter - 14 cm). Blood tests: Er - $3.7 \cdot 10^{12}$, Hb - 120 g/L, Leuk - $30 \times 10^9/L$, e. - 2%, p / rods - 1%, segs. 33%, lymph. - 60%, Mon. - 4%, ESR - 20 mm / h. What is the preliminary diagnosis?

A. Chronic lymphocytic leukemia.

B. Cancer of the liver.

C. Cirrhosis of the liver.

D. Tuberculous lymphadenitis.

E. Lymphogranulomatosis.

10. In a patient 62 years old when the survey revealed enlarged cervical and axillary lymph nodes, soft elastic consistency, mobile, painless. In the 40 years of age suffered from pulmonary tuberculosis. On CT of the chest cavity found up to 1 cm in diameter. The peripheral blood analysis showed small normochromic anemia, leukocyte count $10.2 \times 10^9 /L$, of which 54% lymphocytes. What is the most likely preliminary diagnosis?

A. Tuberculosis of lymph nodes

B. Chronic lymphocytic leukemia

C. Pulmonary Sarcoidosis

D. Metastases in lymph nodes

E. HIV

Control tasks:

Task #1.

Patient 21, homeless, complaining of diarrhea for 2-3 months, weakness, malaise, constant subfebrile fever, recurrent cold sores (herpes) on the lips. During this time, she has lost 13 kg, she connects the loss of weight with an irregular diet. OBJECTIVELY: general condition - medium level of gravity, dry herpetic eruptions are located on the lips, rash, generalized lymphadenopathy, lymph nodes about 1-1.5 cm, tightly elastic, mobile, painless. The liver is palpated 2 cm lower than the edge of the costal arch, smooth, rounded and painless. The spleen is not palpable. In the blood: erythrocytes. - $3.7 \times 10^{12} / l$, Hb- 105 g / l, ESR - 20 mm / h, white blood cells - $10.1 \times 10^{12} / L$ is -5%, n - 6%, from - 63% of lymph. -17%, M. - 3%. Atypical mononuclear - 6%. Platelets - $170 \times 10^9 / l$.

The control questions:

1. What is the most likely (provisional) diagnosis?

2. What is the leading syndrome in a patient?

3. Which diseases should be a differential diagnosis of selected leading syndrome in a patient?

4. What kind of survey is required in this case?

5. Which specialist should send the patient for further examination and treatment?

Task No. 2.

Young man, aged 23, complained of pain and feeling of "foreign body" in the left armpit. 5 days ago he began to observe soreness in the armpit, a little weakness, headache, 2 days the temperature was increased to 37.8 cels. he likes to play with two cats. OBJECTIVE: general condition is satisfactory, but limited movement of his left hand in connection with painful depression. The skin of his left hand and chest erythema nodosum. Increase all of the peripheral lymph nodes up to 1 - 1.2 cm, mobile, painless. In the left armpit lymph node is palpated 3 cm in diameter, more detailed description of it cannot be given because of severe pain. In lung and heart diseases were found. The liver performs at 2 cm from the costal arch, the lower pole of the spleen is palpated. Blood: er. - $4.2 \times 10^{12} / l$, Hb - 110 g / l, ESR 0 18 mm / hour. WBC $3.2 \times 10^9 / L$, after 3 days appeared leukocytosis - $8.1 \times 10^9 / l$, with a slight lymphocytosis (38%) and stab shift - 7%.

The control questions:

1. What preliminary diagnosis?

2. What is the leading syndrome in a patient?

3. Which diseases should be a differential diagnosis of selected leading syndrome in a patient?

4. What examination and treatment should be appointed in this case?
5. What treatment is necessary to appoint a patient?
6. What is the prognosis?

Task No. 3.

Patient 65, a week ago, found at his neck enlargement. Other complaints. Condition satisfactory. The examination revealed enlarged lymph nodes in the right armpit and under the collarbone to 1.5 - 2 cm. The neck on the right is a tumor-formation of soft elastic consistency, movable, painless, size 3 x 3.5 cm in the lungs and heart without pathology. Liver and spleen were not palpable. Blood: er. - 4.1 x 10¹² / l, Hb-105 g / l, ESR 8 mm / h, leukocytes - 10.1 h10¹² / l, e -3%, n - 3%, from - 47%, lymph. - 45%, M - 2%. Cells Botkin-Gumprehta - unit in the sample. Platelets - 190 x 10⁹ / l.

The control questions:

1. What preliminary diagnosis?
2. What is the leading syndrome in a patient?
3. Which diseases should be a differential diagnosis of selected leading syndrome in a patient?
4. What test is this patient?
5. What treatment is necessary to appoint a patient?

Summary:

Recommended reading list

Basic literature:

- Harrison's Principles of Internal Medicine Self-Assessment and Board Review, 20th Edition 20th Edition.- (August 13, 2021). - 736 pages
- Pocket Medicine: The Massachusetts General Hospital Handbook of Internal Medicine / 007 edition (12 Sept. 2019). - 272 pages
- Davidson's Principles and Practice of Medicine: Enhanced Digital Version Included / Elsevier; 23rd edition (25 April 2018). - 1440 pages

Additional literature:

- Macleod's Clinical Examination /Elsevier; 14th edition (11 Jun. 2018). - 400 pages
- Current Medical Diagnosis and Treatment /McGraw-Hill Education; Updated edition (14 Sept. 2021). - 1840 pages
- Lippincott Connect Standalone Courseware for Bates' Guide to Physical Examination and History Taking 1.0 /LWW; 13th ed. edition (23 Mar. 2023).
- Step-Up to Medicine / Wolters Kluwer Health; 5th edition (8 May 2019). - 582 pages
- Goldman-Cecil Medicine, 2-Volume Set (Cecil Textbook of Medicine) / Elsevier; 26th edition (20 Dec. 2019). - 2944 pages
- The Washington Manual of Medical Therapeutics / Wolters Kluwer Health; 36th edition (6 Jun. 2019). - 1074 pages
- Harrison's Manual of Medicine / McGraw-Hill Education; 20th edition (5 Nov. 2019). - 1245 pages

Electronic information resources

- World Health Organization. URL: www.who.int/ru/index.html.
- European Regional Office of the World Health Organization. URL: www.euro.who.int.
- <https://www.aasld.org/>
- https://academic.oup.com/ndt/pages/General_Instruction
- <https://cprguidelines.eu/>
- <https://www.escardio.org/Guidelines/Clinical-Practice-Guidelines>
- <http://www.oxfordmedicaleducation.com/>
- <http://ard.bmj.com>
- <https://www.escardio.org/Guidelines/Clinical-Practice-Guidelines>

Practical class

Topic 29. Management of a patient with hemorrhagic syndrome. Management of a patient with

purpura.

The main goals: to acquire communication skills and skills of clinical examination of a patient with hemorrhagic syndrome ; to be able to establish a preliminary diagnosis, carry out a differential diagnosis and determine the clinical diagnosis of the disease in a patient with hemorrhagic syndrome ; master the principles of treatment, recommendations for lifestyle changes in the management of patients with hemorrhagic syndrome ; diagnose emergency conditions in patients with hemorrhagic syndrome; master the tactics of providing emergency medical care to patients with hemorrhagic syndrome; to be able to perform therapeutic manipulations in patients with hemorrhagic syndrome.

to acquire communication skills and skills of clinical examination of a patient with purpura ; be able to establish a preliminary diagnosis, carry out a differential diagnosis and determine the clinical diagnosis of the disease in a patient with purpura ; master the principles of treatment, recommendations for lifestyle changes in the management of patients with purpura ; to diagnose emergency conditions in patients with purpura; master the tactics of providing emergency medical care to patients with purpura; to be able to perform therapeutic manipulations in patients with purpura.

Key words: in the definition of the concept of hemorrhagic syndrome; hemostasis system and characteristics of the main types of bleeding; the main diseases that are accompanied by hemorrhagic syndrome; etiological factors of diseases accompanied by hemorrhagic syndrome; pathogenesis of diseases accompanied by hemorrhagic syndrome; clinic of diseases accompanied by hemorrhagic syndrome; mechanisms of hematopoiesis and blood coagulation disorders, quantitative and qualitative changes in the composition of peripheral blood in hemorrhagic syndrome; interpretation of the main modern ideas about etiology and pathogenesis; interpretation of changes in the general blood test and myelogram; hemorrhagic syndrome treatment tactics; basic principles of diagnosis and stages of diagnostic search for patients with hemorrhagic syndrome; basic principles of treatment of diseases accompanied by hemorrhagic syndrome; prognosis for the patient; issues of medical rehabilitation and secondary prevention.

in the definition of purpura; hemostasis system and characteristics of the main types of bleeding; the main diseases that are accompanied by purpura; etiological factors of diseases that are accompanied by purpura; pathogenesis of diseases accompanied by purpura; clinic of diseases accompanied by purpura; characteristics of thrombocytopenic purpura, as a type of hemorrhagic disease; mechanisms of hematopoiesis and blood coagulation disorders, quantitative and qualitative changes in the composition of peripheral blood in thrombocytopenic purpura; interpretation of the main modern ideas about etiology and pathogenesis; interpretation of changes in the general blood test and myelogram; tactics of treatment of thrombocytopenic purpura; basic principles of diagnosis and stages of diagnostic search for patients with purpura; basic principles of treatment of diseases accompanied by purpura; prognosis for the patient; issues of medical rehabilitation and secondary prevention.

Equipment: multimedia materials - a set of thematic slides from the department's multimedia library; screenshots of the results of laboratory (expanded blood analysis) and instrumental (x-ray examination of the chest, ultrasound of the abdominal organs, immuno-serological studies (syphilis, HIV infection, hepatitis B and C) studies ; a set of situational problems on the subject of the lesson.

Plan:

1. Organizational measures (greetings, verification of those present, announcement of the topic, purpose of the lesson, motivation of higher education seekers to study the topic)
2. Control of the reference level of knowledge (checking homework, written work, written testing, including writing KROK-2 tests, frontal survey)
3. Formation of professional skills and abilities (mastery of skills, curation, determination of the treatment scheme, laboratory research, etc.): discussing the features of diagnosis and treatment of patients with lymphadenopathy , the most common clinical manifestations, criteria for establishing a diagnosis
4. Summing up (summarizing the topic, evaluating applicants, discussing the next lesson topic and homework)

Control questions:

1. Which group of diseases do all the haemophilias belong to?
2. Which clinical types of hemorrhages do you know?
3. Complete the table "Types of bleeding and the diagnostic criteria for different types of bleeding"

Type	Clinical features	The most possible diseases and syndromes		Tests For homeostasis disorders revealing
		Congenital	Acquired	
Hematoma-hemarthros				
Petechial spotted				
Mixed				
Vasculitic-purpural				
Angiomatous				

2. Describe the clinical forms of hemorrhagic vasculitis.
3. What are the principles of hemorrhagic vasculitis treatment.
4. What stigma of connective tissue dysplasia are identified in patients with telangiectasia?
5. Due to what connective tissue systemic diseases autoimmune thrombocytopenia arise?
6. Due to what systemic diseases of connective tissue occurs autoimmune inhibition of von Willebrand's factor, I, II, V, VII, VIII, IX, X factors.
7. Define Goodpasture's syndrome, explain the pathogenesis of the disease.
8. What laboratory and instrumental violations detected in patients with Goodpasture's syndrome.
9. What are the most affected with hemophilia joints, what medications are used without delay in such cases?
10. What are the X-ray joint changes found in patients with hemophilia?

Tests:

1. Male of 19 years old, complains about volatile pain in large joints, increased temperature to 38.6°C, chill, weakness, rash on the skin of hands and feet appearance of which is accompanied by an insignificant itching. On the 2nd day of the disease objectively: there is a symmetric, expressly outlined purple rash on the skin of hands and feet, symmetric, with traces of scratches. Mucous membranes are not involved. Large joints are insignificantly edematous, sensitive. Liver and spleen are not enlarged. Blood test: E. - 4.1T/L, Hb. - 138 gr/L, CI - 1.0; Leu. -10.6 G/L, E. - 2%, N/Gr. - 4%, Lymph. - 24%, Mon. - 6%, ESR - 26 mm/h., Plt - 260 G/l. Bleeding time by Duke test - 4 minutes. The most possible diagnosis for a patient is?
 - A. Urticaria
 - B. Verlgof's disease
 - C. Hemorrhagic vasculitis
 - D. Rheumatic polyarthritis
 - E. Vinivarter – Burgher's disease
2. A 15-year-old patient with signs of internal hemorrhage has been taken to a hospital after a fight. He has had haemophilia A since childhood. He has been diagnosed with retroperitoneal hematoma. What should be administered in the first place?
 - A. Dried plasma
 - B. Aminocapronic acid
 - C. Cryoprecipitate
 - D. Platelet concentrate
 - E. Fresh blood
3. A patient complains of weakness, dizziness, appearance of bruises on a skin, nose-bleeding, weight

loss. He is ill for 3 months. On examination: moderate general condition, reduced nutritional status, skin is pale with a presence on the front surface of hands, feet and trunk of differently sized multiple bruises ranging from 0.2 to 3.0 cm. What type of bleeding takes place in a patient?

- A. Angiomatous
- B. Hematomas
- C. Mixed
- D. Vasculitis-purpural
- E. Pete with hial-spotted

4. Young man, 16 years old, hospitalized with complaints about nose bleeding, which did not succeed in being stopped, and severe pain in a right elbow joint. He's been ill since childhood, the same complaints are marked for his cousin. Objectively: the elbow joint is enlarged, deformed, hyperemia and hyperthermia of the skin above it. There are signs of arthropathy in other joints. Breathing is vesicular, heart sounds are muffled, pulse is rhythmic, 90/min., BP is 115/70 mm Hg. Blood test. Er. - .3.9 T/L, Hb. - 130 gr/L, CI - 1.0; Leu - 5.6 G/L, Plt. - 220 G/L, ESR - 6 mm/h. Time of blood coagulation at Li-White test: beginning - 24 min., completion - 27 min. 10 sec. What preparations among listed are the most effective for this patient treatment?

- A. Erythrocytes mass
- B. Calcium chloride solution
- C. Cryoprecipitate
- D. Aminocapronic acid
- E. Vikasol

5 . A 48-year-old man complains of constant pain in the upper abdomen, predominantly on the left, which worsens after eating, diarrhea, loss of weight. The patient has an alcohol use disorder. Two years ago he had a case of acute pancreatitis. Blood amylase is 4 g/hour · l. Feces analysis: steatorrhea, creatorrhea. Blood sugar is 6.0 mmol/l. What treatment should be prescribed?

- A. Panzinormforte (Pancreatin)
- B. Insulin
- C. Gastrozepine (Pirenzepine)
- D. Contrykal (Aprotinin)
- E. No-Spa (Drotaverine)

6 . A 48-year-old woman has been suffering from chronic pancreatitis for the last 7 years. Lately she has been noticing an increase in daily feces with foul smell, abdominal distension, gurgling. The patient complains of diarrhea, weakness, fatigability, loss of appetite, loss of weight. What syndrome can be suspected in this case?

- A. Malabsorption
- B. Irritablecolon
- C. Maldigestion
- D. Exudative enteropathy
- E. Endocrine gland failure

7. A patient, 39 years old, admitted to hospital with complaints about the increase in body temperature, sweating, pain in joints, and back. No clinical effect from antibacterial preparations. Objectively - hemorrhagic rash on the skin of hands, feet. Blood test - Er. - 3.7 T/L, Hb - 110 G/L, Leu - 9.1 G/L, Eos.- 34%, Bas. - 1%, band/n. - 6%, segm/n. - 45%, Lymph. - 9%, Mon. - 5%. Plt. - 280 G/L, ESR - 22 mm/h. Urine analysis - protein - 0.066 g/L. What is the diagnosis for this patient?

- A. Hemorrhagic vasculitis
- B. Polyarteritis nodosa
- C. Glomerulonephritis
- D. Rheumatism
- E. Dermatomyositis

8. Patient 31 years old, complains of increased body temperature, sweating, attacks of difficulty in breathing, pain in muscles, joints, intolerable itching of the whole body. Connects his condition worsening with the vaccination against rabies. Objectively - continuous hemorrhagic rash all over the body. Blood - Er. 4.2 T/L, Leu. - 12.8 G/L, Eos. - 18%, Plt - 240 G/L, ESR - 35 mm/h. Urine - proteins - 0.099g/L, Er. - 9-10, hyaline casts. Your diagnosis is?

- A. Polyarteritis nodosa
- B. Reyer's syndrome
- C. Sarcoidosis
- D. Rheumatic fever
- E. Hemorrhagic vasculitis

9. Woman, 23 years old, complains of an increase in body temperature to 38.4°C, appearance of hemorrhagic rash on lower extremities, mild pain of the back, appearance of red-colored urine. Got sick 3 days ago after overcooling. Objectively: skin is pale, on the surface of shins and thighs there is a small hemorrhagic symmetric rash, HR - 90/min., BP is 115/90 mm Hg. Pasternacki's symptom – weakly positive on both sides. In blood: Leu. - 9.6 G/L, Plt - 115 G/L, ESR - 31 mm/h. In urine: proteins - 0.33 g/L, Er. - changed, 3 - 40 in v/f, Leu. - 5-8 in v/f. For patient's treatment it is necessary to appoint

- A. Prednisone
- B. Cyclophosphamide
- S. Plasmapheresis
- D. Diclofenac sodium
- E. Fresh-frozen plasma

10. A patient 48 years old, complains about rash on the skin of the back, frequent nose-bleeds, dizziness. On the mucous membrane of the tongue - numerous telangiectasia. Reduced nutritional status. Objective examination reveals scapula at different level, costal hump, kyphoscoliosis of spine. RR - 18 in min. HR - 80 min., BP - 120/80 mm Hg. Abdomen is soft on palpation. Er. - 3.0 T/L; Hb - 93 g/L; ESR - 23 mm/h; PLT - 411 g/L; CI - 0.83; Leu. - 3.5 G/L; Eos. - 4%, Lym. - 39%, Mon. - 10%, band/n. - 2%, segm/n. - 45%. PTI - 73%, fibrin of plasma - 3.6 g/L, tolerance to heparin - 7 min., Fibrinogen-B (-). The most possible diagnosis is:

- A. Randu-Osler's disease
- B. Polyarteritis nodosa
- C. Lupus erythematosus
- D. Thrombocytopenic purpura
- E. Hemorrhagic vasculitis

Clinical tasks:

Task #1.

A patient T., 22 years old, after the insignificant trauma of the knee there is a considerable knee enlargement, skin hyperemia above it, acute pain on palpation, mobility is limited, almost impossible because of acute pain. Temperature is 37.8C, slight chill. Gums bleeding and formation of intramuscular hematomas were marked before. Regarding hemarthrosis, he was repeatedly treated in the hematologic and traumatologic departments of the district hospital. From domestic anamnesis: both grandmother's brothers were ill with hemophilia.

Question:

1. Your preliminary diagnosis.
2. What plan of additional examination?
3. What X-ray picture is most credible in this case?
4. Tactics of treatment of patients.

Task #2.

Patient, 23 years old, got sick after the prolonged insolation. A disease began with the increased temperature to 38°C, pain and edema of knee, ankle and small wrist joints, increases of submandibular and arm-pits lymph nodes. On examination: cheeks blush as a "butterfly", on the skin of the stomach and forearm there is a petechial rash. Pulse - 118/min., BP is 150/90 mm Hg. Heart borders are extended to the left on 1.5 cm, sounds are weakened, systolic murmur on an apex. Liver +2 cm. Blood test: Er. -2.8 T/l, L. - 3.2 Gr/l, PLT. - 90 Gr/l. Analysis of urine: protein - 4.2 gr/l, Er. - 40-50 in v/a.

Questions:

1. Your preliminary diagnosis.
2. What plan of additional examination?

3. To work out a plan of treatment of the patient.

Task #3.

Woman 23 years old, grumbles about the increase in body temperature to 37.4°C, appearance of hemorrhagic rash on lower extremities, pain in the small of the back, appearance of red urine. Got sick 3 days ago after supercooling. Objectively: a skin is pale, on the surface of the shins and thighs there is a shallow hemorrhagic symmetric rash. HR- 90/min., BP is 115/90 mm Hg. Pasternacki's symptom is weakly positive on both sides. In blood: L. - a 9.6 Gr/l, PLT. - 115 Gr/l, ESR - 31 mm/h. In urine: protein - 0.33 gr/l, Er. - changed, 3-40 in v/a, L. -5-8 in v/a.

Question:

1. What preliminary diagnosis?
2. What methods of additional examination for diagnosis confirmation?
3. Plan of treatment of this patient.

Summary:

Recommended reading list

Basic literature:

- Harrison's Principles of Internal Medicine Self-Assessment and Board Review, 20th Edition 20th Edition.- (August 13, 2021). - 736 pages
- Pocket Medicine: The Massachusetts General Hospital Handbook of Internal Medicine / 007 edition (12 Sept. 2019). - 272 pages
- Davidson's Principles and Practice of Medicine: Enhanced Digital Version Included / Elsevier; 23rd edition (25 April 2018). - 1440 pages

Additional literature:

- Macleod's Clinical Examination /Elsevier; 14th edition (11 Jun. 2018). - 400 pages
- Current Medical Diagnosis and Treatment /McGraw-Hill Education; Updated edition (14 Sept. 2021). - 1840 pages
- Lippincott Connect Standalone Courseware for Bates' Guide to Physical Examination and History Taking 1.0 /LWW; 13th ed. edition (23 Mar. 2023).
- Step-Up to Medicine / Wolters Kluwer Health; 5th edition (8 May 2019). - 582 pages
- Goldman-Cecil Medicine, 2-Volume Set (Cecil Textbook of Medicine) / Elsevier; 26th edition (20 Dec. 2019). - 2944 pages
- The Washington Manual of Medical Therapeutics / Wolters Kluwer Health; 36th edition (6 Jun. 2019). - 1074 pages
- Harrison's Manual of Medicine / McGraw-Hill Education; 20th edition (5 Nov. 2019). - 1245 pages

Electronic information resources

- World Health Organization. URL: www.who.int/ru/index.html.
- European Regional Office of the World Health Organization. URL: www.euro.who.int.
- <https://www.aasld.org/>
- https://academic.oup.com/ndt/pages/General_Instruction
- <https://cprguidelines.eu/>
- <https://www.escardio.org/Guidelines/Clinical-Practice-Guidelines>
- <http://www.oxfordmedicaleducation.com/>
- <http://ard.bmj.com>
- <https://www.escardio.org/Guidelines/Clinical-Practice-Guidelines>

Practical class

Topic 30. Management of a patient with a complicated hypertensive crisis. Management of a patient with cardiac asthma and pulmonary edema

The main goals: to acquire communication skills and skills of clinical examination of a patient with complicated hypertensive crisis, cardiac asthma and pulmonary edema ; to be able to establish a preliminary diagnosis, carry out a differential diagnosis and determine the clinical diagnosis of the

disease in a patient with a complicated hypertensive crisis, cardiac asthma and pulmonary edema ; master the principles of treatment, recommendations for lifestyle changes in the treatment of patients with complicated hypertensive crisis, cardiac asthma and pulmonary edema ; learn to diagnose emergency conditions in patients with complicated hypertensive crisis, cardiac asthma and pulmonary edema and master the tactics of providing emergency medical aid; to be able to perform therapeutic manipulations in patients with complicated hypertensive crisis, cardiac asthma and pulmonary edema.

Key words: definition of the term hypertensive and complicated hypertensive crisis; diagnostic criteria of complicated hypertensive crisis; the main clinical manifestations of hypertensive crises with the following complications: acute coronary syndrome, acute hypertensive encephalopathy, subarachnoid hemorrhage, ischemic stroke, hemorrhagic stroke, acute left ventricular failure (pulmonary edema), acute stratifying aortic aneurysm; eclampsia and preeclampsia; intra- and postoperative hypertension, hypersympatheticotonia (phaeochromocytoma, cocaine, amphetamine intoxication); features of blood pressure correction (target levels), depending on the damage to the target organ; the main groups of drugs used in complicated hypertensive crises and the peculiarities of their appointment depending on the damage to the target organ; defining the terms acute heart failure, cardiac asthma and pulmonary edema; the main causes of acute heart failure (ACS, hypertensive crisis, arrhythmia, acute mechanical cause, PE).

Equipment: multimedia materials - a set of thematic slides from the department's multimedia library; screenshots of laboratory test results: general blood test, general urine test, levels of urea, creatinine (with calculation of GFR), electrolytes, transaminases, if necessary, determine BNP, NT-proBNP, troponins, levels of aldosterone, renin, catecholamines ; a set of situational problems on the topic of the class; screenshots of instrumental research results: blood pressure monitoring, ECG (determination of rhythm disturbances, signs of ischemia, hypertrophy of the heart), RG of the chest organs (contours of the heart, aorta, signs of congestion in the lungs), echocardiography (heart dimensions, areas of hypokinesis, signs of systolic and diastolic dysfunctions), ultrasound of the pleural cavity, pleural cavity; mannequin for practicing the following practical skills: palpation of the chest, palpation of trigger points (intercostal, paravertebral); percussion and auscultation of lungs and heart.

Plan:

1. Organizational measures (greetings, verification of those present, announcement of the topic, purpose of the lesson, motivation of higher education seekers to study the topic)
2. Control of the reference level of knowledge (checking homework, written work, written testing, including writing KROK-2 tests, frontal survey)
3. Formation of professional skills and abilities (mastery of skills, curation, determination of treatment scheme, laboratory research, etc.): discussing the features of diagnosis and treatment of patients with complicated hypertensive crisis, cardiac asthma and pulmonary edema, the most common clinical manifestations, criteria for establishing a diagnosis
4. Summing up (summarizing the topic, evaluating applicants, discussing the next lesson topic and homework).

The control question:

1. Give the definition of a hypertensive crisis.
2. the crises are separated depending on the tactics of treatment?
3. Describe the complications of hypertensive crises
- 4 Describe uncomplicated hypertensive crisis.
5. What diagnostic test are needed to find damage of target organs in the hypertensive crisis?
6. What is the treatment of complicated hypertensive crisis?
7. What are the tactics of treatment of uncomplicated hypertensive crisis?
8. What is meant by the stabilization of the patient's condition?
9. What is the algorithm of treatment of ischemic and hemorrhagic stroke on the background of hypertensive crisis?
10. What is the algorithm of treatment of acute left ventricular failure on the background of the

hypertensive crisis?

11. What is the algorithm of treatment of acute coronary insufficiency and myocardial infarction on background of the hypertensive crisis?

Tests

1. A 55-year-old patient develops skin pallor, anxiety, irritability, agitation, pain in the heart after a stressful situation. BP - 200/100 mm Hg, heart rate 100 beats per minute. What type of hypertensive crisis occurred in this case?

- A. Cerebral
- B. Cardiac
- C. Adrenergic
- D. Nephrotic
- E. Complex cerebral

2. Hypertensive patient began to complain of weakness, nausea, headache, dull pain in the heart, palpitations. Deterioration in the last 4 days. In the morning noted nosebleed. Pulse 110 per minute, rhythmic, BP - 230/110 mm Hg. What is the most likely diagnosis?

- A. Hemorrhagic stroke
- B. Complicated hypertensive crisis
- C. Paroxysmal tachycardia
- D. Uncomplicated hypertensive crisis
- E. Diencephalic crisis

3. A 60-year-old patient with acute Q-wave myocardial infarction hospitalized with blood pressure rise to 260/120 mm Hg, shortness of breath (36 breaths / minute), bubbling breath, a large number of different-sized moist rales in the lower and middle parts of the lungs on both sides. Heart rate - 100 bpm with rare ventricular extrasystoles. Introduction of which drug is contraindicated in this case?

- A. Lasix (furosemide)
- B. Rheopolyglucin
- C. Morphine
- D. Euphyllin
- E. Lidocaine

4. 58-year-old patient who suffers from symptomatic hypertension, felt "fly"-flickering in the field of vision, headache, sudden dizziness, nausea and vomiting. Objective: altered consciousness, BP: 190/140 mm Hg. Symptoms of focal brain damage were found. Which preparation should be administered first?

- A. Antihypertensive drugs.
- B. Anticoagulants.
- C. Metabolic drugs.
- D. Antioxidants.
- E. Antiplatelet agents.

5. 58-year-old patient who suffers from symptomatic hypertension, felt "fly"-flickering in the field of vision, headache, sudden dizziness, nausea and vomiting. Objective: altered consciousness, BP: 190/140 mm Hg, hand and finger tremor, paresthesia. Your diagnosis?

- A. Acute hypertensive encephalopathy.
- B. Ischemic stroke.
- C. Hemorrhagic stroke.
- D. Transient ischemic attack.
- E. Discirculatory encephalopathy.

6. Male, 65 years old, suffers from arterial hypertension for about 20 years. During intense physical exertion developed headache, nausea, vomiting, weakness of the right arm and leg. BP - 220/100 mm Hg, in 2 hours - 240/190 mm Hg. Treatment tactics?

- A. Hospitalization to the intensive care unit.
- B. Hospitalization to the cardiology department.
- C. Treatment on an outpatient basis at home.
- D. Treatment at day care at the polyclinic.

E. Hospitalization to the neurological department.

7. Hypertensive patient aged 63 complains of severe headache and pain in the back of his neck, nausea, vomiting, which appeared after the stress. Objective: heartbeat is rhythmic, I tone above the apex is weakened, the emphasis of II tone above the aortic valve. BP: 180/150 mm Hg. ECG: sinus bradycardia, ST segment depression, negative T deflection in the left precordial leads. Which of the following combinations of drugs is most appropriate for this patient?

- A. Aspirin+clopidogrel, atenolol, nitroglycerin.
- B. Spironolactone, morphine, captopril.
- C. Propranolol, aspirin+clopidogrel, clonidine.
- D. Nitroglycerin, amlodipine, bisoprolol.
- E. Nitroglycerin, aspirin+clopidogrel, metaclopramide.

8. A 50-year-old patient was admitted with complaints of headache, dizziness, the twinkling of "flies" before his eyes, feeling the heat and shaking the whole body, weakness in his right hand and leg. Objective: PS-92 min., BP - 180/100 mm Hg, accent of II tone above aortic valve. Urinalysis during the crisis - protein 0.033 g/L; Er 4-8 in a field of view. What pathological condition has developed in a patient?

- A. Complicated hypertensive crisis.
- B. Uncomplicated hypertensive crisis.
- C. Epileptiform crisis.
- D. Thyrotoxic crisis.
- E. Addison's crisis.

9. The patient G., age 63, has a long-term history of hypertension and does not receive adequate treatment, suddenly developed increased blood pressure, intense constricting pain behind the breastbone radiating to his left hand and to the shoulder and under the left scapula, which was accompanied by cardiac arrhythmia, and malaise. Objective: patient is overweight, hyperemia of the skin, heart sounds of normal volume, accent of II tone above aorta, heart rate 76 bpm, BP - 240/130 mm Hg. ECG: ST-segment depression in V2 - V5 for 3 mm. Your diagnosis?

- A. Pulmonary embolism.
- B. Uncomplicated hypertensive crisis.
- C. Malignant hypertension.
- D. Kussmaul's coma
- E. Complicated hypertensive crisis.

10. Patient aged 47, complains of sudden headache, shortness of breath, pain in the heart. Objective: BP 190/95 mmHg, Pulse - 106 per minute, regular, intense. In the lungs - a hard breathing sounds. Which drug should be administered first?

- A. Nifedipine 30 mg sublingual.
- B. Clonidine 0.075 mg sublingual.
- C. Labetalol 20 mg intravenous
- D. Aminazin 25 mg intramuscular
- E. Dibazol 1% - 4 ml intramuscular

Clinical tasks:

Task No. 1.

The patient, 44 years old, who suffers from hypertension, headache, "internal" tremor, palpitations, fear. OBJECTIVE: Pulse - 100 in 1 min, BP - 200/100 mm Hg. Art., the left border of cardiac dullness shifted by 1.5 cm to the left of the left mid-clavicular lines, the sonorous tones at the upper heart, vesicular breath. The ECG: sinus tachycardia, signs of left ventricular hypertrophy.

Questions:

1. What type of crisis has developed in a patient?
2. Which drug should be assigned to the emergency room?

Task No. 2.

A woman aged 63, suddenly started choking at night. About 15 years suffering from hypertension, 2 years ago suffered a myocardial infarction. OBJECTIVE: The situation in bed - orthopnea, pale skin,

the patient is covered with cold sweat, acrocyanosis. Pulse - 104/min. BP - 210/130 mm Hg. Art., RR - 38 min. P ulmonary percussion sounds, in the lower is dull , upperlung isolated dry rales . In the lower sections - small bubbling.

Questions:

1. What complications developed in a patient?
2. Which algorithm for urgent assistance in this case?

Task No. 3.

The patient, aged 59, who suffered 15 years of hypertension on the background of hypertensive crisis developed acute left ventricular failure.

Questions:

1. Which drug should be assigned to this patient in the first place?
2. What are the principles of treatment of acute left ventricular failure?

Summary:

Recommended reading list

Basic literature:

- Harrison's Principles of Internal Medicine Self-Assessment and Board Review, 20th Edition 20th Edition.- (August 13, 2021). - 736 pages
- Pocket Medicine: The Massachusetts General Hospital Handbook of Internal Medicine / 007 edition (12 Sept. 2019). - 272 pages
- Davidson's Principles and Practice of Medicine: Enhanced Digital Version Included / Elsevier; 23rd edition (25 April 2018). - 1440 pages

Additional literature:

- Macleod's Clinical Examination /Elsevier; 14th edition (11 Jun. 2018). - 400 pages
- Current Medical Diagnosis and Treatment /McGraw-Hill Education; Updated edition (14 Sept. 2021). - 1840 pages
- Lippincott Connect Standalone Courseware for Bates' Guide to Physical Examination and History Taking 1.0 /LWW; 13th ed. edition (23 Mar. 2023).
- Step-Up to Medicine / Wolters Kluwer Health; 5th edition (8 May 2019). - 582 pages
- Goldman-Cecil Medicine, 2-Volume Set (Cecil Textbook of Medicine) / Elsevier; 26th edition (20 Dec. 2019). - 2944 pages
- The Washington Manual of Medical Therapeutics / Wolters Kluwer Health; 36th edition (6 Jun. 2019). - 1074 pages
- Harrison's Manual of Medicine / McGraw-Hill Education; 20th edition (5 Nov. 2019). - 1245 pages

Electronic information resources

- World Health Organization. URL: www.who.int/ru/index.html.
- European Regional Office of the World Health Organization. URL: www.euro.who.int.
- <https://www.aasld.org/>
- https://academic.oup.com/ndt/pages/General_Instruction
- <https://cprguidelines.eu/>
- <https://www.escardio.org/Guidelines/Clinical-Practice-Guidelines>
- <http://www.oxfordmedicaleducation.com/>
- <http://ard.bmj.com>
- <https://www.escardio.org/Guidelines/Clinical-Practice-Guidelines>

Practical class

Topic 31. Management of a patient with acute coronary syndrome. Management of a patient with myocardial infarction. Management of a patient with cardiogenic shock.

The main goals:to acquire communication skills and skills of clinical examination of a patient with acute coronary syndrome, myocardial infarction ; to be able to establish a preliminary diagnosis, carry out a differential diagnosis and determine the clinical diagnosis of the disease in a patient with acute

coronary syndrome, myocardial infarction ; master the principles of treatment, recommendations for lifestyle changes in the management of patients with acute coronary syndrome, myocardial infarction ; learn to diagnose emergency conditions in patients with acute coronary syndrome, myocardial infarction and master the tactics of providing emergency medical aid; to be able to perform therapeutic manipulations in patients with acute coronary syndrome, myocardial infarction .

Key words:modern definition of acute coronary syndrome (ACS) and myocardial infarction (AMI); main issues in the etiology and pathogenesis of GCS; GKS classification (ICD-10 and recommended by WHO); variants of the clinical course of ACS and AMI; ECG diagnosis of GCS; laboratory and biochemical diagnosis of GCS; stages of differential diagnosis according to the leading syndrome; complications of ACS and AMI; principles of treatment of GCS and its complications; rehabilitation of patients after GCS.

Equipment:multimedia materials - a set of thematic slides from the department's multimedia library; screenshots of laboratory test results: general blood test, general urine test, levels of urea, creatinine (with calculation of GFR), electrolytes, transaminases, if necessary, determine BNP, NT-proBNP, troponins, levels of aldosterone, renin, catecholamines ; a set of situational problems on the topic of the class; screenshots of instrumental research results: blood pressure monitoring, ECG (determination of rhythm disturbances, signs of ischemia, hypertrophy of the heart), RG of the chest organs (contours of the heart, aorta, signs of congestion in the lungs), echocardiography (heart dimensions, areas of hypokinesis, signs of systolic and diastolic dysfunctions), ultrasound of the pleural cavity, pleural cavity; mannequin for practicing the following practical skills: palpation of the chest, palpation of trigger points (intercostal, paravertebral); percussion and auscultation of lungs and heart.

Plan:

1. Organizational measures (greetings, verification of those present, announcement of the topic, purpose of the lesson, motivation of higher education seekers to study the topic)
2. Control of the reference level of knowledge (checking homework, written work, written testing, including writing KROK-2 tests, frontal survey)
3. Formation of professional skills and abilities (mastery of skills, curation, determination of treatment scheme, laboratory research, etc.): discussing the features of diagnosis and treatment of patients with complicated hypertensive crisis, cardiac asthma and pulmonary edema, the most common clinical manifestations, criteria for establishing a diagnosis
4. Summing up (summarizing the topic, evaluating applicants, discussing the next lesson topic and homework).

Control questions:

1. Give the definition of acute coronary syndrome (ACS).
2. Explain the difference between the ACS without ST-segment elevation (NSTEMI) and with segment ST elevation (STEMI).
3. List the clinical diagnostic criteria for ACS.
4. What examination methods are required for patients with ACS without segment ST elevation?
5. List the ECG criteria for ACS.
6. What are the biochemical markers of ACS, what do they mean?
7. Basic principles of treatment of ACS.
8. What are the criteria of the effectiveness of treatment of ACS?
9. What distinguishes the treatment of patients with ACS with and without ST segment elevation?

Tests

1. Female 46 years complains of gripping pain behind the sternum, which first appeared 8 hours ago after physical exertion, not relieved after nitroglycerin. Objectively: HR - 80/min., RR - 18/min., BP - 120/80 mmHg. The ECG: 2 mm ST segment depression in II, III, aVF leads. What preliminary diagnosis should be established in this case?
A. Acute coronary syndrome.

- B. Angina pectoris
- C. Myocardial infarction.
- D. Myocarditis.
- E. Pericarditis.

2. A patient of 59 years complains of retrosternal pain lasting over 1 hour, shortness of breath. Takes a sitting position in bed. Objectively: RR - 24/min. In lungs - wet fine bubbling rales in the lower parts. BP - 110/60 mm Hg, pulse - 92/min., heart sounds are muffled. Urgent ECG: ST segment elevation 5 mm in leads V1-V4. What is the most expedient method of treatment in such cases?

- A. Appointment of calcium antagonists
- B. The use of beta-adrenomimetics
- C. Use of digoxin with aminophylline
- D. Appointment of thrombolytic drugs
- E. Use of angiotensin-converting enzyme

3. A previously healthy 47-year-old male was admitted to the hospital with sharp pain in the epigastric region, nausea, vomiting, dizziness, general weakness. Pulse 110 per minute, BP - 90/60 mm Hg. Heart sounds are muffled. Abdomen is soft and painless on palpation. What investigation should be done first?

- A. ECG.
- B. Clinical analysis of blood.
- C. Fibrogastroscopy.
- D. X-ray of the stomach.
- E. Ultrasound of the abdominal cavity.

4. Female 46 years complains of gripping pain behind the sternum, which first appeared 8 hours ago after physical exertion, not relieved after nitroglycerin. Objectively: HR - 80/min., RR - 18/min., BP - 120/80 mmHg. The ECG: 2 mm ST segment depression in II, III, aVF leads. What treatment is most appropriate for this patient?

- A. Beta-blocker, aspirin, clopidogrel, heparin.
- B. Beta-blocker, aspirin, streptokinase, nitrates.
- C. Beta-blockers, aspirin, nitrates, ACE-inhibitors.
- D. Diuretics, aspirin, nitrates, calcium channel blockers.
- E. ACE inhibitors, aspirin, streptokinase, nitrates.

5. A 55-year-old patient complains of severe pain behind the sternum and in the epigastrium, nausea. Complaints first appeared 3 hours before admission. BP 120/70 mmHg., pulse 80 per min., arrhythmic. Moist rales above the lower regions of the lungs. ECG: ST segment elevation in II, III, aVF leads, ST depression in V1-V4. What is the preliminary diagnosis of this patient?

- A. Anterior non-ST segment elevation myocardial infarction
- B. Anterior ST segment elevation myocardial infarction
- C. Pulmonary embolism
- D. Cardiogenic shock
- E. Posterior ST segment elevation myocardial infarction

6. Patient 54 years old, hospitalized with complaints of burning, squeezing pain behind the sternum, not relieved by nitroglycerin with irradiation to the left shoulder, increasing shortness of breath. Objectively: skin pale, heart rate - 112 per minute., rhythmic, weak. BP - 70/50 mm Hg, heart sounds muffled. Vesicular breathing. The abdomen is soft and painless. ECG: sinus rhythm, reduced voltage of R waves, ST segment elevation above isoline and negative T in leads I, II, aVL, V1-V 4. What complication arose?

- A. Cardiogenic shock.
- B. Collapse.
- C. Cardiac asthma
- D. Rupture of the interventricular septum.
- E. Aneurysm of the heart.

7. Patient 55 years, suffering from angina pectoris for 5 years, complains of sudden intense burning pain behind the sternum, which lasts for 2.5 hours. The ECG shows sinus rhythm, heart rate 100/min, ST segment elevation in V3-V6 for 8 mm above the isoline. Heart sounds muffled. BP - 140/90

mmHg. What steps should take priority in such an emergency?

- A. Inhalation of oxygen.
- B. Infusion and dopamine.
- C. Thrombolytic therapy.
- D. Electrocardiostimulation.
- E. heparin infusion

8. The patient aged 56 complains of squeezing pain behind the sternum, which appeared after physical exertion. He took 3 tablets of nitroglycerin at intervals of 5 minutes. An objective examination of pulse rate - 88 / min., rhythmic, BP - 140/90 mm Hg.; heart sounds weakened. You need to assign:

- A. Intravenous infusion of 0.01% solution of nitroglycerin.
- B. Introduce another 1 tablet of nitroglycerin sublingually .
- C. Nitroglycerin sublingual spray.
- D. Nitroglycerin transdermal patches.
- E. 2% nitroglycerin ointment.

9. The patient 60 years old with a diagnosis of coronary heart disease, acute coronary syndrome. After violation of bed regimen patient's condition worsened: increased pain in the chest, shortness of breath and general weakness appeared, BP - 80/50 mmHg, heart rate - 110 per minute. Upper lungs - moist rales, the patient is covered with a cold sticky sweat. Which drug should be administered for the correction of hemodynamics?

- A. Cordiamine.
- B. Phenylephrine.
- C. Dopamine.
- D. Strophanthin.
- E. Prednisolone.

10. Patient 49 years old, complains of intense, squeezing pain behind the sternum, which arose after the stress, lasted over an hour, did not decrease after taking three tablets of nitroglycerin. Previously, such pain stopped after taking a nitroglycerin tablet, lasted no more than 10-15 min., or occurred only after considerable physical exertion. The patient's condition is moderate, acrocyanosis, pulse rate 100/min., BP - 150/100 mmHg. The ECG shows horizontal ST depression in leads V1-V5 of -0.4 mV. Your diagnosis?

- A. STEMI
- B. Stable angina, FC II.
- C. NSTEMI
- D. Acute pericarditis.
- E. Hypertensive crisis.

Clinical tasks:

Task No. 1.

Male 42 years old taken to hospital with complaints of squeezing, burning pain in the heart area radiating to the left shoulder and left shoulder, shortness of breath, severe weakness. Pain appeared for the first time in his life after an emotional stress, lasting about an hour. OBJECTIVE: Pulse - 98 per minute., Rhythmical. BP - 130/80 mmHg.. Heart sounds are muffled, no murmur. The ECG: ST-segment depression and negative T in a tine leads I, AVL, V1-V4.

Questions:

1. What is the most likely diagnosis?
2. What kind of emergency assistance should be provided to the patient?

Task No. 2.

The patient aged 42, half an hour ago a burning pain appeared behind the breastbone radiating to his left arm and sharp general weakness. Condition is moderate, clear consciousness. The skin is pale, cyanosis of the lips. Tone deaf heart, rhythmic, heart rate - 86/ min., BP - 120/80 mm Hg. Vesicular breath. The ECG - ST segment elevation of 3 mm in leads I, AVL, V1-V4.

Questions:

1. Which state has developed in a patient?

2. What additional methods should be applied in this case?
3. Which drug should be appointed in the first place?

Task No. 3.

A man aged 42 was brought to the hospital, complaining of pain in the epigastric area, nausea, vomiting which appeared after consuming fatty foods. The case history: peptic ulcer disease. OBJECTIVE: Upper lung auscultated vesicular breathing, RR - 18 /min. Heart sounds are muffled, heart rate and pulse correspond to the value of 92 minutes., BP - 130/80 mmHg. The abdomen was soft, sensitive during palpation, no symptoms of irritation of the peritoneum. In the blood: Hb - 140 g / l, l. - $9.2 \cdot 10^9 / l$, ESR -17 mm / hour. Urinary diastase - 64 units. Data SPL: concretion in the gallbladder. The ECG: in leads II, III and avF ST elevate above the baseline at 3 mm, T waves positive.

Questions:

1. What is the most probable cause of the deterioration of the patient?
2. Between what diseases should be a differential diagnosis in this case?

Summary:

Recommended reading list

Basic literature:

- Harrison's Principles of Internal Medicine Self-Assessment and Board Review, 20th Edition 20th Edition.- (August 13, 2021). - 736 pages
- Pocket Medicine: The Massachusetts General Hospital Handbook of Internal Medicine / 007 edition (12 Sept. 2019). - 272 pages
- Davidson's Principles and Practice of Medicine: Enhanced Digital Version Included / Elsevier; 23rd edition (25 April 2018). - 1440 pages

Additional literature:

- Macleod's Clinical Examination /Elsevier; 14th edition (11 Jun. 2018). - 400 pages
- Current Medical Diagnosis and Treatment /McGraw-Hill Education; Updated edition (14 Sept. 2021). - 1840 pages
- Lippincott Connect Standalone Courseware for Bates' Guide to Physical Examination and History Taking 1.0 /LWW; 13th ed. edition (23 Mar. 2023).
- Step-Up to Medicine / Wolters Kluwer Health; 5th edition (8 May 2019). - 582 pages
- Goldman-Cecil Medicine, 2-Volume Set (Cecil Textbook of Medicine) / Elsevier; 26th edition (20 Dec. 2019). - 2944 pages
- The Washington Manual of Medical Therapeutics / Wolters Kluwer Health; 36th edition (6 Jun. 2019). - 1074 pages
- Harrison's Manual of Medicine / McGraw-Hill Education; 20th edition (5 Nov. 2019). - 1245 pages

Electronic information resources

- World Health Organization. URL: www.who.int/ru/index.html.
- European Regional Office of the World Health Organization. URL: www.euro.who.int.
- <https://www.aasld.org/>
- https://academic.oup.com/ndt/pages/General_Instruction
- <https://cprguidelines.eu/>
- <https://www.escardio.org/Guidelines/Clinical-Practice-Guidelines>
- <http://www.oxfordmedicaleducation.com/>
- <http://ard.bmj.com>
- <https://www.escardio.org/Guidelines/Clinical-Practice-Guidelines>

Practical class

Topic 32. Management of a patient with pulmonary embolism. Treatment tactics for sudden cardiac death.

The main goals:to acquire communication skills and clinical examination skills of a patient with

pulmonary embolism ; to be able to establish a preliminary diagnosis, carry out a differential diagnosis and determine the clinical diagnosis of the disease in a patient with pulmonary embolism ; master the principles of treatment, recommendations for lifestyle changes in the management of patients with pulmonary embolism ; learn how to diagnose emergency conditions in patients with pulmonary embolism and master the tactics of providing emergency medical aid in case of sudden cardiac death; to be able to perform therapeutic manipulations in patients with pulmonary embolism .

Key words: definition of the BODY; etiology and pathogenesis of PE; clinic and course of PE; differential diagnosis of PE ; treatment tactics for PE ; basic laboratory-instrumental methods of cardiovascular system research; interpretation of ECG, evaluation of ECHO-CG data in PE; interpretation of the main laboratory, instrumental, radiation, radiological, ultrasound methods of examination of patients with PE, in determining the indications and contraindications for their implementation; emergency care for PE at the pre-hospital and hospital stages.

Equipment: multimedia materials - a set of thematic slides from the department's multimedia library; screenshots of laboratory test results (general blood test, general urine test, levels of LDH, urea, creatinine (with calculation of GFR), electrolytes, transaminases, markers of thrombus formation, D - dimer, markers of myocardial damage) ; screenshots of the results of instrumental research (ECG, RG of chest organs, EchoCS, CT or selective angiography, angiopulmonography) ; a set of situational problems on the subject of the lesson.

Plan:

1. Organizational measures (greetings, verification of those present, announcement of the topic, purpose of the lesson, motivation of higher education seekers to study the topic)
2. Control of the reference level of knowledge (checking homework, written work, written testing, including writing KROK-2 tests, frontal survey)
3. Formation of professional skills and abilities (acquisition of skills, curation, determination of a treatment scheme, laboratory research, etc.): discussing the specifics of diagnosis and treatment of patients with pulmonary embolism, treatment tactics for sudden cardiac death, the most common clinical manifestations, criteria for establishing diagnosis
4. Summing up (summarizing the topic, evaluating applicants, discussing the next lesson topic and homework)

Control questions:

1. Describe risk factors for pulmonary embolism.
2. Describe the typical complaints of the patient with pulmonary embolism.
3. Which diagnostic methods are the first line of tests for suspected pulmonary embolism?
4. Describe ECG symptoms of pulmonary embolism.
5. What are the radiological criteria for pulmonary embolism?
6. What is the diagnostic value of cardiac ultrasound in pulmonary embolism?
7. What are the main principles of treatment of pulmonary embolism?
8. Describe indications and contraindications for thrombolytic therapy.
9. What is the approach to patients with pulmonary embolism?
10. Describe the surgical methods of treatment of pulmonary embolism.

Tests

1. A 48-year-old patient complains of sharp pain in the chest, coughing up blood, shortness of breath during physical exertion, weakness. Thrombophlebitis of lower extremities in anamnesis. Objective: skin diffusely cyanotic, pulsation of jugular veins. Respiratory rate - 37 per min. Dull percussion sound above the lower lobe of the left lung. Pleural rub on auscultation. Rhythmic activity of the heart, the frequency of 120 per minute., BP - 100/60 mmHg, muted tones, a gallop rhythm. Accent of II tone above pulmonary artery. Liver is 3 cm below the costal arch. What are the most informative methods of diagnosis in this clinical situation?
A. Complete blood count

B. Ultrasonography of the abdomen

C. D-dimer level

D. C-RP level

E. AsT, AIT levels

2. Geriatric patient presented with sudden appearance of shortness of breath, sharp pain behind the sternum, dry cough, dizziness. On examination - the general condition of the patient is serious, pronounced inspiratory dyspnea, cyanosis of the skin, pathological pulsation in the epigastric region. Percussion reveals the expansion of cardiac dullness to the right, at auscultation - the emphasis and splitting of II tone over the pulmonary artery. What ECG changes are possible in the patient?

A. Overloading the left ventricle.

B. Electrical axis deviation to the left.

C. Complete AV block.

D. Q - III S - I sign

E. The appearance of QS wave.

3. The patient is 63 years old, complains of intense pain in the right half of the chest, dyspnea, hemoptysis, which occurred suddenly during physical exertion. His condition is serious. Diffuse cyanosis. Heart sounds are muffled, accent of II tone above pulmonary artery. Moist rales in the lower lobe of the right lung. BP - 110/90 mmHg, ECG: right electrical axis deviation, SI Q-III sign, "P-pulmonale" in II and III leads. What is the probable diagnosis?

A. Pulmonary embolism.

B. Acute myocardial infarction.

C. Pneumothorax.

D. Acute cholecystitis.

E. Right-sided pneumonia.

4. A 54-year-old male with a history of thrombophlebitis of the lower extremities and bronchial asthma complains of pain behind the sternum. Suddenly the patient lost consciousness. ECG: heart rate - 130 per minute., deep Sin I and Q in III standard leads, ST segment elevation in III, aVF leads. Which group of drugs is most appropriate in this case?

A. ACE inhibitors.

B. Nitrates.

C. Beta-blockers.

D. Calcium antagonists.

E. Thrombolytics.

5. A 57-year-old female had been treated at the surgical department for acute lower-extremity thrombophlebitis. On the 7th day of treatment she suddenly developed pain in the left part of the chest, dyspnea and cough. Body temperature was 36.2°C, respiratory rate - 36/min. The patient was also found to have diminished breath sounds without wheezing. Ps - 142/min, thready. AP - 70/50 mm Hg. The ECG shows S1-QIII syndrome. What is the most likely diagnosis?

A. Cardiac asthma

B. Myocardial infarction

C. Pulmonary embolism

D. Bronchial asthma

E. Pneumothorax

6. Patient 65 years old, preparing for the surgical treatment for varicose veins of the left leg. While walking upstairs felt sudden weakness and lost consciousness. The upper half of the thorax is cyanotic. The lower lobe of the left lung - decreased vesicular breathing. Heart rate - 140 per minute, RR - 40 /min., BP - 65/40 mmHg. ECG: SI Q-III symptom, complete right bundle branch block, negative T in leads III, aVF, V1-V3. What radiographic manifestations are possible in this condition?

A. The expansion and deformation of the roots of the lungs.

B. Increased transparency of lung tissue.

C. Rounded shadow with clear contours in the lower lobe of the left lung.

D. Absence of blood circulation in several lung segments at pulmonary CT angiography.

E. Pulmonary atelectasis.

7. A woman of 65 years, who has a long history of deep vein thrombophlebitis of the lower limbs,

suddenly began choking, coughing with sputum mixed with blood, pain behind the sternum with irradiation to the right side. Pulse rate - 110/min., BP 90/50 mmHg. The ECG: deep SI and Q III. What pathological condition should be suspected in a patient?

- A. Pulmonary embolism.
- B. Acute pneumonia.
- C. Spontaneous pneumothorax.
- D. Myocardial infarction.
- E. Dry pleurisy.

8. Five days after a total hip joint replacement, a 72-year-old woman becomes acutely short of breath, diaphoretic and hypotensive. Both lung fields are clear to auscultation and percussion, but examination of the neck reveals mild jugular venous distension with prominent A waves. Heart sounds are normal. ECG shows sinus tachycardia with a new right bundle branch block and minor nonspecific ST-T wave changes. The most likely diagnosis is:

- A. Aspiration
- B. Pulmonary embolism
- C. Aortic dissection
- D. Acute myocardial infarction
- E. Pericarditis

9. A 77-year-old patient has obesity and varicose vein disease of the lower extremities, complains of shortness of breath, cough, pain in the chest, pain in the right hypochondrium. Objective: skin paleness, blood pressure 115/70 mmHg, RR-36 /min., temp. =37.8 o C, ECG – SI Q-III syndrome. Auscultation: breathing sounds are hard, multiple dry rales. Your preliminary diagnosis?

- A. Pulmonary embolism.
- B. Necrotizing pneumonia.
- C. Myocardial infarction.
- D. Bronchial asthma.
- E. Cardiomyopathy.

10. A patient with varicose vein disease of the lower extremities, suddenly developed sharp pain in the right chest, hemoptysis, pronounced weakness, dizziness. Objectively: cyanosis of the neck, face. PS - 116 per minute, arrhythmic. BP- 110/70 mmHg, heart sounds weakened. RR - 26/min. Auscultation: moist small bubbling rales on the right. The ECG - QS in the III standard lead. Which drug should be prescribed?

- A. Streptokinase.
- B. Cordiamine.
- C. Digoxin.
- D. Sodium nitroprusside.
- E. Phentolamine

Clinical Tasks:

Task No. 1.

The patient's 60 years old, on the third day after venectomy due to thrombophlebitis of subcutaneous veins, suddenly appeared sense of lack of air, cyanotic, expressed psychomotor agitation, tachypnoea, retrosternal pain.

Questions:

1. What is the complication of the postoperative period occurs in this case?
2. What are the ECG criteria for this complication?

Task No. 2.

Patient 60 years old, presents at the emergency department with severe chest pain and hemoptysis. He suffers from varicose veins of the lower extremities. OBJECTIVE: in a serious condition, asthma, gray cyanosis. Swollen neck veins. Heart rate - 130 per minute. BP - 90/70 mm Hg. Above the apex of the heart I relaxed tone, accentuation of II sound in intercostal space on the left. In the lungs, the right - moist rales, pleural rub.

Questions:

1. What complications developed in a patient?
2. What is the most appropriate emergency treatment at this point?

Task No. 3.

Patient K., 74 yrs. old, with history - thrombophlebitis of lower extremities, have nausea, pain behind the sternum, then the loss of consciousness. ECG: Heart rate - 130 per minute., Deep S in I and Q in III standard leads, ST segment elevation in III, AVF.

Questions:

1. What complications developed in a patient?
2. The most appropriate treatment at this point?

Summary:

Recommended reading list

Basic literature:

- Harrison's Principles of Internal Medicine Self-Assessment and Board Review, 20th Edition 20th Edition.- (August 13, 2021). - 736 pages
- Pocket Medicine: The Massachusetts General Hospital Handbook of Internal Medicine / 007 edition (12 Sept. 2019). - 272 pages
- Davidson's Principles and Practice of Medicine: Enhanced Digital Version Included / Elsevier; 23rd edition (25 April 2018). - 1440 pages

Additional literature:

- Macleod's Clinical Examination /Elsevier; 14th edition (11 Jun. 2018). - 400 pages
- Current Medical Diagnosis and Treatment /McGraw-Hill Education; Updated edition (14 Sept. 2021). - 1840 pages
- Lippincott Connect Standalone Courseware for Bates' Guide to Physical Examination and History Taking 1.0 /LWW; 13th ed. edition (23 Mar. 2023).
- Step-Up to Medicine / Wolters Kluwer Health; 5th edition (8 May 2019). - 582 pages
- Goldman-Cecil Medicine, 2-Volume Set (Cecil Textbook of Medicine) / Elsevier; 26th edition (20 Dec. 2019). - 2944 pages
- The Washington Manual of Medical Therapeutics / Wolters Kluwer Health; 36th edition (6 Jun. 2019). - 1074 pages
- Harrison's Manual of Medicine / McGraw-Hill Education; 20th edition (5 Nov. 2019). - 1245 pages

Electronic information resources

- World Health Organization. URL: www.who.int/ru/index.html.
- European Regional Office of the World Health Organization. URL: www.euro.who.int.
- <https://www.aasld.org/>
- https://academic.oup.com/ndt/pages/General_Instruction
- <https://cprguidelines.eu/>
- <https://www.escardio.org/Guidelines/Clinical-Practice-Guidelines>
- <http://www.oxfordmedicaleducation.com/>
- <http://ard.bmj.com>
- <https://www.escardio.org/Guidelines/Clinical-Practice-Guidelines>

Practical class

Topic 33. Management of a patient with paroxysmal rhythm and conduction disord.

The main goals: to acquire communication skills and skills of clinical examination of a patient with paroxysmal rhythm and conduction disorders ; to be able to establish a preliminary diagnosis, carry out a differential diagnosis and determine the clinical diagnosis of the disease in a patient with paroxysmal rhythm and conduction disorders ; master the principles of treatment, recommendations for lifestyle changes in the management of patients with paroxysmal rhythm and conduction disorders ; learn to diagnose emergency conditions in patients with paroxysmal rhythm and conduction disorders and master the tactics of providing emergency medical aid; to be able to perform therapeutic manipulations

in patients with paroxysmal rhythm and conduction disorders .

Key words: anatomical structure of the conducting system of the heart and physiological bases of its functioning; electrocardiogram indicators in healthy people; pathogenesis of heart rhythm and conduction disorders; classification of heart rhythm and conduction disorders; typical clinical manifestations of heart rhythm and conduction disorders; modern methods of instrumental examination of patients with heart rhythm and conduction disorders; leading syndrome of cardiac or conduction rhythm disturbance; formulation of preliminary and final diagnosis.

Equipment:multimedia materials - a set of thematic slides from the department's multimedia library; screenshots of laboratory test results (general blood test, general urinalysis, levels of LDH, urea, creatinine (with calculation of GFR), electrolytes, transaminases, markers of thrombus formation, markers of myocardial damage) ; screenshots of instrumental research results (ECG, RG of chest organs, echocardiography, CT scan) ; a set of situational problems on the subject of the lesson.

Plan:

1. Organizational measures (greetings, verification of those present, notification of the topic, purpose of the lesson, motivation of higher education seekers to study the topic)
2. Control of the reference level of knowledge (checking homework, written work, written testing, including writing KROK-2 tests, frontal survey)
3. Formation of professional abilities and skills (mastery of skills, curation, determination of the treatment scheme, laboratory research, etc.): discussing the specifics of diagnosis and treatment of patients with paroxysmal rhythm and conduction disorders, the most common clinical manifestations, criteria for establishing a diagnosis
4. Summing up (summarizing the topic, evaluating applicants, discussing the next lesson topic and homework)

The control question:

1. Give the definition of paroxysmal arrhythmias.
2. What is the management of haemodynamically unstable patients with narrow complex tachycardia?
3. Describe the algorithm of vagal maneuvers?
4. What are the etiological factors that can lead to paroxysmal arrhythmias and conduction disorders?
5. What are the general principles of diagnostics of paroxysmal arrhythmias?
6. What are the ECG criteria for supraventricular arrhythmias?
7. What are the ECG criteria for ventricular arrhythmias?
8. List the general principles of treatment of paroxysmal arrhythmias.
9. What are the general principles of diagnosis of conduction disorders ?
10. List the general principles of treatment of conduction disorders.

Tests

1. A 54-year-old man admitted to hospital after intense physical exertion when burning pain behind the sternum appeared, radiating to the left hand, without effect after sublingual nitroglycerin, lasted 1.5 hours. ECG - ST segment elevation in leads I, II, aVL, V2 - V4 up to 0.3 mV. After intravenous injection of 100 mg of tissue plasminogen activator, retrosternal pain reappeared, followed by shortness of breath, blood pressure 80/45 mmHg. ECG - signs of ventricular tachycardia 200 per minute. What urgent measures should be taken?
 - A. Electric cardioversion.
 - B. Intravenous injection of lidocaine.
 - C. Temporary endocardial ECS.
 - D. Intravenous amiodarone.
 - E. Appointment of blood transfusion.
2. Patient G., aged 68, long-suffering coronary heart disease, has a history of myocardial infarction. Suddenly there was an attack of palpitations, loss of consciousness after emotional stress. Objectively: patient's condition is severe, skin is moist, pale. Pulse and heart rate cannot be counted. BP - 110/80

mmHg. ECG: Heart rate - 240 per min., QRS complexes are 0.14 sec. What is the best pharmacological intervention in this patient?

- A. Lidocaine.
- B. Strophantin
- C. Verapamil.
- D. Propranolol

E. Sodium adenosine triphosphate.

3. A 42-year-old patient suddenly felt an episode of heartbeat, which was accompanied by general weakness, shortness of breath, heart rate of 170 per minute. ECG: heart rate - 180 per minute, regular rhythm, QRS - 0.10 sec. After the massage of the carotid sinus there was a decrease in heart rate down to 75 bpm. What kind of rhythm disorder was registered in the patient?

- A. Sinus tachycardia.
- B. Supraventricular paroxysmal tachycardia.
- C. Ventricular paroxysmal tachycardia.
- D. Paroxysm of atrial fibrillation.
- E. Ventricular premature beats.

4. A 70-year-old patient with a constant form of atrial fibrillation developed ventricular fibrillation. How can we confirm ventricular fibrillation?

- A. According to the ECG.
- B. In the absence of a pulse.
- C. In the absence of BP.
- D. In case of signs of shock.
- E. In the presence of dilated pupils.

5. A 54-year-old patient with a history of angina pectoris complains of shortness of breath and pain that emerged for the first time on the background of frequent palpitations. Objectively: pulse 120-140 per minute, arrhythmic, BP - 160/100 mm Hg, on the ECG P wave is not determined, RR intervals are different, QRS is not deformed. What kind of arrhythmia can be suspected in this patient?

- A. Ventricular fibrillation.
- B. Sinus arrhythmia.
- C. Supraventricular paroxysmal tachycardia.
- D. Ventricular paroxysmal tachycardia.
- E. Atrial fibrillation.

6. The patient 48 years old, delivered to the hospital due to unconsciousness. His condition is serious, dilated pupils, reacting to light. Breathing is noisy, pulse at radial and carotid arteries is not detectable. BP - 40/20 mmHg. ECG - ventricular fibrillation with a frequency of 210 min. What should be done first?

- A. Intravenous injection of epinephrine with atropine.
- B. Intravenous injection of lidocaine.
- C. Defibrillation
- D. Intravenous amiodarone.
- E. External cardiac massage.

7. A 54-year-old patient with a history of angina pectoris complains of shortness of breath and pain that emerged for the first time on the background of frequent palpitations. Objectively: pulse 120-140 per minute, arrhythmic, BP - 160/100 mm Hg, on the ECG P wave is not determined, RR intervals are different, QRS is not deformed. What drug is most effective in this case?

- A. Metoprolol.
- B. Digoxin.
- C. Verapamil.
- D. Lidocaine.
- E. Amiodarone.

8. A 60-year-old patient suffering from coronary heart disease was taken to the intensive care unit with paroxysmal arrhythmia, which started an hour before hospitalization. Pale, moist skin, swelling of the neck veins. BP - 80/60 mmHg, tachycardia. ECG: heart rate - 220 per minute, rhythm is irregular, P not visualized, QRS complex - 0.09 sec, alteration of R waves. What kind of rhythm disorder

appeared in a patient?

- A. Paroxysm of ventricular tachycardia.
- B. Paroxysm ventricular fibrillation.
- C. Paroxysm of atrial fibrillation.
- D. Paroxysm of SVT.
- E. Paroxysm of sinus tachycardia.

9. 67-year-old patient complains of heart pain, palpitations, shortness of breath at rest. General condition is serious. Acrocyanosis, arrhythmic heart tones, muted. Heart rate - 120 / min., BP - 120/80 mmHg. Liver + 2cm, lower leg edema. ECG - non sinus rhythm, irregular , heart rate - 160 per min ., multiple f-waves. Plasma potassium - 4.8 mmol/L. Which drug should be used in the first place?

- A. Digoxin.
- B. Verapamil
- C. Novocain amide.
- D. Amiodarone.
- E. Potassium chloride.

10. A 35-year-old patient complains of sudden heartbeat, shortness of breath and a dull pain in the heart after physical exertion. History of 12 years suffering from rheumatism without heart failure. Objectively: BP: 110-130/85 mmHg, pulse - 96 / min., heart rate - 130 per minute. ECG: multiple small waves of different shapes instead of P-waves, RR intervals have different duration. What is the most likely diagnosis?

- A. Atrial flutter.
- B. Supraventricular paroxysmal tachycardia.
- C. Atrial fibrillation.
- D. Ventricular paroxysmal tachycardia.
- E. Respiratory arrhythmia.

Clinical Tasks:

Task No. 1.

Patient 60 years. old, complained of palpitations, shortness of breath, squeezing pain in the heart. A year ago, suffered a myocardial infarction. Acrocyanosis, tone heart muted. BP - 110/70 mmHg ECG: rhythm is regular, non-sinus, heart rate - 180 per minute., QRS complex is deformed, width - 0.14 s, with a discordant shift segment ST, negative T.

Questions:

1. What is the most likely diagnosis?
2. What is the algorithm of the management of this rhythm disorder?

Task No. 2.

The patient's 27 years with physical activity was admitted to the hospital with palpitation, pain in the heart. During the 4 years he has been suffering from rheumatism, with mitral heart disease without circulatory disturbances. The ECG heart rate is -180 /min. P is negative, complex QRS - 0.08 s, positive T waves, low amplitude, RR intervals are the same.

Questions:

1. What is the most likely diagnosis?
2. What is the algorithm of the management of this rhythm disorder?

Task No. 3.

In patient 65, which is located on ECG monitoring, suddenly appeared on the monitor, small waves instead of teeth R, which is practically impossible to count. Was diagnosed with clinical death.

Questions:

1. What is the most likely complication in this patient ?
2. What therapeutic measures need to be held in the first place?

Summary:

Recommended reading list

Basic literature:

- Harrison's Principles of Internal Medicine Self-Assessment and Board Review, 20th Edition 20th Edition.- (August 13, 2021). - 736 pages
- Pocket Medicine: The Massachusetts General Hospital Handbook of Internal Medicine / 007 edition (12 Sept. 2019). - 272 pages
- Davidson's Principles and Practice of Medicine: Enhanced Digital Version Included / Elsevier; 23rd edition (25 April 2018). - 1440 pages

Additional literature:

- Macleod's Clinical Examination /Elsevier; 14th edition (11 Jun. 2018). - 400 pages
- Current Medical Diagnosis and Treatment /McGraw-Hill Education; Updated edition (14 Sept. 2021). - 1840 pages
- Lippincott Connect Standalone Courseware for Bates' Guide to Physical Examination and History Taking 1.0 /LWW; 13th ed. edition (23 Mar. 2023).
- Step-Up to Medicine / Wolters Kluwer Health; 5th edition (8 May 2019). - 582 pages
- Goldman-Cecil Medicine, 2-Volume Set (Cecil Textbook of Medicine) / Elsevier; 26th edition (20 Dec. 2019). - 2944 pages
- The Washington Manual of Medical Therapeutics / Wolters Kluwer Health; 36th edition (6 Jun. 2019). - 1074 pages
- Harrison's Manual of Medicine / McGraw-Hill Education; 20th edition (5 Nov. 2019). - 1245 pages

Electronic information resources

- World Health Organization. URL: www.who.int/ru/index.html.
- European Regional Office of the World Health Organization. URL: www.euro.who.int.
- <https://www.aasld.org/>
- https://academic.oup.com/ndt/pages/General_Instruction
- <https://cprguidelines.eu/>
- <https://www.escardio.org/Guidelines/Clinical-Practice-Guidelines>
- <http://www.oxfordmedicaleducation.com/>
- <http://ard.bmj.com>
- <https://www.escardio.org/Guidelines/Clinical-Practice-Guidelines>

Practical class

Topic 34. Management of a patient with severe community-acquired and hospital-acquired pneumonia. Management of a patient with total pleural effusion and pneumothorax.

The main goals:to acquire communication skills and skills of clinical examination of a patient with severe non- hospital and hospital pneumonia, total pleural effusion and pneumothorax; to be able to establish a preliminary diagnosis, carry out a differential diagnosis and determine the clinical diagnosis of the disease in a patient with severe non-hospital and hospital pneumonia, total pleural effusion and pneumothorax; master the principles of treatment, recommendations for lifestyle changes in the management of patients with severe community-acquired and hospital-acquired pneumonia, total pleural effusion and pneumothorax; learn to diagnose emergency conditions in patients with severe non- hospital and hospital pneumonia, total pleural effusion and pneumothorax and master the tactics of providing emergency medical care; to be able to perform therapeutic manipulations in patients with severe non-hospital and hospital pneumonia, total pleural effusion and pneumothorax .

Key words:etiologyand pathogenesis of pneumonia; modern classification of pneumonia; clinical features of various types of pneumonia and possible complications; pneumonia severity criteria and indications for hospitalization; general principles and features of treatment of various variants of pneumonia and possible complications; medical and social examination of pneumonia and its complications; clinical pharmacology of antibiotics; examination of a patient with pneumonia and assessment of the degree of severity and category of this nosology; patient examination plan and evaluation of the results of additional research methods; differential diagnosis of pulmonary infiltrate; substantiation and formulation of clinical diagnosis; prescription of individual treatment for the

patient, selection of the most effective antibiotic or combination depending on the causative agent, category and severity of pneumonia; emergency care for spontaneous pneumothorax, pulmonary edema, pulmonary hemorrhage, acute respiratory failure, infectious-toxic shock.

Equipment: multimedia materials - a set of thematic slides from the department's multimedia library; screenshots of laboratory test results (general blood test, general urine test, second blood test) ; screenshots of instrumental research results (ECG, RG of chest organs, echocardiography, CT scan) ; a set of situational problems on the subject of the lesson.

Plan:

1. Organizational measures (greetings, verification of those present, announcement of the topic, purpose of the lesson, motivation of higher education seekers to study the topic).
2. Control of the reference level of knowledge (checking homework, written work, written testing, including writing KROK-2 tests, frontal survey).
3. Formation of professional skills and abilities (acquisition of skills, curation, determination of a treatment regimen, laboratory research, etc.): discussing the features of diagnosis and treatment of patients with severe community-acquired and hospital-acquired pneumonia, total pleural effusion and pneumothorax, the most common clinical manifestations, diagnostic criteria
4. Summing up (summarizing the topic, evaluating applicants, discussing the next lesson topic and homework)

The control question :

1. Give a definition of the term "pneumonia".
2. What types of pneumonia do you know?
3. Which symptoms are "small" criteria for severe pneumonia?
4. What are the "big" criteria for severe pneumonia?
5. What are the diagnostic criteria for the diagnosis of pneumonia.
6. What is the approach to patients with pneumonia ?
7. Which antibiotic is selected in patients with group IV pneumonia?
8. What types of nosocomial pneumonia do you know?
9. List the diagnostic criteria for nosocomial pneumonia.
10. What are the principles of antibacterial therapy of patients with nosocomial pneumonia?

Tests:

1. The patient S., aged 40, suddenly developed shortness of breath, sharp right chest pain and a dry cough after physical exertion. Objectively : cyanosis, BP 95/60 mm Hg. Pulse rate 115 / min., breathing is frequent, extension of intercostal spaces of the right chest side, percussion sound is hyper resonant . The shift of heart borders to the left. Your diagnosis?
A. Spontaneous pneumothorax.
B. Stroke.
C. Pulmonary embolism.
D. Myocardial infarction.
E. Cardiac asthma.
2. A 52 yo male patient has become ill gradually. There is pain in the left side of the thorax during 2 weeks, elevation of temperature till 38-39oC. On examination: left chest side falls behind in breathing movement no voice tremor over the left lung. Dullness that is more intensive in the lower parts of this lung. Right heart border is deviated outside. Sharply weakened breathing over the left lung, no rales. Heart sounds are muffled, tachycardia. What is the most likely diagnosis?
A. Spontaneous pneumothorax
B. Exudative pleuritis
C. Atelectasis of lung
D. Cirrhotic tuberculosis
E. Infarction-pneumonia
3. Patient M., age d 78, long suffering from diabetes type II. Hospitalized with complaints of fever up

to 38 ° C, chills, cough with a large amount of mucous and purulent sputum mixed with blood, shortness of breath. Acutely ill a week ago, was diagnosed with left lower lobe pneumonia. Treatment of ampicillin yielded some positive effect. However, on the 7th day of illness sharp deterioration appeared: hectic fever, chills, progressive dyspnea, a significant increase in the number of sputum. What is the most likely cause of such deterioration?

- A. Development of the inflammatory infiltrate in the left lung.
- B. The formation of lung abscess.
- C. Development of chronic pulmonary heart.
- D. Pneumothorax.
- E. Thromboembolism of small branches of the pulmonary artery.

4. Patient M., age d 78, long suffering from diabetes type II. Hospitalized with complaints of fever up to 38 ° C, chills, cough with a large amount of mucous and purulent sputum mixed with blood, shortness of breath. Acutely ill a week ago, was diagnosed with left lower lobe pneumonia. Treatment of ampicillin yielded some positive effect. However, on the 7th day of illness sharp deterioration appeared: hectic fever, chills, progressive dyspnea, a significant increase in the number of sputum. Determine subsequent antibacterial therapy in this patient:

- A. Increase the dose of ampicillin.
- B. Assign the third-generation cephalosporin intravenously in combination with aminoglycosides.
- C. Assign aminoglycosides intramuscularly.
- D. Assign penicillin intravenously in large doses.
- E. Assign oral fluoroquinolones.

5. Microbiological examination of the sputum in a patient found *Klebsiella pneumoniae*. Choose the optimal antibiotic therapy:

- A. Second-generation cephalosporins
- B. Semisynthetic penicillin in large doses
- C. Cephalosporins of the second or third generation in combination with aminoglycosides.
- D. Fluoroquinolones.
- E. Macrolides.

6. Patients 35 years old, complains of sudden severe pain in the right chest , dry cough , shortness of breath, tachycardia that appeared after lifting a large load . Objective: skin is cyanotic, increased intercostal spaces, reduced respiratory excursions of the right lung. Percussion - tympanitis above the right side of the chest, auscultation - breath sounds of diminished intensity . Heart borders shifted to the left. Pulse 120 / minute, BP - 90/60 mmHg . The most likely preliminary diagnosis:

- A. Myocardial infarction complicated by acute heart failure.
- B. Pleural effusion.
- C. Lobar pneumonia.
- D. Spontaneous pneumothorax.
- E. Pulmonary embolism.

7. A 56-year-old drowned man was rescued from the water and delivered to the shore. Objectively: the man is unconscious, pale, breathing cannot be auscultated, pulse is thready. Resuscitation measures allowed to save the patient. What complications may develop in the near future?

- A. Encephalopathy
- B. Respiratory arrest
- C. Pulmonary edema
- D. Cardiac arrest
- E. Bronchospasm

8. A 30-year-old male patient complains of dyspnea, heaviness and chest pain on the right, body temperature rises up to 37.2°C. The disease is associated with a chest trauma received 4 days ago. Objectively: skin is pale and moist. Ps - 90 bpm, regular. Palpation reveals a dull sound on the right, auscultation reveals significantly weakened vesicular breathing. In blood: RBCs - $2.9 \cdot 10^{12}/l$, color index - 0.9, Hb - 104 g/l, WBCs - $8.0 \cdot 10^9/L$, ESR - 18 mm/h. What results of diagnostic puncture of the pleural cavity can be expected?

- A. Exudate
- B. Chylous liquid

C. Haemorrhagic punctate

D. Transudate

E. Purulent punctate

9. Patient G. , 54 years old , 4 days before hospitalization was diagnosed with pleuropneumonia with antibiotic resistance . Objectively : RR- 44 / minutes., Body temperature 40.2 ° C, BP - 60/20 mmHg, heart rate 120 per min, heart sounds relaxed, oliguria. PaO₂ - 10.1 kPa, PaCO₂ - 6.2 kPa. After the infusion therapy, the patient's condition had not improved significantly. What determines the severity of patient status?

A. The development of infectious-toxic shock.

B. Acute respiratory failure.

C. Progressive heart failure.

D. Hyperthermia.

E. Renal failure.

10. Patient D., aged 26, during the hard physical work he suddenly felt a sharp pain in the chest, began to choke. Objectively : lip cyanosis, RR- 40 per min. Right chest is increased in volume, is not involved in the act of breathing, right percussion - hyperresonant sound. Your diagnosis?

A. Myocardial infarction.

B. Asthmatic condition.

C. Spontaneous pneumothorax.

D. Pulmonary embolism.

E. Fracture of the ribs on the right with the injury of the pleura.

Clinical Tasks :

Task No. 1.

Patient A., aged 36, went to a doctor complaining of cough with rusty sputum, chest pain during breathing and coughing, shortness of breath, increased body temperature to 40 ° C, pronounced weakness. Sick 2 days ago after hypothermia. His condition was serious, pale skin, covered with cold, sticky sweat, the temperature of 39.8 ° C. On auscultation in the right subscapular area auscultated pleural rub, bronchial breathing, with percussion there is dullness, voice shaking intensified. The RR - 35 per minute, Pulse rate- 120 per minute, BP - 90/60 mm Hg. Abdomen - soft, painless, the liver was not enlarged, there is no swelling. Tests: hemoglobin 140 g / l, WBC 16 x10⁹ / l, N -22%, E - 0-16% LF; m -6%, ESR - 48 mm / h. Urine : protein 0.65 g / l, WBC 2.0 v/f .

Questions:

1. Formulate and justify the diagnosis.

2. Make a plan for the survey.

3. Assign treatment.

Task No. 2 .

Patient S., aged 42, went to a doctor complaining of a cough with purulent sputum, fever to 38 ° C, weakness, One week ago, he had runny nose, dry cough, fever up to 37.5 C, but not treated. The deterioration occurred 2 days ago, when the temperature rose to 40 ° C, cough increased, and appeared greenish sputum. On auscultation in the subscapular and axillary areas left dry and small bubbling rales, RR - 32 / min. Blood test : white blood cells 9.8 x 10⁹ / l, ESR - 29 mm / h.

Questions:

1. Formulate a diagnosis.

2. Make a plan for the survey.

3. Assign treatment.

Task No. 3 .

Patient 54 years old, after lifting a heavy metal rod , felt a pain in the left chest and shortness of breath. Smokes for 15 years and frequent morning cough. OBJECTIVE: pale, moist skin. RR - 36 / min. Percussion left tympanic sound, breathing decreased , moist rales. Pulse - 100 / min., Inspiratory filling decreases. BP -100/70 mmHg. Heart sounds relaxed. Liver not palpable. On his feet a small varicose veins legs.

Questions:

1. Formulate the most likely preliminary diagnosis.
2. An algorithm for emergency care in this case?

Summary:**Recommended reading list****Basic literature:**

- Harrison's Principles of Internal Medicine Self-Assessment and Board Review, 20th Edition 20th Edition.- (August 13, 2021). - 736 pages
- Pocket Medicine: The Massachusetts General Hospital Handbook of Internal Medicine / 007 edition (12 Sept. 2019). - 272 pages
- Davidson's Principles and Practice of Medicine: Enhanced Digital Version Included / Elsevier; 23rd edition (25 April 2018). - 1440 pages

Additional literature:

- Macleod's Clinical Examination /Elsevier; 14th edition (11 Jun. 2018). - 400 pages
- Current Medical Diagnosis and Treatment /McGraw-Hill Education; Updated edition (14 Sept. 2021). - 1840 pages
- Lippincott Connect Standalone Courseware for Bates' Guide to Physical Examination and History Taking 1.0 /LWW; 13th ed. edition (23 Mar. 2023).
- Step-Up to Medicine / Wolters Kluwer Health; 5th edition (8 May 2019). - 582 pages
- Goldman-Cecil Medicine, 2-Volume Set (Cecil Textbook of Medicine) / Elsevier; 26th edition (20 Dec. 2019). - 2944 pages
- The Washington Manual of Medical Therapeutics / Wolters Kluwer Health; 36th edition (6 Jun. 2019). - 1074 pages
- Harrison's Manual of Medicine / McGraw-Hill Education; 20th edition (5 Nov. 2019). - 1245 pages

Electronic information resources

- World Health Organization. URL: www.who.int/ru/index.html.
- European Regional Office of the World Health Organization. URL: www.euro.who.int.
- <https://www.aasld.org/>
- https://academic.oup.com/ndt/pages/General_Instruction
- <https://cprguidelines.eu/>
- <https://www.escardio.org/Guidelines/Clinical-Practice-Guidelines>
- <http://www.oxfordmedicaleducation.com/>
- <http://ard.bmj.com>
- <https://www.escardio.org/Guidelines/Clinical-Practice-Guidelines>

Practical class

Topic 35. Management of a patient with asthmatic status.

The main goals: to acquire communication skills and clinical examination skills of a patient with asthmatic status; be able to establish a preliminary diagnosis, carry out a differential diagnosis and determine the clinical diagnosis of the disease in a patient with asthmatic status ; master the principles of treatment, recommendations for lifestyle changes in the management of patients with asthmatic status ; learn how to diagnose emergency conditions in patients with asthmatic status and master the tactics of providing emergency medical aid; to be able to perform therapeutic manipulations in patients with asthmatic status.

Key words: definition of the concept and reasons for the development of asthmatic status; mechanisms of the formation of bronchial obstruction and methods of its detection; clinical manifestations of asthmatic status; stages of asthmatic status and their clinical manifestations; modern approaches to the diagnosis of asthmatic status; clinical pharmacology of broncholytic and anti-inflammatory drugs; principles of providing emergency care for asthmatic status; differential diagnosis of asthmatic status with other conditions accompanied by broncho-obstructive syndrome.

Equipment:multimedia materials - a set of thematic slides from the department's multimedia library; screenshots of laboratory test results (general blood test, general urine test, second blood test) ; screenshots of instrumental research results (ECG, RG of chest organs, echocardiography, CT scan) ; a set of situational problems on the subject of the lesson.

Plan:

1. Organizational measures (greetings, verification of those present, announcement of the topic, purpose of the lesson, motivation of higher education seekers to study the topic)
2. Control of the reference level of knowledge (checking homework, written work, written testing, including writing KROK-2 tests, frontal survey)
3. Formation of professional abilities and skills (mastery of skills, curation, determination of the treatment scheme, laboratory research, etc.): discussing the features of diagnosis and treatment of patients with asthmatic status, the most common clinical manifestations, criteria for establishing a diagnosis
4. Summing up (summarizing the topic, evaluating applicants, discussing the next lesson topic and homework)

Control questions:

1. Explain the term “status asthmaticus?”
2. How would you classify status asthmaticus?
3. Name symptoms associated with I stage status asthmaticus?
4. Name symptoms associated with II stage status asthmaticus?
5. Name symptoms associated with III stage status asthmaticus
6. What are the symptoms of sympathomimetics toxicity?
7. Principles of treatment of asthmatic status.
8. How to treat asthma status at stage I?
9. Mention important laboratory findings commonly associated with status asthmaticus.
10. What is the first precursor, indicating the improvement of bronchial obstruction in asthmatic status?
11. What is the risk factor for developing severe status asthmaticus?
12. What are the most important clinical signs that indicate the effectiveness of the therapy of asthmatic status.

Tests:

- The patient, aged 37, with a childhood history of asthma, admitted to the intensive care unit. Overall condition is very serious. Sopor. Diffuse cyanosis, cold sweat. Cheyne-Stokes respiration. Auscultation decreased breath sounds in all lung areas, PO₂ - 45 mm Hg (normal: 80-100 mm Hg), PCO₂ - 85 mm Hg (normal: 35-45 mm Hg), BP - 90/60 mm Hg Which method required to eliminate hypoxia?
- A. Inhalation of oxygen-air mixture.
 - B. Introduction of sodium bicarbonate.
 - C. Inhalation of helium-oxygen mixture.
 - D. Hyperbaric oxygenation.
 - E. The introduction of prednisolone.
2. Patients who suffer from asthma for a long time, develop an attack of dyspnea, which lasts for days. Injection of euphilline has not brought relief, after inhalation of salbutamol condition worsened. Objectively: swelling of the neck veins, diffuse cyanosis, dry rales. Heart rate - 100/ min., BP - 130/90 mmHg, heart sounds decreased, accentuation II sound above pulmonic artery. Which drug should be appointed in the first place?
- A. Inhaled ipratropium
 - B. Inhaled cromolyn
 - C. Hydrocortisone oral or IV
 - D. Inhaled beclomethasone

E. 4% solution of sodium bicarbonate

3. The patient 38 years old, taken to the hospital in serious condition. Objectively: expressed shortness of breath, shallow breathing, gasping for air, swollen neck veins, diffuse cyanosis. Over the greater part of the lungs, breathing noises are absent. Pulse 138 per minute, BP-85/60 mmHg, arrhythmic heart sounds, gallop rhythm. Blood gases: PaO₂ - 54 mmHg (normal: 80-100 mm Hg), PaCO₂ - 51 mm Hg (normal: 35-45 mm Hg), pH=7.2 (normal: 7.35-7.45). Emergency therapy?

A. Ganglion blocking agents i/m.

B. Cardiac glycosides i/v.

C. Nitrates sublingually.

D. Diuretics i/v.

E. Glucocorticoids i/v.

4. Patient 37 years complained of attacks of dyspnea, lack of sputum discharge, feeling of "music" in the chest. Objectively: breathing is difficult, shallow, chest excursion is limited, extended exhalation, wheezing is heard at a distance. RR - 14/min. Percussion of the lungs - boxed sound; auscultation - weakened vesicular breathing, dry rales. Heart sounds are muffled, rhythmic, tachycardia. HR - 100 min. The most appropriate drug to rapidly reverse bronchoconstriction?

A. Theophylline.

B. Strophanthin.

C. Prednisone.

D. Diphenhydramine.

E. Adrenaline.

5. A 42-year-old woman suffers from bronchial asthma, has an acute attack of bronchial asthma. What medication from the list below is contraindicated to administer as a first aid?

A. Euphylinum

B. Izadrin

C. Corazolium

D. Morphine hydrochloride

E. Strophanthin hydrochloride

6. A 50-year-old patient complains of shortness of breath and cough during the last days. Sick for 10 years, has always noted a positive effect of inhaled sympathomimetics. This time, after inhalation of salbutamol and intravenous euphylline relief was not observed. His condition is serious. The neck veins are swollen, diffuse cyanosis, dry rales audible at a distance. Auscultation reveals silent zones above the lungs. Which of the following is the most likely diagnosis?

A. Attack of asthma.

B. Asthmatic status, I stage.

C. Asthmatic status, II stage.

D. Asthmatic status, III stage.

E. Prolonged attack of asthma.

7. A 31-year-old patient complains of shortness of breath, choking, dry cough, no sputum discharge. Sick for more than 3 years. Objectively: sitting, fixing the shoulder girdle, remote wheezing. Thorax is barrel-shaped, percussion - boxed sound, hard breathing with long breaths, large number of dry rales. Blood tests: eosinophilia. Your diagnosis?

A. Asthmatic status.

B. Bronchial asthma.

C. Cardiac asthma.

D. Chronic obstructive pulmonary disease.

E. Obturation of the bronchial foreign body.

8. Patient 49 years old, complains of dyspnea, cough. Sputum is not expectorated. Repeatedly applied salbutamol, cromoglycate, but without effect. Objective: sitting, leaning on the table, acrocyanosis. No peripheral edema. Breathing shallow, at some areas is not auscultated; scattered dry rales, significantly lengthened exhalation. Heart sound suppressed, tachycardia. Pulse - 112/min., BP - 110/70 mmHg. Liver at the costal arch. What preliminary diagnosis?

A. Asthmatic status.

B. Bronchial asthma.

C. Aspiration of foreign bodies.

D. Cardiac asthma.

E. Chronic obstructive bronchitis.

9. A 49-year-old patient complains of dyspnea, cough. There are no sputum discharges. He has repeatedly used salbutamol and intal but with no effect. Objectively: he is only able to sit while leaning on the table. Cyanosis of the face, acrocyanosis are present. Breathing is shallow, labored, in some parts it cannot be auscultated; there are diffuse rales, expiration is significantly prolonged. Heart sounds are muffled, tachycardia is present. Ps - 112/min, AP - 110/70 mm Hg. Liver is located near the costal arch. There are no peripheral edema. What is your provisional diagnosis?

A. Status asthmaticus

B. Chronic obstructive bronchitis

C. Bronchial asthma, moderate severity

D. Foreign object aspiration

E. Cardiac asthma

10. Patient with severe bronchial asthma attack that lasts more than 1 hour, Treatment with inhaled salmeterol, ipratropium bromide and IV euphyllin gives no effect. Which drugs should be administered as an emergency treatment?

A. Beta agonist intravenously.

B. Nonsteroidal anti-inflammatory drugs.

C. Antihistamines.

D. Inhaled corticosteroids.

E. Intravenous corticosteroids.

Clinical tasks

Task No. 1.

The patient, 55 years old, is in the intensive care unit with a severe attack of breathlessness. The general condition is worse, pronounced cyanosis, swelling of the neck veins. On auscultation breath is uneven, the heart is hollow tone, heart rate - 112 per minute. BP - 170/110 mm Hg, RR - 30 per min., PaCO₂ - 60 mm Hg., RA₂ - 65 mm Hg.

Questions

1. What is the most likely diagnosis?
2. What kind of emergency assistance should be provided?
3. What is the indicator showing the relief of bronchospasm in this case?

Task No. 2.

The patient, who suffered from asthma for more than 20 years, with shortness of breath suddenly had a persistent cough without sputum, chest pain, and choking. On auscultation, breath decreased, a large number of different-sized wheezing. Treatment with salmeterol without effect.

Questions

1. What complications developed in a patient?
2. What kind of emergency assistance should be provided?

Task No. 3 .

The patient 65 years old, who is in intensive care pulmonary department at the asthmatic condition, a steady oxygenation through the face mask. However, after 4.5 minutes the patient has come "oxygen apnea.

1. The best approach to the patient in this condition?
2. What kind of emergency assistance should be provided?

Summary:

Recommended reading list

Basic literature:

- Harrison's Principles of Internal Medicine Self-Assessment and Board Review, 20th Edition 20th Edition.- (August 13, 2021). - 736 pages

- Pocket Medicine: The Massachusetts General Hospital Handbook of Internal Medicine / 007 edition (12 Sept. 2019). - 272 pages
- Davidson's Principles and Practice of Medicine: Enhanced Digital Version Included / Elsevier; 23rd edition (25 April 2018). - 1440 pages

Additional literature:

- Macleod's Clinical Examination /Elsevier; 14th edition (11 Jun. 2018). - 400 pages
- Current Medical Diagnosis and Treatment /McGraw-Hill Education; Updated edition (14 Sept. 2021). - 1840 pages
- Lippincott Connect Standalone Courseware for Bates' Guide to Physical Examination and History Taking 1.0 /LWW; 13th ed. edition (23 Mar. 2023).
- Step-Up to Medicine / Wolters Kluwer Health; 5th edition (8 May 2019). - 582 pages
- Goldman-Cecil Medicine, 2-Volume Set (Cecil Textbook of Medicine) / Elsevier; 26th edition (20 Dec. 2019). - 2944 pages
- The Washington Manual of Medical Therapeutics / Wolters Kluwer Health; 36th edition (6 Jun. 2019). - 1074 pages
- Harrison's Manual of Medicine / McGraw-Hill Education; 20th edition (5 Nov. 2019). - 1245 pages

Electronic information resources

- World Health Organization. URL: www.who.int/ru/index.html.
- European Regional Office of the World Health Organization. URL: www.euro.who.int.
- <https://www.aasld.org/>
- https://academic.oup.com/ndt/pages/General_Instruction
- <https://cprguidelines.eu/>
- <https://www.escardio.org/Guidelines/Clinical-Practice-Guidelines>
- <http://www.oxfordmedicaleducation.com/>
- <http://ard.bmj.com>
- <https://www.escardio.org/Guidelines/Clinical-Practice-Guidelines>

Practical class

Topic 36. Management of a patient with anaphylactic shock and Quincke's edema.

The main goals: to acquire communication skills and clinical examination skills of a patient with anaphylactic shock and Quincke's edema ; to be able to establish a preliminary diagnosis, carry out a differential diagnosis and determine the clinical diagnosis of the disease in a patient with anaphylactic shock and Quincke's edema ; master the principles of treatment, recommendations for lifestyle changes in the management of patients with anaphylactic shock and Quincke's edema ; learn to diagnose emergency conditions in patients with anaphylactic shock and Quincke's edema and master the tactics of providing emergency medical aid; to be able to perform therapeutic manipulations in patients with anaphylactic shock and Quincke's edema .

Key words: basic etiological factors anaphylactic shock and Quincke's edema; mechanisms of formation of allergic reactions; clinical manifestations of anaphylactic shock and Quincke's edema; modern approaches to the diagnosis of anaphylactic shock and Quincke's edema; principles of providing emergency care for anaphylactic shock and Quincke's edema; differential diagnosis of anaphylactic shock and Quincke's edema with other conditions accompanied by broncho-obstructive syndrome.

Equipment: multimedia materials - a set of thematic slides from the department's multimedia library; screenshots of laboratory test results (general blood test, general urine test, second blood test) ; screenshots of instrumental research results (ECG, RG of chest organs, echocardiography, CT scan) ; a set of situational problems on the subject of the lesson.

Plan:

1. Organizational measures (greetings, verification of those present, announcement of the topic,

- purpose of the lesson, motivation of higher education seekers to study the topic)
2. Control of the reference level of knowledge (checking homework, written work, written testing, including writing KROK-2 tests, frontal survey)
 3. Formation of professional abilities and skills (mastery of skills, curation, determination of the treatment scheme, laboratory research, etc.): discussing the features of diagnosis and treatment of patients with asthmatic status, the most common clinical manifestations, criteria for establishing a diagnosis
 4. Summing up (summarizing the topic, evaluating applicants, discussing the next lesson topic and homework)

Quiz:

1. What are the main types of anaphylactic reactions?
2. List the major pathophysiological effects of stimulation of the H1-histamine receptors.
3. What are the medicines that most often cause anaphylactic shock, and why?
4. Write the main clinical signs:
 - a) the typical form of anaphylactic shock,
 - b) asthmatic option
 - c) hemodynamic form
 - d) abdominal form,
 - e) cerebral variant.
5. Give the definition of Quincke's edema (angioedema).
6. What are the main therapeutic measures emergency medical care with anaphylactic shock (ASH).
7. Why adrenaline is the drug of choice for anaphylactic shock?
8. What properties of glucocorticosteroids determine the need for their use in anaphylactic shock?
9. Why some periods of anaphylactic shock are not shown in the use of antihistamines?
10. What is anaphylactoid shock and how does it differ from anaphylaxis?
11. What are the main therapeutic measures urgent medical care in Quincke edema (angioedema).

Tests:

1. A 44-year-old patient with acute pneumonia had cephazolin introduced intramuscularly. After injection, the patient's condition deteriorated sharply: shortness of breath appeared, the patient got covered with cold sweat and lost consciousness. Pulse 140 per minute, weak filling, BP - 80/40 mm Hg. What a complication arose in a patient?
 - A. Pulmonary embolism.
 - B. Medical anaphylactic shock.
 - C. Dizziness.
 - D. Infection - toxic shock.
 - E. Serum sickness.
2. Patients with acute pneumonia were treated with intramuscular injection of penicillin. After 30 minutes, cyanosis of the lips, face flushing, tachycardia, blood pressure reduction appeared. The doctor concluded that the patient developed anaphylactic shock. Which of the biologically active substances is related to the mechanism of development of anaphylactic shock in this case?
 - A. Epinephrine
 - B. Gastrin
 - C. Histamine
 - D. Renin
 - E. Insulin
3. Women have swollen eyelids, lips, neck, tongue mucosa, cough, shortness of breath, vomiting, which occurred after she ate an orange. Earlier eating oranges caused rash, itching. What pathogenetic mechanism leads to the development of edema?
 - A. Increasing the hydrostatic pressure of blood in the capillaries.
 - B. Violations of the lymph flow.
 - C. The increased permeability of capillaries.
 - D. Reducing oncotic blood pressure.

E. Increase oncotic pressure of tissue fluid.

4. A man dripped both eyes with eye drops containing penicillin. A few minutes later edema of the eyelids, lips, cheeks, cough appeared. Which of these states is this clinical picture most typical for?

A. Anaphylaxis.

B. Angioedema.

C. Collapse state.

D. Bronchial asthma.

E. Idiosyncrasy.

5. The patient complains of shortness of breath, burning and pain in the throat, voice hoarseness, which was relieved by drinking water. An hour ago, while eating watermelon, a wasp stung him. At present he has sharp tongue edema, tongue hardly fits in the mouth, the temperature is 37.3 ° C, tachycardia, blood pressure reduction. The patient needs immediate introduction of:

A. Calcium gluconate.

B. Suprastin.

C. Aminophylline.

D. Adrenaline.

E. Furosemide.

6. A 42-year-old patient during drip infusion of albumin developed itching and flushing of the skin, nausea, severe weakness, tachycardia, blood pressure decrease. What should be further doctor's tactics?

A. Intravenous injection of adrenaline.

B. Introduction of cardiac glycosides.

C. Peritoneal dialysis.

D. Introduction of antihistamines.

E. Stop the i/v infusion.

7. The patient aged 48, who took meloxicam for arthritis, after 3 hours developed increased body temperature, fever, headache, erythematous rash on the skin, which quickly turned into bubbles of irregular shape, followed by symptoms of acute cardiovascular failure. What complication arose in a patient?

A. Acute circulatory failure.

B. Urticaria.

C. Anaphylaxis.

D. Fever of unknown origin.

E. Nodular erythema.

8. Patient 42 years old, admitted to a hospital with complaints of fainting, weakness, shortness of breath. The deterioration began suddenly after being bitten by bees in the left arm. Objectively - in a serious condition, pale skin, heart rate - 110 per minute., BP 90/60 mmHg. What first aid is required during transportation to the hospital by relatives?

A. Apply the tourniquet above the bite, apply a warm heating pad.

B. Tourniquet below the bite, apply ice.

C. Intense massage of the bite area.

D. Tourniquet above the bite, apply ice.

E. Tourniquet below the bite, apply a heating pad.

9. Patient 18 years old complains of dyspnea, cough, itchy skin. Ill acutely, about an hour ago after receiving ibuprofen. From childhood - urticaria, bronchial asthma. Objectively: paraorbital swelling, redness and swelling of the face. Breath with wheezing. Pulse 96/ min., BP - 80/50 mm Hg. The drug of first aid will be?

A. Prednisone.

B. Aminophylline.

C. Epinephrine.

D. Loratadine.

E. Digoxin.

10. The patient after administration of tetanus vaccine in a few minutes developed severe weakness, dizziness, palpitations, shortness of breath. Later lost consciousness. Objectively: marked pallor of the

skin and mucous membranes, sweating, Pulse 110/ min., BP 60/40 mm Hg. The reason for the deterioration of the patient?

- A. Angioedema
- B. Asthmatic status.
- C. Pain shock.
- D. Hemorrhagic shock.
- E. Anaphylaxis.

Clinical tasks

Task No. 1.

Patient 43 years old, with intramuscular bicillin emerged severe headache, ringing in the ears, pain behind the breastbone, feeling hot, sweating. Objectively: state of the patient's plight, PS - 115/min, BP - 80/30 mm Hg

Questions:

1. What complications develop in patients?
2. Which drugs should be entered in the first place?

Task No. 2.

The patient vaccinated with influenza vaccine. Ten minutes after vaccination the patient's condition deteriorated: there was severe weakness, dizziness, palpitations, pressure in the chest, shortness of breath. Objectively: expressed pallor, sweating, heart rate 110 per minute., BP-80/50 mmHg.

Questions:

1. Is separation necessary for the patient if hospitalized?
2. What kind of emergency assistance should be provided at the pre-hospital stage?

Task No. 3.

Patient admitted to hospital with complaints of sharp pain, red urine, nausea, vomiting. To establish the diagnosis, the urologist ordered a contrast urography. During the diagnostic procedure the patient appeared short of breath, anxiety, tachycardia - 130 min., Blood pressure decreased from 125/70 mmHg. to 50 / 0 mm Hg, the skin became cyanotic shade.

Questions:

1. What caused the deterioration of the patient?
2. What kind of emergency assistance should be provided to the patient?

Summary:

Recommended reading list

Basic literature:

- Harrison's Principles of Internal Medicine Self-Assessment and Board Review, 20th Edition 20th Edition.- (August 13, 2021). - 736 pages
- Pocket Medicine: The Massachusetts General Hospital Handbook of Internal Medicine / 007 edition (12 Sept. 2019). - 272 pages
- Davidson's Principles and Practice of Medicine: Enhanced Digital Version Included / Elsevier; 23rd edition (25 April 2018). - 1440 pages

Additional literature:

- Macleod's Clinical Examination /Elsevier; 14th edition (11 Jun. 2018). - 400 pages
- Current Medical Diagnosis and Treatment /McGraw-Hill Education; Updated edition (14 Sept. 2021). - 1840 pages
- Lippincott Connect Standalone Courseware for Bates' Guide to Physical Examination and History Taking 1.0 /LWW; 13th ed. edition (23 Mar. 2023).
- Step-Up to Medicine / Wolters Kluwer Health; 5th edition (8 May 2019). - 582 pages
- Goldman-Cecil Medicine, 2-Volume Set (Cecil Textbook of Medicine) / Elsevier; 26th edition (20 Dec. 2019). - 2944 pages
- The Washington Manual of Medical Therapeutics / Wolters Kluwer Health; 36th edition (6 Jun. 2019). - 1074 pages
- Harrison's Manual of Medicine / McGraw-Hill Education; 20th edition (5 Nov. 2019). - 1245 pages

Electronic information resources

- World Health Organization. URL: www.who.int/ru/index.html.
- European Regional Office of the World Health Organization. URL: www.euro.who.int.
- <https://www.aasld.org/>
- https://academic.oup.com/ndt/pages/General_Instruction
- <https://cprguidelines.eu/>
- <https://www.escardio.org/Guidelines/Clinical-Practice-Guidelines>
- <http://www.oxfordmedicaleducation.com/>
- <http://ard.bmj.com>
- <https://www.escardio.org/Guidelines/Clinical-Practice-Guidelines>

Practical class

Topic 37. Management of a patient with acute liver failure.

The main goals: to acquire communication skills and skills of clinical examination of a patient with acute liver failure ; to be able to establish a preliminary diagnosis, carry out a differential diagnosis and determine the clinical diagnosis of the disease in a patient with acute liver failure ; master the principles of treatment, recommendations for lifestyle changes in the management of patients with acute liver failure ; learn to diagnose emergency conditions in patients with acute liver failure and master the tactics of providing emergency medical care; to be able to perform therapeutic manipulations in patients with acute liver failure.

Key words: reasons for the development of hepatic encephalopathy from minimal manifestations to hepatic coma; pathogenetic options; clinical features of the course of those diseases that lead to the occurrence of such a complication; diagnostic methods (endoscopy, ultrasound, liver tests, viral markers and others); existing standards of treatment, efferent methods of treatment; primary and secondary prevention; prognosis and performance.

Equipment:multimedia materials - a set of thematic slides from the department's multimedia library; screenshots of laboratory test results (general blood analysis (platelet content, bleeding duration), general urinalysis (bile pigment content, diastase), coprogram, coagulogram, biochemical blood analysis (ALT, AST, total bilirubin and its fractions, total protein content and its fractions, creatinine, urea, a- amylase), blood test for HbSAg, HbCAg, PCR for TORCH infection); screenshots of the results of instrumental research (ECG; ultrasound of the abdominal organs through the cavity; liver biopsy; measurement of COS and lactate indicators; study of gastric lavage); a set of situational problems on the subject of the lesson.

Plan:

1. Organizational measures (greetings, verification of those present, announcement of the topic, purpose of the lesson, motivation of higher education seekers to study the topic)
2. Control of the reference level of knowledge (checking homework, written work, written testing, including writing KROK-2 tests, frontal survey)

3. Formation of professional abilities and skills (mastery of skills, curation, determination of the treatment regimen, laboratory research, etc.): discussing the specifics of diagnosis and treatment of patients with acute liver failure, the most common clinical manifestations, criteria for establishing a diagnosis
4. Summing up (summarizing the topic, evaluating applicants, discussing the next lesson topic and homework)

Control questions .

1. Define the syndrome of acute liver failure.
2. List the etiologic factors of acute hepatic failure.
3. What different types of liver disease exist ?
4. What are the clinical criteria for acute liver failure?
5. List the major neuro -psychiatric symptoms of liver failure.
6. What are the complications of acute liver failure?
7. What is the diagnostic program in patients with acute hepatic failure?
8. What first aid should be provided to patients at the prehospital stage?
9. List the basic principles of acute liver failure therapy.
10. What are the criteria for the effectiveness of acute liver failure treatment?

Tests

1. The patient , 24 years old , hospitalized in the gastroenterology department with a diagnosis of chronic viral hepatitis B with a high degree of activity. On the 5th^{day} of hospitalization the patient lapsed into a soporous state, jaundice increased and liver decreased in size, tremor of limbs . BP - 95/60 mm Hg, pulse -110 beats / min., rhythmical . What state has developed in a patient?
 - A. Subarachnoid hemorrhage.
 - B. Acute hepatic failure.
 - C. Hypoglycemic coma.
 - D. Collapse .
 - E. Uremia .
2. The patient , 24 years old , hospitalized in the gastroenterology department with a diagnosis of chronic viral hepatitis B with a high degree of activity. On the 5th^{day} of hospital stay the patient went into a soporous state , sharply increased jaundice and liver decreased in size, tremor of limbs. BP - 95/60 mm Hg, pulse - 110 beats / min. To confirm the diagnosis the following tests should be done :
 - A. Ultrasonography of the liver.
 - B. Computerized tomography of the head.
 - C. Determination of transaminases and indicators of nitrogen metabolism.
 - D. Electrocardiography.
 - E. Fibrogastroduodenoscopy.
3. athognomonic symptom of acute liver failure is:
 - A. Increased blood cholesterol level.
 - B. Reduction of blood glucose.
 - C. Increased AST, ALT.
 - D. Increasing K + and Na +.
 - E. Increased lymphocytes.
4. Patient 53 years old, is in soporific condition. Objectively : icteric skin , BP 90/60 mmHg, hepatic smell from the mouth, nystagmus, delirium, Kussmaul 's breathing, ascites. Liver + 7 cm, dense, painful, Hb 94 g/L, PLT $72 \cdot 10^9/L$, Blood glucose 10 mmol /L, Bilirubin 678 mmol /L, A s T 320 U/L, ALT 300 U/L , creatinine 140 mmol/liter. Liver ultrasound: - "chopped" with vascular net , parenchyma is diffusely changed. What is your diagnosis ?
 - A. Hepatocellular deficiency.
 - B. A nemesis coma.
 - C. Diabetic coma.
 - D. Renal function deficiency .

E. Hypotonic crisis.

5. Patient S., aged 58, the condition is extremely serious, disoriented in time and space, seizures, delirium and excitement with the next drowsiness, poor coordination of movements, "flapping" tremor of the fingers and toes, jaundice, hepatic odor from the mouth. In the blood: ESR 48 mm/h, $Er \cdot 2.8 \times 10^{12} /L$, total bilirubin 295 $\mu\text{mol/L}$, AST 240 U/L, ALT 300 U/L. What is your diagnosis?

A. Hepatic coma.

B. Uremic coma.

C. Myocardial infarction.

D. Ischemic stroke.

E. Pulmonary embolism.

6. Patient 56 years old, for 6 years has been suffering from liver cirrhosis, was admitted to the intensive care unit in soporo se condition. Objectively: jaundice, liver breath, nystagmus, Kussmaul's breathing. Liver + 7 cm, the edge is painful. Hb 80 g/L, $PLT 68 \times 10^9 /L$, Total bilirubin 420 $\mu\text{mol/L}$, creatinine 267 $\mu\text{mol/L}$, urea - 13 mg/dL. What complications have developed in a patient?

A. Thrombosis of the portal vein.

B. Acute renal failure.

C. Anemic crisis.

D. Hepatocellular coma.

E. Subhepatic jaundice.

7. Patient T., aged 52, drowsy, "liver" smell from the mouth, three times vomiting. Sick with stomach ulcer. 2 months ago, was treated for gastric bleeding with blood components. His condition is serious, intense jaundice, hemorrhages on the mucous membranes. The liver is determined below the costal arch. Pulse 110 per minute. BP - 90/60 mm Hg. Indicate the most likely diagnosis.

A. Dehydration shock.

B. Infection - toxic shock.

C. Acute renal failure.

D. Acute liver failure.

E. Acute respiratory failure.

8. In a 32-year-old patient with acute hepatitis, a physician noticed an emotional weakness, increase in the intensity of jaundice, "liver" smell from the mouth. The patient complains of headache, nausea, insomnia at night. Objectively: body temperature - 38.2 °C, pulse - 114 min., Hemorrhages on the skin of the trunk, limbs, post-injectional hematoma, reduced size of the liver. Leukocytes - $12 \times 10^9 /L$, protein thrombin index - 65%. What kind of complications can you think about?

A. DIC-syndrome.

B. Acute renal failure.

C. Acute liver failure.

D. Infection - toxic shock.

E. Meningoencephalitis.

9. The patient, aged 47, treated for a long time from alcoholic cirrhosis. After the alcohol intake the condition has quickly deteriorated: jaundice developed, nausea, vomiting, impaired consciousness. Ps - 62 min., BP 90/60 mmHg, rhythmic activity of the heart, abdomen is distended, liver + 2 cm. Total bilirubin - 180 $\mu\text{mol/L}$, ALT - 280/L, AST - 300/L. What infusion therapy should be used:

A. 5% glucose solution, ornitsil.

B. Sodium chloride (0.9%) solution, ornitsil.

C. Reopolyglukine.

D. Polyglukin.

E. The red blood cells.

10. Patient S., aged 53, was brought by an ambulance. Patient indifferent, talks slowly, confused consciousness. Smell of alcohol from the mouth. Skin and mucous membranes are icteric. Tachycardia. The liver is soft, stands 1 cm below the costal arch. In the blood - leukocytosis, increased transaminases, hyperbilirubinemia, reduced alkaline phosphatase, prothrombin. Blood glucose - 6.8 mmol/liter. What is the pathology of a patient?

A. Acute hepatic failure

B. Hyperglycemic coma

- C. Hypoglycemic coma
- D. Delirium tremens
- E. Renal failure

Clinical tasks

Task No. 1.

Patient 38 years old, was taken to the hospital unconscious. Anamnesis: working in a chemical shop. On the eve after work drank alcohol. After 6 hours appeared a headache, nausea, vomiting, liquid stool with a specific smell, epyleptic seizures. Objectively: dilated pupils, tendon reflexes are absent, skin jaundiced with multiple petechiae and hemorrhages. RR -26 in 1 min., Pulse 112 b. / m in., BP - 70/40 mm Hg. The liver appears from under the costal arch by 5 cm. In the blood sharply increased levels of bilirubin, increased ALT, AST.

Questions

1. What is the preliminary diagnosis?
2. What emergency care does the patient require?

Task No. 2.

In a 21-year-old boy, a patient with chronic hepatitis C had appeared the euphoria, disorientation, which were replaced by sleepiness, consciousness confusion. On the skin - hemorrhagic rash, nosebleed, from the mouth - sweet smell.

Questions

1. What is the most possible complication?
2. What emergency care does the patient require?

Task No. 3.

Patient 55 years old, was operated on for choledocholithiasis. After 3 days there appeared apathy, headache, anorexia, jaundice which have been growing progressively, and were accompanied by intense skin itching. There is hemorrhage into the sclera and conjunctiva, dyspnea, tachycardia, drowsiness, "hepatic" smell from the mouth.

Questions

1. What is the mechanism that causes this complication?
2. What therapeutic steps should be taken in this case?

Summary:

Recommended reading list

Basic literature:

- Harrison's Principles of Internal Medicine Self-Assessment and Board Review, 20th Edition 20th Edition.- (August 13, 2021). - 736 pages
- Pocket Medicine: The Massachusetts General Hospital Handbook of Internal Medicine / 007 edition (12 Sept. 2019). - 272 pages
- Davidson's Principles and Practice of Medicine: Enhanced Digital Version Included / Elsevier; 23rd edition (25 April 2018). - 1440 pages

Additional literature:

- Macleod's Clinical Examination /Elsevier; 14th edition (11 Jun. 2018). - 400 pages
- Current Medical Diagnosis and Treatment /McGraw-Hill Education; Updated edition (14 Sept. 2021). - 1840 pages
- Lippincott Connect Standalone Courseware for Bates' Guide to Physical Examination and History Taking 1.0 /LWW; 13th ed. edition (23 Mar. 2023).
- Step-Up to Medicine / Wolters Kluwer Health; 5th edition (8 May 2019). - 582 pages
- Goldman-Cecil Medicine, 2-Volume Set (Cecil Textbook of Medicine) / Elsevier; 26th edition (20 Dec. 2019). - 2944 pages
- The Washington Manual of Medical Therapeutics / Wolters Kluwer Health; 36th edition (6 Jun. 2019). - 1074 pages
- Harrison's Manual of Medicine / McGraw-Hill Education; 20th edition (5 Nov. 2019). - 1245 pages

Electronic information resources

- World Health Organization. URL: www.who.int/ru/index.html.
- European Regional Office of the World Health Organization. URL: www.euro.who.int.
- <https://www.aasld.org/>
- https://academic.oup.com/ndt/pages/General_Instruction
- <https://cprguidelines.eu/>
- <https://www.escardio.org/Guidelines/Clinical-Practice-Guidelines>
- <http://www.oxfordmedicaleducation.com/>
- <http://ard.bmj.com>
- <https://www.escardio.org/Guidelines/Clinical-Practice-Guidelines>

Practical class

Topic 38. Management of a patient with acute renal failure

The main goals: to acquire communication skills and clinical examination skills of a patient with acute kidney injury; be able to establish a preliminary diagnosis, carry out a differential diagnosis and determine the clinical diagnosis of the disease in a patient with acute kidney damage ; master the principles of treatment, recommendations for lifestyle changes in the management of patients with acute kidney damage ; learn to diagnose emergency conditions in patients with acute kidney damage and master the tactics of providing emergency medical aid; to be able to perform therapeutic manipulations in patients with acute kidney damage .

Key words: definition of the term acute kidney injury; main criteria of acute kidney injury; etiological factors leading to the occurrence of acute kidney damage; RIFLE criteria for acute kidney injury; basic diagnostic methods; treatment tactics; disease prognosis; primary and secondary prevention.

Equipment: multimedia materials - a set of thematic slides from the department's multimedia library; screenshots of laboratory test results (general blood analysis (platelet content, bleeding duration), general urinalysis (bile pigment content, diastase), coprogram, coagulogram, biochemical blood analysis (ALT, AST, total bilirubin and its fractions, total protein content and its fractions, creatinine, urea, a- amylase), blood test for HbSAg, HbCAg, PCR for TORCH infection); screenshots of the results of instrumental research (ECG; ultrasound of the abdominal organs through the cavity; liver biopsy; measurement of COS and lactate indicators; study of gastric lavage); a set of situational problems on the subject of the lesson.

Plan:

1. Organizational measures (greetings, verification of those present, announcement of the topic, purpose of the lesson, motivation of higher education seekers to study the topic)
2. Control of the reference level of knowledge (checking homework, written work, written testing, including writing KROK-2 tests, frontal survey)
3. Formation of professional abilities and skills (mastery of skills, curation, determination of the treatment regimen, laboratory research, etc.): discussing the specifics of diagnosis and treatment of

patients with acute liver failure, the most common clinical manifestations, criteria for establishing a diagnosis

4. Summing up (summarizing the topic, evaluating applicants, discussing the next lesson topic and homework)

Control questions:

1. Give the determination of ARF syndrome.
2. What are the basic etiological factors of ARF development?
3. What forms of ARF are different depending on causal factors?
4. Describe the clinical manifestations of ARF.
5. What is the difference between functional and organic forms of ARF?
6. What stages are selected in the clinical flow of ARF?
7. What complications can develop in patients with ARF?
8. List the changes of laboratory indexes due to ARF.
9. What examination plan must be conducted for patients with ARF?
10. Name the basic principles of ARF treatment.
11. What are the indications for conducting dialysis therapy?
12. What are the criteria of treatment efficiency?

Tests.

1. A 37-year-old patient was brought to the resuscitation unit. General condition of the patient is very serious. Sopor. The skin is gray, moist. Turgor is decreased. Pulse is rapid, intense. BP - 160/110 mm Hg, muscle tone is increased. Hyperreflexia. There is an ammonia odor in the air. What is the presumptive diagnosis?

- A. Uraemic coma
- B. Alcoholic coma
- C. Hyperglycemic coma
- D. Hypoglycemic coma
- E. Cerebral coma

2. In a woman 27 years old, who during two days was in an unconscious state after a road traffic accident, the excretion of urine has sharply decreased. What is the most possible cause of renal function disturbance?

- A. Absence of regulator influencing of cortex
- B. Acidosis development
- C. BP decrease
- D. Violation of water-salt exchange
- E. Intoxication with metabolic leftover products

3. The signs of kidney insufficiency have developed in a patient after traumatic shock. What pathogenetic mechanisms cause this pathological condition?

- A. The injury of renal glomerular apparatus.
- B. Decreasing volume of glomerular filtration.
- C. Blockage of urine outflow
- D. Oppressing of urine excretion in renal channels.
- E. Renal channels obstruction.

4. Patient aged 52, who suffers from urolithiasis, during the last days has sharp pain in the right lumbar area. The patient's condition has worsened: a general weakness, nausea, vomited, labored breath appeared. On admission to the hospital a diagnosis was set: Urolithiasis. Acute obstruction of the right ureter. ARF. What primary measures must be taken?

- A. Prescribe antibiotics.
- B. Surgical interference and stone deletion.
- C. Hemodialysis.
- D. Peritoneal dialysis.
- E. Lithotripsy.

5. In a few hours after bringing a patient with acute myocardial infarction out of cardiogenic shock,

- the patient's condition worsened again. On biochemical research: creatinine - 330 $\mu\text{mol/L}$, urea - 25 mmol/L, K^+ - 7.2 mmol/L. What is the indication for immediate dialysis initiation in this case?
- Grave general condition of patient
 - Cardiogenic shock in history
 - Creatinine: -330 $\mu\text{mol/L}$
 - Urea- 25 mmol/L
 - K^+ - 7.2 mmol/L
6. iuresis in a patient who suffers from ARF is 350 ml per day. How will you describe this index?
- Anuria.
 - Oliguria.
 - Polyuria.
 - An index is normal.
 - Pollakiuriya.
7. A patient with urolithiasis developed sharp pain in the left lumbar area during the last hours. The general state of the patient worsened, temperature rose, expressed general weakness, nausea appeared, the amount of urine decreased. What can be the sign of ARF development?
- Increased amounts of leucocytes in urinalysis.
 - Erythrocytes appearing in urinalysis.
 - Presence of protein in urinalysis.
 - Decreased daily diuresis to 500 ml.
 - Cylinders presence in urinalysis.
8. On the second day after skin contact with mercury compounds, the patient developed dermatitis, the temperature of the body rose. On the fifth day has developed a clinical picture of:
- Toxic hepatitis.
 - ARF .
 - Anaphylactic shock .
 - CRF.
 - Injury of reticular-endothelial system.
9. As a result of an accident, the patient was poisoned with mercury chloride. In 2 days daily diuresis is 620 ml. Headache, faintness, vomiting, cramps. On auscultation above lungs moist rales can be heard. What pathological process takes place in this case?
- Toxic hepatitis.
 - Acute renal failure.
 - Anaphylactic shock .
 - Ischemic stroke
 - Injury of reticular-endothelial system.
10. In a patient P., 62 years old, on the 4th day after a surgery concerning the resection of the stomach according to ^{Bilrot} -1, sharp weakness, somnolence, nausea, cramps, dull pain in the back, swelling of the abdomen, diminishing of diuresis to 200 ml/day appeared. In blood: Er. - $3.0 \cdot 10^{12}/\text{L}$, creatinine - 370 $\mu\text{mol/L}$, urea - 10.0 mmol/l. What post-surgical complication had developed in a patient?
- Acute renal failure.
 - Chronic kidney insufficiency.
 - Thrombosis of the portal vein.
 - Ischemic stroke.
 - Badda-Kiari's syndrome.

Clinical tasks

Task N1.

A patient is 48 years old, delivered to the admission room of the hospital. From anamnesis: the day before he ate mushrooms which he picked by himself. Grumbles about a general weakness, urges on vomiting, urine of brown color, a few of urine for days. Objectively: skin covers are pale. Pulse-100/min., BP of 90/50mm. Hg. Sharp kidney insufficiency was suspected.

Questions:

1. That is the reason for ARF development?
2. What laboratory research is the most informative for diagnosis verification?

Task N2.

Patient T., 35 years old, during hemotransfusion of 200 ml of erythrocytes mass began to complain of headache, pain in the small of the back, tingling. Complication of transfusion - hemotransfusion of other blood type was diagnosed.

Questions:

1. What leading clinical syndrome can result in the death of the patient during 2-7 days from the development of this complication?
2. What algorithm of the first aid in this case?

Task N3.

In a patient 20 years old, after criminal abortion the state of health has sharply worsened: there has developed oliguria 70 ml, BP 80/50 mm Hg, closeness of urine 1,008-1,010, Erythrocytes 20-30 in eyeshot, potassium of plasma - 7.2 mmol/l, creatinine - 0.6 mmol/l.

Questions:

1. What complication did develop in a patient?
2. What is an absolute indication for urgent hemodialysis?

Summary:

Recommended reading list

Basic literature:

- Harrison's Principles of Internal Medicine Self-Assessment and Board Review, 20th Edition 20th Edition.- (August 13, 2021). - 736 pages
- Pocket Medicine: The Massachusetts General Hospital Handbook of Internal Medicine / 007 edition (12 Sept. 2019). - 272 pages
- Davidson's Principles and Practice of Medicine: Enhanced Digital Version Included / Elsevier; 23rd edition (25 April 2018). - 1440 pages

Additional literature:

- Macleod's Clinical Examination /Elsevier; 14th edition (11 Jun. 2018). - 400 pages
- Current Medical Diagnosis and Treatment /McGraw-Hill Education; Updated edition (14 Sept. 2021). - 1840 pages
- Lippincott Connect Standalone Courseware for Bates' Guide to Physical Examination and History Taking 1.0 /LWW; 13th ed. edition (23 Mar. 2023).
- Step-Up to Medicine / Wolters Kluwer Health; 5th edition (8 May 2019). - 582 pages
- Goldman-Cecil Medicine, 2-Volume Set (Cecil Textbook of Medicine) / Elsevier; 26th edition (20 Dec. 2019). - 2944 pages
- The Washington Manual of Medical Therapeutics / Wolters Kluwer Health; 36th edition (6 Jun. 2019). - 1074 pages
- Harrison's Manual of Medicine / McGraw-Hill Education; 20th edition (5 Nov. 2019). - 1245 pages

Electronic information resources

- World Health Organization. URL: www.who.int/ru/index.html.
- European Regional Office of the World Health Organization. URL: www.euro.who.int.
- <https://www.aasld.org/>
- https://academic.oup.com/ndt/pages/General_Instruction
- <https://cprguidelines.eu/>
- <https://www.escardio.org/Guidelines/Clinical-Practice-Guidelines>
- <http://www.oxfordmedicaleducation.com/>
- <http://ard.bmj.com>
- <https://www.escardio.org/Guidelines/Clinical-Practice-Guidelines>

Practical class

Topic 39. Management of a patient with acute abdominal pain. Management of a patient with gastrointestinal bleeding.

The main goals: to acquire communication skills and skills of clinical examination of a patient with acute abdominal pain; be able to establish a preliminary diagnosis, carry out a differential diagnosis and determine the clinical diagnosis of the disease in a patient with acute abdominal pain ; master the principles of treatment, recommendations for lifestyle changes in the management of patients with acute abdominal pain ; learn to diagnose emergency conditions in patients with acute abdominal pain and master the tactics of providing emergency medical care; to be able to perform therapeutic manipulations in patients with acute abdominal pain .

Key words: causes of acute abdominal pain syndrome development ; pathogenetic options; clinical features of the course of those diseases that lead to the occurrence of such a complication; diagnostic methods (general blood test, liver tests, endoscopy, ultrasound, CT and others); existing treatment standards; primary and secondary prevention; prognosis and performance; causes of gastrointestinal bleeding; pathogenetic options; clinical features of the course of those diseases that lead to the occurrence of such a complication; diagnostic methods (general blood test, liver tests, endoscopy, ultrasound, CT and others); existing treatment standards.

Equipment: multimedia materials - a set of thematic slides from the department's multimedia library; screenshots of laboratory test results (general blood test, general urinalysis, coagulogram, co-program) ; screenshots of the results of instrumental research (ECG; ultrasound of the abdominal cavity, pelvis, thoracic cavity, endoscopic research methods) ; a set of situational problems on the subject of the lesson.

Plan:

1. Organizational measures (greetings, verification of those present, announcement of the topic, purpose of the lesson, motivation of higher education seekers to study the topic)
2. Control of the reference level of knowledge (checking homework, written work, written testing, including writing KROK-2 tests, face -to- face survey)
3. Formation of professional abilities and skills (mastery of skills, curation, determination of the treatment regimen, laboratory research, etc.): discussing the specifics of diagnosis and treatment of patients with acute abdominal pain, the most common clinical manifestations, criteria for establishing a diagnosis
4. Summing up (summarizing the topic, evaluating applicants, discussing the next lesson topic and homework)

Control questions

1. Give the definition of acute abdominal syndrome.
2. List main groups of causes that determine the development of acute pain in the stomach:
3. What aspects should you pay attention to during the questioning of a patient with acute abdominal pain?
4. What abdominal pain features do you know?
5. What information can be obtained on the physical examination of the patient?
6. Due to which diseases an acute abdominal pain in combination with blood pressure decrease (BP) is most frequently observed?
7. Give the definition to " acute " abdomen syndrome .
8. What diseases are characterized by the development of " acute " abdomen?
9. List the indications for urgent hospitalization.
10. What basic principles of treatment of patients with " acute " abdominal syndrome on prehospital stage?
11. What main groups of gastro - intestinal bleeding causes do you know?
12. What diseases are the most often to give rise to gastro-intestinal bleeding?
13. Characterize clinical manifestations of gastro-intestinal bleeding, depending on the level of their

occurrence.

14. What are the main clinical syndromes of posthemorrhagic anemia.
15. What are the severity stages of hemorrhagic shock do you know?
16. List the basic principles of gastro-intestinal bleeding diagnosis
17. What are the basic principles of gastrointestinal bleeding treatment?
18. Describe the main methods of stopping the bleeding.
19. What steps should be taken to restore hemodynamics and oxygen transport?
20. What is the treatment of refractory shock?

Tests

1. A young man , 18 years old, was delivered to the hospital Admission Room with complaints of pain attacks in the right half of the abdomen with irradiation in the scrotum , nausea, vomiting. Acutely got sick for the first time. On palpation : muscle strain in the right half of the abdomen. Shchetkin - Blumberg's symptom is questionable. Pasternatskiy's symptom is weakly positive from the right side, there is urinary retention. The temperature is 37.7 ° C, Leuk . = 8.0×10^9 /L. In the analysis of urine collected from the catheter, 10-15 fresh erythrocytes in the area of vision . Which of the following diagnoses is most likely?
 - A. Renal colic.
 - B. Acute appendicitis.
 - C. Acute cholecystitis.
 - D. Ileus.
 - E. Perforated duodenal ulcer.
2. Patient , aged 47, with IHD went to a doctor complaining about intense pain in the epigastric region for 2 hours, which occurred suddenly after physical exertion, not relieved by nitroglycerin and analgesics. On examination - the state of moderate severity, skin pale and covered with cold sweat. BP 90/60 mm Hg., Heart rate - 110 per minute. On auscultation - vesicular breathing , heart sounds arrhythmic , muffled. Abdomen is soft on palpation, symptoms of peritoneal irritation are absent. The ECG - sinus rhythm, left axis deviation, ST segment elevation in II, III, and AVF. Which of the following diagnoses is the most likely?
 - A. Stomach ulcer.
 - B. Diaphragmatic hernia.
 - C. Acute cholecystitis.
 - D. Acute coronary syndrome.
 - E. Spontaneous pneumothorax.
3. Male 39 years old, working as a stevedore, after a sharp lifting felt an intense pain in the left hypochondrium. Objective: diffuse cyanosis, increased intercostal spaces. On percussion - tympanitis from the left, on auscultation - prominent weakening of the respiratory noises. Borders of the heart are displaced to the right. Pulse 120 per minute, BP 90/60 mmHg . Palpation of the abdomen is soft and painless. The most reliable preliminary diagnosis is :
 - A. Perforated duodenal ulcer.
 - B. Diaphragmatic hernia.
 - C. Myocardial infarction.
 - D. Exudative pleurisy.
 - E. Spontaneous pneumothorax
4. Female 35 years old , after an injection of nonsteroidal anti-inflammatory drugs for radicular syndrome felt sharp pain in the epigastric region, nausea. Patient's condition quickly deteriorated: skin is pale, covered with cold sweat. BP 80/50 mmHg. HR 120 per minute. Abdomen is soft on palpation; symptoms of peritoneal irritation are absent. Which of the following diagnoses is most likely?
 - A. Cardiogenic shock.
 - B. Diaphragmatic hernia.
 - C. Anaphylactic shock, abdominal form.
 - D. Perforated duodenal ulcer.
 - E. Spontaneous pneumothorax.
5. A 45 yo woman complains of severe pain in the right abdominal side radiating in the right

supraclavicular area, fever, dryness and bitterness in the mouth. There were multiple vomitings without relief. The patient relates the onset of pain to the intake of fat and fried food. Physical examination: the patient lies on the right side, pale, dry tongue, tachycardia. The right side of the abdomen is painful during palpation and somewhat tense in the right hypochondrium. What is the most likely diagnosis?

- A. Acute cholecystitis
- B. Perforative ulcer
- C. Acute bowel obstruction
- D. Acute appendicitis
- E. Right-sided renal colic

6. Female 55 years old, overweight, felt a sharp pain in the right abdomen after the birthday party. Pain was accompanied by nausea, vomiting, feeling of bitterness in the mouth. On examination – general condition of moderate severity. BP = 140/90 mm Hg, HR 110 per minute. Heart sounds are muffled, rhythmic activity. Vesicular breathing. On palpation of the abdomen, the patient feels sharp pain in the right hypochondrium. Positive Ortner's, Courvoisier's symptoms. Your preliminary diagnosis:

- A. Acute pancreatitis.
- B. Biliary colic.
- C. Acute appendicitis.
- D. Duodenum ulcer perforation.
- E. Acute pancreatitis.

7. The patient, 62 years old, went to the hospital with complaints about intense pain in the right side of the abdomen, which is intensified on deep breathing and coughing, dry cough and fever to 39 °C. A patient is sick for 4 days. On examination: pale skin, acrocyanosis, RR - 32 per minute, BP 100/70 mm Hg., heart rate - 110 per minute. Under the right scapula - dull percussion sounds, on auscultation - crackling. Palpation revealed pain in the projection of the gallbladder. Liver on the edge of the costal arch. What method of research is needed in this case?

- A. Ultrasonography of the abdominal cavity.
- B. Retrograde cholecystography.
- C. Radiography of the chest.
- D. EFGDS.
- E. Diagnostic laparoscopy.

8. Male, 44 years old, after alcohol abuse felt a sharp, girdle pain in the upper abdomen, which was accompanied by repeated vomiting without relief. The patient's condition is serious, skin is pale, covered with cold sweat, blood pressure 90/60 mmHg., Heart rate - 110 per minute. Distended abdomen, tenderness on palpation. Which figure is decisive for diagnosis in this case?

- A. Neutrophil leukocytosis with a shift to the left.
- B. Increased blood glucose levels.
- C. Hyperamylasemia.
- D. Hyperasotemia.
- E. Increase in ALT, AST.

9. A 28-year-old patient has been hospitalized for pain in the epigastric region. He has a 10-year history of duodenal ulcer (DU). Recently, the pain character has changed: it became permanent, persistent, irradiating to the back. There are general weakness, dizziness, fatigue. The patient has lost weight. Objectively: HR - 68/min, AP - 120/80 mm Hg. What is the most likely cause of deterioration?

- A. Haemorrhage
- B. Penetration
- C. Perforation of duodenal wall
- D. Exacerbation of duodenal ulcer
- E. Stenosis development

10. Patient 44 years old, received treatment with nonsteroidal anti-inflammatory drugs for reactive arthritis. Suddenly he felt sharp pain in the upper abdomen, nausea. On examination: tongue is dry and furred with white bloom. On auscultation: vesicular breathing. RR - 18 min. Heart sounds are clear. HR - 90 min, blood pressure - 110/70 mmHg. The abdomen is soft on palpation, pain in the upper half,

the symptoms of peritoneal irritation are absent. Which research method would be the best in this case?

- A. Ultrasonography of the abdominal cavity.
- B. Retrograde cholecystography.
- C. Radiography of the chest.
- D. EFGDS.
- E. Diagnostic laparoscopy.

11. A 35 yo male patient was admitted to a hospital. A patient is pale, at an attempt to stand up he complains of strong dizziness. There was vomiting like coffee grounds approximately an hour ago. BP - 90/60 mm Hg., pulse - 120 b/min. In the anamnesis, a patient has suffered from an ulcer of the stomach, painless form during 4 years. An ulcer was exposed at gastrofiberoscopy. Your diagnosis:

- A. Erosive gastritis
- B. Ulcer of duodenum, complicated with bleeding
- C. Ulcer of stomach, complicated with bleeding
- D. Acute pleurisy
- E. Acute myocardial infarction, abdominal form

12. A 45-year-old male patient undergoing treatment for peptic ulcer complains of weakness, dizziness, coffee-ground vomiting, melena. After administration of haemostatics the patient's condition has not improved, fresh blood has shown up in the vomit, skin bruises of different sizes have appeared. In blood: thrombocytes - $50 \times 10^9/L$, Lee-White clotting time - 35 minutes, APTT - 80 seconds. In this case it is most rational to administer the following preparation:

- A. Heparin
- B. Fresh frozen plasma
- C. Fibrinogen
- D. Rheopolyglucinum
- E. Vikasol

13. The patient, 40 years old, felt weakness, nausea, liquid tarry stools. On examination: consciousness maintained, tremor of the fingers. Skin is pale, with scratching. Pulse 106 per minute, BP-110/60 mm Hg, RR-14/min. Heart sounds are relaxed, rhythmic, and in lungs - vesicular breathing. Ascites, varicose veins of the anterior abdominal wall, palpation of the abdomen, painless, the liver + 8 cm thick, the edge is sharp, tight, spleen + 6 cm. Blood: Hb 90 g / l, Er- $3.5 \times 10^{12}/L$, Cl. - 0.95, glucose 3.0 mmol / L, urea - 3.1 mmol / L, creatinine 0.19 micromol / l, bilirubin - 156 mmol / L (direct-78 mmol / l), ALT - 90 U/L, prothrombin 65% . The most reliable diagnosis is?

- A. Cirrhosis of the liver, stomach bleeding from varicose veins.
- B. Exacerbation of chronic hepatitis, bleeding from the hemorrhoidal veins.
- C. Gastric ulcer, gastric bleeding.
- D. Ulcerative colitis.
- E. Hepato-renal failure, intestinal bleeding.

14. A patient aged 60, complains about intermittent abdominal distension, constipation, the presence of blood in the stool. He is sick for 6 months. Had lost 6 kg. The abdomen is not distended, soft, mildly painful in the left iliac region, palpation defines the dense formation of up to 6 cm in size. Your diagnosis?

- A. Cancer of the sigmoid colon.
- B. Ulcerative colitis.
- C. Hemorrhoids
- D. Coprostasia.
- E. Spastic colitis.

15. The patient complains about cramping abdominal pain and stool mixed with blood and pus up to 10 times a day. Sick for 3 weeks. Colonoscopy: the mucous membrane of the sigmoid colon covered with petechial hemorrhages and ulcers. Your diagnosis?

- A. Ulcerative colitis.
- B. Crown's disease.
- C. Irritable bowel syndrome
- D. Ischemic colitis

E. Chronic (nonulcerous) colitis

16. The patient, 45 years old, takes over 15 years of nonsteroidal anti-inflammatory drugs and periodically prednisolone from rheumatoid arthritis. Suddenly, in the morning she felt nausea, epigastric pain, severe weakness. The emergency room doctor fixed: the patient is conscious, pale skin, weak pulse, filling in 116 min, blood pressure, 65/55 mmHg, heart - the sounds are weakened, in lungs - vesicular breathing, coated tongue, abdomen is soft on palpation, painful in the epigastric region, peristalsis auscultated. The most reliable diagnosis is?

A. Bleeding from acute peptic ulcer.

B. Acute pancreatitis.

C. Perforated gastric ulcer.

D. Acute drug gastritis.

E. Dissecting aneurysm of the aorta.

17. The patient, 64 years old, complains of the presence of dark blood with clots in faecal mass, general weakness. Recently lost 6 kg. The skin and mucous membranes are pale. Subcutaneous fat is expressed moderately. HR - 82 beats / min. BP - 145/80 mm Hg. Pulse has good filling and tension, rhythmic. The abdomen is soft, slightly painful in the upper half. At what level of the digestive tract may be the place of bleeding?

A. Colon.

B. Esophagus.

C. Stomach.

D. 12-duodenum.

E. Small intestine.

18. The patient, aged 28, was delivered to the hospital in serious condition. Complaints of pain in the epigastrium, "ground coffee" vomiting, weakness, heartburn. Got sick 8 hours ago. Previously, heartburn, which relieved after taking soda. Reduced feeding, pale, blood pressure 80/40 mmHg, pulse 110 beats per minute. Blood Hb - 78 g / L, erythrocyte - $2.2 \times 10^{12}/L$, Ht - 0.34. Rectal finger examination found mushy black stool. What preliminary diagnosis can be made?

A. Duodenal ulcer, acute gastric bleeding.

B. Acute alcohol poisoning.

C. Acute pancreatic necrosis.

D. Ulcerative colitis, a severe form.

E. Acute hemorrhagic gastritis.

19. In a 30-year-old man marks nocturnal pains in the epigastric region during the last month, which decreased after a meal. Two days ago thin black stool appeared. Objectively: the general condition of the patient is satisfactory. Moderate tachycardia (up to 100 for 1 min.). BP is normal. The abdomen is soft, no sharp pain in the epigastric region. Hb - 100 g / l, the deficit CBV (circulation blood volume) - 15%. What kind of research is needed for diagnosis?

A. EGDS.

B. PH-metry of gastric contents.

C. X-ray of the abdominal cavity.

D. Sigmoidoscopy.

E. Fibrocolonoscopy.

20. In a 72-year-old patient, during a hypertensive crisis, an emergent bleeding from the rectum appeared. For several years, suffered from aching pain along the large intestine, constipation. The abdomen is soft and painless on palpation. Hemorrhoids do not bleed. In the ampoule there are clots of dark blood. Erythrocytes $4.2 \times 10^{12}/L$ Hb - 126 g / liter. Which research method would be the most helpful?

A. Irrigation.

B. Sigmoidoscopy.

C. Colonoscopy.

D. X-ray abdomen survey.

E. Rectal finger examination.

Clinical tasks

Task No. 1.

In a patient with arterial hypertension suddenly appeared the sharp pain behind the sternum with irradiation to the back, extends to the spine, expressed increasing shortness of breath, dizziness.

Objectively : pale skin. Pulse 116 per minute., rhythmic , asymmetric in arms . BP 90/50 mmHg, heart tones are weakened, systolic-diastolic murmur over the aorta. In the lungs, vesicular breathing, the abdomen is soft and painless.

Questions

1. What disease can be suspected?
2. What additional methods of examination must be applied in this case?

Task No. 2.

The patient, 33 years old, with duodenum ulcer due to pronounced exacerbation of the disease had suddenly appeared "dagger" a pain in the ep and gastr al area . Objectively : symptoms of peritoneum irritation, disappearance of hepatic dullness; radiologically - free air in the abdominal cavity.

Questions

1. What complication had developed in a patient ?
2. What emergency care does the patient require?

Task No. 3.

The patient , 74 years old, complained of pain and bloating , nausea. He suffers from coronary artery disease, has post - infarction and atherosclerotic cardiosclerosis. Objectively: the state is serious, distended abdomen, abdominal wall is slightly involved in the act of breathing. On laparoscopy in the abdominal cavity revealed a small amount of muddy liquid, one of the loops of the small intestine has a dark bluish color.

Questions

1. What is the most reliable diagnosis?
2. What first aid does the patient need ?

Task No. 4.

The patient M., aged 47, who had viral hepatitis B 2 years ago, is observed a constant dyspeptic syndrome, weight loss. Suddenly, after a meal and little physical activity began to vomit with dark blood. OBJECTIVE LY : Skin is pale, moist, icteric sclera, blood pressure 80/50 mmHg. Pulse 102 beats per minute., ascites, hepatosplenomegaly.

Questions

1. What is the most significant cause of bleeding?
2. What is the algorithm for emergency care in this clinical case?

Task 5.

The patient P., aged 23, during half a year noted pain in the epigastrium , which was at night, sour belching, suddenly started "coffee grounds" vomiting and emerged dizziness in the street. He was delivered to the hospital by an ambulance.

Questions

1. What is the preliminary diagnosis?
2. What is the algorithm for emergency care in this clinical case?

Task No. 6 .

In patient N. 48 years old, 5 months after emotional stress appeared hypogastrium pains , loss of weight, nausea, diarrhea up to 14-16 times a day mixed with blood and pus in the stool. OBJECTIVE: on palpation in the abdomen is determined spasmodic painful intestine .

Questions

1. What studies should be primarily done for the diagnosis verification ?
2. What is the algorithm for emergency care in this clinical case?

Summary:

Recommended reading list

Basic literature:

- Harrison's Principles of Internal Medicine Self-Assessment and Board Review, 20th Edition 20th Edition.- (August 13, 2021). - 736 pages
- Pocket Medicine: The Massachusetts General Hospital Handbook of Internal Medicine / 007 edition (12 Sept. 2019). - 272 pages
- Davidson's Principles and Practice of Medicine: Enhanced Digital Version Included / Elsevier; 23rd edition (25 April 2018). - 1440 pages

Additional literature:

- Macleod's Clinical Examination /Elsevier; 14th edition (11 Jun. 2018). - 400 pages
- Current Medical Diagnosis and Treatment /McGraw-Hill Education; Updated edition (14 Sept. 2021). - 1840 pages
- Lippincott Connect Standalone Courseware for Bates' Guide to Physical Examination and History Taking 1.0 /LWW; 13th ed. edition (23 Mar. 2023).
- Step-Up to Medicine / Wolters Kluwer Health; 5th edition (8 May 2019). - 582 pages
- Goldman-Cecil Medicine, 2-Volume Set (Cecil Textbook of Medicine) / Elsevier; 26th edition (20 Dec. 2019). - 2944 pages
- The Washington Manual of Medical Therapeutics / Wolters Kluwer Health; 36th edition (6 Jun. 2019). - 1074 pages
- Harrison's Manual of Medicine / McGraw-Hill Education; 20th edition (5 Nov. 2019). - 1245 pages

Electronic information resources

- World Health Organization. URL: www.who.int/ru/index.html.
- European Regional Office of the World Health Organization. URL: www.euro.who.int.
- <https://www.aasld.org/>
- https://academic.oup.com/ndt/pages/General_Instruction
- <https://cprguidelines.eu/>
- <https://www.escardio.org/Guidelines/Clinical-Practice-Guidelines>
- <http://www.oxfordmedicaleducation.com/>
- <http://ard.bmj.com>
- <https://www.escardio.org/Guidelines/Clinical-Practice-Guidelines>

Practical class

Topic 40. Emergency conditions in the clinic of military therapy.

The main goals:to acquire communication skills and skills of clinical examination of a patient in emergency situations in a military medicine clinic; learn to establish a preliminary diagnosis, carry out a differential diagnosis and establish a clinical diagnosis of a disease in a patient in emergency conditions in a military medicine clinic; to diagnose emergency conditions in patients with emergency conditions in the military medicine clinic; determine tactics and provide emergency medical care to patients with emergency conditions in the military medicine clinic; to be able to perform medical manipulations on patients with emergency conditions in the military medicine clinic.

Key words: characteristic therapeutic pathologies in the war and at disasters natural and man- made; features organizations therapeutic assistance in local wars in the armed forces conflicts and at disasters natural and man-made; principles medical sorting and organizations emergency medical assistance to the wounded , injured and sick on stages evacuation; features medical evacuation support at firearms injuries , burns, frostbite and radiation defeats; features medical evacuation support at damage combat poisonous substances and poisoned by poisons technical fluids ; about sobriety carrying out detoxification therapy on stages evacuation at acute poisoning ; about sobriety carrying out antidote therapy on stages evacuation at damage combat poisonous substances; features pathogenetic and symptomatic therapy at injuries , lesions and diseases ; about sobriety occurrence course and treatment diseases of internal organs in wartime.

Equipment:multimedia materials - a set of thematic slides from the department's multimedia library; a set of situational problems on the topic of the class; dummies for practicing practical skills.

Plan:

1. Organizational measures (greetings, verification of those present, announcement of the topic, purpose of the lesson, motivation of higher education seekers to study the topic)
2. Control of the reference level of knowledge (checking homework, written work, written testing, including writing KROK-2 tests, frontal survey)
3. Formation of professional abilities and skills (mastery of skills, curation, determination of the treatment regimen, laboratory research, etc.): discussing the specifics of diagnosis and treatment of patients with acute abdominal pain, the most common clinical manifestations, criteria for establishing a diagnosis
4. Summing up (summarizing the topic, evaluating applicants, discussing the next lesson topic and homework)

Control questions:

1. Characteristics of therapeutic pathology at war and in natural and manmade disasters.
2. Specifics of therapeutic care in local wars and armed conflicts and natural/manmade disasters.
3. The principles of triage and emergency medical aid organization at the stages of evacuation.
4. Specifics of medical evacuation support in gunshot wounds, burns, frostbite, and radiation damage.
5. Features of medical evacuation support in cases of chemical warfare agents and toxic poisoning technical liquids intoxication.
6. Detoxification phases during evacuation of acutely poisoned victims.
7. Antidote therapy during evacuation in case of use of chemical warfare agents.
8. Features of pathogenetic and symptomatic therapy for wounds, injuries and internal diseases.
9. Origin, course and treatment of diseases of internal organs in wartime.
10. Organization of qualified and specialized medical care for the wounded, sick and afflicted.

Tests

1. The basic principle of the medical triage of casualties is:
 - A) Diagnosis of the disease and its prognosis
 - B) Age of the patient
 - C) The severity of injury or disease
 - D) Damage-causing agent
 - E) The urgency of the medical and evacuation measures
2. Diseases that make rescue operations in the area of emergency situations most difficult to carry out are:
 - A) ARVIs
 - B) Especially dangerous infections
 - C) Cardiovascular disorders
 - D) Respiratory diseases
 - E) Skin and subcutaneous tissue diseases
3. In extremely severe acute radiation syndrome in the first three days we prescribe:
 - A) Antiemetics;
 - B) Tranquilizers;
 - C) Medications for dealing with the collapse and hypotension;
 - D) Radioprotective drugs, antibiotics
 - E) Pathogenetic and symptomatic therapy
4. How many stages are organized in the modern system of medical evacuation?
 - A) Five stages of evacuation
 - B) Four stages of medical evacuation
 - C) One stage of medical evacuation
 - D) Three stages of medical evacuation

- E) Two stages of medical evacuation
5. In-hospital medical evacuation provides:
- A) First aid
 - B) Qualified and specialized medical care
 - C) Primary physician care
 - D) Pre-hospital and skilled medical care
 - E) All answers are correct
6. Priority actions at the accident site:
- A) Organization of all kinds of intelligence, bringing in full readiness of the emergency services and getting ready ways of physical and medical protection.
 - B) Evacuation of the population, the mobilization of the necessary material and technical resources, changing the mode of operation, the maintenance of public order.
 - C) Examination of emergency site, calculation of sanitary losses.
 - D) Prediction and assessment of the situation in the accident site, the organization of medical intelligence, deployment of additional hospital beds for admission of affected.
 - E) Organization of all kinds of intelligence (chemical, radiological, bacteriological).
7. Chlorine and ammonia vapor causes:
- A) Excitement and euphoria
 - B) Irritation of the upper respiratory tract
 - C) Skin lesions, chemical burns
 - D) Neurological disorders
 - E) Toxic pulmonary edema
8. Medical triage begins:
- A) In the accident or catastrophe site
 - B) In the units of specialized medical care
 - C) While transporting affected people to hospitals
 - D) In the primary casualty collection sites
 - E) In health care facilities
9. Antidote for organophosphate poisoning is:
- A) Magnesium sulfate
 - B) Atropine
 - C) Prozerin
 - D) Sodium thiosulfate
 - E) Unithiol
10. The optimal period for getting qualified medical aid is:
- A) any period of time;
 - B) within 3 hours;
 - C) within 3-6 hours;
 - D) within 6-9 hours
 - E) within 9-12 hours;

Clinical tasks

- 1.** The victim V. delivered to the sorting area 2.5 hours after a nuclear explosion. Complaining of a severe headache, dizziness, increasing weakness, thirst, constant nausea and vomiting. These symptoms appeared after 5-10 minutes after irradiation and steadily grew. On examination, sluggish, slow-moving, there is flushing of the skin, redness of the sclera, continued vomiting. ON pulse beats / min, rhythmic, muffled heart sounds, I tone at the top is weakened, BP - 90/70 mm Hg., 24 breaths per minute. The body temperature of 38.7 ° C. Indications of personal dosimeter: 5.9 Gy.
1. Formulate and justify a diagnosis.
 2. Conduct medical triage.
 3. Determine the amount of needed first aid and evacuation goal of the victim.
- 2.** The victim K. delivered to the sorting area from the source of the use of chemical weapons 2.5

hours after a chemical attack. Complaints of chest pain, headache, dizziness, "fog" in front of his eyes. These changes in the condition of the victim came in 10-15 minutes after leaving the affected area. Independently introduced the antidote from the individual first-aid kit.

On examination, apathetic, depressed. Skin is moist, pupils contracted, their reaction to light is weakened. Pulse 70 beats / min, rhythmic, muffled heart sounds, no noise, blood pressure - 150/90 mm Hg, vesicular breathing.

1. Formulate and justify a diagnosis.
2. Conduct medical triage.
3. Determine the amount of first aid and evacuation goal of the victim.

3. B. The victim was in the focus of the use of napalm. Delivered to the sorting area in 2 hours. Complaints of a headache of pulsating nature, tinnitus, the emergence of "fog" in front of the eyes, the increasing muscle weakness, especially in the legs. On examination, marked psychomotor agitation, euphoria, facial flushing pulse 96 beats / min, heart sounds weak, BP - 90/70 mm Hg., 24 breaths per minute, vesicular breathing. The body temperature of 37.0 ° C.

1. Formulate and justify a diagnosis.
2. Conduct medical triage.
3. Determine the amount of first aid and evacuation goal of the victim

Summary:

Recommended reading list

Basic literature:

- Harrison's Principles of Internal Medicine Self-Assessment and Board Review, 20th Edition 20th Edition.- (August 13, 2021). - 736 pages
- Pocket Medicine: The Massachusetts General Hospital Handbook of Internal Medicine / 007 edition (12 Sept. 2019). - 272 pages
- Davidson's Principles and Practice of Medicine: Enhanced Digital Version Included / Elsevier; 23rd edition (25 April 2018). - 1440 pages

Additional literature:

- Macleod's Clinical Examination /Elsevier; 14th edition (11 Jun. 2018). - 400 pages
- Current Medical Diagnosis and Treatment /McGraw-Hill Education; Updated edition (14 Sept. 2021). - 1840 pages
- Lippincott Connect Standalone Courseware for Bates' Guide to Physical Examination and History Taking 1.0 /LWW; 13th ed. edition (23 Mar. 2023).
- Step-Up to Medicine / Wolters Kluwer Health; 5th edition (8 May 2019). - 582 pages
- Goldman-Cecil Medicine, 2-Volume Set (Cecil Textbook of Medicine) / Elsevier; 26th edition (20 Dec. 2019). - 2944 pages
- The Washington Manual of Medical Therapeutics / Wolters Kluwer Health; 36th edition (6 Jun. 2019). - 1074 pages
- Harrison's Manual of Medicine / McGraw-Hill Education; 20th edition (5 Nov. 2019). - 1245 pages

Electronic information resources

- World Health Organization. URL: www.who.int/ru/index.html.
- European Regional Office of the World Health Organization. URL: www.euro.who.int.
- <https://www.aasld.org/>
- https://academic.oup.com/ndt/pages/General_Instruction
- <https://cprguidelines.eu/>
- <https://www.escardio.org/Guidelines/Clinical-Practice-Guidelines>
- <http://www.oxfordmedicaleducation.com/>
- <http://ard.bmj.com>
- <https://www.escardio.org/Guidelines/Clinical-Practice-Guidelines>

Practical class

Topic 41. Peculiarities of management of seriously ill, incurable patients.

The main goals: to acquire communication skills and clinical examination skills of seriously ill, incurable patients; master the principles of treatment, recommendations for lifestyle changes in the management of seriously ill, incurable patients; learn to diagnose emergency conditions in seriously ill, incurable patients and master the tactics of providing emergency medical aid; to be able to perform therapeutic manipulations in seriously ill, incurable patients.

Key words: the creation of hospice care in a historical aspect; definition of hospice as a medical institution; hospice structure; principles of providing medical care in hospice conditions. Hospice charter; special requirements for hospice staff; types of anesthesia used in hospice care; the concept of "three-stage pain relief system"; peculiarities of ethical and deontological relations between doctor and patient in hospice practice; hospice care in pediatrics; ambulatory polyclinic link in the structure of hospice care.

Equipment: multimedia materials - a set of thematic slides from the department's multimedia library; a set of situational problems on the topic of the class; dummies for practicing practical skills.

Plan:

1. Organizational measures (greetings, verification of those present, announcement of the topic, purpose of the lesson, motivation of higher education seekers to study the topic)
2. Control of the reference level of knowledge (checking homework, written work, written testing, including writing KROK-2 tests, frontal survey)
3. Formation of professional abilities and skills (mastery of skills, curation, determination of the treatment regimen, laboratory research, etc.): discussing the specifics of diagnosis and treatment of patients with acute abdominal pain, the most common clinical manifestations, criteria for establishing a diagnosis
4. Summing up (summarizing the topic, evaluating applicants, discussing the next lesson topic and homework)

Control questions:

1. Creation of hospice care in historical perspective.
2. Definition of the hospice as a medical institution.
3. Structure of the hospice.
4. The principles of medical care in a hospice. Rules of hospice.
5. Specific requirements for hospice staff.
6. Types of pain relief used in Hospice Care.
7. The term "three-tier system of relief".
8. Features of the ethical-deontological physician-patient relationship in the practice of hospice
9. Hospice care in Pediatrics.
10. Outpatient care in the structure of hospice care.

Tests

1. Methods of treating cancer patients at the hospice stage:
 - A) Radical, palliative and symptomatic
 - B) Surgical, pharmacological
 - C) Chemotherapy, radiotherapy
 - D) Life-long treatment
 - E) Radical and anti-relapse treatment
2. What type of palliative care is used in patients with late-diagnosed lung cancer - the most common cancer pathology in men?
 - A) The control of pain
 - B) Psychological support for the patient
 - C) Help in dealing with legal issues
 - D) Operative and conservative treatment of complications
 - E) All of the above

3. The primary goal of hospice medicine is:
 - A) Recovery of the patient
 - B) Treatment of complications
 - C) Create the most fulfilling life in the time remaining to the patient
 - D) Spa treatment of the patient
 - E) Psychological help for sick relatives
4. In Ukraine malignancies among the causes of death of the population are at the:
 - A) 1st place
 - B) 2nd place
 - C) 7-8th place
 - D) 10th place
 - E) 15th place
5. In industrialized countries, the main reason for the increase in mortality from cancer is:
 - A) the aging of the population
 - B) a sharp deterioration of ecological conditions
 - C) increasing impact of occupational hazards
 - D) no correct answer
 - E) bad habits
6. Painless tumor formation 23 mm palpated in the left breast, nipple is deformed, areola swelling is noted, no discharge from the nipple. Regional lymph nodes are not palpable. The most likely diagnosis
 - A) fibroadenoma
 - B) nodal mastopathy
 - C) lipoma
 - D) Breast cancer
 - E) Mintz disease
7. A patient who is supervised because of end-stage breast cancer, developed complicated lymphostasis of upper limb after combined treatment for breast cancer. The following treatment methods can be applied:
 - A) Vibromassage
 - B) Wearing elastic compressive sleeves
 - C) The application of ointment with horse chestnut extract
 - D) Prevention of erysipelas
 - E) All answers are correct
8. For the prevention of what condition "opioid rotation" is used?
 - A) depression of the respiratory center
 - B) vomiting
 - C) opioid resistance
 - D) allergic reactions
 - E) the progression of cancer
9. What is the visual analog scale (VAS) scoring from 1 to 10?
 - A) The extent of cancer process
 - B) The strength of pain
 - C) Assessment of the quality of hospice care
 - D) The degree of depletion of a cancer patient
 - E) Visual acuity patients
10. Which drugs would you prefer in case of pain of low intensity (in the first stage of pharmacotherapy of pain):
 - A) Promedol
 - B) Morphine
 - C) Tramadol
 - D) Ibuprofen
 - E) Nalbuphine

Clinical tasks

1. The patient P. 84 years old, stage 4 prostate cancer. Multiple metastases in the abdomen, persistent pain (VAS 7-8). The patient is in a state of depression.

1. Determine the tactics of patient care.
2. Types of psychological support to the patient.
3. Assign adequate analgesic therapy.

2. Patient G., 50 years old, a radiologist. In history: goiter, elevated TSH levels. Family history: grandmother died of thyroid cancer, survived after combined therapy for 5 years. Recently complains of an increase in the rate of growth of goiter, the appearance of thick formations in the gland tissue, difficulty in movement, shortness of breath, weakness, abdominal enlargement. Objectively: the body temperature is N, the thyroid gland is enlarged, palpable induration without clear boundaries can be palpated, pain in the bones, signs of ascites. Lab testing reveals an elevated level of calcitonin.

1. Your diagnosis?
2. With what diseases differential diagnosis is needed?
3. Main directions of hospice care.

3. Patient N., 70 years old. Has a history of achalasia of the esophagus. Complaints of chest pain, feeling of fullness in the chest when eating, increased salivation, weakness, difficulty swallowing. Objectively: the patient is asthenic, malnourished, pale skin, peripheral lymph nodes are not enlarged, vesicular breathing, conducted in all lung segments, tongue is coated with white bloom, abdomen is soft and painless. Chest radiography + contrast: without lung pathology, esophagus has narrowing of the lumen due to the infiltration of the posterior and anterior wall of the middle and lower thoracic parts, uneven contours of the esophagus. Esophagoscopy: medium- and lower thoracic parts show infiltration of the mucosa, the esophageal lumen is narrowed to 0.6 cm. Histological examination: squamous cell carcinoma.

1. Management of the patient.
2. Types of parenteral nutrition in this patient
3. Methods of pain-control

Summary:

Recommended reading list

Basic literature:

- Harrison's Principles of Internal Medicine Self-Assessment and Board Review, 20th Edition 20th Edition.- (August 13, 2021). - 736 pages
- Pocket Medicine: The Massachusetts General Hospital Handbook of Internal Medicine / 007 edition (12 Sept. 2019). - 272 pages
- Davidson's Principles and Practice of Medicine: Enhanced Digital Version Included / Elsevier; 23rd edition (25 April 2018). - 1440 pages

Additional literature:

- Macleod's Clinical Examination /Elsevier; 14th edition (11 Jun. 2018). - 400 pages
- Current Medical Diagnosis and Treatment /McGraw-Hill Education; Updated edition (14 Sept. 2021). - 1840 pages
- Lippincott Connect Standalone Courseware for Bates' Guide to Physical Examination and History Taking 1.0 /LWW; 13th ed. edition (23 Mar. 2023).
- Step-Up to Medicine / Wolters Kluwer Health; 5th edition (8 May 2019). - 582 pages
- Goldman-Cecil Medicine, 2-Volume Set (Cecil Textbook of Medicine) / Elsevier; 26th edition (20 Dec. 2019). - 2944 pages
- The Washington Manual of Medical Therapeutics / Wolters Kluwer Health; 36th edition (6 Jun. 2019). - 1074 pages
- Harrison's Manual of Medicine / McGraw-Hill Education; 20th edition (5 Nov. 2019). - 1245 pages

Electronic information resources

- World Health Organization. URL: www.who.int/ru/index.html.
- European Regional Office of the World Health Organization. URL: www.euro.who.int.
- <https://www.aasld.org/>

- https://academic.oup.com/ndt/pages/General_Instruction
- <https://cprguidelines.eu/>
- <https://www.escardio.org/Guidelines/Clinical-Practice-Guidelines>
- <http://www.oxfordmedicaleducation.com/>
- <http://ard.bmj.com>
- <https://www.escardio.org/Guidelines/Clinical-Practice-Guidelines>