

ХІРУРГІЧНА СТОМАТОЛОГІЯ

UDC

DOI <https://doi.org/10.35220/2078-8916-2023-48-2.14>**A. G. Gulyuk,**

Doctor of Medical Sciences, Professor,
Head of the Department of Surgical Dentistry,
Odessa National Medical University, 2 Valikhovsky lane,
Odessa, Ukraine, postal code 65082 hirstom@onmedu.edu.ua

THE ABBE FLAP IN SECONDARY CLEFT LIP REPAIR (CLINICAL CASE)

Secondary deformities of the cleft lip are unfortunately very common, and severe cases can involve scar contracture, vermilion deficiency, and a tight upper lip. In these cases, reconstruction often requires replacement of the central philtral unit with full-thickness tissue, including vermilion, *m. orbicularis oris*, and skin. Results of cleft lip repair are often poor because of inappropriate use of the hypoplastic prolabial tissue, failure to anatomically reunite the orbicularis muscle, and scarring. **Purpose.** This article reports on the Abbé flap for correction of mild tightness of the corrected cleft lip and nose deformity. **Patients and methods.** 12 patients with a moderately tight lip deformity, from 18 to 25 years old, underwent this procedure. 9 had a unilateral deformity and 3 a bilateral deformity. The flap, which was taken from the central portion of the lower lip vermilion, was designed to repair the vermilion tubercle and the Cupid's bow. It was inserted into the center of the upper lip and the pedicle was divided 1 week after operation. **Technique.** The Abbe flaps in this series were taken from the middle of the lower lip to replace a portion of the upper lip. Lip height to the nose or to the labiomental fold was assessed at the preoperative visit so that postoperative lip height could be correlated to the pre-existing anatomy. **Conclusion.** Use of modified Abbé flap to reconstruct the contour of the vermilion tubercle and the Cupid's bow makes the upper lip look more natural. Even though maxillofacial reconstructive surgery has undergone a sea change from the use of traditional flaps to the present day microsurgical free tissue transfer, Abbe still holds in a position as a reliable method of lip reconstruction. Our experience with 12 patients with Abbe flap reconstruction has been encouraging and the result obtained was extremely satisfactory. The Abbe flap procedure gives satisfactory results in the secondary reconstruction of deficient upper lips in persons with cleft lip. The width of the flap must be 1 to 1.5 cm, the length should be sufficient to reach the base of the columella, the shape triangular or shield-shaped, and the position medial. The tissue transfer from the lower lip creates philtral dimple and philtral ridges. Disadvantages of the Abbe flap include patient discomfort and the need for multiple procedures.

Key words: Abbe flap, elimination of secondary deformity of the upper lip, non-fusion of the upper lip.

A. G. Gulyuk,

доктор медичних наук, професор,
завідувач кафедри хірургічної стоматології,
Одеський національний медичний університет,
Валіховський провулок, 2, м. Одеса, Україна,
індекс 65082 hirstom@onmedu.edu.ua

КЛАПОТЬ АББЕ ПРИ ВТОРИННОМУ ВІДНОВЛЕННІ НЕЗРОЩЕННЯ ВЕРХНЬОЇ ГУБИ (КЛІНІЧНИЙ ВИПАДОК)

Вторинні деформації після усунення незрошення верхньої губи, на жаль, дуже поширені, і у важких випадках можуть спостерігатися рубцева контрактура, брак м'яких тканин середньої частини верхньої губи. У цих випадках реконструкція часто вимагає збільшення обсягу тканин, що утворюють центральну частину верхньої губи. Результати пластики верхньої губи часто незадовільні через неправильне використання недорозвинених тканин оро-губної ділянки, нездатність анатомічно з'єднати фрагменти кругового м'яза і утворення рубців. **Мета роботи.** У цій статті показані результати використання клаптя за Аббе для корекції недостатнього обсягу тканин середнього відділу верхньої губи при усуненні вторинної деформації після хейлопластики. **Пацієнти та методи.** Цю процедуру пройшли 12 пацієнтів з помірно напруженою деформацією губ у віці від 18 до 25 років. У 9 була одностороння деформація і у 3 – двостороння. Клапоть, який був узятий з центральної частини нижньої губи, був призначений для відновлення горбка і дужки Купідона. Він був вставлений в центр верхньої губи, і живляча ніжка була відокремлена через 1 тиждень після операції. Клапоть за Аббе в цій серії був взятий з середини нижньої губи, щоб замінити частину верхньої губи. Висота губи оцінювалася при передопераційному відвідуванні, щоб післяопераційну висоту губи можна було співвіднести до існуючої. **Висновок.** Використання модифікованого клаптя Аббе для відновлення контуру дуги Купідона надає верхній губі більш природний вигляд. Незважаючи на те, що щелепно-лицьова реконструктивна хірургія зазнала значних змін від використання традиційних клаптів до сучасної мікрохірургічної пересадки вільних тканин, метод за Аббе як і раніше залишається надійним методом реконструкції губ. Наш досвід роботи з 12 пацієнтами, які перенесли реконструкцію за Аббе, був обнадійливим, а отриманий результат був надзвичайно задовільним. Процедура використання клаптя Аббе дає задовільні результати при вторинній реконструкції дефектів верхньої губи у осіб з незрошенням верхньої губи. Перенесення тканин з нижньої губи створює достатній обсяг середньої частини верхньої губи. До недоліків клаптя Аббе відносяться дискомфорт пацієнта і необхідність проведення декількох процедур. **Ключові слова.** клапоть за Аббе, усунення вторинної деформації верхньої губи, незрошення верхньої губи.

Introduction. Secondary deformities of the cleft lip are unfortunately very common, and severe cases can involve scar contracture, vermilion deficiency, and a tight upper lip. In these cases, reconstruction often requires replacement of the central philtral unit with full-thickness tissue, including vermilion, m. orbicularis oris, and skin. The Abbe flap offers full-thickness reconstruction of the central aesthetic unit of the upper lip by replacing the deficient and scarred tissue and restoring functional competence to the oral sphincter. (Theodore T. N., et al; 2014; John C Koshy, et al, 2010 Sarrami SM, et al 2021., Ma H, et al 2019; Ishigaki T, Udagawa A., 2021; Li L, et al, 2015;).

Results of bilateral cleft lip repair are often poor because of inappropriate use of the hypoplastic prolabial tissue, failure to anatomically reunite the orbicularis muscle, and scarring. The Abbe flap is an effective tool for reconstruction of the philtral landmarks, reconstitution of oral competence of the orbicularis, and recreation of Cupid's bow and the central pout. Although this procedure is relatively straightforward, special attention to designing the new philtrum, marking intact landmarks, and careful dissection of the labial artery are required for successful reconstruction. (Lo LJ, Kane AA, Chen YR., 2003).

In the repair of unilateral cleft lip, the Cupid's bow, and vermilion on the affected side are sometimes lowered excessively. Methods involving skin and mucosa flaps have been used to correct this issue, but they pose some risk of scarring. The authors here describe a layered muscle flap technique that was based on the anatomical research of nasal-labial muscles, especially the levator labii superioris alaeque nasi muscle. This technique can be used to suspend the Cupid's bow and vermilion in secondary unilateral cleft lip repair. These patients were treated using the layered muscle flap surgical technique. The heights of specific bilateral landmarks were measured on patient photos and used to define the symmetry of bilateral Cupid's bow and vermilion. The comparison between post-operative and pre-operative symmetries was used to evaluate the post-operative results, and most of them were satisfactory. The results were also mostly well retained in follow-up investigations. This layered muscle flap technique could be effective in selected cases. (Ma H., et al; 2019).

The Abbe flap is a full-thickness composite flap, involving the transfer of the skin, muscle, and mucosa of the central part of the lower lip to the upper lip. This vermilion-pedicled flap, based on the inferior labial

vessels, has been used for secondary corrections in cleft deformities, more often in bilateral cases. Indications for its use include deficiency of scarring of the central part of the upper lip. thinness of the vermilion with a nonexistent lip tuberculum, or the absence of a Cupid's bow. The procedure may be combined with other reconstructive procedures. (Theodore T. N., et al; 2014; Bagatin M, Most SP. 2002;) Use of modified Abbe flap to reconstruct the contour of the vermilion tubercle and the Cupid's bow makes the upper lip look more natural (Takato T., et al; 1996). There are several surgical techniques for unilateral cleft lip repair. In most of these techniques, the points where the postoperative scars cross the vermilion border are on the peak of the Cupid's bow. These scars make the shape of Cupid's bow indistinct. (Ishigaki T, Udagawa A. 2021). A solid understanding of cutaneous anatomy is important in flap design and elevation. Depending on the defect location, the Abbe flap pedicle is the superior or inferior labial artery, originating from the facial artery just lateral to the oral commissure. These vessels then course in a horizontal plane deep to mucosa overlying the orbicularis oris muscle to anastomose at the midline with contralateral branches. The superior labial artery provides blood supply to the upper lip with terminal branches supplying the nasal alae and septum. The inferior labial artery provides blood supply to the lower lip and superior part of the chin. Small cutaneous branches are cut during flap elevation but spontaneous sensory recovery is often excellent. (T.T. Nyame, A. Pathak, S. G. Talbot, 2014).

Purpose. This article reports on the Abbé flap for correction of mild tightness of the corrected cleft lip and nose deformity.

Patients and methods. 12 patients with a moderately tight lip deformity, from 18 to 25 years old, underwent this procedure. 9 had a unilateral deformity and 3 a bilateral deformity. The flap, which was taken from the central portion of the lower lip vermilion, was designed to repair the vermilion tubercle and the Cupid's bow. It was inserted into the center of the upper lip and the pedicle was divided 1 week after operation.

Technique. The Abbe flaps in this series were taken from the middle of the lower lip to replace a portion of the upper lip. Lip height to the nose or to the labiomental fold was assessed at the preoperative visit so that postoperative lip height could be correlated to the pre-existing anatomy (Fig. 1).

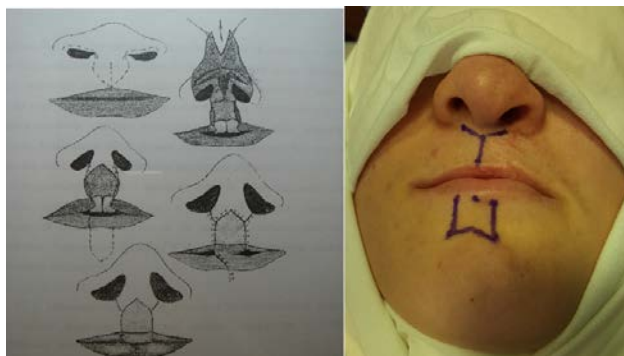


Fig. 1. The Abbe flaps were taken from the middle of the lower lip to replace a portion of the upper lip

The surgery involved the following consideration:

- All flaps originating from the lower lip and moved to the upper lip were arterially based laterally on the same side as the upper-lip defect;
- Abbe flaps for upper-lip replacement have always made the full height of the upper lip regardless of the amount of skin being replaced;
- The flap was always cut through on the non pedicled side first to locate the position of the artery in relation to the muscle and the vermilion cutaneous border;
- The vermilion was cut through on the pedicled side for 3 to 4 mm to line up the flap vermilion cutaneous border with the recipient vermilion cutaneous border (Fig. 2, 3).

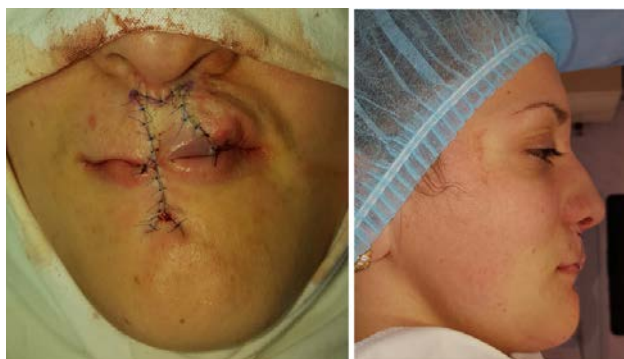

Fig. 2. Flap originating from the lower lip and moved to the upper lip were arterially based laterally on the same side as the upper-lip defect

All patients were placed on a clear liquid diet for one day, a pureed diet for two days, and then onwards normal diet. Tooth brushing was encouraged. Internal prostheses were always removed. In the office, 2,5 to 3 week after the reconstruction, the pedicle was injected with 1 to 2 ml lidocaine with epinephrine 1: 200000. After 10 min, the flap was divided with a No. 10 blade and inset. Mucosal tissue was undermined for closure; however, no significant mucosal adjustments were made. Resorbable sutures were placed in the oral mucosa.

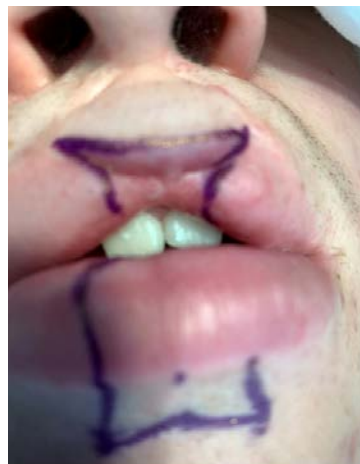

Fig. 3. Abbe flaps for upper-lip replacement have always made the full height of the upper lip regardless of the amount of skin being replaced; lower-lip replacement flaps were boxed (not triangular) and tailored at any level necessary

Discussion. Reconstruction of the lip for defects from, congenital, post-traumatic, and, rarely, infectious processes has been described for more than 200 years [16, 17]. Lip defects can be classified as partial defects that involve only skin or mucosa or they can be classified as full-thickness defects involving skin and muscle, with or without mucosal involvement [18–20]. Lip defects are also classified by location. Defects can be limited to the cutaneous lip or vermilion or involve the both. Upper lip defects can further be divided into those that involve the philtrum, medial lip, or lateral upper lip. Lower lip defects can also be divided into central or lateral, with or without commissural involvement. The size of the defects is also a helpful means of defining the lip defects. Four categories are commonly considered: one third or less of the lip, one third to two thirds of the lip, more than two thirds of the lip, and defects that result in total loss of one lip in combination with defects in the other lip. Microsurgical techniques have greatly enhanced our ability to restore large parcels of tissue in the head and neck, and the lips and perioral region are no exception. Microsurgical techniques are particularly valuable when local tissues are insufficient for adequate repair of large composite defects [19, 20].

The best reconstructions use as much local tissue as possible until free tissue transfer is inevitable, at which point the free flap is joined with the local tissues in as much functional manner as possible. Although, variety of techniques have been proposed for the reconstruction of 1/3rd to 2/3rd sized lip defects, none is ideal. It is obvious from the observations made in our present study that Abbe-Estlander flap provides a reliable reconstructive flap. This is supported by the fact that none of our patient

had dehiscence or necrosis of the flap. Flanagan [21] used a narrow full-thickness free graft from the lower lip to the upper lip for correction of a flat upper lip. Mild superficial necrosis occurred in all his cases. Multiple functional and aesthetic criteria were used to assess the versatility of Abbe-Estlander flap.

The functional criteria were evaluation of mouth opening, presence or absence of lip competence, presence or absence of symmetrical lip movements and the presence or absence of normal speech. The key to optimal restoration of lip function is the reconstitution of the orbicularis oris muscle with its reinnervation [22, 23]. The extensive review of literature implies that a two stage procedures is required for restoring adequate mouth opening, but the same was accomplished in our study with single stage alone. Only one patient required a second stage (cheiloplasty) to get adequate mouth opening and enhance oral commissural appearance. Rolda et al., [24] restored the mouth competence and symmetry with a single stage procedure. They did not encounter microstomia in any patient. In literature the major disadvantage of abbe-estlander flaps is microstomia [25]. In this study, only one patient suffered from the same. None of patients had persistent speech problems and lip incompetence at three months postoperative.

These findings are in consistent with the finding of Zhai et al., [22]. The aesthetic criteria were presence or absence of symmetrical mouth opening, presence or absence of hypertrophic scar and the presence or absence of an aesthetic oral commissure. The best way to achieve a good aesthetic outcome is to use identical or similar tissue for reconstruction of defects [22]. As the Abbe-Estlander flap imports identical tissue for reconstruction, it fulfils the requirements of a good aesthetic outcome. Our study also had good aesthetic results in terms of symmetrical mouth opening and oral competence. Although one patient had a hypertrophic scar but the overall results were satisfactory with regard to cosmetic appearance. Our result is in consistent with the study of Motamedi [26], Bennis and Vegter et al., [27]. This procedure was less mutilating, less stressful and well suited for elderly patients whose general health was not optimal [26].

This flap may represent an alternative to microvascular reconstruction for defects involving up to 1/3rd to 2/3rd of the lip. Because of its rich vascularity [28, 29]. It is an ideal flap for the irradiated patient and those that have undergone neck dissection. Although, the major limiting factor is its size, it was successfully used for reconstructing 1/3rd to 2/3rd of lip defects in this study. Zide MF and Fuselier C [30], Yamauchi et al., [31] and Ali Ebrahimi et al., [32] also stated that Abbe flaps for lower-lip defects typically fill defects comprising 30% to 80% of

the total lip width. The Abbe flap technique has several advantages over other techniques such as: 1) It is safe and a reliable flap with an excellent blood supply that affords versatility in flap design even after bilateral neck dissection. 2) Simple to perform, and provides functionally and aesthetically pleasing result for reconstruction of 1/3rd to 2/3rd sized lip defects. 3) Safer and less mutilating for elderly patients with multiple morbidities, who represent a poorer operative risk. 4) Change of appearance is very minimal and very acceptable for the patients. 5) Improves functional results in terms of speech and symmetrical lip movements.

Results. (Fig. 4).

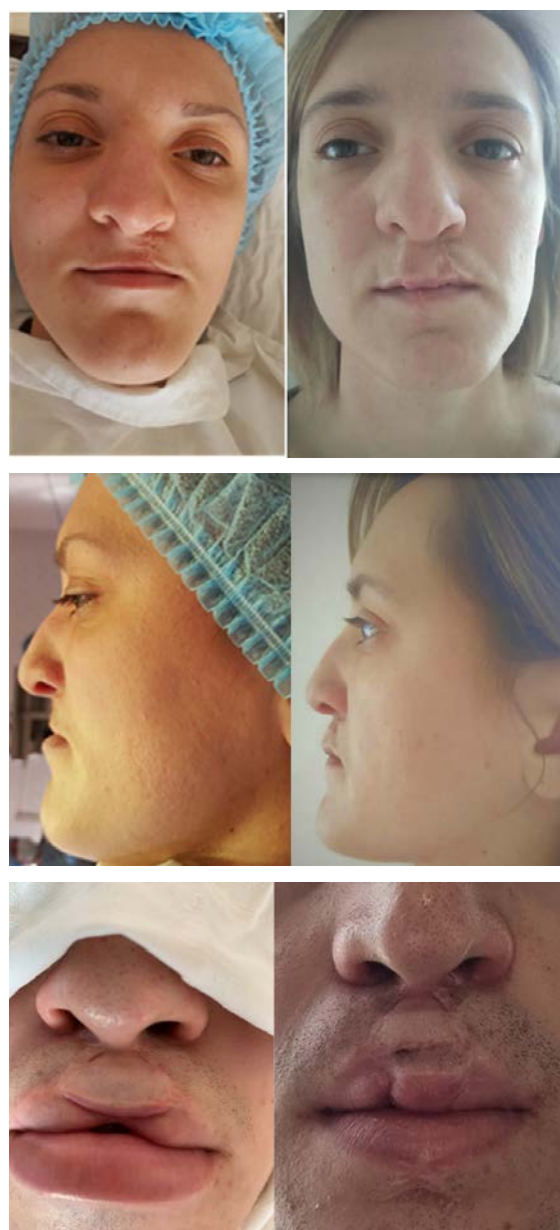

Fig. 4. Each patient showed a more natural contour of the vermilion tubercle and the Cupid's bow. The scarring of the donor site was inconspicuous

Conclusions. Use of modified Abbé flap to reconstruct the contour of the vermilion tubercle and the Cupid's bow makes the upper lip look more natural. Even though maxillofacial reconstructive surgery has undergone a sea change from the use of traditional flaps to the present day microsurgical free tissue transfer, Abbe still holds in a position as a reliable method of lip reconstruction. Our experience with 12 patients with Abbe flap reconstruction has been encouraging and the result obtained was extremely satisfactory. The Abbe flap procedure gives satisfactory results in the secondary reconstruction of deficient upper lips in persons with cleft lip. The width of the flap must be 1 to 1.5 cm, the length should be sufficient to reach the base of the columella, the shape triangular or shield-shaped, and the position medial. The tissue transfer from the lower lip creates philtral dimple and philtral ridges. Disadvantages of the Abbe flap include patient discomfort and the need for multiple procedures.

References:

1. Abbe, R. (1968). A new plastic operation for the relief of deformity due to double harelip (reprint from: Medical Record 1898;53:477) *Plast Reconstr Surg*, 42, 481–3.
2. Burgett, G.C., & Menick, F.J. (1986). Aesthetic restoration of one half of the upper lip. *Plast Reconstr Surg*, 78, 583–93.
3. Baumann, D., & Robb G. (2008). Lip reconstruction. *Semin Plast Surg*, 13(2), 269–80 doi: 10.1055/s-0028-1095886
4. McGregor, I.A. (1963). The Abbe Flap: its use in single and double lip clefts. *Br J Plast Surg*, 16, 46–59.
5. Gillies, H.D., & Millard, D.R. (1957). *The Principles and Art of Plastic Surgery*. Boston, MA: Little, Brown.
6. Theodore, T. Nyame, Abraham Pathak, & Simon G. Talbot. (2014). The Abbe Flap for Upper Lip Reconstruction. *Eplasty*, 27, 14, ic30.
7. John, C. Koshy, Warren, A. Ellsworth, Safa, E. Sharabi, Daniel, A Hatef, Larry, & H Hollier jr Samuel Stal. (2010). Bilateral cleft lip revisions: the Abbe flap *Plast. Reconstr. Surg*, 126(1), 221-227.
8. Lo, L.J., Kane, A.A., & Chen, Y.R. (2003). Simultaneous reconstruction of the secondary bilateral cleft lip and nasal deformity: Abbé flap revisited. *Plast Reconstr Surg*, 112(5), 1219-27.
9. Bagatin, M., & Most, S.P. (2002). The Abbe flap in secondary cleft lip repair *Arch Facial Plast Surg*, 4(3), 194-7.
10. Ma, H., Zhang, N., Yin, N., & Guo, B. (2019). Application of a Layered Muscle Flap Technique for the Reconstruction of the Cupid's Bow and Vermilion in the Repair of Secondary Cleft Lip Deformities. *J Craniofac Surg*, 30(8), 723-727.
11. Takato, T., Yonehara, Y., Susami, T., & Uoshima, K. (1996). Modification of the Abbé flap for reconstruction of the vermilion tubercle and Cupid's bow in cleft lip patients. *J Oral Maxillofac Surg*, 54(3), 256-61; discussion 261-2.
12. Ishigaki, T., & Udagawa, A. (2021). Use of the Modified Unilateral Cleft Lip Repair Technique to Establish a Cupid's Bow With a Natural Structure. *Cleft Palate Craniofac J.*, 58(6), 791-795 doi: 10.1177/1055665620962364.
13. Li, L., Xie, F., Ma, T., & Zhang, Z. (2015). Reconstruction of Philtrum Using Partial Splitting and Folding of Orbicularis Oris Muscle in Secondary Unilateral Cleft Lip. *Plast Reconstr Surg*, 136(6), 1274-1278 doi: 10.1097/PRS.0000000000001795.
14. Sarrami, S.M., Skochdopole, A.J., Ferry, A.M., Buchanan, E.P., Hollier L.H. Jr, & Dempsey RF. (2021). Revisional Techniques for Secondary Cleft Lip Deformities. *Semin Plast Surg*, 35(2), 65-71 doi: 10.1055/s-0041-1728673.
15. Boson, A.L., Boukavalas, S., Hays, J.P., Hammel, J.A., Cole, E.L., & Wagner, R.F.Jr. (2021). Upper Lip Anatomy, Mechanics of Local Flaps, and Considerations for Reconstruction. *Cutis*, 107(3), 144-148 doi: 10.12788/cutis.0205
16. Williams, E.F., & Hove, C.R. (2002). *Facial Plastic and Reconstructive Surgery*. (2d ed.) New York: Thieme; Lip Reconstruction. In Papel, Nachlas, Sykes, et al., editors; pp. 634–45.
17. Cupp, C.L., & Larrabee, W.F. (1993). Reconstruction of the lips. *Operative Techniques in Otolaryngology-Head and Neck Surgery*; 4(1):46–53 [http://dx.doi.org/10.1016/S1043-1810\(10\)80106-X](http://dx.doi.org/10.1016/S1043-1810(10)80106-X).
18. Constantinidis, J., Federspil, P., & Iro, H. (1999). Functional and aesthetic objectives in the reconstruction of lip defects. *Facial Plast Surg*, 15(4), 337–49 doi: 10.1055/s-2008-1064335.
19. Mazzola, R.F., & Lupo, G. (1984). Evolving concepts in lip reconstruction. *Clin Plast Surg*, 11(4), 583–617.
20. Wilson, J.S., & Walker, E.P. Reconstruction of the lower lip. *Head Neck Surg*. 1981;4(1):29–44 doi:10.1002/HED.2890040108.
21. Flanagan, W.S. (1956). Free composite grafts from lower to upper lip. *Plast Reconstr Surg (1946)*, 17(5), 376–80 doi: 10.1097/00006534-195605000-00005.
22. Zhai, Q.K., Tan, X.X., Jin, Z.L., & et al. (2012). Reconstruction for defects of the lower lip after tumor ablation. *J Craniofac Surg*, 23(2), 552–55.
23. Rea, J.L., Davis, W.E., & Rittenhouse, L.K. (1978). Reinnervation of an Abbe-Estlander and a Gillies fan flap of the lower lip: electromyographic comparison. *Arch Otolaryngol*, 104(5), 294–95. doi: 10.1001/archotol.1978.00790050060014.
24. Roldán, J.C., Teschke, M., Fritzer, E., & et al. (2007). Reconstruction of the lower lip: rationale to preserve the aesthetic units of the face. *Plastic and Reconstructive Surgery*, 120(5), 1231–39 doi: 10.1097/01.prs.0000279147.73273.e9.

25. Kronic, A.L., Weitzul, S., & Taylor, R.S. (2005). Advanced reconstructive techniques for the lip and perioral area. *Dermatol Clin*, 23(1), 43–53 doi: 10.1016/j.det.2004.08.009.
26. Motamedi, M.H., & Behnia, H. (1999). Experience with regional flaps in the comprehensive treatment of maxillofacial soft-tissue injuries in war victims. *J Craniomaxillofac Surg*, 27:256–65 doi: 10.1016/s1010-5182(99)80038-9.
27. Vegter, F., Mulder, J.W., Hage, J.J. (1998). The lip index: an anthropometric tool to evaluate objectively the result of the Abbe flap procedure. *Ann Plast Surg*, 41(2), 166–70 doi: 10.1097/00000637-199808000-00009.
28. Nakajima, H., Imanishi, N., & Aiso, S. (2002). Facial artery in the upper lip and nose: anatomy and a clinical application. *PlastReconstr Surg*, 109(3), 855–61. doi: 10.1097/00006534-200203000-00003.
29. Schulte, D.L., Sherris, D.A., & Kasperbauer, J.L. (2001). The anatomical basis of the Abbé flap. *Laryngoscope*, 111(3), 382–86 doi: 10.1097/00005537-200103000-00004.
30. Zide, M.F., & Fuselier, C. (2001). The partial-thickness cross-lip flap for correction of postoncologic surgical defects. *J Oral Maxillofac Surg*, 59(10), 1147–53 doi: 10.1053/joms.2001.26715.
31. Yamauchi, M., Yotsuyanagi, T., & Ezoe, K. (2009). Estlander flap combined with an extended upper lip flap technique for large defects of lower lip with oral commissure. *J PlastReconstrAesthet Surg*, 62(8):997–1003 doi: 10.1016/j.bjps.2008.02.013.
32. Ali Ebrahimi, Gholam Reza Maghsoudnia, & Arshadip A. A. (2011). Prospective comparative study of lower lip defects reconstruction with different local flaps. *J CraniofacSurg*, 22, 2255–59 doi: 10.1097/SCS.0b013e318232786d.