

ARTICLES  
(/ARTICLES)

CASES (/CASES)

COURSES  
(/COURSES)

PROFILE  
(/USERS/YULIIA-  
SOLODOVNIKOVA)



Introduction to oncology  
staging CT  
Sally Ayesa



(<https://radiopaedia.org/courses/featured-video>)

# Wilson disease



Case contributed by Yuliia Solodovnikova (/users/yuliia-solodovnikova)  
Diagnosis certain

Edit case

Share (/cases/wilson-disease-11)

Add to

## × Citation, DOI, disclosures and case data



(/)

MENU

SEARCH

### Citation:

Solodovnikova Y, Wilson disease. Case study, Radiopaedia.org (Accessed on 13 Jun 2023) <https://doi.org/10.53347/rID-163863>

### DOI:

<https://doi.org/10.53347/rID-163863> (<https://doi.org/10.53347/rID-163863>)

### Permalink:

<https://radiopaedia.org/cases/163863>  
(<https://radiopaedia.org/cases/163863>)

### rID:

163863

### Disclosures:

At the time the case was submitted for publication Yuliia Solodovnikova had no financial relationships to ineligible companies (/articles/disclosures) to disclose.

View Yuliia Solodovnikova's current disclosures (</users/yuliia-solodovnikova>)



**Case created:**

4 Mar 2023

**Case published:**

17 Mar 2023

**Revisions:**

12 times, by 3 contributors - see full revision history and disclosures (</cases/wilson-disease-11/revisions>)

**Systems:**

Central Nervous System (</articles/section/all/central-nervous-system>)

**Quiz mode:**

Included

---

**Presentation**

Initially presented with a tremor in upper extremities, predominantly left-sided. In several months she developed head and low extremities tremor, as well as whole body rigidity, mask-like face, and inability to smile.

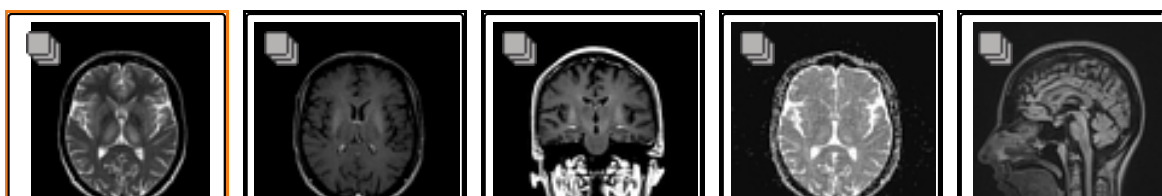**Patient Data**

**Age:** 30 years

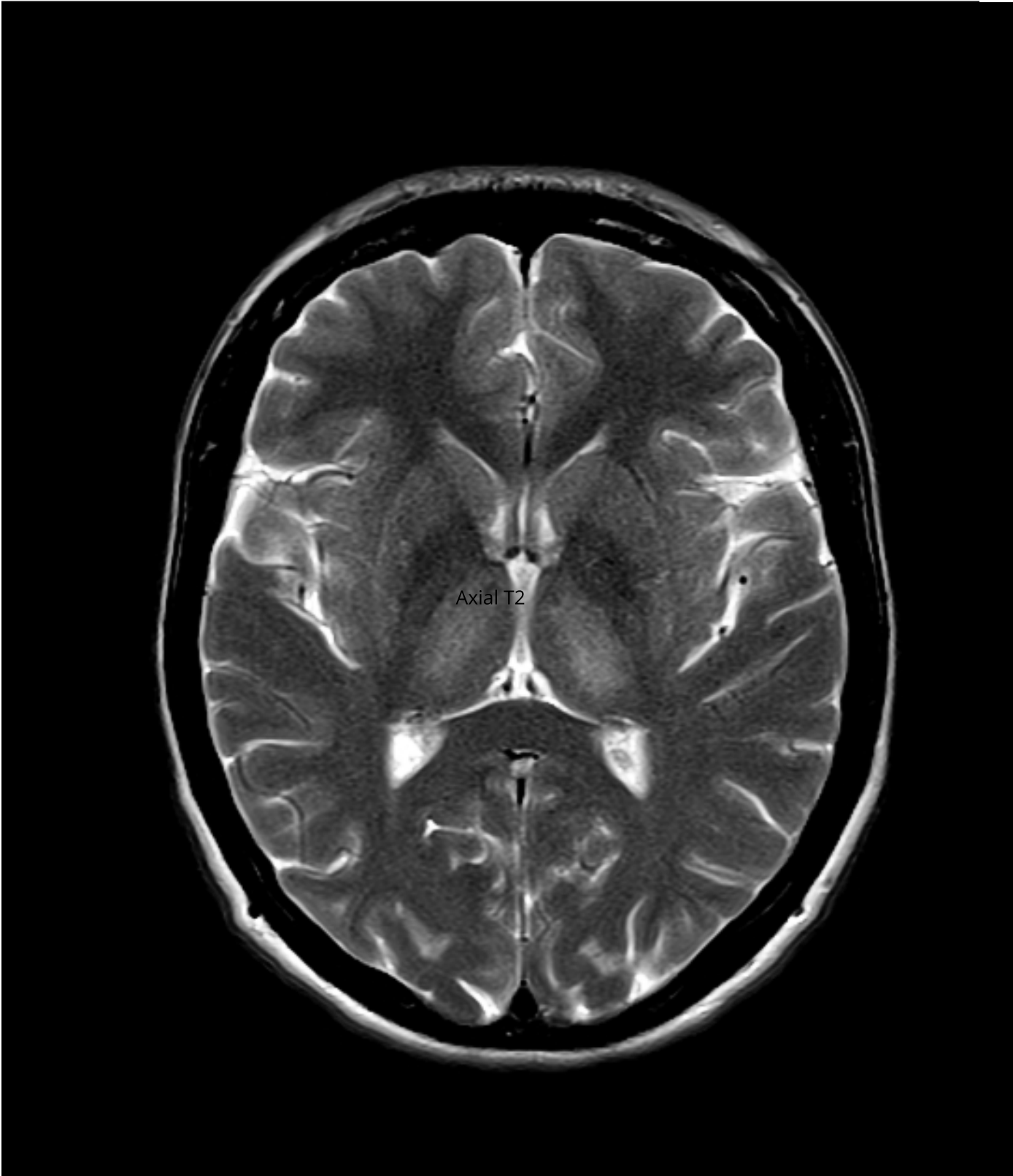
**Gender:** Female

**MRI**

(</cases/163863/studies/133380>)



<p>Axial T2</p> <p>(/images/61466 712? case_id=163863 )</p>	<p>Axial T1 C+</p> <p>(/images/61466 739? case_id=163863 )</p>	<p>Coronal T1 C+</p> <p>(/images/61466 763? case_id=163863 )</p>	<p>Axial ADC</p> <p>(/images/61575 256? case_id=163863 )</p>	<p>Sagittal FLAIR</p> <p>(/images/61575 349? case_id=163863 )</p>
---	--	--	--	---



---

+ **1 case question available**

## Case Discussion



Laboratory testing revealed reduced serum copper at 10.3  $\mu\text{mol/L}$  (normal range 12.9-24.4  $\mu\text{mol/L}$ ) and reduced serum caeruloplasmin at 0.12 g/L (normal range 0.23-0.45 g/L).

An ophthalmologic examination was performed and showed Kayser-Fleisher rings in the cornea.

This case demonstrates the typical CNS manifestations of Wilson disease (hepatolenticular degeneration) and the role of imaging in making the correct diagnosis.

---

+ **3 public playlists include this case**

### × **Related Radiopaedia articles**

- [Double panda sign \(/articles/double-panda-sign\)](/articles/double-panda-sign)
- [Wilson disease \(/articles/wilson-disease-2\)](/articles/wilson-disease-2)
- [Wilson disease \(CNS manifestations\) \(/articles/wilson-disease-cns-manifestations-1\)](/articles/wilson-disease-cns-manifestations-1)

### × **Promoted articles** (advertising)

Quieting a Rib-Framed Honeycomb Core Sandwich Panel for a Rotorcraft Roof

Hambric, Stephen A. et al., *Journal of the American Helicopter Society*

Wind Tunnel Results Showing Rotor Vibratory Loads Reduction Using Higher Harmonic Blade Pitch

Hammond, C. E. et al., Journal of the American Helicopter Society, 1983

A Simplified Dynamic Model of the T700 Turboshaft Engine

Ahmet Duyar et al., Journal of the American Helicopter Society

Video Series: Anemia in Chronic Kidney Disease in Primary Care

Stephen Brunton et al, Clinical Diabetes

CME Series: Anemia in Chronic Kidney Disease in Primary Care

Stephen Brunton et al, Clinical Diabetes

Clinical Diabetes Video Series: Anemia in CKD in Primary Care

Stephen Brunton et al, Clinical Diabetes



Powered by **TREND MD**

I consent to the use of Google Analytics and related cookies across the TrendMD network (widget, website, blog). [Learn more \(https://www.trendmd.com/google-analytics#\)](https://www.trendmd.com/google-analytics#)

Yes

No

### Case completeness



98% complete. Why not add:

- Diagnostic certainty
- Patient's presentation
- Patient data
- Study findings
- Case discussion
- MRI image sequences

Modality

Related articles

A couple of questions and answers



## How to use cases

You can use Radiopaedia cases in a variety of ways to help you learn and teach.

- Add cases to playlists (</articles/playlists>)
- Share cases with the diagnosis hidden (</articles/sharing-cases-and-playlists>)
- Use images in presentations (</articles/using-and-attributing-images-from-radiopaedia>)
- Use them in multiple choice question (</articles/image-interpretation-questions>)

Creating your own cases is easy.

- Case creation learning pathway (</courses/help-creating-cases>)

ADVERTISEMENT: Supporters see fewer/no ads

## Articles (/articles/section/all/all)

### By Section:

Anatomy

(/articles/section/anatomy/all)

Approach

(/articles/section/approach/all)

Artificial Intelligence

(/articles/section/artificial-intelligence/all)

Classifications

(/articles/section/classifications/all)

Gamuts

(/articles/section/gamuts/all)

Imaging Technology

(/articles/section/physics/all)

Interventional Radiology

(/articles/section/interventional-radiology/all)

Mnemonics

(/articles/section/mnemonics/all)

Pathology

(/articles/section/pathology/all)

Radiography

(/articles/section/radiography/all)

Signs (/articles/section/signs/all)

Staging

(/articles/section/staging/all)

## Cases (/cases)



Breast (/cases/system/breast)

Cardiac (/cases/system/cardiac)

Central Nervous System

(/cases/system/central-nervous-system)

Chest (/cases/system/chest)

Forensic (/cases/system/forensic)

Gastrointestinal

(/cases/system/gastrointestinal)

Gynaecology

(/cases/system/gynaecology)

Haematology

(/cases/system/haematology)

Head & Neck

(/cases/system/head-neck)

Hepatobiliary

(/cases/system/hepatobiliary)

Interventional

(/cases/system/interventional)

Musculoskeletal

(/cases/system/musculoskeletal)

Obstetrics

(/cases/system/obstetrics)

Oncology

(/cases/system/oncology)

Paediatrics

(/cases/system/paediatrics)

Syndromes  
(/articles/section/syndromes/all)

## By System:

Breast (/articles/section/all/breast)

Cardiac  
(/articles/section/all/cardiac)

Central Nervous System  
(/articles/section/all/central-nervous-system)

Chest (/articles/section/all/chest)

Forensic  
(/articles/section/all/forensic)

Gastrointestinal  
(/articles/section/all/gastrointestinal)

Gynaecology  
(/articles/section/all/gynaecology)

Haematology  
(/articles/section/all/haematology)

Head & Neck  
(/articles/section/all/head-neck)

Hepatobiliary  
(/articles/section/all/hepatobiliary)

Interventional  
(/articles/section/all/interventional)

Musculoskeletal  
(/articles/section/all/musculoskeletal)

Obstetrics  
(/articles/section/all/obstetrics)

Spine (/cases/system/spine)

Trauma (/cases/system/trauma)

Urogenital  
(/cases/system/urogenital)



Vascular (/cases/system/vascular)

Not Applicable  
(/cases/system/not-applicable)

## Radiopaedia.org (/)

**ABOUT (/ABOUT)**

**BLOG (/BLOG)**

**FEATURE SPONSOR (/FEATURE-SPONSOR)**

**DONATE (/SUPPORTERS)**

Editors (/editors)

Expert advisers (/expert-advisers)

Help (/articles/style-guide-and-help)

 Facebook  
(<https://www.facebook.com/Radiopae>)

 Twitter  
(<https://twitter.com/Radiopaedia>)

 Newsletter  
(<http://eepurl.com/ltOWf>)



Oncology

(/articles/section/all/oncology)

Paediatrics

(/articles/section/all/paediatrics)

Spine (/articles/section/all/spine)

Trauma

(/articles/section/all/trauma)

Urogenital

(/articles/section/all/urogenital)

Vascular

(/articles/section/all/vascular)



---

[Contact Us \(/contact\)](/contact)

[Terms of Use \(/terms\)](/terms)

[Privacy Policy \(/terms#privacy-policy\)](/terms#privacy-policy)

[Licensing \(/licence\)](/licence)

[Sponsorship \(/sponsorship\)](/sponsorship)

[Developers \(/developers\)](/developers)

© 2005–2023 Radiopaedia.org