

Запорізький медичний журнал



Том 24, № 6(135), листопад – грудень 2022 р.

<http://zmj.zsmu.edu.ua>

Науково-практичний журнал
Запорізького державного медичного університету

ISSN (print): 2306-4145. ISSN (online): 2310-1210

Видається з вересня 1999 р. Періодичність – 1 раз на два місяці.
Свідоцтво про реєстрацію KB № 25086-15026ПР від 31.12.2021 р.
Передплатний індекс – 90253

Атестований як наукове фахове видання України категорії «А»,
в якому можуть публікуватися результати дисертаційних робіт
доктора філософії, доктора та кандидата наук

Галузь знань – охорона здоров'я (22);
спеціальності: медицина – 222, педіатрія – 228, стоматологія – 221,
фармація, промислова фармація – 226
(наказ МОН України № 1301 від 15.10.2019 р.)

Журнал включений до WEB OF SCIENCE[®], Ulrich's Periodicals
Directory (США), WorldCat (США), The National Center
for Biotechnology Information (США), National Library of Medicine (США),
WORLDWIDE ELIBRARY (США), DOAJ, ROAD (Франція), Google Scholar
(Академія) та інших міжнародних наукометричних баз даних

Статті рецензуються за процедурою Double-blind.
Ліцензія Creative Commons

Рекомендовано до друку Вченою радою ЗДМУ,
протокол № 2 від 26.10.2022 р.
Підписано до друку 02.11.2022 р.

Редакція:

Літературний редактор О. С. Савеленко
Технічний редактор Ю. В. Полупан

Адреса редакції та видавця:



ЗДМУ, пр. Маяковського, 26,
м. Запоріжжя, Україна, 69035



med.jur@zsmu.zp.ua



<http://zmj.zsmu.edu.ua>

Головний редактор

професор Ю. М. Колесник (Запоріжжя)

Заступник головного редактора

професор В. А. Візір (Запоріжжя)

Відповідальний секретар

професор В. В. Сиволап (Запоріжжя)

Редакційна колегія

проф. А.В. Абрамов (Запоріжжя)
акад. НАМН України, проф. М.А. Андрейчин (Тернопіль)
проф. І.Ф. Беленічев (Запоріжжя)
проф. І.М. Бондаренко (Дніпро)
проф. Маргус Війгімаа (Таллінн, Естонія)
проф. М.Л. Головаха (Запоріжжя)
проф. М.М. Долженко (Київ)
проф. Н.Г. Завгородня (Запоріжжя)
акад. НАМН України, проф. В.М. Запорожан (Одеса)
проф. Луціш Запрутко (Познань, Польща)
проф. Марек Зентек (Вроцлав, Польща)
проф. А.Г. Каплашенко (Запоріжжя)
проф. В.М. Клименко (Запоріжжя)
акад. НАМН України, проф. В.М. Коваленко (Київ)
проф. С.М. Коваль (Харків)
проф. О.А. Козьолкін (Запоріжжя)
проф. М.О. Корж (Харків)
чл.-кор. НАН, акад. НАМН України О.В. Коркушко (Київ)
проф. Г.О. Леженко (Запоріжжя)
чл.-кор. НАМН України, проф. В.М. Лісовий (Харків)
проф. І.А. Мазур (Запоріжжя)
проф. Кшиштоф Наркевич (Гданськ, Польща)
проф. С.М. Недельська (Запоріжжя)
чл.-кор. НАМН України, проф. В.З. Нетяженко (Київ)
акад. НАМН, чл.-кор. НАН України,
проф. О.С. Никоненко (Запоріжжя)
проф. Петер Нільссон (Мальме, Швеція)
проф. Дженнаро Пагано (Неаполь, Італія)
проф. О.І. Панасенко (Запоріжжя)
чл.-кор. НАМН України, проф. Т.О. Перцева (Дніпро)
проф. Ю.М. Степанов (Дніпро)
проф. В.Д. Сиволап (Запоріжжя)
проф. В.О. Туманський (Запоріжжя)
проф. Генрієтта Фаркаш (Будапешт, Угорщина)
акад. НАМН України, проф. Ю.І. Фещенко (Київ)
проф. Свапандип Сингх Чимні (Амрітсар, Індія)
проф. Яцек Шепетовський (Вроцлав, Польща)

Scientific Medical Journal. Publisher Zaporizhzhia State Medical University

Zaporozhye Medical Journal (established in September 1999) is an multidisciplinary publication for exchange of scientific and clinical information, publishing original research and news encompassing all aspects of medicine and is published 6 times a year. The journal publishes articles, original papers, reviews and book reviews of general interest in medicine. Submit papers are peer-reviewed. License Creative Commons

Indexing: Web of Science Core Collection, Emerging Sources Citation Index, Ulrich's Periodicals Directory (USA), WorldCat (USA), ISSN (France), Index Copernicus (Poland), BASE - Bielefeld Academic Search Engine (Germany), getCITED (USA), UIF (Universal Impact Factor), DRJI (Sweden), JournalTOCs, CiteFactor (USA/Canada), PILA – Publishers International Linking Association, Inc, CROSSREF (USA), The National Library of Medicine (USA), The National Center for Biotechnology Information, Research Bible (Japan), SIS (Scientific Indexing Services) (USA), Hinari, DOAJ (Directory of Open Access Journals), Worldwide Science Education Library (USA), ROAD, Google Scholar

Editorial office: Maiakovskiy Avenue, 26, Zaporizhzhia, 69035, UKRAINE. **E-mail:** med.jur@zsmu.zp.ua

Editor-in-Chief

Yu. M. Kolesnyk
(Zaporizhzhia, Ukraine)

Deputy Editor-in-Chief

V. A. Vizir
(Zaporizhzhia, Ukraine)

Executive secretary

V. V. Syvolap
(Zaporizhzhia, Ukraine)

Editorial Board

A.V. Abramov (Zaporizhzhia, Ukraine)
M.A. Andreichyn (Ternopil, Ukraine)
I.F. Bielenichev (Zaporizhzhia, Ukraine)
I.M. Bondarenko (Dnipro, Ukraine)
Swapandeeep Singh Chimni (Amritsar, India)
M.M. Dolzhenko (Kyiv, Ukraine)
Henriette Farkas (Budapest, Hungary)
Yu.I. Feshchenko (Kyiv, Ukraine)
M.L. Holovakha (Zaporizhzhia, Ukraine)
A.H. Kaplaushenko (Zaporizhzhia, Ukraine)
V.M. Klymenko (Zaporizhzhia, Ukraine)
O.V. Korkushko (Kyiv, Ukraine)
M.O. Korzh (Kharkiv, Ukraine)
S.M. Koval (Kharkiv, Ukraine)
V.M. Kovalenko (Kyiv, Ukraine)
O.A. Koziolkin (Zaporizhzhia, Ukraine)
H.O. Lezhenko (Zaporizhzhia, Ukraine)
V.M. Lisovyi (Kharkiv, Ukraine)

I.A. Mazur (Zaporizhzhia, Ukraine)
Krzysztof Narkiewicz (Gdansk, Poland)
S.M. Nedelska (Zaporizhzhia, Ukraine)
V.Z. Netiazhenko (Kyiv, Ukraine)
Peter M. Nilsson (Malmö, Sweden)
O.S. Nykonenko (Zaporizhzhia, Ukraine)
Gennaro Pagano (Naple, Italy)
O.I. Panasenko (Zaporizhzhia, Ukraine)
T.O. Pertseva (Dnipro, Ukraine)
Yu.M. Stepanov (Dnipro, Ukraine)
V.D. Syvolap (Zaporizhzhia, Ukraine)
Jacek Szepietowski (Wroclaw, Poland)
V.O. Tumanskyi (Zaporizhzhia, Ukraine)
Margus Viigimaa (Tallinn, Estonia)
V.M. Zaporozhan (Odesa, Ukraine)
Lucjusz Zaprutko (Poznan, Poland)
N.H. Zavorodnia (Zaporizhzhia, Ukraine)
Marek Ziętek (Wroclaw, Poland)

A clinical case of gunshot shrapnel penetrating wound of the chest with injury to the inferior vena cava with migration of a foreign body along the blood stream

V. I. Tsybaliuk^{1,A,F}, I. A. Lurin^{1,6,A,E,F}, V. V. Makarov^{1,2,3,A,B,C}, V. V. Nehoduiko^{1,2,3,A,B,C,F},
O. V. Buchnieva^{1,5,B}, S. V. Tertyshnyi^{1,4,A,B,D,E}, Yu. V. Bunin^{1,3,C,E}

¹National Academy of Medical Sciences of Ukraine, Kyiv, ²Kharkiv National Medical University, Ukraine, ³Military Medical Clinical Center of the Northern Region of the Command of Medical Forces, Armed Forces of Ukraine, Kharkiv, ⁴Military Medical Clinical Center of the Southern Region of the Command of Medical Forces, Armed Forces of Ukraine, Odesa, ⁵SI "Zaitsev V. T. Institute of General and Emergency Surgery of the National Academy of Medical Sciences of Ukraine", Kharkiv, ⁶State Scientific Institution "Scientific and Practical Center of Preventive and Clinical Medicine" of the State Administration of Affairs, Kyiv, Ukraine

A – research concept and design; B – collection and/or assembly of data; C – data analysis and interpretation; D – writing the article; E – critical revision of the article; F – final approval of the article

Key words:
gunshot wounds,
inferior vena cava,
bleeding.

Zaporozhye
medical journal
2022; 24 (6), 760-764

*E-mail:
drug2008@ukr.net

Damage to the major vessels in a retroperitoneal trauma belongs to the category of the most difficult, including damage to the inferior vena cava.

The aim of the work is to demonstrate the features of clinical manifestations and tactical solutions of a gunshot fragment blind wound of the inferior vena cava with the migration of a foreign body along the blood stream.

Materials and methods. A case of a gunshot fragment wound of the inferior vena cava with migration of the foreign body along the blood stream was studied. An injured person underwent sCT with and without contrast, FAST protocol, general blood test, biochemical blood test, CBV was determined using the formula of Moore, hourly diuresis was measured.

Results. The patient was operated on for vital signs, the condition of the injured person was stabilized. During the revision of the abdominal cavity and paranephric tissue, no foreign body was identified. In the immediate postoperative period, the injured person underwent chest and abdominal CT, according to the data of that, a metal fragment was identified, which migrated along the inferior vena cava to the point of connection with the right atrium.

The injured man was operated on at another specialized facility, where the foreign body was removed using a surgical magnetic tool.

Conclusions. Fire damage to the inferior vena cava is classically accompanied by a severe general condition, massive blood loss, which requires urgent surgical interventions. Multi-component preoperative preparation, a clearly established diagnostic plan, a multidisciplinary approach based on the example of our clinical case allow saving life even in the most complex cases.

Ключові слова:
вогнепальні
поранення, нижня
порожниста вена,
кровотеча.

Запорізький
медичний журнал.
2022. Т. 24, № 6(135).
С. 760-764

Клінічний випадок вогнепального осколкового проникного поранення грудної клітки з ушкодженням нижньої порожнистої вени з міграцією стороннього тіла по кровеносному руслу

V. I. Tsybaliuk, I. A. Lurin, V. V. Makarov, V. V. Nehoduiko,
O. V. Buchnieva, S. V. Tertyshnyi, Yu. V. Bunin

Пошкодження магістральних судин заочервеної травми належить до категорії найскладніших, зокрема й пошкодження нижньої порожнистої вени.

Мета роботи – демонстрація особливостей клінічних проявів і тактичних рішень вогнепального осколкового сліпого поранення нижньої порожнистої вени з міграцією стороннього тіла за током крові.

Матеріали та методи. Вивчили випадок вогнепального осколкового поранення нижньої порожнистої вени з міграцією стороннього тіла за током крові. Пораненому виконали СКТ із контрастуванням та без нього, FAST протокол, загальний і біохімічний аналізи крові, визначили ОЦК за допомогою формули Мура, погодинний діурез.

Результати. Здійснили оперативне втручання за життєвими показаннями, стан пораненого стабілізовано. Під час ревізії черевної порожнини та паранефральної клітковини стороннє тіло не ідентифіковано. В післяопераційному періоді відразу пораненому повторно виконали СКТ органів грудної клітки та черевної порожнини, у результаті ідентифіковано металевий осколок, що мігрував по нижній порожнистій вені до місця з'єднання з правим передсердям.

Пораненого прооперували в іншому спеціалізованому закладі, де видалили стороннє тіло за допомогою хірургічного магнітного інструменту.

Висновки. Вогнепальні пошкодження нижньої порожнистої вени зазвичай супроводжуються тяжким загальним станом, масивною крововтратою, що спричиняє здійснення термінових оперативних втручань. Багатокомпонентна передопераційна підготовка, чітко встановлений діагностичний план, мультидисциплінарний підхід на прикладі клінічного випадку, що описали, дають змогу зберегти життя навіть у таких найскладніших кейсах.

The changing nature of warfare and the use of personal protective equipment have a significant impact on the number and type of sanitary losses. During the local wars and armed conflicts of the last decades, the tactics of conducting hostilities have changed: missile and bomb strikes, raiding of the area are more often used, the conduct of motor vehicle or human convoys through enemy territory is considered as a type of operations accompanied by the sanitary losses from the enemy attack or detonations on mines, in connection with which the structure of combat surgical trauma has changed. In recent years, both types of explosive devices used in military conflicts and the nature of combat wounds from them have changed [1]. The use of mines, improvised explosive devices, and new types of heavy-energy weapons has become a characteristic feature of modern military conflicts. A change in the tactics of conducting an armed conflict with the transition from a maneuverable war to a remote character of fighting, the use of new-generation weapons with new ballistic characteristics, and new deadlines for delivering the wounded to a level of medical care has led to a change in the mechanism and severity of injuries [2].

In the authors' opinion, evacuation of wounded persons to a medical institution with available specialized surgical care from the line of contact with the enemy, the involvement (use) of a multi-component examination (chest and abdominal CT, abdominal CT angiography, ultrasound of the abdomen and retroperitoneal space, chest and abdominal cavity organs (OAC) RG, a multidisciplinary approach to treatment of a wounded person with a gunshot injury of the inferior vena cava, demonstrates practical feasibility, uniqueness and variety of injuries.

The paper demonstrates a diagnostic algorithm not only as an example of highly specialized surgical care for the wounded in the Navy, but also shows the high quality of medical care provided in the Armed Forces Navy. In our report, we present a clinical case of a wounded Sh., 35 years old, with the following diagnosis: combined gunshot wound of the head, chest, abdomen, upper and lower extremities from 06.10.2022. Penetrating wound of the left temporal area with a gunshot fracture of the left temporal bone of the inferior orbital wall, paraorbital hematoma on the left; conjunctival chemosis in the left eye. Thoracoabdominal wound on the right with damage to the middle and lower lobe of the right lung, diaphragm, retroperitoneal hematoma on the left with the presence of a foreign body (a metal fragment) in the left renal vein and its migration with the blood flow into the inferior vena cava. Hemopneumothorax on the right. Pneumomediastinum. Hydropericardium. Subcutaneous emphysema. Penetrating wound of the right shoulder with a gunshot fracture of the right humerus. Blunt injury to the right hip with a gunshot fracture of the greater trochanter of the right femur with a damage to the right femoral artery and the presence of a free foreign body in the pelvis (a metal fragment). Blunt injury to the penis body. Blunt and penetrating wounds of the soft tissues of the right forearm and hand, left thigh and both shins.

With continuous hostilities, the expediency of demonstrating the option of surgical treatment for wounded and injured with damages to the inferior vena cava remains at a high level, as it is one example of this type of damage treatment.

Statistical materials presented during previous military conflicts (in Vietnam 1964–1973, Afghanistan 1979–1989, the North Caucasus 1994–1996, 1999–2002, the US war in Afghanistan and Iraq 2001–2009) [3,4] differ according to the injury nature and the number of damaged anatomical structures, among which vascular damage is represented in the range of 2.7–8.0 % [5,6]. Such figures are due to the fact that the collection and generalization of information during the military conflict is significantly complicated. In our observations, it is further complicated by the fact that the term of the military conflict is still ongoing in Ukraine.

According to V. M. Rohovskyi, a gunshot damage to blood vessels ranges from 2.8 % to 8.0 % [3,6]. During the Anti-Terrorist Operation in the east of Ukraine in 2014–2015, damage to the major vessels occurred in 2 % of victims. 90 % of the wounded had injuries to the vessels of the lower extremities [6]. During the war in Afghanistan, isolated gunshot injuries to arteries were found in 24 % of the wounded, in the remaining cases, they were accompanied by damages to long tubular bones – in 47 %, major veins – in 42 %, and nerves – in 45 % [7]. According to N. M. Rich et al., who analyzed traumatic injuries in the Vietnam war, combined injuries of vessels and nerves were in 42.2 % of the wounded, vessels and bones – in 28.5 %, injuries to veins accounted for 37.7 % of all vascular injuries [8–10].

Gunshot wounds with damage to organs and vascular structures of the retroperitoneal space are an extremely rare and very difficult problem that a surgeon must solve in a matter of moments to save life of the wounded. Damage to the major vessels due to abdominal trauma belongs to the most difficult category, including damage to the inferior vena cava [11–13]. Lethality in case of damage to the suprahepatic and retrohepatic part of the inferior vena cava is 100%, suprarenal and renal – 60.6 %, infrarenal – 30.6 %.

Special attention should be paid to gunshot injuries of the inferior vena cava. These injuries, in combination with damages to the abdominal organs, lead to a high mortality rate of 86 % [14]. The clinical picture of a wounded with a damage to the inferior vena cava requires a specific, narrowly focused (or defined) algorithm of the diagnostics and differential diagnosis by a military surgeon or a civilian surgeon during the treatment of a wounded with damage to the specified anatomical structure of the human body.

Aim

The aim of the clinical case is to demonstrate the features of clinical manifestations and tactical decisions in case of a gunshot shrapnel wound of the inferior vena cava with the presence of a foreign body in the vessel lumen.

Clinical case

A wounded Sh., 35 years old, was admitted to the Military Medical Clinical Center of the Northern Region (MMCC NR) CMF of the Armed Forces of Ukraine in a serious condition with mechanical ventilation. The medical documentation indicated that he was wounded 4 hours before admission. He was operated on in the advanced surgical group, brought to the Military Medical Center of the Republic of Poland with the diagnosis: Combined gunshot wound of the head,

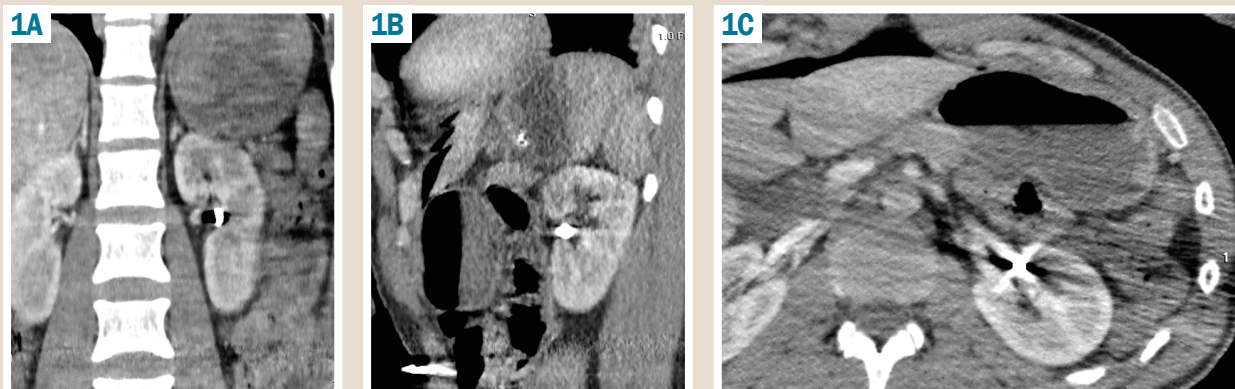


Fig. 1. sCT of chest and abdominal organs before surgical treatment in different planes. **A:** longitudinal; **B:** sagittal; **C:** lumbar. The presence of a foreign body (a metal fragment) in the left renal hilum.

chest, abdomen, upper and lower limbs from 06.10.2022. Penetrating wound of the left temporal area with a gunshot fracture of the left temporal bone of the inferior orbital wall, paraorbital hematoma on the left. Conjunctival chemosis in the left eye. Thoracoabdominal wound on the right with damage to the middle and lower lobe of the right lung, diaphragm, retroperitoneal hematoma on the left with the presence of a foreign body (a metal fragment) in the left renal vein. Hemopneumothorax on the right. Pneumomediastinum. Hydropericardium. Subcutaneous emphysema. Penetrating wound of the right shoulder with a gunshot fracture of the right humerus. Blunt injury to the right hip with a gunshot fracture of the greater trochanter of the right femur with a damage to the right femoral artery and the presence of a free foreign body in the pelvis (a metal fragment). Blunt injury to the penis body. Blunt and penetrating wounds of the soft tissues of the right forearm and hand, left thigh and both shins. Operations (October 6, 2022): primary surgical treatment (PST) of wounds, thoracocentesis on the right, drainage of the pleural cavity according to Bülaeu, laparocentesis, drainage of the abdominal cavity. PST of wounds of the right thigh with end-to-end anastomosis on the right superficial femoral artery.

According to a CT scan (spiral computed tomography) of the head, thoracic and abdominal cavity organs: the condition after a penetrating gunshot wound to the zygomatic area on the left. Multifragmentary fractures of all the walls of the left maxillary sinus, the left inferior orbital wall, a fracture of the left zygomatic bone body with a significant displacement, a fragmentary fracture of the left mandibular branch. No pathological focal changes were found in the brain substance. The lateral ventricles were not dilated. The average structures were not changed. The condition after blunt gunshot penetrating wounds of the chest and abdomen. Drainage of the right pleural cavity, laparocentesis, right-sided pneumothorax. Pneumomediastinum. Subtotal consolidation of the right lung tissue (pneumonitis), fluid accumulation in the pericardium (hydropericardium), in the projection of the left renal hilum, a metal fragment measuring 7.0×5.0 mm, unchanged paranephric tissue. In the soft tissues of the pelvis, adjacent to the iliac wing, there was a fragment of 6×5 mm (it was impossible to exclude a damage to the intestine, taking into account the trajectory of the wound channel), right comminuted femoral neck fracture

with the presence of a metal fragment of 9×5 mm (Fig. 1).

After stabilization of the general condition of the wounded in order to prevent complications (07.10.2022) we performed an operation: right thoracocentesis, re-draining the pleural cavity according to Bülaeu. Laparotomy. Revision of the abdominal cavity organs and retroperitoneal space on the left. Dissection of retroperitoneal hematoma on the left. Sanitation and drainage of the retroperitoneal space on the left. Repeated surgical treatment of wounds of the right thigh. Additional drainage of the pleural cavity according to Bülaeu on the right, mediastinotomy, drainage of the anterior mediastinum. PST of the gunshot wound of the left cheek, zygomatic areas, open reposition of the upper and lower jaws on the left and the left zygomatic bone with metal osteosynthesis (MOS) titanium miniplates and minimesh. Secondary surgical treatment (SST) of gunshot wounds of the right thigh and left shin. PST of gunshot wounds of the right shoulder. SST of the right humerus fracture with a rod external fixation device (EFD).

During the surgical intervention in the paranephric tissue on the left, a metal fragment was not identified. In the postoperative period, we performed a control CT scan of the chest and abdominal organs: the metal fragment migrated along the inferior vena cava to the point of connection with the right atrium (Fig. 2).

The wounded man was transferred to SI "Zaitsev V. T. Institute of General and Emergency Surgery of the National Academy of Medical Sciences of Ukraine", where he underwent sternotomy, pericardiectomy, removal of the foreign body (the metal fragment) using a magnetic flexible device to remove ferromagnetic foreign bodies from the mouth of the inferior vena cava, pleural and pericardial drainage (Fig. 3).

Later, the wounded man was transferred to the MMCC NR CMF of the Armed Forces of Ukraine for further treatment. On the 14th day, he was submitted to the military medical commission and discharged to the unit with a sick leave for 30 calendar days.

Results

Our clinical case was delivered to the Medical Military Clinical Center of the NR from the previous stage of the forward surgical group (FSG) of the area of responsibility within 4 hours by an ambulance.

Multidisciplinary assessment of the nature and features of the injury. The patient was operated on for vital signs. Taking into account the seriousness of the general condition, instrumental monitoring methods were used urgently in the preoperative algorithm of the examination, the FAST protocol, general blood tests, biochemical blood analysis, CBV determination using the formula of Moore, and hourly diuresis included. In parallel with the diagnostic procedures, there was preparation – stabilization of the serious condition of the wounded in the form of puncture of the subclavian vein, antibiotic prophylaxis, analgesia in order to combat the phenomena of hemorrhagic shock, infusion of erythrocyte mass and FSG. On 06.10.2022, operative intervention was carried out for vital signs, the condition of the injured person was stabilized. On 07.10.2022, in order to prevent fat or thromboembolism, PST of the wound was performed, as well as the right humerus fracture fixation with a rod of the EFD, open reposition of the upper and lower jaws on the left and the left zygomatic bone, MOS with titanium miniplates and a minimesh. There were no signs of peritonitis. During the revision of the abdominal cavity and paranephric tissue, no foreign body was identified. Therefore, in the postoperative period, the wounded person underwent a CT scan of the chest and abdominal cavity. According to the CT scan data, the metal fragment was identified. It migrated along the inferior vena cava to the place of connection with the right atrium.

After the approval of the leadership of the MMCC of the Republic of Poland, the wounded man was transferred to SI "Zaitsev V. T. Institute of General and Emergency Surgery of the National Academy of Medical Sciences of Ukraine".

Discussion

Considering the high mortality in gunshot wounds of the inferior vena cava, the presence of foreign bodies inside the vessel lumen is a rare clinical case [10,11]. Migration of the foreign body – the fragment of gunshot origin in the direction of blood flow, was clinically asymptomatic in this case. Contrast methods for the vascular system examination did not give a clear localization of the foreign body. Performing the second CT scan after the surgery made it possible to determine its location and perform the second surgical intervention with a different approach in order to extract it.

Conclusions

1. Fire damage to the inferior vena cava is classically accompanied by a severe general condition, massive blood loss, and requires urgent surgical interventions which should be performed by experienced and highly qualified surgeons, in the best case – by vascular surgeons with experience in stopping bleeding in case of gunshot damage to the major vessels.

2. Multi-component preoperative preparation, clearly established diagnostic plan, multidisciplinary approach on the example of our clinical case make it possible to save life even in the most complicated cases.

Conflicts of interest: authors have no conflict of interest to declare.
Конфлікт інтересів: відсутній.

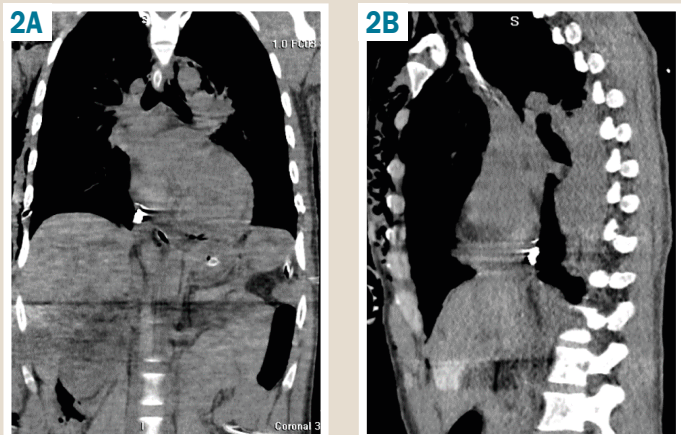


Fig. 2. sCT of the chest and abdominal organs after laparotomy. **A:** longitudinal; **B:** sagittal; **C, D:** lumbar. The presence of a foreign body (a metal fragment) in the mouth of the inferior vena cava.

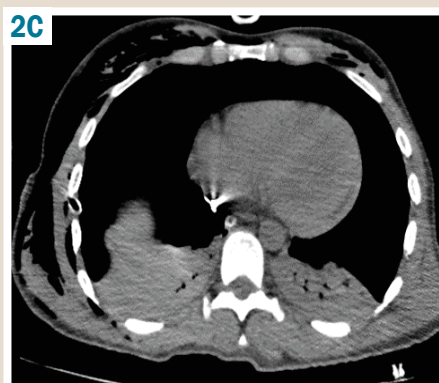
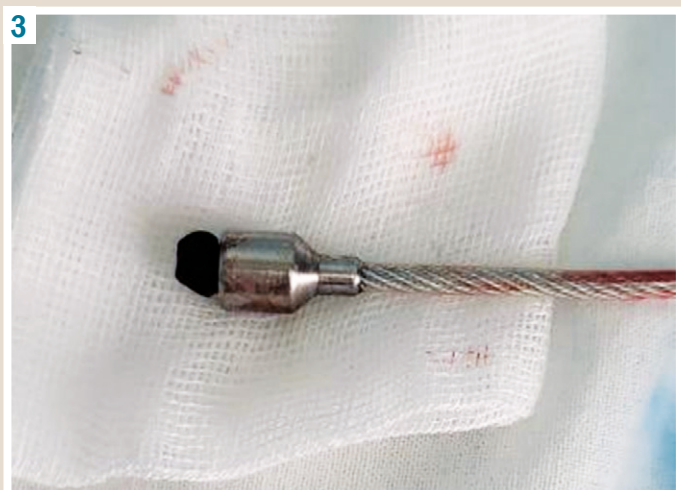
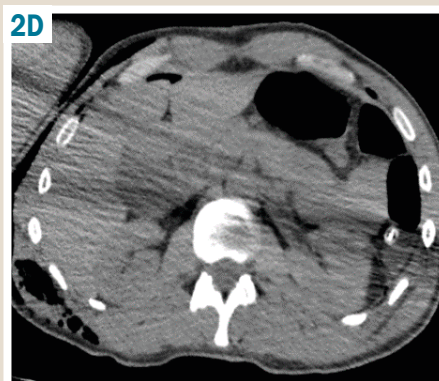
Fig. 3. Removed foreign body (the metal fragment) from the mouth of the inferior vena cava using the magnetic flexible device for removing ferromagnetic foreign bodies.



Надійшла до редакції / Received: 10.10.2022
Після доопрацювання / Revised: 19.10.2022
Прийнято до друку / Accepted: 25.10.2022

Information about authors:

Tsybaliuk V. I., MD, PhD, DSc, Academician of the National Academy of Medical Sciences of Ukraine, President of the National Academy of Medical Sciences of Ukraine, National Academy of Medical Sciences of Ukraine, Kyiv.

ORCID ID: [0000-0001-7544-6603](https://orcid.org/0000-0001-7544-6603)

Lurin I. A., MD, PhD, DSc, Professor, National Academy of Medical Sciences of Ukraine, Vice President of the National Academy of Medical Sciences of Ukraine, Major General of the Medical Service, Kyiv; State Scientific Institution "Scientific and Practical Center of Preventive and Clinical Medicine" of the State Administration of Affairs, Kyiv.

ORCID ID: [0000-0001-6280-1725](https://orcid.org/0000-0001-6280-1725)

Makarov V. V., MD, PhD, DSc, Professor, Head of the Department of Surgery 4, Kharkiv National Medical University, Ukraine.

ORCID ID: [0000-0002-4224-0294](https://orcid.org/0000-0002-4224-0294)

Nehoduiko V. V., MD, PhD, DSc, Associate Professor of the Department of Surgery, Kharkiv National Medical University; Kharkiv Military Medical Clinical Center of the Northern Region, Ministry of Defense, Ukraine.

ORCID ID: [0000-0003-4540-5207](https://orcid.org/0000-0003-4540-5207)

Buchnieva O. V., MD, PhD, SI "V.T. Zaitsev Institute of General and Emergency Surgery of the National Academy of Medical Sciences of Ukraine", Kharkiv.

ORCID ID: [0000-0002-7054-1844](https://orcid.org/0000-0002-7054-1844)

Tertyshnyi S. V., MD, PhD, Lieutenant Colonel of the Medical Service, Head of the Surgical Infection Department, Military Medical Clinical Center of the Southern Region, Odesa, Ukraine.

ORCID ID: [0000-0002-4949-5409](https://orcid.org/0000-0002-4949-5409)

Bunin Yu. V., MD, Head of the Thoracoabdominal Surgery Clinic, Kharkiv Military Medical Clinical Center of the Northern Region, Ministry of Defense, Ukraine.

ORCID ID: [0000-0002-1807-437X](https://orcid.org/0000-0002-1807-437X)

Відомості про авторів:

Цимбалюк В. І., д-р мед. наук, академік НАМН України, президент НАМН України, м. Київ.

Лурін І. А., д-р мед. наук, віцепрезидент НАМН України, професор, генерал-майор медичної служби, ДУ «Науково-практичний центр профілактичної та клінічної медицини» Державного управління справами, м. Київ.

Макаров В. В., д-р мед. наук, професор, зав. каф. хірургії 4, Харківський національний медичний університет, Україна.

Негодуйко В. В., д-р мед. наук, Військово-медичний клінічний центр Північного регіону Міністерства оборони України, м. Харків; доцент каф. хірургії, Харківський національний медичний університет, Україна.

Бучнева О. В., канд. мед. наук, ДУ «Інститут загальної та невідкладної хірургії імені В. Т. Зайцева Національної академії медичних наук України», м. Харків, Україна.

Тертишний С. В., канд. мед. наук, підполковник медичної служби, начальник відділення хірургічної інфекції, Військово-медичний клінічний центр Південного регіону Міністерства оборони України, м. Одеса, Україна.

Бунін Ю. В., полковник медичної служби, начальник хірургічної клініки, Військово-медичний клінічний центр Північного регіону Міністерства оборони України, м. Харків.

References

- [1] Brown, K. V., Guthrie, H. C., Ramasamy, A., Kendrew, J. M., & Clasper, J. (2012). Modern military surgery: lessons from Iraq and Afghanistan. *The Journal of bone and joint surgery. British volume*, 94(4), 536-543. <https://doi.org/10.1302/0301-620X.94B4.28602>
- [2] Boiko, V. V., Lisovyj, V. M., Makarov, V. V., Lurin, I. A., Zamiatin, P. M., Kryvoruchko, I. A., Lykhman, V. M., Pavlov, O. O., Prasol, V. O., Taraban, I. A., Honcharenko, L. Y., Minukhin, D. V., Shcherbakov, V. I., Kravtsov, A. V., Lutsenko, Ye. V., Syzyj, M. Yu., Tarasenko, L. H., Tsodikov, V. V., Arsenij I. I., ... Shypilov, S. A. (2018). *Obrani lektsii z viiskovo-polovoi khirurgii* [Selected lectures on military field surgery]. Kharkiv: "NTMT" publishing house. [in Ukrainian].

- [3] Duke, E., Peterson, A. A., & Erly, W. K. (2014). Migrating bullet: A case of a bullet embolism to the pulmonary artery with secondary pulmonary infarction after gunshot wound to the left globe. *Journal of emergency, trauma, and shock*, 7(1), 38-40. <https://doi.org/10.4103/0974-2700.125638>
- [4] Hussein, N., Rigby, J., & Abid, Q. (2012). Bullet embolus to the right ventricle following shotgun wound to the leg. *BMJ case reports*, 2012, bcr2012007471. <https://doi.org/10.1136/bcr-2012-007471>
- [5] Fernandez-Ranvier, G. G., Mehta, P., Zaid, U., Singh, K., Barry, M., & Mahmoud, A. (2013). Pulmonary artery bullet embolism-Case report and review. *International Journal of surgery case reports*, 4(5), 521-523. <https://doi.org/10.1016/j.ijscr.2013.02.017>
- [6] Rohovskyi, V. M. (2014). *Vkazivky po viiskovo-polovii khirurgii MO Ukrainy* [Instructions on military field surgery of the Ministry of Defense of Ukraine]. Kyiv. [in Ukrainian].
- [7] Mykhailosov, R. M., Velykodnyi, O. M., Bilenkyi, V. A., Nehoduiko, V. V., & Borodai, V. O. (2016). *Prystrij hnuchkyi dla vydalennia feromagnitnykh storonnikh til* [A flexible device for removing ferromagnetic foreign bodies]. *Ukraine Patent UA 105452*. <https://sis.ukrpatent.org/uk/search/detail/549654/>
- [8] Khomenko, I. P., Tsema, Ie. V., Koval, B. M., Gangal, I. I., Dinets, A. V., & Mishalov, V. G., (2019). Sochetannoe oskolochnoe ranenie nizhnei poloi veny, vyzvavshee pulevuyu emboliyu legochnoi arterii (klinicheskoe nablyudenie i obzor literatury) [Combined shrapnel injury of the inferior vena cava which caused bulletpulmonary artery embolism (case report and review of the literature)]. *Khirurgiia Ukrainy*, (2), 69-80. [in Ukrainian]. <https://doi.org/10.30978/SU2019-2-69>
- [9] Rich, N. M., & Spencer, F. C. (1978). *Vascular trauma*. Philadelphia etc. Saunders Co.
- [10] Yoon, B., Grasso, S., & Hofmann, L. J. (2018). Management of Bullet Emboli to the Heart and Great Vessels. *Military medicine*, 183(9-10), e307-e313. <https://doi.org/10.1093/milmed/usx191>
- [11] Yordanov, Y., Pateron, D., & May, A. (2014). An unusual aetiology of abdominal pain: the forgotten bullet. *BMJ case reports*, 2014, bcr2014208268. <https://doi.org/10.1136/bcr-2014-208268>
- [12] Wojda, T. R., Dingley, S. D., Wolfe, S., Terzian, W. T. H., Thomas, P. G., Vazquez, D., Sweeney J., & Stawicki, S. P. (2017). Foreign Intravascular Object Embolization and Migration: Bullets, Catheters, Wires, Stents, Filters, and More. In *Emboic Diseases – Unusual Therapies and Challenges*. InTech. <https://doi.org/10.5772/68039>
- [13] Grechanyk, O. I., Abdullaiev, R. Ya., Lurin, I. A., Gumenuk, K. V., Nehoduiko, V. V., & Sliesarenko, D. O. (2021). Modern aspects of diagnosis of the abdominal gun-shot woundings. Experience of a hybrid war in the East of Ukraine. *Klinicheskaja Khirurgiia*, 88(5-6), 42-52. <https://doi.org/10.26779/2522-1396.2021.5-6.42>
- [14] Kazmirchuk, A., Yarmoliuk, Y., Lurin, I., Gybalo, R., Burianov, O., Derkach, S., & Karpenko, K. (2022). Ukraine's Experience with Management of Combat Casualties Using NATO's Four-Tier "Changing as Needed" Healthcare System. *World journal of surgery*, 46(12), 2858-2862. <https://doi.org/10.1007/s00268-022-06718-3>