

O.I. Tiron, O.F. Dzygal, O.V. Onufryenko, O.M. Komlevoi,
V.Yu. Shapovalov¹, O.I. Yatsyna²
Odessa National Medical University, Odessa, ¹Military Medical Clinical Center of the Southern
Region, Ministry of Defence, Ukraine, Odessa. ²National Cancer Institute, Kyiv

THYROID GLAND PARENCHYMA MORPHOLOGICAL ABNORMALITIES IN RATS ON THE THIRD DAY AFTER SKIN THERMAL BURNING

e-mail: chekina.o@ukr.net

The purpose of the study was to establish thyroid gland histological and ultrastructural changes of experimental animals 3 days after the thermal skin injury under physiological 0.9 % NaCl solution administration. Intrathyroid hemodynamic changes, the stromal component structure alterations and destructive processes in the thyroid gland morpho-functional unit - the follicle - were detected on the microscopic level three days after the animals' skin experimental thermal injury under the physiological 0.9 % NaCl solution administration. Thyroid gland capsule and stroma throughout this period of the trials were characterized by collagen fibers swelling and focal leukocyte infiltration with segmented neutrophils predominance. Thyroid hemodynamics disturbances were manifested by arterial and venous plethora, stasis in the arterial vessels of the organ and components of the microcirculatory bed. Follicular cells contained a small nucleus with shallow karyolema invaginations, marginally located heterochromatin and small lumps of it dispersed throughout the karyoplasm. Experimental animals' thyroid gland hemocapillaries were characterized by both basement membrane components and the endothelial layer swelling as well as stasis of the lumen. Endotheliocytes contained nuclei with heterochromatin peripheral localization. The third day after a skin burn under the physiological 0.9 % NaCl solution administration resulted in certain alterations in the structure of the vascular component of the gland; its stroma and parenchyma were established at the microscopic and submicroscopic level, which could lead to a violation of the secretory cycle of follicular cells and, as a result, to an imbalance in the synthesis and excretion of thyroid hormones. These pathomorphological intrathyroid disorders indicate these micro-changes possible reversibility which is important in terms of such a contingent of patients' pharmacotherapy.

Key words: thyroid gland, parenchyma, burning injury, morphological disturbances, hematoxylin-eosin, follicle, thyrocyte, capillary, stasis.

O.I. Тірон, О.Ф. Дзигал, О.В. Онуфрієнко, О.М. Комлевої,
В.Ю. Шаповалов, О.І. Яцина

МОРФОЛОГІЧНІ ПОРУШЕННЯ ПАРЕНХІМИ ЩИТОПОДІБНОЇ ЗАЛОЗИ У ЩУРІВ НА ТРЕТЮ ДОБУ ПІСЛЯ ТЕРМІЧНОГО ОПІКУ ШКІРИ

Метою дослідження було дослідити гістологічні та ультраструктурні зміни щитоподібної залози піддослідних тварин через 3 доби після термічної травми шкіри при введенні фізіологічного 0,9 % розчину NaCl. Через три доби після експериментального термічного ураження шкіри тварин при введенні фізіологічного 0,9 % розчину NaCl на мікроскопічному рівні виявлено внутрішньотиреоїдні гемодинамічні зміни, зміни структури стромального компонента та деструктивні процеси в морфо-функціональній одиниці щитовидної залози – фолікулі. Капсула та строма щитовидної залози протягом цього періоду досліджень характеризувались набряком колагенових волокон та вогнищевою лейкоцитарною інфільтрацією з переважанням сегментоядерних нейтрофілів. Порухення гемодинаміки щитовидної залози проявлялося артеріальним і венозним повнокрів'ям, стазом в артеріальних судинах органу та складових мікроциркуляторного русла. Фолікулярні клітини містили невелике ядро з неглибокими каріолемними інвагінаціями, маргінально розташований гетерохроматин і невеликі його грудочки, розсіяні по каріоплазмі. Для гемокапілярів щитовидної залози характерно набухання як компонентів базальної мембрани, так і ендотеліального шару, а також стаз просвіту. Ендотеліоцити містили ядра з гетерохроматиною периферичною локалізацією. На третю добу після опіку шкіри при введенні фізіологічного 0,9 % розчину NaCl відбуваються певні зміни в структурі судинного компонента залози, її стромі та паренхіми на мікроскопічному та субмікроскопічному рівнях, які можуть призвести до порушення секреторного циклу фолікулярних клітин і, як наслідок, до порушення синтезу і секреції тиреоїдних гормонів. Виявлені патоморфологічні інтратиреоїдні порушення вказують на можливу зворотність цих мікрозмін, що є важливим з точки зору фармакотерапії такого контингенту пацієнтів.

Ключові слова: щитоподібна залоза, паренхіма, опікова травма, морфологічні порушення, гематоксилін-еозин, фолікул, тиреоцит, капіляр, стаз.

The work is fragments of the research project "Peculiarities in micro-ultramicroscopic structure and histochemical properties of body tissues during the development of compensatory-adaptive reactions", state registration No 0121U108204.

Natural and man-made disasters, modern military conflicts are accompanied now by injuries complicated by burns, acute haemorrhages and at least resulting shock of varying severity [2]. Thermal injuries are one of the most urgent both medical and social problems of world modern medicine including the same in Ukraine [6]. Above 45,000 people suffer from burns every year in Ukraine, these data occupy the third place in the structure of mortality as a result of all injuries, second only to traffic injuries in terms of frequency [2].

The urgency of the problem of burn injury is determined by the frequent lesions of adults and children, the complexity and prolonged character of treatment, long-term disability and relatively high

mortality [7, 11]. Despite the significant progress achieved in this pathology treatment the mortality rate among severely burned patients remains high, especially with critical (40-50 % of the body surface) and supercritical (over 50 %) deep burns [10].

A large number of pathological processes develop in the body in response to a burn injury which involves almost all organs and systems, leading to an expressed homeostasis disturbances and adaptation processes disruption [12]. One of the most important burn injury aspects which directly affect its pathogenetic mechanisms severity is endocrine dysregulation at the initial stages of the pathological process, manifested by significant metabolic disorders which direction and severity are directly related with the level of endogenous hormones [15].

Clarification of the mechanisms of damage, structural reconstruction and subsequent reparative processes in the case of thyroid gland thermal damage is of great interest. It is clear that the endocrine system, characterized by a wide range of regulatory hormonal influences on organs, organ systems and regulatory systems of the biological organism, determines the primary reactions in response to thermal damage [8]. It is known that thyroid gland under the influence of temperature factors of threshold and suprathreshold intensity, taking into account large-scale duplicative feedback mechanisms, thyroid hormones wide range of physiological activity, structural and functional organization and morpho-functional peculiarities, is considered to be one of the leading subject to thermal shock [5]. Thyroid gland was observed to be highly sensitive to the influence of adverse environmental factors, in particular burn injuries [6].

In conditions of the affected and/or burned organism structural and functional changes in the organs, including the thyroid gland, dysfunctions of many organs and systems are involved in mediating the pathological process, in particular, the system of blood, cardiovascular, respiratory and other systems. Pathogenetic mechanisms of primary and associated pathological processes induced by thyroid gland burn damage were insufficiently studied. We suppose that this might be as the result of, firstly, unexplained thyroid gland parenchyma morpho-functional dysfunctions in the dynamics of the burn effect and, secondly, unexplored chains of the “*vicious circle*” pathological processes determined by thyroid dysfunction and occur with other organs and body systems participation.

The purpose of the study was to establish thyroid gland histological and ultrastructural changes in experimental animals 3 days after the thermal skin injury under physiological 0.9 % NaCl solution administration.

Materials and methods. Experimental trials were performed on 90 white male rats weighing 160-180 g (obtained from the vivarium of the Institute of Pharmacology and Toxicology of the National Academy of Medical Sciences of Ukraine) on the basis of the Research Center of N.I. Pirogov Vinnytsia National Medical University. Animals keeping, handling and manipulation was carried out in accordance with the “General Ethical Principles of Animal Experiments” adopted by the First National Congress on Bioethics (Kyiv, 2001) and was guided by the recommendations of the European Convention for the Protection of Vertebrate Animals for Experimental and Other Scientific Purposes (Strasbourg, 1985) and guidelines of the State Pharmacological Center of the Ministry of Health of Ukraine on “Preclinical studies of drugs” (2001) as well as rules of humane treatment of experimental animals and conditions approved by the Committee on Bioethics of N.I. Pirogov Vinnytsia National Medical University (Prot. N1 from 14.01.2010).

Thermal skin burns of 2-3 degrees were modeled by four copper plates (each surface area equal to 13.86 cm²) applying to pre-depilated side surfaces of the rats body for 10 sec, these rats were preheated for 6 min in water with a temperature of 100°C [9]. The total area of skin lesions was 21-23 %. The first 7 days, rats were infused with 0.9 % NaCl solution into the inferior vena cava. Animals were euthanized by decapitation (after 1, 3, 7, 14 and 21 days). Shaving, venous catheterization, skin burns and decapitation of rats were performed under propofol (i.v., 60 mg/kg) anesthesia.

Biological material collection for microscopic examination was done according to used method [3]. The thyroid gland samples were fixed with 10 % neutral formalin solution, then dehydrated by passing through increasing concentrations of alcohol and embedded into paraffin blocks. The obtained sections, 5–6 μm thick, were stained with Hematoxylin-Eosin [3].

The histological sections were examined under the MIKROmed SEO SCAN light microscope (“Sumy Electron Optics”, Sumy, Ukraine), the photomicrographs were taken with the Vision CCD Camera with an image output system for histological specimens. The thyroid gland samples collected for electron microscopic examination were fixed with 2.5 % glutaraldehyde solution, then post-fixed with 1 % osmium tetroxide prepared with phosphate buffer. Further processing was done according to used method [3].

Ultrathin sections made with ultramicrotome LKB-3 were contrasted with uranyl acetate, lead citrate according to the Reynolds method [1] and examined under the electron microscope PEM-125K.

All morphological researches were performed under the Agreements on Scientific Cooperation among the Histology, Cytology and Embryology Department of Odesa National Medical University and Research Center of N.I. Pirogov Vinnytsia National Medical University (from 01.01.2018) and Histology and Embryology Department of I. Gorbachevsky Ternopil National Medical University (from 01.01.2019).

Results of the study and their discussion. Intrathyroid hemodynamic changes, the stromal component structure alterations and destructive processes in the thyroid gland morpho-functional unit – the follicle, were detected on the microscopic level three days after the animals' skin experimental thermal injury under the physiological 0.9 % NaCl solution administration. Thyroid gland capsule and stroma throughout this period of the experimental trials were characterized by collagen fibers swelling and focal leukocyte infiltration with segmented neutrophils predominance.

Thyroid hemodynamics disturbances were manifested by both arterial and venous plethora, stasis in the arterial vessels of the organ and components of the microcirculatory bed (fig. 1 A). Arterial spasm with perivascular edema was also detected (fig. 1 B).

3 days after skin thermal injury under the physiological 0.9 % NaCl solution administration most of the follicles in the composition of the particles were overstretched by a dense homogeneous colloid and lined with flat thyrocytes which may indicate a decrease in thyroid hormones levels secreted into the bloodstream. A significant part of follicular cells had a cubic shape, oxyphilic cytoplasm and a rounded nucleus with dense basophilic heterochromatin (Fig. 1 C). There are also locally swollen thyrocytes with illuminated areas of the cytoplasm, which is clearly visible in semi-thin sections stained with methylene blue (fig. 1 D).

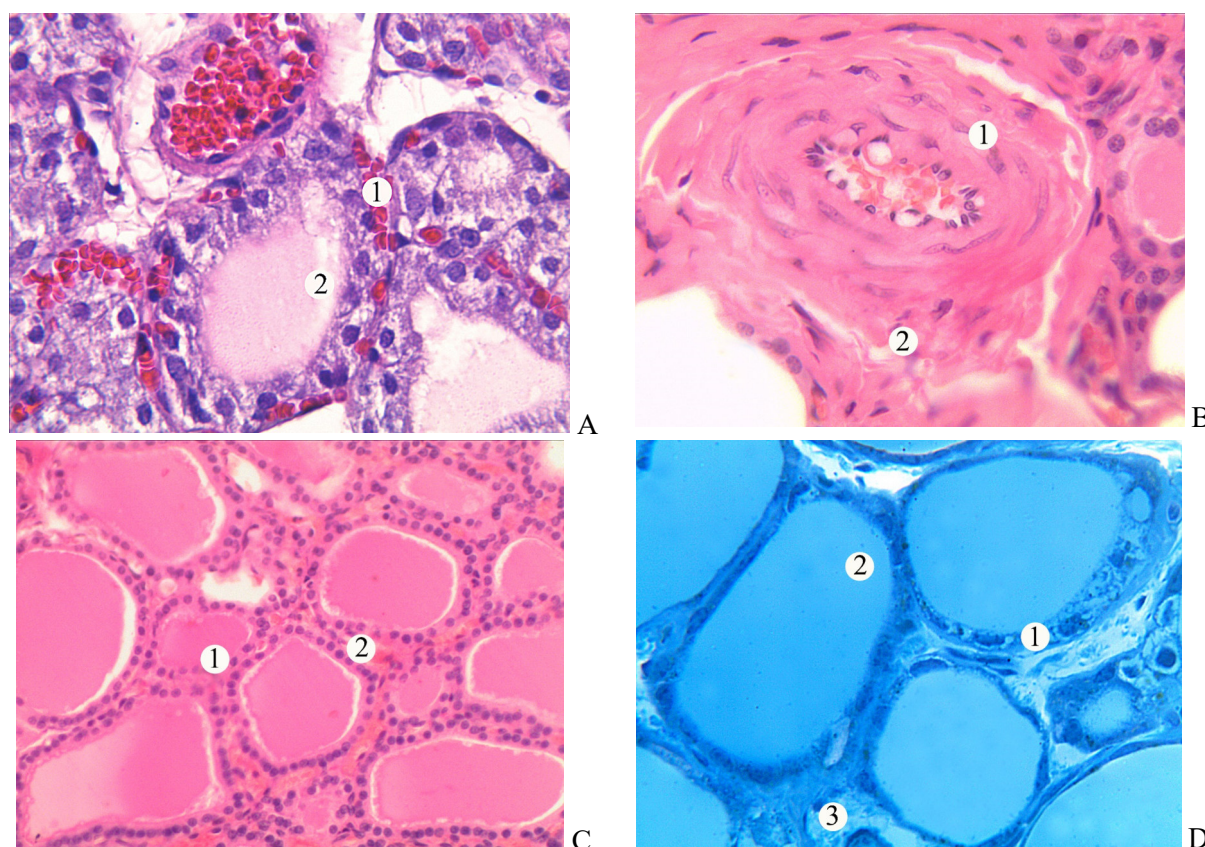


Fig. 1. Microscopic changes of the thyroid gland 3 days after skin experimental thermal injury under the physiological 0.9 % NaCl solution administration. Hematoxylin-Eosin staining. x 400. A – 1 – stasis in capillaries; 2 - follicles. Hematoxylin-Eosin staining. x 400. B – 1 – media of the artery; 2 – perivascular edema. Hematoxylin-Eosin staining. x 400. C – 1 – follicle, 2 – capillaries. Hematoxylin-Eosin staining. x 200. D – 1 – thyrocytes with illuminated areas of cytoplasm, – colloid of follicles, 3 – interstitial connective tissue. Semi-thin cut. Methylene blue staining. x 400.

Electron microscopic studies on the 3rd day after a skin thermal injury under the physiological 0.9 % NaCl solution administration confirm destructive changes detected in our histological analysis of the thyroid gland samples in the used experimental conditions.

Follicular cells contained a small nucleus with shallow karyolem invaginations, marginally located heterochromatin and small lumps of it dispersed throughout the karyoplasm. Swollen, damaged

mitochondria, significantly expanded, and sometimes destroyed tubules of the granular endoplasmic reticulum were observed in their cytoplasm. Such changes in general-purposed organelles gave the cytoplasm a vacuolated appearance at the submicroscopic level. At the microscopic level they looked like areas of illumination. Individual microvilli were recorded on the apical surface of thyrocytes which indicates low functional activity of endocrinocytes. A homogeneous colloid was detected in the lumen of the follicle (fig. 2).

Experimental animals' thyroid gland hemocapillaries on the 3rd day after a skin thermal injury under physiological 0.9 % NaCl solution administration were characterized by both basement membrane components and the endothelial layer swelling as well as stasis of the lumen. Endotheliocytes contained nuclei with heterochromatin peripheral localization. The swollen cytoplasm contained general-purposed organelles and microbubbles formed in the process of pinocytosis.

Expansion of intercellular spaces was observed in areas of contact between neighboring endotheliocytes (fig. 3).

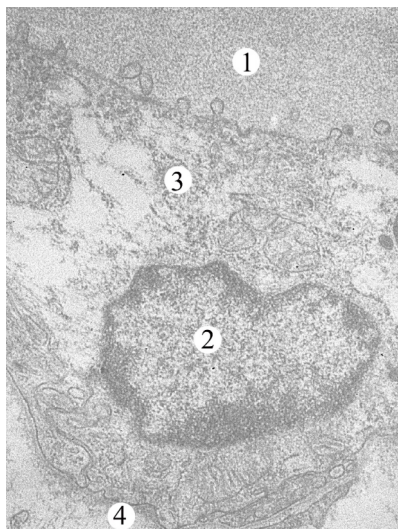


Fig. 2. Ultrastructure of the wall of the thyroid gland follicle of an animal 3 days after a skin thermal injury under physiological 0.9 % NaCl solution administration. Electron micrograph. x 12000. 1 – follicle lumen, 2 – nucleus and 3 – thyrocyte cytoplasm, 4 – basement membrane.

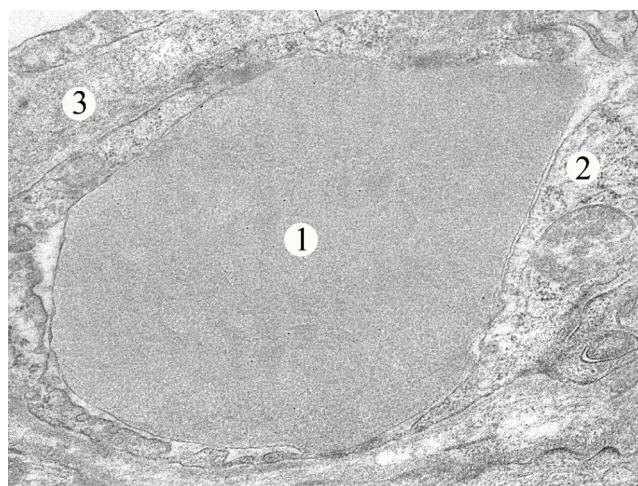


Fig. 3. Thyroid gland hemocapillary submicroscopic organization of an animal 3 days after a skin thermal injury under physiological 0.9 % NaCl solution administration. Electron micrograph. x 12000. 1 – capillary lumen with an erythrocyte, 2 – endotheliocyte cytoplasm, 3 – capillary basement membrane.

Our results on experimental animals' thyroid gland morphologic changes 3 days after the skin thermal injury in a certain way correspond to our ultrastructure investigations 24 hrs in the same modeled pathologic condition [13] and do not contradict to other data [4–7]. The data obtained allowed us to trace certain morphological disturbances in the thyroid parenchyma in the long-term dynamics of a thermal injury [14].

Earlier data indicated that 1 day after the thermal injury micro- and submicroscopic studies could show only primary and/or reactive adjunctive-compensatory changes and initial manifestations of thyroid gland parenchyma destruction [13]. 3 days further we revealed the expressed manifestation of the initial features of thermal-provoked “stress reaction” in the form of intrathyroid parenchymal, stromal and vascular lesions.

It was shown that during the first 24 hours after the burn, the main pathological changes in the thyroid gland correspond to the first phase of the lesion - the phase of post-traumatic depression. This phase is characterized by an extensive increase in the follicles of the gland. 14 days after the burn we observed the maximum degree of destructive changes in the thyroid gland and 21 days after the burn we detected the signs of thyroid gland destruction together with compensatory-adaptive changes [14]. In other words, on the 3rd day of the course of the burn pathological process, the pathomorphological intraorganic disorders identified by us indicate their reversibility, which is important to take into account in terms of pharmacotherapy of such a contingent of patients in a clinical setting.

Our actual data showing more pronounced intrathyroid micro-pathology explains, from one side, the ultrastructural phenomena developed 3 days after a skin thermal injury and, from the other side, give an opportunity to follow the perspective discussion on three main areas. The first one - one should suppose the emerging ultrastructural mechanism of the entire thyroid parenchyma approaching dysfunction in the burn disease dynamics. This seems to us important in both the diagnostic and preventive aspects of these results possible implementation in the clinic.

The second - it is logical to assume that, knowing intracellular and intraorganic micro-disturbances we are able to anticipate chain and/or sequential pathogenetic mechanisms mediated by thyroid gland involvement. In this case, the sanogenetic mechanisms activation is extremely important; their achievement will give us a significant array of fundamental knowledge about endocrine dysfunctions in burn disease which is also important from a general theoretical and preventive point of view.

And, thirdly, it is extremely important for us to know the entire dynamics of intrathyroid microdisorders during the entire period of burn disease, since in this case there is every chance to successfully develop an effective pathogenetically determined pharmacological correction of thyroid dysfunction in model conditions.

Conclusions

1. The third day after a skin burn under the physiological 0.9 % NaCl solution administration resulted in the following intrathyroid pathomorphological changes – certain alterations in the structure of the vascular component of the gland, its stroma and parenchyma were established at the microscopic and submicroscopic level, which could lead to a violation of the secretory cycle of follicular cells and, as a result, to an imbalance in the synthesis and excretion of thyroid hormones.

2. The pathomorphological intrathyroid disorders identified on the third day after a skin burn under the physiological 0.9 % NaCl solution administration indicate this thyroid gland micro-changes possible reversibility which is important in terms of such a contingent of patients' clinical pharmacotherapy.

3. Important are knowledge of the entire dynamics of intrathyroid microdisorders during the whole period of burn disease, since in this case there is every chance to successfully develop an effective pathogenetically determined pharmacological correction of thyroid dysfunction in model conditions.

Prospects for furthers research include a comprehensive experimental investigation of intraglandular pathomorphological disorders in the burn disease dynamics to evaluate the thyroid dysfunction structural and hormonal correlates. This will allow the developed pathogenetically substantiated therapy aimed to thyroid gland structure, function and hormonal secretion restoring in the post-burn period.

References

1. Bagrii MM, Dibrova VA, Popadynets OG, Gryshuk MI. *Metodyky morfologichnykh doslidzen*. Vinnytsia: Nova knyga. 2016; 328 [in Ukrainian]
2. Voyenno-polyova khirurgiya: pidruchnyk. Red. Ja.L. Zaruckiy, V.Ja. Bilyj. Kyiv : FENIKS, 2018: 544 [in Ukrainian]
3. Horalsky LP, Khomych VT, Kononskyi OI. *Osnovy histolohichnoyi tekhniki i morfofunktsionalni metody doslidzen u normi ta pry patolohiyi*. Zhytomyr : ZhNAEU, 2019: 286 [in Ukrainian]
4. Nebesna ZM, Yeroshenko GA. *Histolohichni ta histokhimichni zminy lehen pry eksperymentalniy termichniy travmi*. Svit medytsyny ta biolohiyi. 2015; 2(49) :106–110 [in Ukrainian]
5. Strelchenko YuI, Zyablitsev SV, Yelskyi VM. *Patofiziolohichni vzayemozvyazky hipofizarno-tyreoyidnoyi ta hipofizarno-nadnyrkovoyi system pid vplyvom polyaryzovanoho svitla v shchuriv iz dozovanyim opikom vidkrytyam polumyam*. Clinical and experimental pathology. 2012; 11(2–3) :156–158 [in Ukrainian]
6. Chernyakova HM, Minukhin VV, Voronin EP. *Suchasnyy pohlyad na mistseve likuvannya opikiv z infektsiynym komponentom*. Herald of problems of biology and medicine. 2016; 4(133) :68–72 [in Ukrainian].
7. Bahemia IA, Muganza A, oore R, Sahid F, Menezes CN. *Microbiology and antibiotic resistance in severe burns patients: a 5 year review in an adult burns unit*. Burns 2015; 41(7): 1536–1542, <https://doi.org/10.1016/j.burns.2015.05.007>.
8. Dzevulska IV, Kovalchuk OI, Cherkasov EV, Majewskiy OYe, Shevchuk YuG, Pastukhova VA, Kyselova TM. *Influence of lactoproteinum solution with sorbitol on DNA content of cells of endocrine glands on the background of skin burn in rats*. World of Medicine and Biology. 2017; 2(64):33–39. doi:10.26724/2079-8334-2018-2-64-33-39.
9. Gunas I, Dovgan I, Masur O. *Method of thermal burn trauma correction by means of cryoinfluence*. Abstracts are presented in *zusammen mit der Polish Anatomical Society with the participation of the Association of Anatomistes Verhandlungen der Anatomischen Gesellschaft, Olsztyn. Jena – Munchen Der Urban & Fischer Verlag, 1997: 105.*
10. Hwang W, Yoon SS. *Virulence characteristics and an action mode of antibiotic resistance in multidrug-resistant Pseudomonas aeruginosa*. Sci Rep 2019; 9(1): 487, <https://doi.org/10.1038/s41598-018-37422-9>.
11. Leontyev AE, Pavlenko IV, Kovalishena OV, Saperkin NV, Tulupov AA, Beschastnov VV *Application of Phagotherapy in the Treatment of Burn Patients (Review)*. *Sovrem Tekhnologii Med*. 2021;12(3) :95–103. doi: 10.17691/stm2020.12.3.12.
12. Plichta JK, Holmes CJ, Gamelli RL, Radek KA. *Local burn injury promotes defects in the epidermal lipid and antimicrobial peptide barriers in human autograft skin and burn margin: implications for burn wound healing and graft survival*. J Burn Care Res. 2017;38(1) :212–226. <https://doi.org/10.1097/bcr.0000000000000357>.
13. Tiron OI. *Features of morphological changes in the thyroid gland of white male rats 1 day after thermal trauma of the skin on the background of the introduction of 0.9 % NaCl solution*. Biomedical and Biosocial Anthropology, 2019; 37: 55–59. DOI: <https://doi.org/10.31393/bba37-2019-09>
14. Tiron O.I., Stetsenko A.V., Yatsyna O.I., Zayats L.M., Kolotvin A.O., Shumilina K.S. *The morphological changes of the white rats' thyroid gland 21 days after experimental thermal burn injury under NaCl systemic administration* // World of Medicine and Biology. 2022; 2(80) :237–241. DOI 10.26724/2079-8334-2022-2-80-237-241
15. Williams FN, Herndon DN. *Metabolic and Endocrine Considerations After Burn Injury*. Clin Plast Surg. 2017;44(3):541–553. doi: 10.1016/j.cps.2017.02.013.

Стаття надійшла 29.08.2021 р.