

## STUDY OF OSTEOPLASTIC AND ANTI-INFLAMMATORY EFFICIENCY OF DRUGS CONTAINING CALCIUM HYDROXYAPATITE AND HYALURONIC ACID

Larkina, S. A.<sup>1</sup>; Seletska, O. V.<sup>2</sup>; Makarenko, O. A.<sup>3</sup>; Vastyanov, R. S.<sup>1</sup>; Badiuk, N. S.<sup>4\*</sup>

<sup>1</sup>Odessa National Medical University, Odessa, Ukraine

<sup>2</sup>Kings College, London, UK

<sup>3</sup>Odessa I. I. Mechnikov National University, Odessa, Ukraine

<sup>4</sup>State Enterprise Ukrainian Research Institute of Transport Medicine of the "Ministry of Health of Ukraine", Odessa, Ukraine

\*corresponding author \*badiuk\_ns@ukr.net

### Abstract

The aim of the study was to assess the anti-inflammatory properties of injections of calcium hydroxyapatite (CaHA) drugs of various concentrations and hyaluronic acid on the state of periodontal tissues in rats with experimental periodontitis.

The study was carried out on the periodontal tissues of rats in which periodontitis was reproduced. The animals were divided into 5 groups: Group 1 - intact (control); Group 2 - rats with reproduced periodontitis without treatment; Group 3 - rats with periodontitis, which were treated by injections of calcium hydroxyapatite at a concentration of 55.7%; Group 4 - rats with periodontitis, which were treated by joint injections of "calcium hydroxyapatite 55.7% + stabilized hyaluronic acid"; Group 5 - rats with periodontitis, which were treated by injections of "calcium hydroxyapatite 27.85% + unstabilized hyaluronic acid". The effectiveness of treatment was assessed by the activity of elastase, alkaline and acid phosphatases in the bone tissue of the jaw, the concentration of malondialdehyde, the activity of elastase and acid phosphatase in the rat gingival homogenate.

Single subgingival injections of calcium hydroxyapatite in combination with hyaluronic acid had a pronounced anti-inflammatory effect on the soft tissues of the periodontium, reducing the concentration of malondialdehyde in the homogenates of the gums of rats with periodontitis by 24.6 - 40.3%, the activity of acid phosphatase - by 25.3 - 38, 3%, elastase activity - by 23.5 - 29.8%. No direct relationship was found between the calcium concentration in the drugs and their anti-inflammatory effect. A high concentration of calcium without hyaluronic acid was less effective than a low concentration combined with hyaluronic acid.

Experimental studies have shown the ability of drugs of calcium hydroxyapatite in combination with hyaluronic acid to inhibit the activity of destructive enzymes and increase the activity of the osteoblast marker in the jaw bone tissue of rats with periodontitis, along with a decrease in inflammation markers in the gums of animals with periodontitis.

**Keywords:** *experimental periodontitis, inflammation, rats, bone tissue, hyaluronic acid, calcium hydroxyapatite, periodontitis, subgingival injections*

## Introduction

Inflammatory periodontal diseases - their diagnosis, treatment and prevention - is one of the most difficult tasks of modern dentistry, which is explained by the multicomponent, clinical persistence, frequent chronicity of the inflammatory-destructive and / or degenerative pathological process in the periodontal tissues. This also explains the insufficient effectiveness of therapeutic and prophylactic measures in patients with periodontitis, which served as the basis for conducting a number of experimental studies.

The problem of periodontal diseases is known for their widespread prevalence, numerous studies in this area and the search for new methods of prevention and treatment of this pathology. It still remains relevant, despite the modern advances in dentistry, pharmacology and osteology.

An additional difficulty is the choice of pharmacological drugs for the treatment of periodontitis, since the prescribed drugs must have anti-inflammatory and antimicrobial efficacy, stimulate metabolic and regenerative processes in the periodontium. Often, to achieve these effects, it is necessary to resort to polytherapy, which is not effective. With this in mind, an important task is to develop new methods of complex treatment of periodontitis.

Calcium hydroxyapatite has been long used in dentistry for topical application and to stimulate bone regeneration in the surgical treatment of periodontal bone defects [6, 7, 9]. The anti-inflammatory and regenerative properties of hyaluronic acid drugs have also been shown both experimentally and in a clinical setting [4, 5, 10, 11]. The combined use of these drugs in injectable form for osteoplastic purposes shows their advantage [8].

The aim of the work is to evaluate the anti-inflammatory efficacy of single subgingival injections of calcium hydroxyapatite drugs of various concentrations, without the addition of hyaluronic acid and with the addition of stabilized and unstabilized hyaluronic acid, in rats with experimental periodontitis.

The anti-inflammatory efficacy of the selected drugs was determined by us by the change in the activity of inflammation markers in the mucous

membrane and bone tissue, which is important for the clinical orientation of promising results, given that the course of inflammatory-necrotic and degenerative processes, the state of immunobiological surveillance, as well as proliferative activity are characteristic of functional activity of these tissues.

## Materials and methods

The study was carried out on 78 female Wistar rats, 6-7 months old, with an average weight of  $285 \pm 34$  g. The animals were kept on a standard ration in vivarium with free access to food and water. The experimental study was approved by the Ethics Commission of the Odessa National Medical University (Protocol No. 17 dated 02.02.2021).

The animals were randomized into 5 groups:

1. Intact (control);
2. Rats with reproduced periodontitis without treatment (P);
3. Rats with periodontitis treated with injections of calcium hydroxyapatite with a concentration of 55.7% (P + Ca);
4. Rats with periodontitis, which were treated by injections of "calcium hydroxyapatite 55.7% + stabilized hyaluronic acid" (P + Ca + HA stab);
5. Rats with periodontitis, which were treated by injections of "calcium hydroxyapatite 27.85% + unstabilized hyaluronic acid" (P + Ca + HA unstab).

Experimental periodontitis was reproduced by adding peroxidized sunflower oil to the feed at the rate of 1 ml per 1 animal per day [3]. On the 21st day of modeling of periodontitis, the drugs in a dose of 0.1 ml were injected into the gums of the lower molars of rats once.

The following drugs were used in the work: for rats of group 3 "Calcium hydroxyapatite" Crystallys ("Luminera", Israel), for rats of group 4 "Hydroxyapatite calcium and stabilized hyaluronic acid" HArmonyCa ("Luminera", Israel) and for rats of group 5 "Hydroxyapatite calcium and hyaluronic acid, unstabilized" Crystallys + Luminera Hydryal 2% in a 1:1 ratio ("Luminera", Israel).

The animals were euthanized under thiopental anesthesia (20 mg / kg, intraperitoneally) by bloodletting from the heart 2, 4, and 6 weeks after injections of the drugs.

In homogenates of bone tissue (75 mg / ml 0.1 N citrate buffer pH 6.1), the activity of elastase was

determined by hydrolysis of Nt-BOC-L-alanin-p-nitrophenyl ester, alkaline (ALP) and acid phosphatases (AP) by hydrolysis of para-nitrophenyl phosphate at pH 10.1 and 4.8, respectively [3]. In gingival homogenates (20 mg/ml 0.05 M Tris-HCl buffer pH 7.5), inflammatory markers were determined: the content of malondialdehyde with thiobarbituric acid (MDA), elastase and acid phosphatase activity [3].

The data obtained were calculated statistically using the parametric ANOVA criterion, which was accompanied as a correspondence by the Newman-Keuls test [1]. The minimum statistical probability was determined at  $p < 0.05$ .  $P_1$  was calculated in case of the data obtained were compared with the same in groups of animals with periodontitis without treatment.

Experimental studies were conducted in accordance with the rules established by the Directive of the European Parliament and the Council (2010/63 / EU), by the order of the Ministry of Education and Science, Youth and Sports of Ukraine No. 249 of March 1, 2012 "On Approval of the Procedure for conducting scientific experiments, experiments on animals by scientific institutions " and methodical recommendations.

## Results

The study of enzyme activity in the jaws of animals revealed abnormalities in the bone tissue of rats with periodontitis. An alimentary excess of peroxides leads to a decrease in the activity of alkaline phosphatase (ALP) in the jaws of rats with periodontitis by 1.7 times ( $p < 0.001$ ), which indicates inhibition of the intensity of bone mineralization (Table 1).

The injection of calcium hydroxyapatite (55.7%) into the gums of rats of the 3rd group did not have a significant effect on the alkaline phosphatase activity, which remained at a low level ( $p < 0.001-0.002$  and  $p_1 > 0.1$ , Table 1) at all stages of the study.

The use of a calcium composition (27.85%) with unstabilized hyaluronic acid also stimulated the alkaline phosphatase activity in the bone tissue of the jaws of rats of the 5th group ( $p < 0.001-0.05$  and  $p_1 > 0.1$ ) only after 6 weeks. The results obtained indicate that the use of calcium hydroxyapatite injections at a concentration even 2 times lower than in the 4th group, in combination with

unstabilized hyaluronic acid, can prevent a decrease in the activity of bone alkaline phosphatase during periodontitis (Fig. 1).

The course of the acute inflammatory process in the periodontium caused an increase in the activity of acid phosphatase (AP) in the jaws of rats (Table 1), which indicates active resorption of bone tissue, since this enzyme is considered to be a marker of osteoclast activity. The increase in acid phosphatase was 40.1% after 5 weeks of pathology modeling ( $p < 0.01$ ), 54.0% ( $p < 0.05$ ) - after 7 weeks and 55.7% ( $p < 0.05$ ) after 9 weeks of pathology modeling.

The injection of calcium hydroxyapatite (55.7%) did not have a significant effect on the activity of bone acid phosphatase in rats with periodontitis at the first stage ( $p > 0.05$  and  $p_1 > 0.1$ ). In 4 and 6 weeks after injections, the inhibitory effect of hydroxyapatite on the activity of acid phosphatase in the jaws of rats with periodontitis was established. The level of this indicator corresponded to normal values ( $p > 0.1$ ).

Injections of calcium (55.7%) in combination with stabilized hyaluronic acid had a more pronounced inhibitory effect on the activity of acid phosphatase, and hence on the resorption of bone tissue in the jaws of rats with periodontitis. The activity of acid phosphatase in the jaws of the 4th group of rats decreased to normal in 2 weeks after injections ( $p > 0.1$  and  $p_1 < 0.01$ ). At the subsequent stages of the study, the activity of the bone resorption marker was low and corresponded to the values in intact animals ( $p > 0.1$  and  $p_1 < 0.01-0.05$ ), Fig. 2.

The composition of calcium (27.85%) with unstabilized hyaluronic acid only at the last stage, 6 weeks after its injection, reduced the activity of acid phosphatase in the jaws of rats to a level that was intermediate between normal and periodontitis ( $p > 0.1$  and  $p_1 > 0.1$ , Table 1).

Table 1 shows the results of a study of the activity of bone elastase in the jaws of rats with periodontitis. It is known that this enzyme takes part in the hydrolysis of the protein part of the bone tissue. After 5 weeks of consumption of peroxidized oil by rats, the activity of elastase in the bone tissue of the jaws increased by 63.7% ( $p < 0.002$ ), by 88.9% ( $p < 0.001$ ) - after 7 weeks and by 76.7% ( $p < 0.001$ ) after 9 weeks of modeling the pathology (Table 1).

Injection of calcium hydroxyapatite (55.7%) to rats of the 3rd group prevented an increase in the

activity of elastase in the bone tissue of rats with periodontitis only 2 weeks after injections ( $p > 0.1$  and  $p_1 > 0.1$ ). At subsequent stages of the study, the activity of elastase in the bone tissue of rats of this group was high ( $p_1 > 0.05-0.1$ ), which indicates the low ability of calcium hydroxyapatite without hyaluronic acid to inhibit the destruction of bone tissue (Table 1).

The activity of elastase in the bone tissue of rats of the 4th group, which was injected with calcium hydroxyapatite (55.7%) in combination with stabilized hyaluronic acid, was low and corresponded to the level in intact animals at all stages of the analysis ( $p > 0.05-0.1$  and  $p_1 < 0.001-0.01$ ) Fig. 3.

Calcium hydroxyapatite (27.85%) with unstabilized hyaluronic acid also had an inhibitory effect on collagen destruction in the jaws of rats with periodontitis, since the elastase activity in the 5th group did not exceed normal values ( $p > 0.05-0.1$ ) and was lower than with periodontitis ( $p_1 < 0.01-0.05$ ). It is important to emphasize that the calcium concentration in this group is 2 times lower than in the 3rd and 4th groups, which indicates a more pronounced ability of the calcium composition with hyaluronic acid to inhibit the destruction of bone tissue collagen induced by lipid peroxides (Fig. 3).

In the gums of rats with periodontitis, the markers of inflammation were determined - the level of MDA (malondialdehyde), the activity of acid phosphatase and elastase. As you can see from the table. 2, modeling of periodontitis causes the accumulation of the secondary product of lipid peroxidation, malondialdehyde (MDA), in the gums of rats of the 2nd group. Its content increased after 5 weeks by 54.8% ( $p < 0.02$ ), after 7 weeks - by 82.2% ( $p < 0.001$ ) and after 9 weeks - by 74.1% ( $p < 0.001$ ). This indicates the intensification of peroxide processes in the gum tissue. The injection of calcium hydroxyapatite into rats of the 3rd group did not significantly affect the MDA level in the rat gum after 2 weeks ( $p_1 > 0.2$ ). After 4 weeks, a decrease in this indicator was recorded by 1.4 times ( $p_1 < 0.001$ ), and after 6 weeks - a more significant (1.6 times) decrease in the MDA level ( $p > 0.6$  and  $p_1 < 0.001$ ).

The content of MDA in the gums of animals of the 4th group decreased significantly 4 weeks after injection ( $p_1 < 0.002$ ) and to the normal level at the last period of the study ( $p > 0.7$  and  $p_1 < 0.001$ ).

The composition of calcium hydroxyapatite with unstabilized hyaluronic acid reduced the MDA level to the greatest extent at the 1st observation period ( $p_1 < 0.05$ ) and turned out to be the most effective, but at the subsequent period no differences in the MDA level in the gums of rats of 3<sup>rd</sup>, 4<sup>th</sup> and 5<sup>th</sup> groups were found. After 6 weeks, the MDA level was high (Table 2), which indicates a rapid, but not prolonged antioxidant effect of this composition ( $p < 0.01$  and  $p_1 < 0.002$ ).

Studies have shown an intensification of lipid peroxidation in the gums of rats that consumed long-term peroxidized oil, as well as the ability of calcium hydroxyapatite drugs, to a greater extent in combination with hyaluronic acid, to prevent the accumulation of the toxic product MDA in the gums of rats, induced by an alimentary excess of lipid peroxides (Fig. 4).

Acid phosphatase (AP) is a marker of increased membrane permeability. It is known that the development of inflammation is accompanied by a sharp increase in the activity of this enzyme in tissues, and therefore, the activity of acid phosphatase is considered to be a marker of inflammation [3]. An alimentary excess of lipid peroxides led to a significant increase in the activity of acid phosphatase in the gum tissue of rats of the 2nd group, as evidenced by the results presented in table. 2. So, after 5 weeks of modeling periodontitis in the gums of animals, an increase in acid phosphatase activity was noted by 24.4% ( $p < 0.05$ ), after 7 - by 29.3% ( $p < 0.01$ ), and after 9 weeks - by 49.8% ( $p < 0.002$ ). The results obtained indicate the development of inflammation in the gums of animals under the influence of long-term consumption of lipid peroxides with food (Table 2).

Injections of calcium hydroxyapatite to animals with periodontitis decreased after 2 weeks the acid phosphatase activity in the gums to normal ( $p > 0.8$  and  $p_1 < 0.01$ ). Subsequently, the activity of acid phosphatase in the gums of rats of the 3rd group remained low ( $p > 0.7-0.8$  and  $p_1 < 0.001-0.002$ ).

Lower values of this marker of inflammation were registered in the gums of rats of the 4<sup>th</sup> group. The acid phosphatase activity in the gums of rats of this group 4 weeks after injection was 29.9% lower than in animals of the 2nd group ( $p > 0.4$  and  $p_1 < 0.001$ ) and 38.3% lower after 6 weeks ( $p > 0.5$  and  $p_1 < 0.001$ ) Figure 5.

The use of calcium hydroxyapatite in combination with unstabilized hyaluronic acid in rats of the 5th group caused a significant decrease in the activity of acid phosphatase in the gums of animals at the last observation period - 6 weeks after injection of the drug composition ( $p > 0.3$  and  $p_1 < 0.01$ ).

According to the analysis of acid phosphatase, the most effective composition was calcium hydroxyapatite with stabilized hyaluronic acid (Table 2).

Reproduction of periodontitis promoted an increase in the activity of elastase in the gums of rats by 36.9% ( $p < 0.02$ ) after 5 weeks, by 44.4% ( $p < 0.001$ ) - after 7 weeks and by 41.9% ( $p < 0.001$ ) - after 9 weeks of modeling pathology (table 2).

It is important to note that 2 weeks after injections of all drugs, the activity of elastase in the gum tissues increased more significantly than in the gums of animals of the 2nd group, in which periodontitis was modeled and did not receive treatment ( $p_1 < 0.01-0.05$ ). Since other markers of inflammation (MDA level and acid phosphatase activity) in the gums of rats of groups 3-5 at this time of observation either did not change or decreased, it can be assumed that such an increase in elastase activity may be associated not with an inflammatory reaction, but with active rearrangement of elastic fibers of gum tissue caused by the injection of drugs. Evidence of this was the analysis data at the next stage - 4 weeks after the injection. The degree of elastase activity in the gums of animals of groups 3-5 did not exceed the value of this indicator in the gums of rats of the 2nd group ( $p_1 > 0.2-0.4$ ) Fig. 6.

6 weeks after injections of calcium hydroxyapatite or its combined injection with hyaluronic acid, a decrease in elastase activity in the gums of all experimental groups of rats ( $p_1 < 0.001$ ) to normal values ( $p > 0.3-0.8$ ) was recorded. The obtained results, along with the normalization of the MDA level and the activity of acid phosphatase in the gums of rats with periodontitis, indicate the absence of inflammation in the soft tissues of the periodontitis during periodontitis, and hence the anti-inflammatory efficacy of the studied drugs.

Thus, analyzing the results obtained, it can be concluded that the most pronounced inhibitory effect on the enhanced bone resorption of the jaws

of rats with peroxide periodontitis was exerted by calcium hydroxyapatite at a concentration of 55.7% with stabilized hyaluronic acid. The effectiveness of this drug can be explained by the inhibition of the activity of destructive bone enzymes, as well as in the normalization of bone mineralization processes by increasing the activity of alkaline phosphatase.

Unexpectedly, the calcium drugs turned out to be effective at a concentration of 27.85%, which is 2 times lower than the others, but in combination with 2% unstabilized hyaluronic acid. Apparently, the inhibition of the activity of destructive enzymes of acid phosphatase and, to a greater extent, elastase of the jaw bone tissue occurs under the influence of the injection of unstabilized hyaluronic acid [2]. This composition turned out to be the most effective in terms of the degree of influence on MDA after 2 weeks and kept the effect up to 4 weeks, but after 6 weeks the level of MDA was high (Table 2), that is, the effect is fast, but requires course of injections.

Analysis of markers of inflammation in the gums of rats with periodontitis established the activation of lipid peroxidation by an increase in the MDA level, an increase in the permeability of lysosomal membranes in terms of acid phosphatase activity, and an increase in the destruction of elastic fibers of the soft tissues of the periodontitis due to an increase in elastase activity. The injection of calcium hydroxyapatite, as well as its combinations with stabilized or unstabilized hyaluronic acid after 6 weeks, contributed to the normalization of all studied parameters, which means that it showed anti-inflammatory efficacy. The anti-inflammatory advantage can be noted for injections of calcium hydroxyapatite with hyaluronic acid.

Taking into account the relevance of the topic, the obtained reliable results of the effectiveness of calcium hydroxyapatite drugs with hyaluronic acid, light injection technique that does not require surgical specialization and operating room, we consider it is necessary to carry out further studies to study the anti-inflammatory efficacy of calcium hydroxyapatite drugs with hyaluronic acid for preventive and therapeutic purposes in periodontitis.

### Conclusions

1. Nutritional intake of peroxidized sunflower oil led to the activation of resorption in the jaws of rats:

an increase in the activity of destructive enzymes (acid phosphatase and elastase) against the background of a decrease in the activity of alkaline phosphatase involved in mineralization.

2. Injection of calcium hydroxyapatite drugs with hyaluronic acid promoted inhibition of acid phosphatase (by 25.1 - 32.4%) and elastase (by 25.7 - 37.2%), as well as an increase in the activity of alkaline phosphatase in the bone tissue of animals (by 19.4 - 24.8%). Alkaline phosphatase activity in rats injected with calcium hydroxyapatite alone remained low, as in periodontitis.

3. The calcium hydroxyapatite drug with a concentration of 27.85%, which is 2 times lower than the others, but in combination with 2% unstabilized hyaluronic acid increased the calcium content to almost normal. Apparently, the level of calcium was restored due to inhibition of the activity of destructive enzymes of acid phosphatase and, to a greater extent, elastase of the jaw bone tissue under the influence of the injection of unstabilized hyaluronic acid.

4. Injections of calcium hydroxyapatite drugs with hyaluronic acid had a pronounced anti-inflammatory effect on the soft tissues of the periodontium, reducing the level of MDA in homogenates of the gums of rats with periodontitis by 24.6 - 40.3%, the activity of acid phosphatase - by 25.3 - 38.3%, elastase activity - by 23.5 - 29.8%.

5. The concentration of calcium hydroxyapatite did not show a direct dependence on the experimental results. In the groups, where the concentration was 55.7%, but there was no hyaluronic acid, the result was worse than in the group, where the concentration of calcium hydroxyapatite was 2 times lower, but with the addition of hyaluronic acid.

### Acknowledgments

The authors declare that there are no conflicts of interest.

### References

1. Lapach S.N., Chubenko V.A., Babich P.N. Statistical Methods in Life Sciences Research Using Excel. Moscow : Morion, 2000. 320 p [In Russian].
2. Larkina S.A., Seletskaya A.V., Makarenko O.A. Study of anti-inflammatory efficacy of hyaluronic

acid preparations of various concentrations in rats with experimental periodontitis. Bull Dentistry. 2019; 31 (1): 2-7 [In Russian].

3. Levitsky A.P., Makarenko O.A., Demyanenko S.A. Experimental dentistry methods. Simferopol : Publishing House "Tarpan", 2018. 78 p [In Russian].
4. Al-Shammar N.M., Shafshak S.M., Ali M. S. Effect of 0.8% Hyaluronic Acid in Conventional Treatment of Moderate to Severe Chronic Periodontitis. J Contemp Dent Pract. 2018; 19 (5): 527-534.
5. Casale M., Moffa A., Vella P. Hyaluronic acid: Perspectives in dentistry. A systematic review. International Journal of Immunopathology and Pharmacology. 2016; 29 (4): 572-582.
6. Debnath T., Chakraborty A., Tamal K.P. A clinical study on the efficacy of hydroxyapatite - Bioactive glass composite granules in the management of periodontal bony defects. J Indian Soc Periodontol. 2014; 18 (5): 593-600.
7. Kaneko A., Marukawa E., Harada H. Hydroxyapatite nanoparticles as injectable bone Substitute Material in a Vertical Bone Augmentation Model. In vivo. 2020; 34: 1053-1061.
8. Larkina S.O., Makarenko O.A., Vastyanov R.S., Yermuraki P.P. Investigation of calcium- and hyaluronic acid-containing drugs osteoplastic activity in rats with periodontitis. World of Medicine and Biology. 2020; 1(71): 191-196.
9. Leal A.M.C., Beserra D.S.M.V., da Silva F.E.C., Menezes de Carvalho A.L., Tabchoury C.P.M., Vale G.C. Development of an Experimental Dentifrice with Hydroxyapatite Nanoparticles and High Fluoride Concentration to Manage Root Dentin Demineralization. Int J Nanomedicine. 2020; 5 (15): 7469-7479.
10. Mendes T.D., Araújo V.A., Filho J.L., Monteiro L.B., Guimarães M.V. The use of Hyaluronic Acid as an adjuvant Therapeutic Approach to Non Surgical Periodontal Therapy for Periodontitis. Braz. J. Develop. (Curitiba). 2020; 6 (5): 29219-29234.
11. Salwowska N.M., Bebenek K.A., Żądło D.A., Wcisło-Dziadecka D.L. Physicochemical properties and application of hyaluronic acid: a systematic review. Journal of Cosmetic Dermatology. 2016; 15: 520-526.

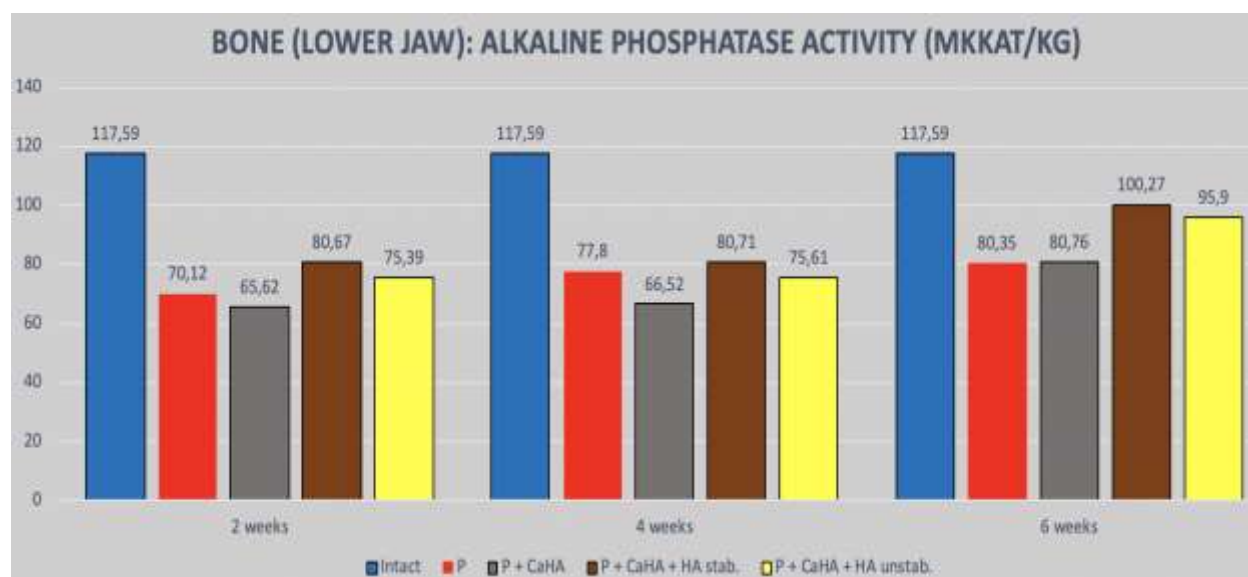
**Table 1.** The effect of calcium and hyaluronic acid drugs on the activity of alkaline phosphatase, acid phosphatase and elastase in the bone tissue of the lower jaw of rats with experimental periodontitis

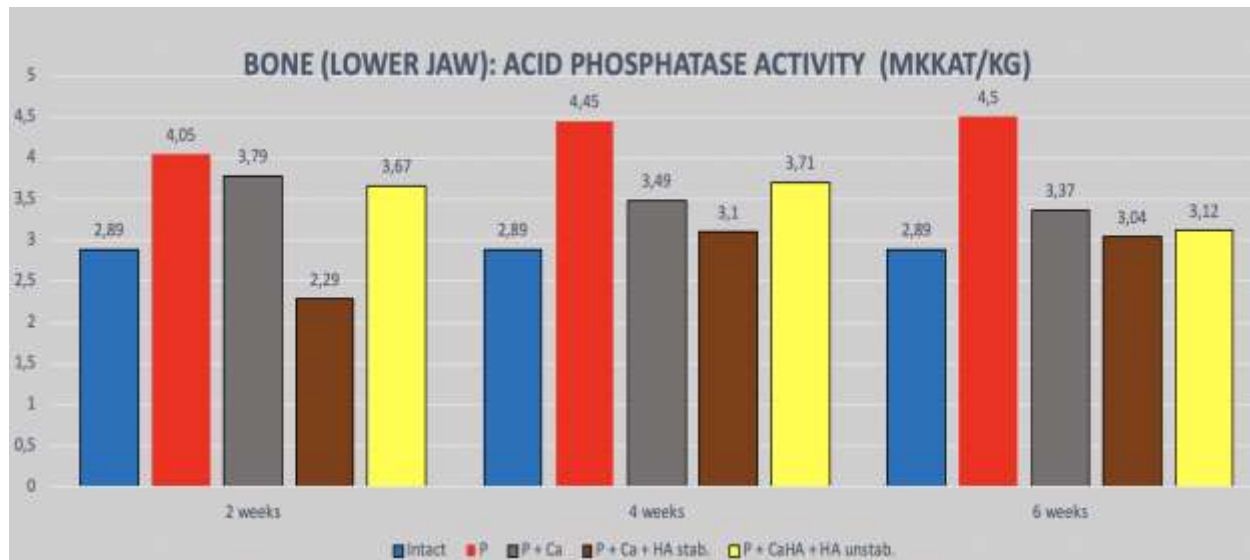
N	Group	2 weeks after injections (5 weeks simulated periodontitis)			4 weeks after injections (7 weeks simulated periodontitis)			6 weeks after injections (9 weeks simulated periodontitis)		
		Alkaline Phosphatase $\mu\text{cat}/\text{kg}$	Acid Phosphatase $\mu\text{cat}/\text{kg}$	Elastase $\mu\text{cat}/\text{kg}$	Alkaline Phosphatase $\mu\text{cat}/\text{kg}$	Acid Phosphatase $\mu\text{cat}/\text{kg}$	Elastase $\mu\text{cat}/\text{kg}$	Alkaline Phosphatase $\mu\text{cat}/\text{kg}$	Acid Phosphatase $\mu\text{cat}/\text{kg}$	Elastase $\mu\text{cat}/\text{kg}$
1.	Intact	117,6 $\pm$ 4,67	2,89 $\pm$ 0,51	15,26 $\pm$ 1,09	117,6 $\pm$ 4,67	2,89 $\pm$ 0,51	15,26 $\pm$ 1,09	117,6 $\pm$ 4,67	2,89 $\pm$ 0,51	15,26 $\pm$ 1,09
2.	P	70,12 $\pm$ 5,45***	4,05 $\pm$ 0,31**	24,98 $\pm$ 1,36**	77,80 $\pm$ 4,40***	4,45 $\pm$ 0,07*	28,83 $\pm$ 1,89***	80,35 $\pm$ 3,57***	4,50 $\pm$ 0,40*	26,96 $\pm$ 2,96***
3.	P+Ca	65,62 5,75***	3,79 $\pm$ 0,13	18,91 $\pm$ 2,82	66,53 $\pm$ 7,15***	3,49 $\pm$ 0,21	27,20 $\pm$ 2,89**	80,76 $\pm$ 4,64**	3,37 $\pm$ 0,53	20,03 $\pm$ 1,82*
4.	P+Ca+HA stab	80,67 $\pm$ 3,82	2,29 $\pm$ 0,29##	17,13 $\pm$ 0,70##	80,71 $\pm$ 4,89	3,10 $\pm$ 0,28##	20,98 $\pm$ 3,12#	100,27 $\pm$ 6,29#	3,04 $\pm$ 0,25#	16,92 $\pm$ 1,11###
5.	P+Ca+HA unstab	75,39 $\pm$ 5,02***	3,67 $\pm$ 0,07*	16,98 $\pm$ 2,12#	75,61 $\pm$ 8,68***	3,71 $\pm$ 0,10*	23,28 $\pm$ 1,31#	95,90 $\pm$ 12,19*	3,12 $\pm$ 0,22	18,55 $\pm$ 1,67##

Note:

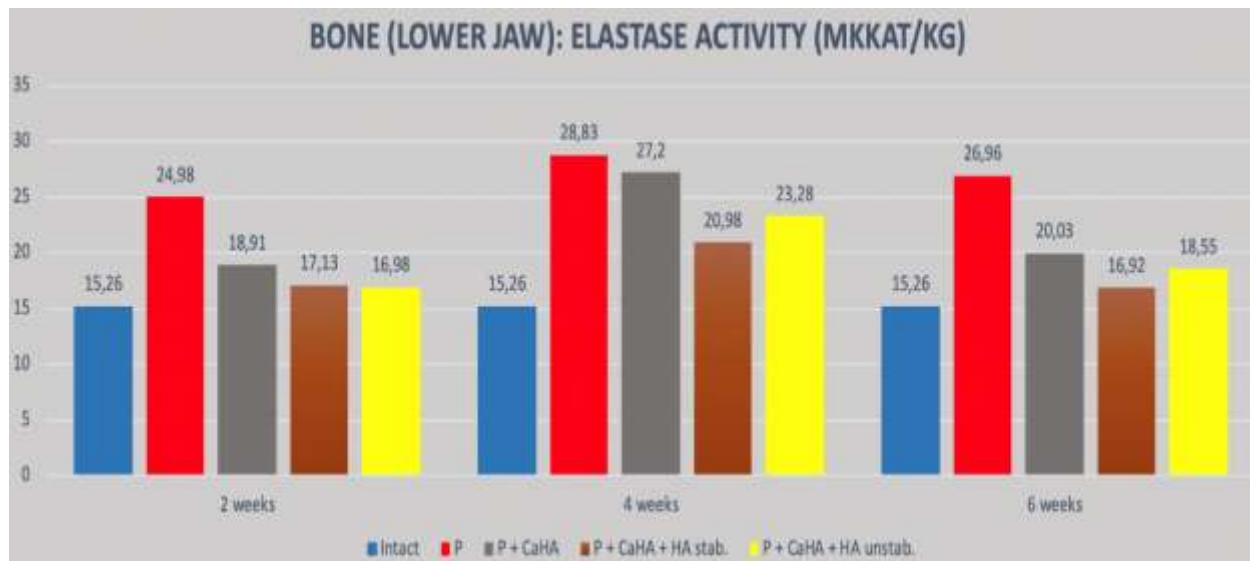
\* –  $p < 0,05$ , \*\* –  $p < 0,01$  and \*\*\* –  $p < 0,001$  - the significant differences of the investigated indexes compared with the analogous data in control observations;

# –  $p < 0,05$ , ## –  $p < 0,01$  and ### –  $p < 0,001$  - the significant differences of the investigated indexes compared with the similar data in animals with periodontitis without treatment (ANOVA+Newman-Keuls test).

**Figure 1.** Influence of calcium and hyaluronic acid drugs on the activity of alkaline phosphatase in the bone tissue of the lower jaw of rats with experimental periodontitis.



**Figure 2.** Influence of calcium and hyaluronic acid drugs on the activity of acid phosphatase in the bone tissue of the lower jaw of rats with experimental periodontitis.



**Figure 3.** The effect of calcium and hyaluronic acid drugs on the activity of elastase in the bone tissue of the lower jaw of rats with experimental periodontitis.



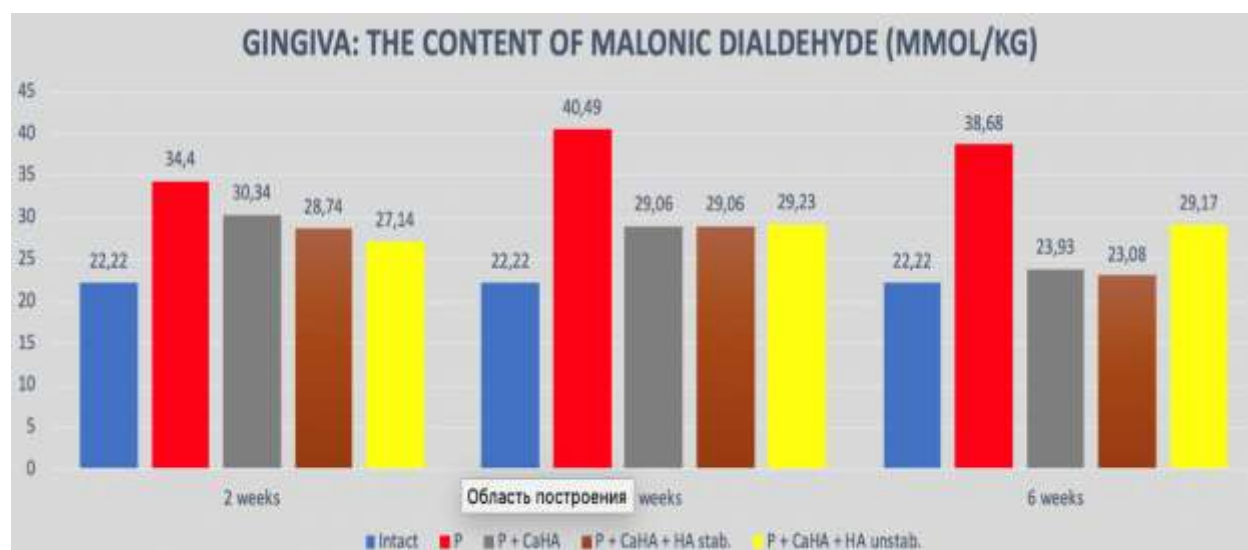
**Table 2.** The effect of calcium and hyaluronic acid drugs on the content of malondialdehyde (MDA), the activity of acid phosphatase (AP) and elastase in the gums of rats with peroxide periodontitis

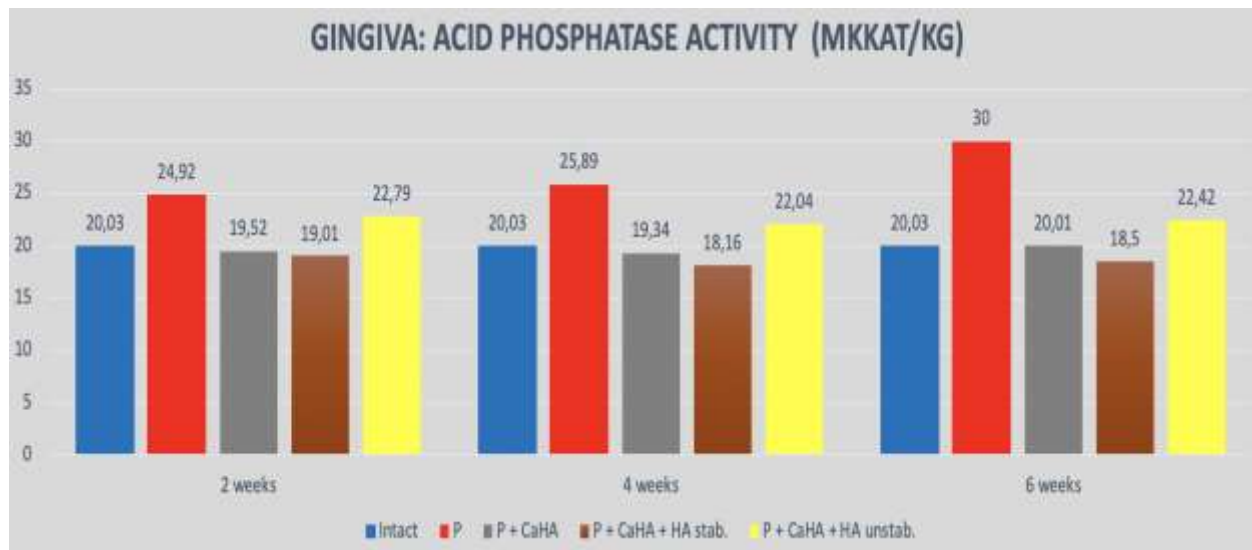
N	Group	2 weeks after injections (5 weeks simulated periodontitis)			4 weeks after injections (7 weeks simulated periodontitis)			6 weeks after injections (9 weeks simulated periodontitis)		
		MDA mmol/kg	Acid Phos- phatase μcat/kg	Elastase μcat/kg	MDA mmol/kg	Acid Phos- phatase μcat/kg	Elastase μcat/kg	MDA mmol/kg	Acid Phos- phatase μcat/kg	Elastase μcat/kg
1.	Intact	22,22± 2,01	20,03± 1,64	53,33± 2,05	22,22± 2,01	20,03± 1,64	53,33± 2,05	22,22± 2,01	20,03± 1,64	53,33± 2,05
2.	P	34,40± 3,12**	24,92± 1,62*	73,00± 5,37*	40,49± 2,35***	25,89± 1,28**	77,00± 1,51***	38,68± 1,88***	30,00± 2,19**	75,67± 1,46***
3.	P+Ca	30,34± 0,63*	19,52± 1,16##	87,44± 5,19***	29,05± 1,22***###	19,34± 1,24##	81,22± 2,59***	23,93± 2,23###	20,01± 0,60###	57,89± 3,62###
4.	P+Ca+HA stab	28,74± 0,88**	19,01± 1,50##	89,67± 6,24***#	29,07± 1,64*##	18,16± 1,30###	72,22± 5,60**	23,08± 1,48###	18,50± 1,62###	54,00± 2,23###
5.	P+Ca+HA unstab	27,14± 1,27*#	22,79± 2,01	94,44± 3,53***##	29,23± 1,05**##	22,04± 1,59	69,13± 4,53**	29,17± 1,43***#	22,42± 1,56##	53,11± 3,71###

Note:

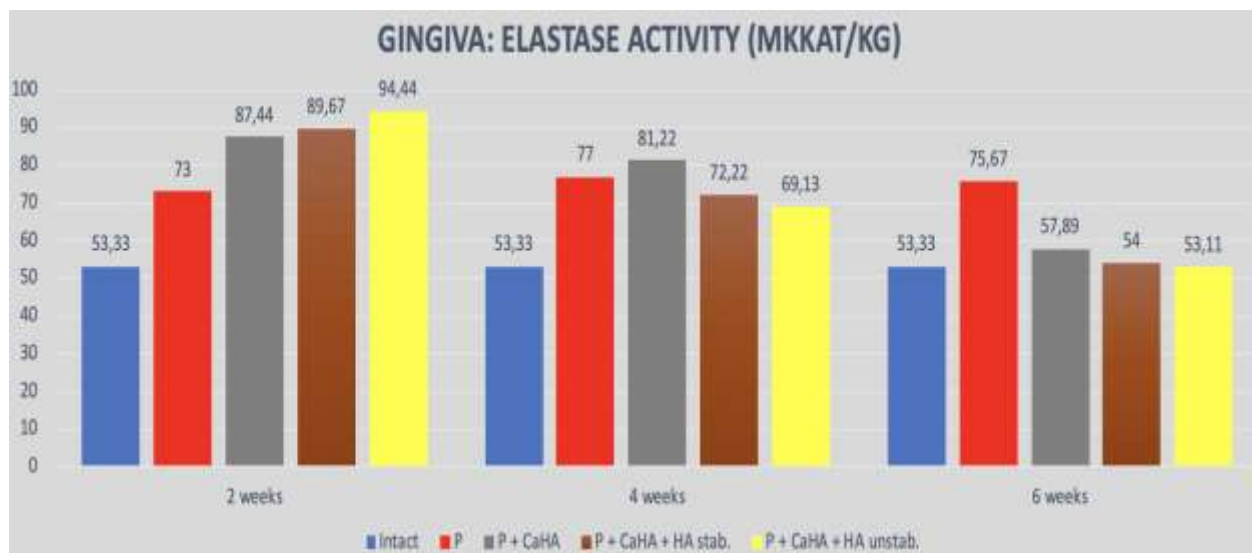
\* –  $p < 0,05$ , \*\* –  $p < 0,01$  and \*\*\* –  $p < 0,001$  - the significant differences of the investigated indexes compared with the analogous data in control observations;

# –  $p < 0,05$ , ## –  $p < 0,01$  and ### –  $p < 0,001$  - the significant differences of the investigated indexes compared with the similar s data in animals with periodontitis without treatment (ANOVA+Newman-Keuls test).

**Figure 4.** Influence of calcium and hyaluronic acid drugs on the content of malondialdehyde (MDA) in the gums of rats with experimental periodontitis.



**Figure 5.** The effect of calcium and hyaluronic acid drugs on the activity of acid phosphatase in the gums of rats with experimental periodontitis.



**Figure 6.** The effect of calcium and hyaluronic acid drugs on elastase activity in the gums of rats with experimental periodontitis.