

The journal has had 5 points in Ministry of Science and Higher Education parametric evaluation. § 8. 2) and § 12. 1. 2) 22.02.2019.
© The Authors 2020;

This article is published with open access at Licensee Open Journal Systems of Nicolaus Copernicus University in Torun, Poland
Open Access. This article is distributed under the terms of the Creative Commons Attribution Noncommercial License which permits any noncommercial use, distribution, and reproduction in any medium, provided the original author (s) and source are credited. This is an open access article licensed under the terms of the Creative Commons Attribution Non commercial license Share alike. (<http://creativecommons.org/licenses/by-nc-sa/4.0/>) which permits unrestricted, non commercial use, distribution and reproduction in any medium, provided the work is properly cited.
The authors declare that there is no conflict of interests regarding the publication of this paper.

Received: 09.11.2020. Revised: 25.11.2020. Accepted: 24.12.2020.

WAYS TO IMPROVE EXTERNAL STRUCTURES FOR OSTEOSYNTHESIS OF DISTAL HUMERUS FRACTURES (EARLY RESULTS)

A. I. Bodnya, S. L. Dubovik

The Odessa National Medical University, Ukraine

ORCID Bodnya A.I. – [org/0000-0002-4042-3599](https://orcid.org/0000-0002-4042-3599)

ORCID Dubovik C. L. – <https://orcid.org/0000-0001-7754-1524>

Abstract

The results of the first clinical application of the developed external device for osteosynthesis of distal humerus fractures are presented. **Purpose:** to improve the extrafocal method of reposition and fixation of humerus shaft fractures at the level of the lower third, taking into account the anatomical and physiological features of the area damaged. **Material and methods:** Functional, basic fixing and repositioning capabilities of the previously used external device, its advantages and disadvantages are considered. A minimally invasive guided technique for external rod fixation in the treatment of low third humerus' fractures is described. An improved version of the apparatus layout and transosseous osteosynthesis technology was used in 10 patients. The design of the device allows to eliminate the displacement of the humerus fragments, ensures the stability of their fixation, while maintaining the function of the elbow joint. The indications for the use of external fixation were extra-articular fractures of the humerus in the distal third - type 12A (n = 6), 12B (n =3) and 12C (n =1) according to the AO / ASIF classification. **Results:** The analysis of treatment outcomes showed that the technology of minimally invasive osteosynthesis allows to achieve positive results in most patients with a minimum of complications - 90.5 ± 3.3 points

according to MEPS's clinic method of assessing the function of the elbow joint. **Conclusions:** The developed device for transosseous osteosynthesis of distal humerus fractures, is the method of choice and can be widely used in traumatology and orthopedics.

Key words: humerus fracture; lower third part of humerus shaft; transosseous osteosynthesis

Introduction. Fractures of the humerus in its distal third part form 30% of cases. The treatment of this localization fractures (type 12A-C according to the AO/ASIF classification) presents certain difficulties in distal fragment reposition and fixation [1, 8, 10].

Despite the modern active surgical tactics of the Swiss AO and medical rehabilitation, unsatisfactory results of treatment range from 19.3 to 62% [4], and disability is 13–20% [6]. The incidence of various complications in ORIF of the distal third of the humerus remains high, for example ununited fractures and false joints account for about 15%, contractures of the elbow joint - 82%, damage to the nerve trunks - 17.1%, heterotopic ossification - 28.2 - 49% [5, 7].

The data presented indicate this injury high severity and an insufficient quality of medical care provided. These determines the urgency of the problem and need to find ways of its solution. The search for optimal technical solutions in creating devices for transosseous osteosynthesis by simplifying the installation of the structure and increasing its functionality is currently of great scientific and practical interest.

Purpose: to improve the extrafocal method of reposition and fixation of humerus shaft fractures at the level of the lower third, taking into account the anatomical and physiological features of the area damaged.

Materials and methods. To create favorable conditions for anatomical reposition and union of fragments, as well as to provide the earliest possible movements in the elbow joint was the main point in the treatment of patients with the humerus shaft fractures at the level of the lower third. For this, we evaluated the technical capabilities of the previously used device of the original design, analyzed our own experience of its clinical use in the treatment of patients with diaphyseal fractures of the humerus [2]. Despite the rather favorable treatment results achieved, the variability of the technique depending on the nature and level of the fracture plane, the features of the angular displacements of the bone fragments of the distal shoulder, led us to the need to improve the reposition technique with the use of threaded rods. In an effort to optimize the functionality of the device by eliminating the identified

shortcomings and increasing its repositioning capabilities, we changed, first of all, the layout of the repositioning support structure (Fig. 1).



Fig 1. Devices for transosseous osteosynthesis of diaphyseal fractures of humerus at the level of the lower third: original (a) and improved (b) design layout

The development was based on the following tasks: 1) to create a design, the parameters of which allow to effect a common mounting for the victims with different shoulder lengths; 2) optimize the number of threaded rods in the device to achieve stable fixation of shoulder fragments for the period necessary for knitting consolidation; 3) to ensure the mobility of repair nodes in different planes and directions to control the distal fragment of the humerus; 4) to provide conditions in the device that allow to preserv the function of the elbow joint in the early postoperative period. Our goal was achieved by developing a device and technology for controlled external fixation of the humerus shaft fractures at the level of the lower third. The authors took out a patent for the development mentioned (Ukrainian patent No. 119470 dated 06.25.2019).

The device proposed (Fig. 1-b) is one-sided external fixing rod based on G. A. Ilizarov's apparatus and "Osteomechanic" [3], the design of which forms two supports - stabilizing and repositioning. We have been using the improved external fixation device in clinical practice since 2019 in the treatment of 10 patients with isolated fractures of the distal third of the humerus. The patients aged 19 - 56 years old (mean age 40.2 years) among them

there were 8 men and 2 women. 6 patients extra-articular fractures of the humerus in the distal third (type 12A), 3 patients had a fracture of 12B type and 1 patient had 12C type fracture according to AO / ASIF classification.

Fractures with a direct mechanism of injury were caused by a fall on the arm in 8 cases, with an indirect one (arm wrestling competitions) - in 2 cases. Damage of the right shoulder had 6 victims, the left one was damaged in 4 persons. Open fractures of I-II severity according to Gustilo R.B. & Anderson J.T. (1976) were diagnosed in 2 patients. The fractures appeared as a result of perforation of the skin of the shoulder with fragments from the inside. All patients underwent primary surgical debridement upon admission. Clinical and radiological examination was carried out according to the standard scheme of patients' examination, both at admission and in the preoperative period. Surgical interventions were performed within 2 to 5 days after the injury. There were no complications after surgery, antibiotic therapy, daily bandaging with antiseptics was performed. The next day after the application of the device, the patients began to perform movements in the elbow joint. The average length of stay in hospital was 7.4 days.

Results and discussion. Early results of treatment (6 - 12 months) were studied in 8 patients, two patients still continue treatment. The follow-up examination of patients after discharge was carried out once every 6 weeks. The apparatus's timing of fixation depended on the nature of the fracture and clinical and radiological signs of consolidation. So, for fractures type 12A the average fixation period was up to 3 months, for comminuted fractures (types B and C) - 4 - 5.5 months. Rehabilitation carried out in the postoperative period made it possible, in the overwhelming majority, to avoid complications and speed up the process of rehabilitation treatment in patients after the device was dismantled. In the treatment of fractures of the distal third of the humerus, the main group consisted of late complications: inflammation of the soft tissues around the rod in 2 patients, delayed consolidation in 1 patient. The causes of the complications mentioned depended on the trauma severity and patients' in compliance of the recommendations got after their discharge from the hospital. These complications did not require premature dismantling of the apparatus, since all of the complications were stopped as a result of therapeutic measures taken and did not significantly affect the outcome.

Early treatment outcomes were determined using the MEPS elbow function assessment technique [9]. Based on the data obtained, the examined patients had a positive

result, where the average outcome was 90.5 ± 3.3 points (from 80 to 96). We present one of our observations of surgical treatment as a clinical example.

Patient G., 38 years old, medical history sheet N 1867, was injured on May 25, 2019, was admitted to the emergency department after an industrial injury - he fell from scaffolding. The victim was taken to the hospital by the ambulance team, where, upon admission, radiation diagnostics was performed (Fig. 2-a, b), post-traumatic neuropathy of the radial nerve and a wound on the inner surface of the lower third of the left shoulder 1×0.5 cm were clinically determined.

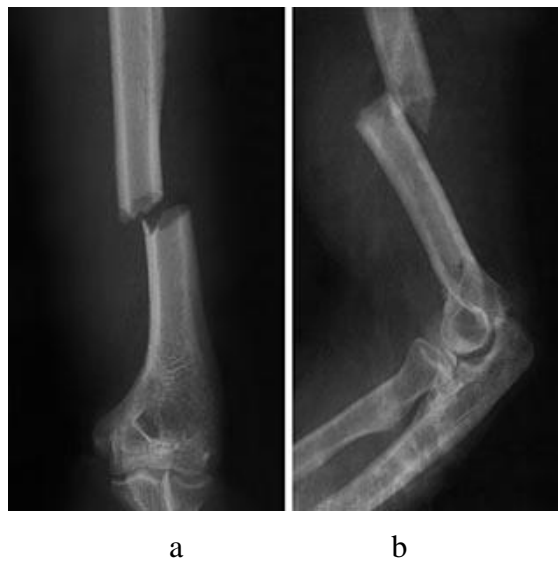

Fig. 2. Photographs of radiographs of the elbow joint in direct (a) and lateral (b) projections upon admission

As a result of clinical and radiological examination, a secondary open (I degree of severity according to Gustilo R.B. and Anderson J. T., 1976) transverse fracture of the left humerus in the lower third with displacement of fragments (type 12A3) was diagnosed. Closed fracture of the base of the III - IV metacarpal bones of the left hand without displacement. Primary surgical treatment of the wound was performed followed by immobilization with a plaster bandage of the left wrist joint. After a consultation with a neurologist and the appropriate treatment was prescribed. The patient was hospitalized in the trauma department, where on May 27, 2019 transosseous osteosynthesis of the left shoulder with a rod device of our design (Fig. 3) was performed.

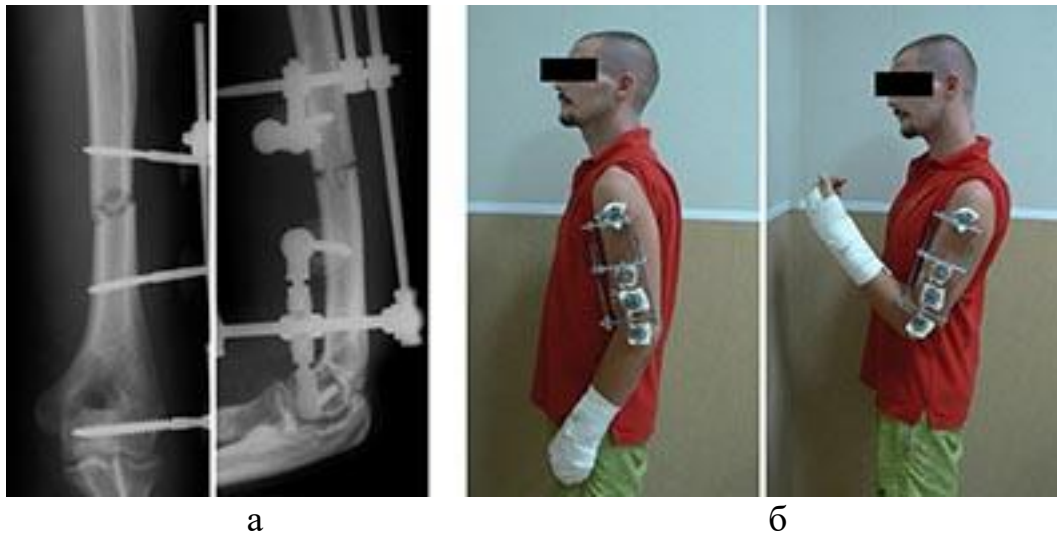


Fig. 3. Photographs of control radiographs (a) and functional result (b) after surgery

During operation the displacement of bone fragments was eliminated, the axis of the limb was restored (Fig. 3-a). In order to prevent inflammation of soft tissues in the postoperative period the patient underwent antibiotic therapy, dressings with antiseptics. Exercise therapy of adjacent joints was conducted. The wound healed by primary intention, the sutures were removed on the 10th day, the patient was discharged from the hospital for outpatient observation with a range of motion in the elbow joint - S: 20°/ 0 /100° (Fig. 3-b). The apparatus was dismantled in 3 months after the operation, at the same time the restoration of the radial nerve was established. During the control X-ray examination in 12 months after the injury, the fusion of bone fragments was determined (Fig. 4-a). During a clinical examination, the restoration of the range of motion in the elbow joint was established in full - S: 0°/ 0 /150° (Fig. 4-b).

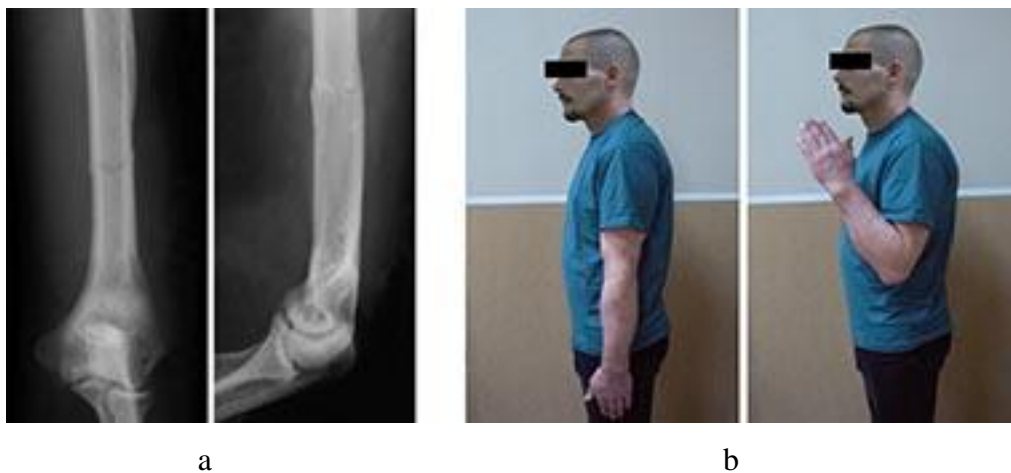

Fig. 4. Photographs of control radiographs (a) and functional result (b), 12 months after treatment

The anatomical and functional result according to the MEPS clinical scale was rated as excellent (100 points). Working capacity was restored in 8 months after the injury.

Thus, a minimally invasive technology for osteosynthesis of distal humerus fractures and an optimal course of restorative treatment are the key to achieving positive anatomical and functional results after surgery, and also provide for the prevention of complications and preparation for continuing professional activities.

Conclusions. We believe that the continuation of research in this direction is appropriate, since further improvement and introduction of new minimally invasive developments into clinical practice will increase the effectiveness of surgical treatment of distal humerus fractures.

The device for transosseous osteosynthesis of fractures of the humeral shaft at the level of the lower third among the known modern fixators is the method of choice, since it allows to eliminate all types of displacements, provides stable fixation of fragments for the period of union, while maintaining the function of the joints, and can be widely used in traumatology and orthopedics.

Conflict of interest: The author declares that there is neither conflict of interest no financial interest in the preparation of this article.

References:

1. Bets I.G. Surgical treatment of fractures of the humerus and biological aspects of osteosynthesis / I.G. Bets // Trauma. - 2017. - No. 6 (18). – P. 167-173. doi: 10.22141/1608-1706.6.18.2017.121196
2. Bodnya A. I. Apparatus for external osteosynthesis of fractures of the distal third of the humerus / A. I. Bodnya, V. Kh. Slavov, S. N. Krivenko // Orthopedics, traumatology and prosthetics. - 2010. - No. 4. - P. 60-64.
3. Kataev I.A. Unified combined spitting system through bone-managed fixation "Osteomehanik" / I.A. Kataev, V.P. Tansyura, O.Ya. Lobko // Register of medical, biological and scientific and technical innovations. - Kyiv, 1995. - VIP. 5. - No. 42/5/5.
4. Kurinny I.M., Strafun O.S. The results of the treatment of ailments with fractures of the distal epimetaphysis of the humerus cyst and their findings / I.M. Kurinny, O.S. Strafun / Trauma. - 2019. - No. 3 (20). – P. 60-67. doi: 10.22141/1608-1706.3.20.2019.172095
5. Prevention, treatment and rehabilitation of post-traumatic and post-operative contractures of the elbow joint / A. A. Buryanov, V. P. Kvasha, I. A. Solovyov, D. Yu.

Kovalchuk, D. A. Chekushin // Chronicle of Traumatology and Orthopedics. - 2018. - No. 3-4 (39-40). – P. 143-147. URL: http://nbuv.gov.ua/UJRN/Lto_2018_3-4_28

6. The rate of disability after injuries of the upper limb in Ukraine for 2017 / L. Yu. Naumenko, A. V. Ipatov, T. O. Zub, A. O. Mametiev // Trauma. - 2018. - No. 4 (19). – P. 9 - 14. doi: 10.22141/1608-1706.4.19.2018.142100

7. The frequency of aggravation of diaphyseal fractures of limbs by the data of Kharkiv traumatological medical expert commission / O. K. Popsuyshapka, V. O. Litvishko, O. E. Uzhigova, O. O. Pidgaiska // Orthopedics, traumatology and prosthetics. - 2020. - No. 1 (618). – P. 20-25. doi: 10.15674/0030-59872020120-25

8. Conservative vs. operative treatment for humeral shaft fractures: a meta-analysis and systematic review of randomized clinical trials and observational studies / B.J.M. Van de Wall, Y. Ochen, F.J.P. Beeres, R. Babst, B.C. Link, M. Heng // J. Shoulder Elbow Surg. - 2020. - Vol. 29(7). - P. 1493-1504. doi:10.1016/j.jse.2020.01.072

9 Morrey B.F. Functional evaluation of the elbow / B.F. Morrey, K.-N. An, E.Y. Chao // The elbow and its disorders; Ed. B.F. Morrey. – [Ed. 2nd]. – Philadelphia : W.B. Saunders Company, 1993. - P. 86-89.

10. Sabapaty S.R. Treatment of mutilating hand injuries: An international perspective / S.R. Sabapaty // Hand Clinics. - 2016. - Vol. 32(4). - P. 435-602. doi: 10.1016/S0749-0712(16)30091-9